CASE REPORT

TJG
The Turkish Journal of Gastroenterology

Jejunal stricture in a premature infant: Is cytomegalovirus the causative pathogen or a superinfection?

Aysel ÜNLÜSOY AKSU[1], Sinan SARI[1], Ramazan KARABULUT[2], Özgür EKİNCİ[3], Buket DALGIÇ[1]

Departments of [1]Pediatric Gastroenterology, [2]Pediatric Surgery and [3]Pathology, Gazi University School of Medicine, Ankara

Cytomegalovirus infection can cause gastrointestinal disease, especially in immunocompromised patients and premature infants. In the neonatal period, however, gastrointestinal involvement is infrequent. A case of cytomegalovirus enteritis and jejunal stricture in a preterm neonate is presented. The diagnosis was established after the histopathology of the surgical specimen demonstrated the presence of cytomegalovirus inclusion bodies. Every neonatal gastrointestinal cytomegalovirus infection case has been described in the literature as a necrotizing enterocolitis-like illness, but none of them clearly identifies whether cytomegalovirus was the pathogen responsible for causing necrotizing enterocolitis or whether cytomegalovirus occured as an infection during the course of necrotizing enterocolitis.

Key words: Bowel stricture, cytomegalovirus, newborn

Jejunal striktür ile izlenen prematüre bebekte sitomegalovirüs enfeksiyonu

Sitomegalovirüs enfeksiyonu, özellikle prematüre doğmuş bebeklerde ve immün yetmezliği olan hastalarda gastrointestinal hastalığa yol açabilir. Yenidoğan döneminde gastrointestinal tutulum nadirdir. Bu makalede prematüre doğmuş bebekte sitomegalovirüs enteriti ve jejunal striktür birlikteliği sunulmuştur. Cerrahi olarak çıkarılan barsak segmentinde histopatolojik olarak sitomegalovirüs inklüzyon cisimciklerinin görülmesiyle tanı konulmuştur. Literatürdeki sitomegalovirüs enfeksiyonuna bağlı gastrointestinal tutulumu olan yenidoğanlarda, nekrotizan enterokolit benzeri semptomlar görülmüştür. Ancak, bu vakalarda sitomegalovirüs enfeksiyonunun nekrotizan enterokolit ile ilişkisi gösterilememiştir.

Anahtar kelimeler: Barsak striktürü, sitomegalovirüs, yenidoğan

INTRODUCTION

Cytomegalovirus (CMV) is the most common intrauterine infection with a reported incidence ranging from 0.2 to 2.2% (1). Although only 5-10% of infants with CMV infections are symptomatic, the mortality rate ranges from 20-30%, and 90% of survivors may experience sequalae during the first five years of life (2). Manifestations of in utero infection include growth retardation, skin rashes, chorioretinitis, intra cerebral calcifications, abnormal liver function tests and thrombocytopenia. Death is generally due to disseminated intravascular coagulation, hepatic failure or bacterial infection. If premature infants are infected postnatally such as through blood transfusion, progression will be more rapid and is usually more fatal than congenital infection (3). CMV infection can cause gastrointestinal (GI) disease especially in immunocompromised patients or in premature infants. Although gastrointestinal involvement is infrequent at the neonatal period, it can present in utero as ecogenic

Address for correspondence: Aysel ÜNLÜSOY AKSU
Department of Pediatric Gastroenterology, Gazi University School of Medicine, Ankara, Turkey
E-mail: ayselun@gmail.com

Manuscript received: 02.10.2011 **Accepted:** 18.06.2012

Turk J Gastroenterol 2013; 24 (3): 273-276
doi: 10.4318/tjg.2013.0561

bowel (2), or post natally as jaundice, mucosal ulceration, protein-losing gastropathy, enterocolitis, diarrhea, hematemesis, bloody stool, volvulus, ileal atresia, ileal perforation, ileal and colonic stricture (1,3,4). Pathologic identification of nuclear inclusions on mucosal biopsy confirms the diagnosis. Herein we report the case of a premature infant with probable perinatal CMV infection who was noted to have a jejunal stricture.

CASE REPORT

A 1290 g girl was born at 30 weeks' gestation to gravida 3, para 2, 24-year-old woman via vaginal delivery. Non-invasive oxygen therapy was administered due to neonatal respiratory distress. When the patient was fed enterally on postnatal day 7, she developed abdominal distension and sepsis-like symptoms. Without definite evidence of necrotizing enterocolitis (NEC) on abdominal x-rays, multiple antibiotics were administered. On postnatal day 30, abdominal distension and bilious emesis occurred leading to a preliminary diagnosis of NEC and prompting administration of multiple antibiotics again. The baby continued to have abdominal distension after every meal and rarely passed stool. By postnatal day 60, intermittent episodes of feeding intolerance recurred and no weight gain was noted by this time. Additionally, bilious and bloody aspirates were seen in her feeding tube. Abdominal ultrasonography and tomography revealed distended bowel loops with multiple fluid levels. Intestinal imaging with barium enema showed significant distention of proximal jejunal loops. Four hours later, barium enema had not passed through the distal jejunal segment (Figure 1). Additionally colonic imaging by means of rectal barium enema was normal.

At 88 days of age, she was referred to tertiary gastroenterology and pediatric surgery at our hospital with a diagnosis of jejunal obstruction. On admission, she weighed 1670 g (<3rd percentile) and exhibited evident abdominal distention without an abdominal mass or organomegaly. A laparotomy was then performed at three months of life, which revealed a jejunal stricture (Figure 2). The affected bowel was removed and an end-to-end anastomosis was constructed. After the surgery, she received parenteral nutrition and antibiotic therapy. On postoperative day five, enteral feedings were resumed. Three days later, however, she began to experience respiratory distress and bradycardia, requiring intubation. The patient subsequently died due to nosocomial sepsis.

Pathological examination of surgical specimen showed CMV enteritis and many inclusion bodies scattered in the bowel wall, especially in the endothelial cells (Figure 3). Diffuse ulcerations extended throughout the submucosa. Immunohistologically, the presence of CMV was confirmed in bowel tissue (Figure 4). The whole blood polymerase chain reaction (PCR) test was positive for CMV DNA ($13x10^6$ copy/ml). Cystic fibrosis was excluded by means of gene analysis.

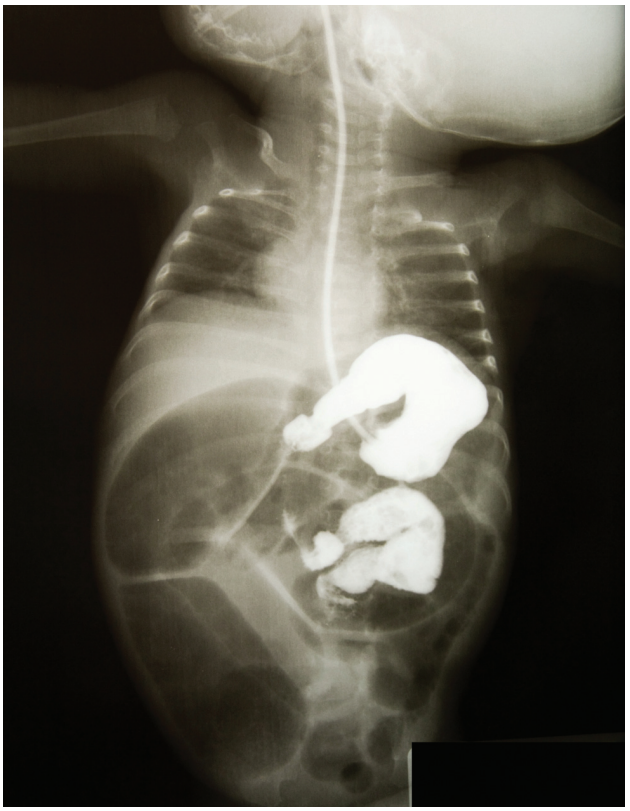

Figure 1. Barium enema of the bowel.

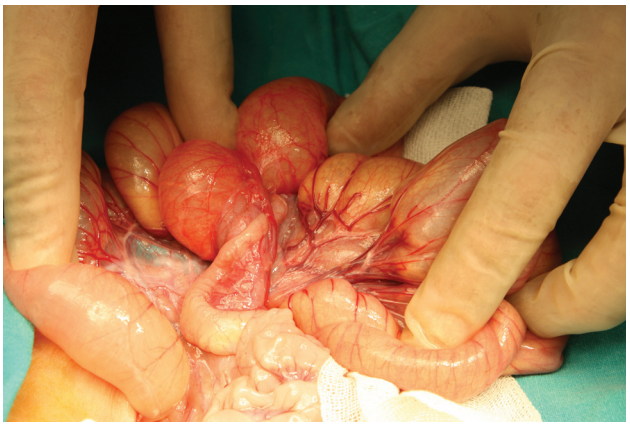

Figure 2. Image of jejunal stricture.

DISCUSSION

All cases of neonatal CMV infection are mentioned in the literature as NEC-like illnesses but none of them clearly identifies whether CMV was the causative pathogen responsible for NEC or whether it occured only as an infection during the course of NEC (5). Most of the patients in the literature were premature babies and most of them showed no other features of the disease, except GI involvement of CMV infection (4, 5).

Possible routes of infection were congenital or perinatal; or related to the means of delivery, transmission in breast milk or transfusion of blood products. It is difficult to distinguish congenital from perinatal infection. Only 5% of CMV-infected neonates are symptomatic at birth (6). Cytomegalovirus infections are characterized by multiple organ' involvement such as the central nervous system, liver, spleen, eyes (1). In this case, there was no hydrocephalus or calcifications on transfontanelle ultrasonography. The patient did not have organomegaly, abnormal liver function tests or thrombocytopenia. Other features of congenital CMV infection were not noted in this patient. Also, there was no sign of infection in the mother prenatally. Perinatal CMV infections are asymptomatic in about 90% of affected infants (7). If the infection is symptomatic, clinical manifestations will frequently include sepsis-like deterioration. Our patient presented with a GI stricture, and she was symptomatic as early as the seventh day of life. However, the infant repeatedly exhibited sepsis-like symptoms. Additionally, colonic imaging by means of rectal barium enema did not demonstrate any unused colon. This favors that the jejunal stricture occured afterwards. The infant received five packed red cell transfusions, and all of blood products were leukocyte depleted. Tranfusion-related CMV transmission was less probable, but was not excluded. We did not test the breast milk for CMV in our case, but it is another possible route of transmission of infection.

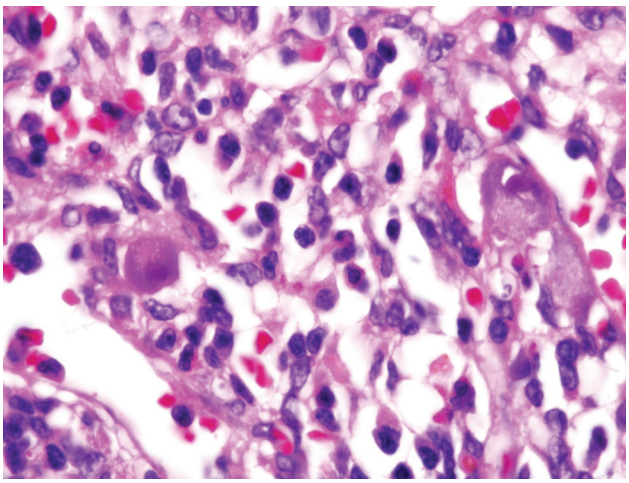

Figure 3. Nuclear CMV inclusions surrounded by a clear halo. Hematoxylin&Eosin, original magnification x1000, oil immersion.

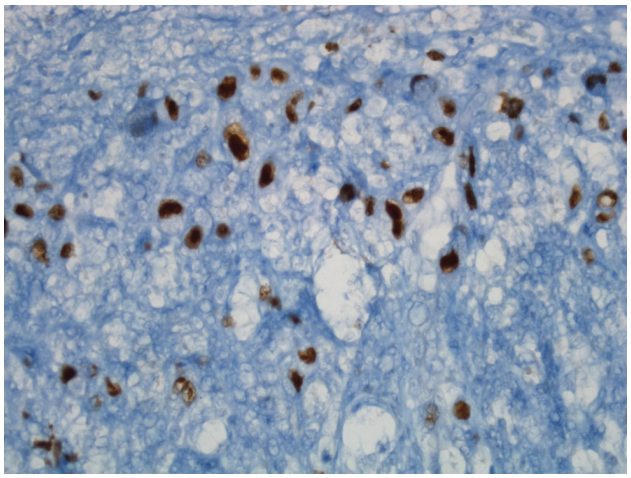

Figure 4. Immunohistochemical detection of CMV viral inclusions. Peroxidase with DAB chromogen, original magnification x400.

Frequently, terminal ileal and colonic portions of the GIS maybe involved with CMV, but two patients similar to this case have presented with ileal strictures and ulceration (1, 4). Bonnard et al. reviewed five cases, one of them, whose mother had CMV IgM detected in serum, had ileal atresia. Srinivasjois et al. presented a case of post-natally acquired CMV-related enteritis, and symptoms started in the fourth week of life as diarrhea, feed intolerance, abdominal distension and sepsis-like deterioration resulting in an ileal stricture.

Our patient's presentation correlates with the existing literature, as CMV infection can cause bowel strictures or atresia in addition to bowel obstruction or NEC-like symptoms. The mechanism of bowel stricture is not established. However, it is maintained that destruction of the myenteric plexus by CMV may result in bowel strictures (1). An alternate proposal is that intra-uterine vasculitis of the developing midgut may lead to intestinal atresia (1). Whether CMV is causing this bowel pathology or it is a superinfection in the inflammatory areas of the bowel is not clearly defined.

Diagnosis of CMV infection at the neonatal period is based on polymerase chain reaction (PCR) and cultures of urine, blood and the respiratory tract.

Additionally, stool PCR can also be used to verify intestinal CMV involvement (8). But the gold standar to prove the presence of intestinal disease is pathologic tissue examination demonstrating CMV inclusion bodies (9). CMV infection should be kept in mind in the differential diagnosis of a premature infant with unusual GI manifestations. Srinivasjois et al. suggest testing the stool and/or rectal swab for localised CMV GI involvement, as other tests will not provide diagnostic results (4). Positive CMV serology or cultures from the urine are also not sufficient to account for the presence of CMV in GI involvement (1). Finally, since it is not always possible to distinguish intestinal CMV involvement from NEC, all surgical specimens should be screened for CMV.

REFERENCES

1. Bonnard A, Le Huidoux P, Carricaburu E, et al. Cytomegalovirus infection as a possible underlying factor in neonatal surgical conditions. J Pediatr Surg 2006;41:1826-9.
2. Baley JE, Toltzis P. Perinatal viral infections. In: Martin RJ, Fanaroff AA, Walsch MC, editors. Fanaroff and Martin's Neonatal-Perinatal Medicine. 8th edition. Philadelphia. Mosby Elsevier, 2006; 843-7.
3. Huang YC, Lin TY, Huang CS, Hseun C. Ileal perforation caused by congenital or perinatal cytomegalovirus infection. J Pediatr 1996;129:931-4.
4. Srinivasjois RM, Kava MP, Thomas A, Rao SC. Cytomegalovirus-associated ileal stricture in a preterm neonate. J Paediatr Child Health 2008;44:80-2.
5. Ekema G, Pedersini P, Milianti S, et al. Colonic stricture mimicking Hirschsprung's disease: a localized cytomegalovirus infection. J Pediatr Surg 2006;41:850-2.
6. Shetty A, Barnes R, Lazda E, et al. Cytomegalovirus: a cause of colonic stricture in a premature infant. J Infect 2007;54:e37-9.
7. Trincado DE, Rawlinson WD. Congenital and perinatal infections with cytomegalovirus. J Paediatr Child Health. 2001;37:187-92.
8. Michel D, Marre E, Hampl W, et al. Intestinal cytomegalovirus disease in immunocompromised patients may be ruled out by search for cytomegalovirus DNA in stool samples. J Clin Microbiol 1995;33:3064-7.
9. Goodgame RW. Gastrointestinal cytomegalovirus disease. Ann Intern Med 1993;119:924-35.