Turk J Gastroenterol 2007; 18 (3): 198-200

# A patient with primary biliary cirrhosis accompanied by Graves disease and Hurthle cell adenoma

## Graves Hastalığı ve Hurthle hücreli adenomlu hastada Primer Biliyer Siroz birlikteliği

Demet G. YAŞAR[1], Seren ÖZENİRLER[2], Mehmet DOĞAN[3]

*Departments of [1]Internal Medicine, [2]Gastroenterology, and [3]Pathology, Gazi University, Faculty of Medicine, Ankara*

*A case of Hurthle cell adenoma and Graves disease associated with primary biliary cirrhosis is reported in a 51-year-old woman, who developed elevated liver enzymes and hyperthyroidism. Thyroid disorders accompanying primary biliary cirrhosis, especially hypothyroidism, are well documented. Concomitance of primary biliary cirrhosis and hyperthyroidism is rare. Moreover, there has been no previous report of a case with Hurthle cell adenoma accompanied by Graves disease and primary biliary cirrhosis.*

**Key words:** Graves disease, Hurthle cell adenoma, primary biliary disease, autoimmunity

*51 yaşında bayan hasta hipertiroidizm ve karaciğer enzim yüksekliği nedeni ile araştırılarak Hurthle hücreli adenom, Graves' hastalığı ve primer biliyer siroz tanıları aldı. Primer biliyer siroz ile birlikte tiroid hastalıkları özellikle de hipotiroidizm sık görülmektedir. Fakat primer biliyer siroz ve hipertiroidizm birlikteliği nadirdir. Bu olgu; daha önce Hurthle hücreli adenom, Graves' hastalığı ve primer biliyer siroz birlikteliği gösterilmediğinden ilginçtir.*

**Anahtar kelimeler:** Graves hastalığı, primer biliyer siroz, otoimmünite, Hurthle hücreli adenoma

## INTRODUCTION

Primary biliary cirrhosis (PBC) is most commonly seen in middle-aged women. It is a chronic cholestatic liver disease with destruction of intrahepatic bile ducts, followed by progressive fibrosis and ultimately cirrhosis. The etiology of PBC is presently unknown, but an autoimmune origin is suggested (1). There is evidence that PBC has an autoimmune nature. It is reported to be accompanied by a variety of disorders like autoimmune thyroiditis, rheumatoid arthritis, Sjögren's syndrome and Raynaud's phenomenon (2). Although concomitance of PBC and hyperthyroidism is quite rare, in this case report we describe a patient with PBC and hyperthyroidism, due to Graves disease (GD). Only six patients with PBC and hyperthyroidism have been reported in the literature: four with GD, one with hashitoxicosis and one with painless thyroiditis (3-6). Hurthle cell adenoma accompanied by GD in a PBC patient has not yet been reported.

## CASE REPORT

A 51-year-old woman was admitted to our hospital due to liver dysfunction in October 2004. Six months earlier, she was found to have an elevated level of γ-glutamyl transpeptidase (γ-GTP) at 352 U/L, alkaline phosphatase (ALP) at 257 U/L, aspartate aminotransferase (AST) at 41 U/L and alanine aminotransferase (ALT) at 62 U/L, while waiting for ophthalmologic decompression. She was not alcoholic, and had no history of blood transfusions or drug allergies. However, in 1999 she was diagnosed as GD because of weight loss (10 kg in 5 months), sweating, tremors, pruritus, large goiter and exophthalmia. Her free thyroxine index was 10.7 ng/dl (0.7-1.9) and thyroid stimulating hormone (TSH) was 0.043 uIU/ml (0.3-5); as a result, propylthiouracil and propranolol therapy was administered. Since her symptoms decreased, she did not have her periodic examination until her goiter became enlarged and she developed shortness of breath. She underwent thyroidectomy

**Address for correspondence:** Seren ÖZENİRLER
Department of Gastroenterology, Gazi University, Faculty of Medicine, Ankara, Turkey
Phone: +90 312 202 58 19 • Fax: +90 312 212 46 47
E-mail: serenozenir@yahoo.com

**Manuscript received:** 14.03.2007 **Accepted:** 14.06.2007

in 2002. Pathologic study results revealed diffuse hyperplasia and Hurthle cell adenoma of the thyroid gland (Figure 1). At physical examination her blood pressure was 130/80 mmHg and pulse was 80 beats/min. Exophthalmia and nontender liver palpable 1 cm under the right costal margin were noted. Heart and lung examinations were unremarkable. Laboratory analysis including complete blood count and serum chemistry showed no abnormality except AST level at 48 U/L (0-40), ALT level at 70 U/L (0-40), ALP level at 307 U/L (0-250) and γ-GTP level at 352 U/L. Antimitochondrial antibodies of M2 type (AMA M2) were positive at a titer of 1/320. Serum immunoglobulin M (IgM) level of 290 mg/dl (60-263) was found; IgA and IgG levels were in normal limits. Hepatitis C virus, hepatitis B surface antigen, antinuclear antibody, and antismooth muscle antibody were normal. Serum total zinc level and copper level were negative. Abdominal ultrasonography and computed tomography examinations did not reveal any evidence of biliary dilatation or any other disease. Pathological study of the biopsy material from the liver showed destruction of several bile ducts. There were lymphocyte infiltrations both surrounding these ducts and in the enlarged portal area (stage I-II) (Figure 2, 3). The patient was diagnosed as PBC due to the clinical criteria and pathological findings and treatment with ursodeoxycholic acid 15 mg/kg/day was initiated. Three months later her serum levels of ALP and GGT had decreased to 143 U/L and 136 U/L, respectively.

## DISCUSSION

It is possible for more than one autoimmune disease to appear in a patient. PBC with hyperthyroidism was reported in only six patients: four with GD, one with hashitoxicosis and one with painless thyroiditis. Our patient had PBC with GD and Hurthle cell adenoma.

Graves disease is currently accepted as an autoimmune disease of an unknown etiology (7). Hurthle cells can be found in non-malignant thyroidal diseases such as GD, Hashimoto disease and toxic multinodular goiter (8). In contrast, Hurthle cells make up more than 75% of the cell population in Hurthle neoplasms, which are usually encapsulated and form single nodules (9). One of the treatment choices for adenoma and GD is thyroidectomy, as in our patient. PBC is diagnosed by infiltration of small bile ducts by lymphocytes, presence of AMA M2 and increased IgM levels. AMAs of

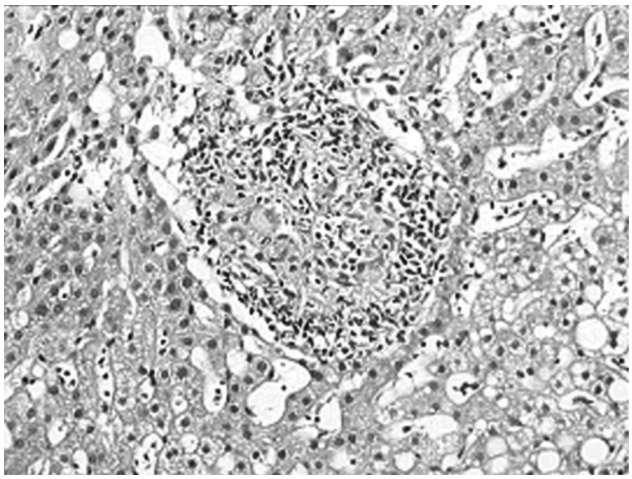

**Figure 1**. Encapsulated nodular lesion composed of Hürthle cells (hematoxylin-eosin stain, x 12.5)

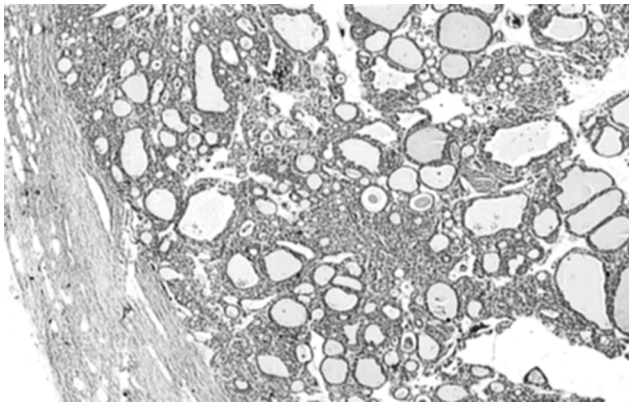

**Figure 2**. Portal inflammation with peripheral cholangal proliferation (serpentine-like pattern) (hematoxylin-eosin stain, x 100). Inset: Lymphocyte permeation to bile duct epithelium (hematoxylin-eosin stained, x 200)

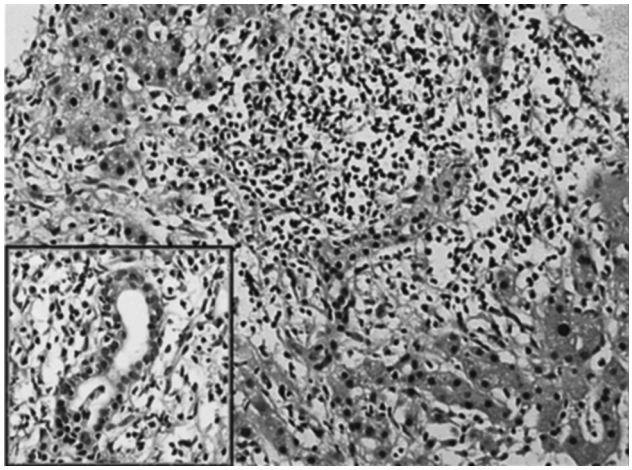

**Figure 3**. Non-necrotizing granuloma formation (hematoxylin-eosin stain, x 100)

M2 type are strongly associated with PBC, occurring in more than 95% of the patients (1). Signs and laboratory data in our patient fulfilled all diagnostic criteria for PBC; furthermore, there were evidences implying that PBC in this patient was autoimmune in origin: (a) disease-specific autoantibodies and T cells, (b) infiltrating lymphocytes into the bile ducts, and (c) association with other autoimmune diseases (1).

Although hyperthyroidism rarely accompanies PBC, its presence is well documented in our patient. In case of an autoimmune thyroid disease, either hypothyroidism or hyperthyroidism, the presence of PBC should be considered in patients with elevated liver enzymes or pruritus.

## REFERENCES

1. Bjorkland A, Totterman TH. Is primary biliary cirrhosis an autoimmune disease? Scand J Gastroenterol Suppl 1994; 204: 32-9.
2. Mackay IR, Whittingham S, Fida S, et al. The peculiar autoimmunity of primary biliary cirrhosis. Immunol Rev 2000; 174: 226-37.
3. Sato N, Ohira H, Orikasa H, et al. Primary biliary cirrhosis associated with painless thyroiditis. Intern Med 1999; 38: 244-8.
4. Mayaudon H, Algayres JP, Crozes P, et al. Basedow disease during primary biliary liver cirrhosis. Presse Med 1994; 23: 629.
5. Nieri S, Riccardo GG, Salvadori G, Surrenti C. Primary biliary cirrhosis and Graves' disease. J Clin Gastroenterol 1985; 7: 434-7.
6. Sasaki H, Matake H, Eimoto T, et al. Asymptomatic primary biliary cirrhosis (A-PBC) associated with so-called "Hashitoxicosis". Nippon Naika Gakkai Zasshi 1987; 76: 746-7.
7. Greenspan FS. The thyroid gland. In: Greenspan FS, Gardner DG, eds. Basic and clinical endocrinology, 7th ed. US: Lange Medical Books/McGraw-Hill, 2004; 260-73.
8. Caplan RH, Abellera RM, Kisken WA. Hurthle cell neoplasms of the thyroid gland: reassessment of functional capacity. Thyroid 1994; 4: 243-8.
9. Nishiyama RH. Overview of surgical pathology of the thyroid gland. World J Surg 2000; 24: 898-906.