was thought. Later the patient was intubated and cardiac arrest developed. The patient could not respond to the cardiopulmonary resuscitation.

The reasons underlying acute colonic pseudo-obstruction are either surgical or medical, which might be associated with intra-, retro-, extraperitoneal surgery, trauma, sepsis, malignancy, systemic diseases, fluid-electrolyte imbalances. The pathogenesis generally cannot be clarified. The most common mechanism is the sympathetic-parasympathetic neurostimulatory imbalance (3). The myxedematous respiratory failure is rarely seen in elders. A series consisting of seventeen patients was presented by Guo et al. (4). Alopecia, hyperhidrosis, xanthomas and palmoplantar keratoderma may be seen in thyroid diseases (1). Palmoplantar keratoderma co-occurring with myxedema has been reported in the literature (1, 5); however, the pathogenesis cannot be clearly identified. Keratin-1 and keratin-2 mutations are suspected. Hypothyroidism with myxedematous respiratory failure in elders is vitally important in terms of prognosis (6).

As a consequence, Ogilvie's syndrome may present with many varying clinical situations. Coexisting with acute colonic pseudo-obstruction and myxedema coma, palmoplantar keratoderma should also be kept in mind.

REFERENCES

1. Niepomniszcze H, Amand RH. Skin disorders and thyroid diseases. J Endocrinol Invest 2001; 24: 628-38.
2. Jordan RM. Myxedema coma: pathophysiology, therapy and factors affecting prognosis. Med Clin North Am 1995; 79:185.
3. Delgado-Aros C, Camilleri M. Pseudo- obstruction in the critically ill. Best Prac Res Clin Gastroenterol 2003; 17: 427-44.
4. Guo F, Xu T, Wang H. Early recognition of myxedematous respiratory failure in the elderly. Am J Emerg Med 2009; 27:212-5.
5. Mittal RR, Jha A. Palmoplantar keratoderma in myxedema. Indian J Dermatol Venereol Leprol 2002; 68: 242.
6. Weetman AP. Hypothyroidism. Fauci AS, Braunwald E, Kasper DL, Hauser SL, Longo DL, Jameson JL, Loscalzo J, ed. Harrisons Principles of Internal Medicine 17 th ed. United States of America: McGraw-Hill, 2008; 2229-33.

Gökhan SARGIN[1], İrfan YAVAŞOĞLU[2], Gürhan KADIKÖYLÜ[2], Zahit BOLAMAN[2]

Departments of [1]Internal Medicine and [2]Division of Hematology, Adnan Menderes University, School of Medicine, Aydın

Solitary rectal ulcer syndrome presenting as polypoid mass lesions in a female patient

Bir kadın hastada polipoid kitle lezyonları şeklinde görülen soliter rektal ülser sendromu

To the editor,

Solitary rectal ulcer syndrome (SRUS) is a rare benign disease of the rectum, which predominately affects young adults aged between 30 and 50 years with a prevalence of 1 in 100.000 people per year (1). SRUS usually presents with a symptom complex of rectal bleeding, passage of mucus and straining on defecation, tenesmus, perineal and abdominal pain, sensation of incomplete defecation, constipation and rectal prolapse (2). The underlying etiology of SRUS is not fully understood, but it is likely to be secondary to ischemic changes in the rectum associated with paradoxical contraction of the pelvic floor and external anal sphincter muscles and with rectal prolapse (3). The macros-

Address for correspondence: Ümit Bilge DOĞAN
Adana Numune Training and Research Hospital,
Department of Gastroenterology,
Adana, Turkey
E-mail: ubdogan@hotmail.com

Manuscript received: 26.03.2012 **Accepted:** 12.04.2012

doi: 10.4318/tjg.2013.0524

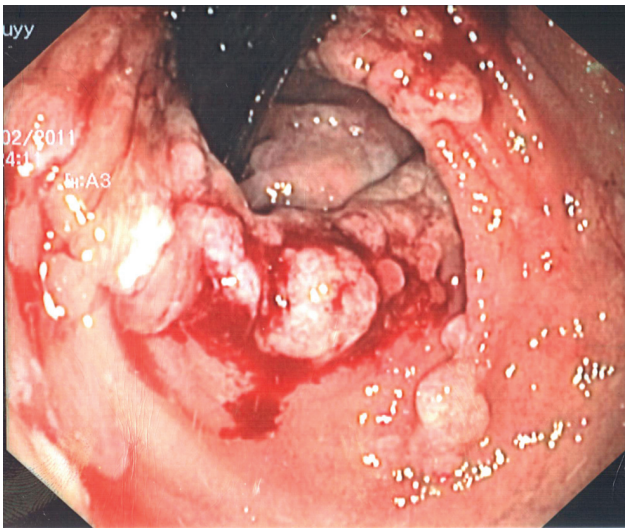

Figure 1. Endoscopic picture of the rectum showing multiple polypoid mass lesions with surface ulceration.

copic appearance of the rectal lesion may vary from hyperemia to ulceration or a polypoid lesion that can mimic carcinoma (4), although the histological findings are characteristic, with fibromuscular obliteration of the lamina propria and disorientation of muscle fibers (5). We report the case of a woman who presented with a polypoid mass lesion of the rectum representing a SRUS variant.

A 20-year-old female patient was referred to our gastroenterology clinic with a 2-year history of recurrent rectal bleeding. Digital rectal examination revealed an irregular broad based polypoid lesion palpated on the rectum about 8 cm from the anal verge. The laboratory findings were normal. Colonoscopy revealed multiple polypoid mass lesions in the rectum located at 5-10 cm from the anal verge with circumferential distribution. The mucosal surface of these lesions was ulcerated and covered with exudates. The surrounding mucosa was smooth with absence of the normal vascular pattern (Figure 1). The remaining colon up to the cecum was normal. Several mucosal biopsies were obtained from the lesions. Histopathological examination revealed focal ulcerations of the lining mucosa with granulation tissue formation. There was smooth muscle fiber expansion between glands up to the submucosa which was perpendicular to the glands (Figure 2A-C). The crypt architecture was maintained, with no findings of granuloma, atypia, or malignancy.

In adults, 25-32% of SRUS may appear as polypoid lesions (6). The SRUS-polypoid variant may lead to serious misdiagnosis as its appearance may be confused with an inflammatory polyp, hyperplastic polyps, or rectal carcinoma (6,7). Our pati-

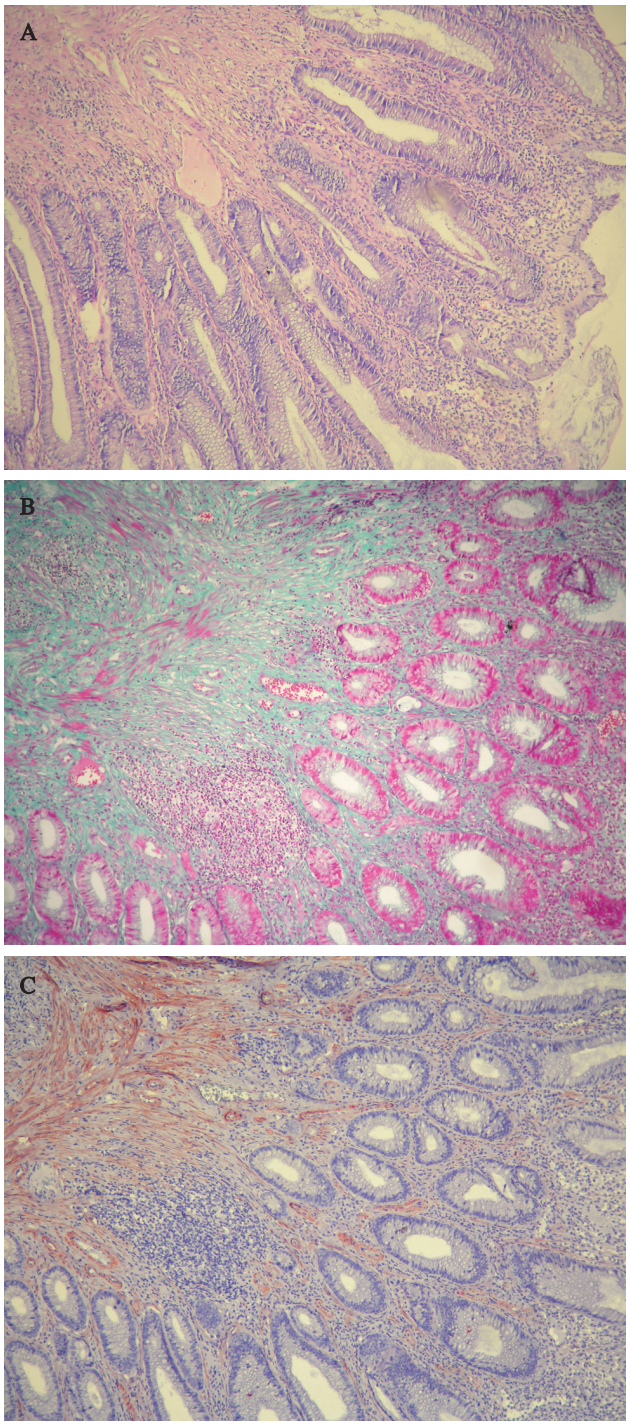

Figure 2. Histopathological examination. **(A)** Surface serration with fibromuscular obliteration and crypts' distortion (HE stain x 200); **(B)** Smooth muscle proliferation in the muscularis mucosa and extending in between the mucosal glands (Masson's trichrome stain x 200); **(C)** Immunohistochemical stains for SMA confirming fibromuscular obliteration of the lamina propria (200 x).

ent had multiple polypoid lesions that were circumferential with an ulcerated surface that mimicked rectal cancer in its appearance.

In conclusion, the presence of a rectal polypoid mass with ulceration in a young adult with rectal bleeding should raise the suspicion of SRUS.

REFERENCES

1. Madigan MR, Morson BC. Solitary ulcer of the rectum. Gut 1969; 10:871-81.
2. Keshtgar AS. Solitary rectal ulcer syndrome in children. Eur J Gastroenterol Hepatol 2008; 20:89-92.
3. Mackle EJ, Parks TG. The pathogenesis and pathophysiology of rectal prolapse and solitary rectal ulcer syndrome. Clin Gastroenterol 1986; 15:985-1002.
4. Wong WM, Lai KC, Shek TW, Lam SK. Self-inflicted rectal ulcer with exuberant granulation tissue: a lesion that mimics carcinoma. Gastrointest Endosc 2002; 55:951-2.
5. Malik AK, Bhaskar KV, Kochhar R, et al. Solitary ulcer syndrome of the rectum-a histopathologic characterisation of 33 biopsies. Indian J Pathol Microbiol 1990; 33:216-20.
6. Chong VH, Jalihal A. Solitary rectal ulcer syndrome: characteristics, outcomes and predictive profiles for persistent bleeding per rectum. Singapore Med J 2006; 47:1063-8.
7. Sztarkier I, Benharroch D, Walfisch S, Delgado J. Colitis cystica profunda and solitary rectal ulcer syndrome-polypoid variant: Two confusing clinical conditions. Eur J Intern Med 2006; 17:578-9.

Ümit Bilge DOĞAN[1], Pelin DEMİRTÜRK[2], Salih AKIN[1], Agah Bahadır ÖZTÜRK[1], Serkan YALAKİ[1]

Departments of [1]Gastroenterology and [2]Pathology, Adana Numune Training and Research Hospital, Adana

Spontaneous enterocutaneous fistula: Unusual presentation of colon cancer

Spontan enterokütanöz fistül: Kolon kanserinin nadir görülen bir prezentasyonu

To the Editor

A 66-year-old male patient was admitted to our service with a spontaneous enterocutaneous fistula (ECF) of colon cancer. He had a history of a painful swelling over the left lower quadrant (LLQ) about three months prior to admission. The swelling opened spontaneously two months later discharging intestinal content (Figure-1A). He had also suffered from malaise, weight loss, and rectal bleeding in the last six months. In his detailed history, he stated that he had on/off bleeding hemorrhoids in the past. Because he related recent rectal bleeding to hemorrhoids, he did not seek medical attention earlier. On examination, he was cachectic and had a skin ulcer of about 7x5 cm over the LLQ with intestinal discharge. He presented with an abdominal computed tomography showing a mass in the sigmoid colon communicating with the skin (Figure-1B). Colonoscopy revealed a obstructing mass in the sigmoid colon. Biopsy showed a tubulovillous adenoma with severe dysplasia with adjacent invasive malignancy. The patient underwent en bloc left hemicolectomy with resection of abdominal wall including the fistula and end colostomy with Hartmann procedure (Figure-1C). An abdominoplasty was required to repair anterior abdominal wall defect (Figure-1D-F). Cutaneous involvement was confirmed histopathologically (Figure-1E). The patient had an uneventful recovery.

Address for correspondence: Yusuf GÜNAY
Başkent University İstanbul Hospital,
Department of General Surgery, İstanbul, Turkey
Phone: + 90 216 554 15 00/2060 • Fax: + 90 216 651 98 58
E-mail: drygunay@yahoo.com

Manuscript received: 29.02.2012 **Accepted:** 03.04.2012

doi: 10.4318/tjg.2013.0519