TJG
The Turkish Journal of Gastroenterology

Successful endoscopic extraction of dental prosthesis trapped in the pharynx

Farinkste takılmış olan dental protezin başarılı bir şekilde çıkarılması

To the editor,

We read with great interest the article by Tihan et al. reporting the esophageal perforation due to inadvertent swallowing of a dental prosthesis (1).

Foreign body ingestion and food bolus impaction are well-recognized and relatively common problems in the emergency department, causing serious morbidity in less than 1% of all patients; 1500 deaths per year are attributed to the ingestion of foreign bodies in the United States (2,3). The type of foreign bodies varies greatly: mainly food boluses, coins, fish bones, dental prostheses, or chicken bones (4). Dental prostheses have a frequency of 8,6-14,3% among ingested foreign bodies (4, 5).

A 83-year-old man was admitted to the emergency unit because of ingesting his dental prosthesis during sleep. He had woke up with discomfort in his throat and realized that he ingested his prosthesis. Chest X-ray was taken immediately in the emergency room, and the ingested prosthesis was seen in the cervical region (Figure 1). Upper gastrointestinal endoscopy was performed, and the prosthesis was seen to be trapped in the pharynx (Figure 2). A trial to extract the prosthesis with polypectomy snare was attempted. Due to the risk of perforation, we did not force it much but managed to pull out the prosthesis without any complication, except little bleeding which stopped spontaneously. Among the ingested foreign bodies, dental prostheses pose more difficulty to the endoscopist. In a large series from China, endoscopic failure was noted mostly in cases with dental prosthesis ingestion (44%) (3). Another major problem during endoscopic extraction of prosthesis is the risk of complications such as laceration and perforation (3). In our case, the prosthesis could be easily and safely removed. But the case presented by Tihani et al. seems to be a difficult one, and perforation occurred as one of the hooks had been lodged in the esophageal wall. Their case shows that if the prosthesis is lodged in the esophageal wall, there is a high probability of perfora-

Figure 1. Direct plain radiogram showing dental prosthesis in the cervical region

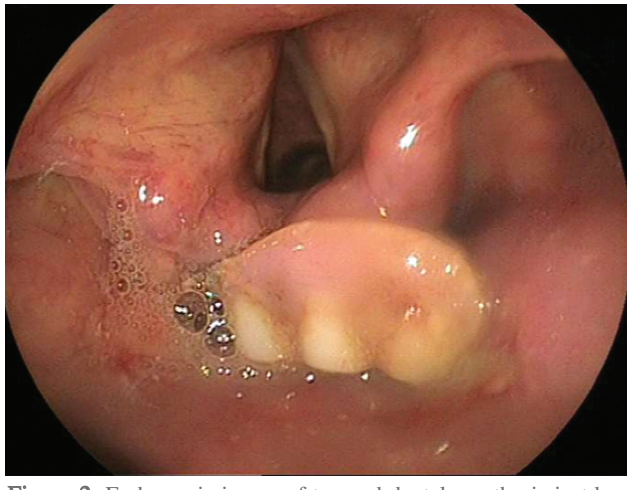

Figure 2. Endoscopic image of trapped dental prosthesis just beneath vocal cords

Address for correspondence: Ali Erkan DUMAN
Kocaeli University Faculty of Medicine, Department of Gastroenterology, İzmit, Turkey
E-mail: dralierkanduman@hotmail.com

Manuscript received: 26.12.2011 **Accepted:** 02.02.2012

Turk J Gastroenterol 2013; 24 (4): 367-376
doi: 10.4318/tjg.2013.0473

tion. Therefore, endoscopic procedure should be performed with the attendance of an anesthesiologist as urgent tracheal intubation may be necessary. Also, the surgical team should be alerted, and operation room should be ready. Taking into account the high probability of perforation, endoscopic retrieval may not be a good therapeutic option in such a case, and surgery may be the initial choice. Elective surgery will lead to less morbidities and shorten the duration of hospitalization.

REFERENCES

1. Tihan D, Trabulus D, Altunkaya A, et al. Esophageal perforation due to inadvertent swallowing of a dental prosthesis. Turk J Gastroenterol 2011; 22:529-33.
2. Lyons MF II, Tsuchida AM. Foreign bodies of the gastrointestinal tract. Med Clin North Am. 1993; 77:1101-14.
3. Uyemura MC. Foreign body ingestion in Children. Am Fam Physician 2005; 72:287-91.
4. Li ZS, Sun ZX, Zou DW, et al. Endoscopic management of foreign bodies in the upper-GI tract: experience with 1088 cases in China. Gastrointest Endosc 2006; 64:485-92.
5. Katsinelos P, Kountaras J, Paroutoglou G, et al. Endoscopic techniques and management of foreign body ingestion and food bolus impaction in the upper gastrointestinal tract: a retrospective analysis of 139 cases. J Clin Gastroenterol 2006; 40:784-89.

Ali Erkan DUMAN, Uğur KORKMAZ, Mürsel SALİ, Altay ÇELEBİ, Ömer ŞENTÜRK, Sadettin HÜLAGÜ

Department of [1]Gastroenterology, Kocaeli University School of Medicine, İzmit

An unusual cause of granulomatous gastritis in an elderly patient: *Helicobacter pylori*

Yaşlı hastada granülamatöz gastritin nadir nedeni: Helikobakter pilori

To the editor

Granulomatous gastritis is a rare disease (1). The cause of granulomatous gastritis is determined with exclusion of granulomatous diseases. *Helicobacter pylori (Hp)* may unusually be associated with granulomatous gastritis (2,3). Our case was an elderly patient with granulomatous gastritis that recovered entirely after *Hp* eradication therapy.

A 68-year-old man presented to the department of gastroenterology with a 4-week history of epigastric pain. He did not have fever, respiratory symptoms, or diarrhea. He had no history of inflammatory bowel disease, peptic ulcer disease, sarcoidosis, or abdominal surgery. His physical examination was normal. His complete blood count, erythrocyte sedimentation rate, blood chemistry, chest radiograph, and abdominal ultrasound were normal. Serum angiotensin-converting enzyme levels were normal. Upper gastrointestinal endoscopy showed erythema of the antral mucosa. Two gastric biopsy specimens from the antrum demonstrated chronic inflammation and non-caseating granulomas composed of epithelioid histiocytes, mononuclear cells, and multinucleated giant cells (Figure-1). *Hp* was detected by histologic examination of specimens from antrum. Terminal ileum and colon were normal endoscopically. Biopsies of ileal mucosa were normal. We determined granulomatous gastritis association with *Hp* infection. The patient was given pantoprazole 80 mg/day, amoxi-

Address for correspondence: Adnan TAŞ
Osmaniye Public Hospital, Department of Gastroenterology, Osmaniye, Turkey
Phone: + 90 312 595 42 72
E-mail: dradnantas@gmail.com

Manuscript received: 01.02.2012 **Accepted:** 11.06.2012

doi: 10.4318/tjg.2013.0549

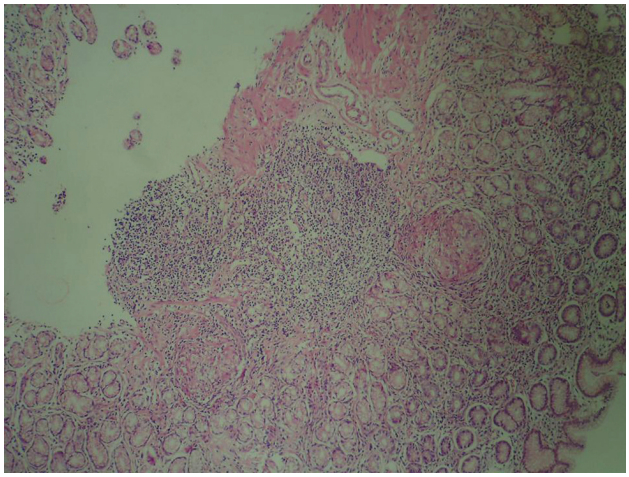

Figure 1. Non-caseating granuloma including histiocytes, mononuclear cells, and multinucleated giant cell (hematoxylin&eosin, x100).

cillin 2000 mg/day, and levofloxacin 500 mg/day for 2 weeks for treatment of *Hp* infection. The effect of the *Hp* eradication therapy was evaluated at the antral mucosa by endoscopy 3 months later and endoscopy was normal. Biopsy specimens from the antrum demonstrated chronic inflammation without any granulomas, and the tests for *Hp* were negative.

Granulomatous gastritis has been reported in 0.27% of gastric biopsy cases. According to the etiologic classification of granulomatous gastritis, the following rates have been estimated: Crohn disease (52%), isolated granulomatous gastritis (25%), foreign bodies (10%), underlying malignancy (7%), sarcoidosis (1%), Whipple disease (1%) and unclassified (3%) (4). *Hp* infection of the gastric mucosa is frequently associated with nonspecific gastritis (5). Dhillon and Sawyerr first reported an association between granulomatous gastritis and *Hp* in 1989 (6). In our case, we showed the resolution of symptoms, endoscopic findings, and granulomatous gastritis after successful *Hp* eradication therapy. The granulomas had disappeared 3 months after *Hp* eradication in our patient.

In conclusion, we have showed the probable association between granulomatous gastritis and *Hp* infection. *Hp* infection should be considered in the differential diagnosis of granulomatous gastritis. We recommend *Hp* eradication for patients with granulomatous gastritis and *Hp* infection.

REFERENCES

1. Maeng L, Lee A, Choi K, et al. Granulomatous gastritis: a clinicopathologic analysis of 18 biopsy cases. Am J Surg Pathol 2004; 28:941-5.
2. Özturk Y, Büyükgebiz B, Özer E, et al. Resolution of Helicobacter pylori associated granulomatous gastritis in a child after eradication therapy. J Pediatr Gastroenterol Nutr 2004; 39:286-7.
3. Miyamoto M, Haruma K, Yoshihara M, et al. Isolated granulomatous gastritis successfully treated by Helicobacter pylori eradication: a possible association between granulomatous gastritis and Helicobacter pylori. J Gastroenterol 2003; 38:371-5.
4. Ectors NL, Dixon MF, Geboes KJ, et al. Granulomatous gastritis: a morphological and diagnostic approach. Histopathology 1993; 23:55-61.
5. Cohen MC, Cueto RuaE, Balcarce N, et al. Assessment of the Sydney System in Helicobacter pylori-associated gastritis in children. Acta Gastroenterol Latinoam 2000; 30:35-40.
6. Dhillon AP, Sawyerr A. Granulomatous gastritis associated with Campylobacter pylori. APMIS 1989; 97:723-7.

Adnan TAŞ[1], Gülzade KARAMAN[2], Hacer ÇELİK[3]

Departments of [1]Gastroenterology, [2]Pathology and [3]Chest Diseases, Osmaniye Public Hospital, Osmaniye