Inborn errors of metabolism in the differential diagnosis of fatty liver disease

Yılmaz Yıldız[1], Hatice Serap Sivri[2]

[1]Pediatric Metabolic Diseases Unit, Dr. Sami Ulus Training and Research Hospital for Maternity and Children's Health and Diseases, Ankara, Turkey
[2]Division of Metabolic Diseases, Department of Pediatrics, Hacettepe University School of Medicine, Ankara, Turkey

Cite this article as: *Yıldız Y, Sivri HS. Inborn errors of metabolism in the differential diagnosis of fatty liver disease. Turk J Gastroenterol 2020; 31(1): 3-16.*

ABSTRACT

Nonalcoholic fatty liver disease (NAFLD) has become the most common chronic liver disease across all age groups. Obesity, diabetes, and metabolic syndrome, are the primary causes that are closely linked with the development of NAFLD. However, in young children, rare inborn errors of metabolism are predominant secondary causes of NAFLD. Furthermore, inborn errors of metabolism causing hepatosteatosis are often misdiagnosed as NAFLD in adolescents and adults. Many inborn errors of metabolism are treatable disorders and therefore require special consideration. This review aims to summarize the basic characteristics and diagnostic clues of inborn errors of metabolism associated with fatty liver disease. A suggested clinical and laboratory diagnostic approach is also discussed.
Keywords: *Inborn errors of metabolism, liver steatosis, metabolic diseases, nonalcoholic fatty liver disease, steatohepatitis*

INTRODUCTION

Nonalcoholic fatty liver disease (NAFLD) is considered the most common chronic liver disease in children and adults (1,2). Nearly 20%-30% of all adults are estimated to have NAFLD (3). Based on autopsies from accidental deaths, the prevalence of NAFLD has been reported to be as high as 9.6% in lean and 38% in obese children (4). The increased occurrence of NAFLD is comparable to those of obesity, diabetes, and metabolic syndrome, which have ultimately intertwined pathogenetic mechanisms (1).

The diagnosis of NAFLD requires radiologic or histologic evidence of hepatosteatosis. Furthermore, secondary causes of fat deposition in the liver, including significant alcohol intake; certain medications; and other liver diseases, such as inborn errors of metabolism (IEMs), must be excluded (5). IEMs are defined as monogenic disorders associated with disruption of the synthesis or breakdown of molecules in specific metabolic pathways. More than 1,000 IEMs are defined to date (6), with a total estimated prevalence of 1 in 2,000 live births (7). Most IEMs are autosomal recessive traits; therefore, a high prevalence may be observed in populations with high rates of consanguineous marriages (8). A few basic properties of IEMs are summarized in Table 1.

Considering the high prevalence of obesity and metabolic syndrome and its dominant impact on the development on NAFLD, the secondary causes of hepatosteatosis, particularly rare diseases, such as IEMs, may be overlooked. The current clinical practice guidelines recommend laboratory investigations to rule out some of the more common IEMs (5). Furthermore, it is established that children require a more comprehensive evaluation than adults (2,5,9,10). Although this approach is reasonable, it should not be disregarded that IEMs are underdiagnosed, particularly in adults. Therefore, an effort should be made to search for and find these undiagnosed patients. To ensure this, metabolic work-up may need to be extended, based on certain suspicious findings in history and physical examination.

In this review, we aim to provide gastroenterologists with an overview of IEMs that can present with or feature fatty liver disease. A summary of these conditions with a focus on diagnostic tools is presented in Table 2. Non-Mendelian genetic predisposition to NAFLD, nonmetabolic hereditary (for example cystic fibrosis) or nonhereditary conditions (for example celiac disease) associated with NAFLD, metabolic hepatopathies that do not cause NAFLD (for example hereditary hemochromatosis), and methods to diagnose the presence and consequences of NAFLD are beyond the scope of this review. In children, since alcohol consumption is not a major contributor to the development of hepatosteatosis, the term "pediatric fatty liver disease" may be preferred instead of NAFLD

Corresponding Author: ***Hatice Serap Sivri; ssivri@hacettepe.edu.tr***
Received: ***May 11, 2019*** *Accepted:* ***June 13, 2019***
© Copyright 2020 by The Turkish Society of Gastroenterology · Available online at turkjgastroenterol.org
DOI: ***10.5152/tjg.2019.19367***

(10). Henceforth, the phrase "fatty liver disease (FLD)" will be used here to refer to the disease in all age groups.

DISORDERS OF ENERGY METABOLISM

Disorders of carbohydrate metabolism

Adenosine triphosphate (ATP) synthesis depends on the oxidation of carbohydrates and fatty acids. Glucose is degraded via the glycolysis pathway to pyruvate, which is converted to acetyl-CoA for the Krebs cycle. Excess glucose is stored as glycogen and converted back to glucose when needed. Fructose and galactose are metabolized to glycolytic pathway intermediates. Disruptions in these pathways cause energy depletion and hepatosteatosis.

Hereditary fructose intolerance (HFI) is an inherited and treatable disorder of fructose metabolism, which should be considered in all patients with FLD, hypertransaminasemia, or hepatomegaly. Infants with HFI are asymptomatic as long as they are fed exclusively with breastmilk or standard formula. However, cultural practices, such as feeding trace amounts of sugar or honey or administration of medical formulations containing sorbitol as a sweetener, may cause symptoms to develop in early infancy. However, the disease onset usually coincides with the introduction of complementary foods, such as fruits, sweets, or sugar. The intake of fructose, sucrose, or sorbitol causes recurrent vomiting, abdominal pain, failure to thrive, hypoglycemia and metabolic acidosis. Over time, patients develop aversion to fruits and sweet foods, thereby spontaneously minimizing their fructose intake. Nevertheless, minimal fructose consumption induces hepatosteatosis, leading to hypertransaminasemia, hepatomegaly and eventually fibrosis, which may be the presenting signs. The detection of fructose accumulation is challenging because fructose intake is extremely low. In case of clinical suspicion, analysis of *ALDOB* gene is the preferred method of diagnosis. Elimination of fructose, sucrose and sorbitol from the diet results in complete recovery (11). Aversion to fruits, table sugar, sweets, and syrup-containing desserts should be specifically questioned in all patients with FLD. The absence of dental caries is also suggestive of the absence of fructose intake because cariogenic bacteria cannot grow without fructose.

Classical galactosemia is another disorder of monosaccharide metabolism, which can cause FLD, but only in symptomatic young infants. Ingestion of galactose from breastmilk or formula causes rapid and diffuse macrovesicular steatosis, cholestasis and eventually acute liver failure and death, unless galactose-free feeding is initiated (12,13). Cataracts, brain edema, tubular dysfunction, hemolysis and gram-negative bacterial sepsis can be associated features. Galactosemia must be suspected in all severely-ill newborns with cholestasis. Empirical treatment should be administered until it is ruled out. The detection of reducing substances or galactose in urine can raise the suspicion of galactosemia. However, this is not reliable, as infants are often too ill to consume enough galactose to allow detection (false-negatives). Galactosuria can occur in portosystemic shunts or in liver dysfunction due to other causes (false-positives). The diagnosis is instead confirmed by measuring galactose-1-phosphate-uridyltransferase (GALT) activity in erythrocytes or by genetic analysis. A normal GALT activity does not rule out galactosemia in patients who recently received erythrocyte transfusions (13).

Glycogen storage diseases (GSDs) are a large group of heterogeneous disorders involving the liver and/or mus-

Table 1. General principles in diagnosis of IEMs.

IEMs are numerous. It is impossible to know them all. Consider treatable and more common IEMs first.
Failure to recognize treatable, rare IEMs may result in complications, including severe morbidity and mortality. Specific treatment is available for many IEMs.
Diagnosis of an IEM in an index patient (proband) may help not only the patient, but also facilitate early diagnosis and intervention for family members. Prenatal or preimplantation diagnosis can prevent recurrence of the disease in an affected family.
Since most IEMs are autosomal recessive traits, family members may be carriers and not affected by the disease. Absence of the disease in family members does not rule out IEMs.
Consider IEMs when signs or symptoms are atypical, progressive, unexplained, unresponsive to standard treatment or inexplicably associated with involvement of other organ systems.
IEMs are not confined to neonates and young children. They can present at any age from the antenatal period to old age.

IEMs: Inborn errors of metabolism

Table 2. Inborn errors of metabolism to consider in fatty liver disease.

Disease	Clinical and laboratory clues	Defective gene(s)
Disorders of Carbohydrate Metabolism		
Hereditary fructose intolerance	Aversion to fruits and sweets, hepatomegaly, HTA, renal Fanconi syndrome, no dental caries	*ALDOB*
Classical galactosemia	Liver failure, cholestasis, hypoglycemia, cataracts, brain edema, and gram negative sepsis	*GALT*
Glycogen storage disease type Ia	Doll-like facies, HM, hypoglycemia, lactic acidosis, hyperuricemia, dyslipidemia, and renal Fanconi syndrome	*G6PC*
Glycogen storage disease type Ib	Features of GSD-Ia + neutropenia, recurrent infections, IBD	*SLC37A4*
Glycogen storage disease type III	HM, hypoglycemia, dyslipidemia, and FTT; in IIIa: progressive myopathy and elevated creatine kinase	*AGL*
Glycogen storage disease type IV	HM, FTT, and early cirrhosis in progressive form	*GBE1*
Glycogen storage disease type VI	HM, sometimes with hypoglycemia, FTT, and dyslipidemia	*PYGL*
Glycogen storage disease type IXa-c	Variable findings: HM, FTT, hypoglycemia, and dyslipidemia	*PHKA2, PHKB, PHKG2*
Glycogen storage disease type XI	Doll-like facies, FTT, HM, fasting hypoglycemia, postprandial hyperglycemia, Fanconi syndrome: RTA, glucosuria, and rickets	*SLC2A2*
Fatty Acid Oxidation Disorders		
Primary carnitine deficiency	Dilated CMP, hypoglycemia, and liver dysfunction	*SLC22A5*
Carnitine palmitoyl transferase I deficiency	Hypoglycemia, HTA, liver dysfunction, and RTA	*CPT1*
Carnitine:acylcarnitine translocase deficiency	CMP, dysrhythmias, and hyperammonemia	*SLC25A20*
Carnitine palmitoyl transferase II deficiency	CMP, hypoglycemia, and liver dysfunction in younger patients and rhabdomyolysis in older patients	*CPT2*
MCAD deficiency	Hypoglycemia, Reye-like syndrome, sudden death	*ACADM*
VLCAD deficiency	CMP, hypoglycemia, hypotonia, and hepatopathy in younger patients and rhabdomyolysis in older patients	*ACADVL*
LCHAD/MTP deficiency	CMP, dysrhythmias, hypotonia, rhabdomyolysis, neuropathy, retinopathy, and maternal HELLP syndrome or AFLP	*HADHA, HADHB*
Multiple acyl-CoA dehydrogenase deficiency	CMP, hypoglycemia, metabolic acidosis, and liver dysfunction in younger and progressive proximal myopathy in older patients	*ETFA, ETFB, ETFDH*
Mitochondrial Diseases		
Hepatocerebral mitochondrial DNA maintenance defects	Early liver failure, cholestasis, and elevated lactate, often with neurological signs (hypotonia, nystagmus, epilepsy etc.)	*POLG, TWNK, DGUOK, SUCLG1, MPV17, IFAM*
Other mitochondrial hepatopathies	Liver dysfunction and elevated lactate, usually with neurological involvement	*LARS, IARS, FARS2, GFM1, BCS1L, SCO1, SERAC1…*
Reversible infantile liver failure	Liver failure spontaneously resolving after infancy	*TRMU*
Lipid Storage Diseases		
Lysosomal acid lipase deficiency	Wolman's disease: HSM, calcified adrenals, and diarrhea; CESD: HTA, microvesicular steatosis, and dyslipidemia	*LIPA*
Chanarin-Dorfman syndrome	Ichthyosis, neurological signs, and lipid vacuoles in peripheral blood smear	*CDS*

Table 2. Inborn errors of metabolism to consider in fatty liver disease. (Continued)

Disease	Clinical and laboratory clues	Defective gene(s)
Niemann-Pick disease type C	(Hepato)splenomegaly, neonatal cholestasis, later-onset neurological signs	*NPC1, NPC2*
Disorders of Lipoprotein Metabolism		
Familial combined hyperlipidemia	Elevated cholesterol and triglycerides	*LPL*
Familial chylomicronemia	Recurrent pancreatitis, HSM, lipemic serum, and severe HTG	*LPL, APOC2, GPIHBP1*
Hypobetalipoproteinemia Abetalipoproteinemia and autosomal recessive hypobetalipoproteinemia	Usually asymptomatic with low serum lipids Malabsorption, malnutrition, ataxia, neurodegeneration, night blindness, and extremely low serum lipids	*APOB, MTTP, PCSK9* *MTTP, APOB, PCSK9*
Disorders of Amino Acid Metabolism		
Hereditary tyrosinemia type 1	Infantile cholestastic liver failure or later-onset HM, HTA, cirrhosis, and HCC with or without Fanconi syndrome	*FAH*
Deficiencies of urea cycle enzymes	Hyperammonemic encephalopathy, neurological symptoms, acute or chronic liver dysfunction, and Reye-like syndrome	*NAGS, CPS1, OTC, ASS1, ASL, ARG1*
Citrin deficiency	Infancy: cholestasis; childhood: FTT, dyslipidemia, and carbohydrate aversion; adulthood: hyperammonemia	*SLC25A13*
Congenital Disorders of Glycosylation		
PMM2-CDG	Typical facies, abnormal fat pads, inverted nipples, and proteinuria	*PMM2*
MPI-CDG	Coagulopathy, thrombophilia, protein-losing enteropathy	*MPI*
PGM1-CDG	HM, HTA, hyperinsulinism, CMP, cleft palate/bifid uvula	*PGM1*
TMEM199-CDG	High ALP, dyslipidemia, high copper, low ceruloplasmin	*TMEM199*
Other CDGs with liver involvement	Variable liver disease with neurologic and multisystem involvement.	*CCDC115, ATP6AP1, ALG3, COG6*
Other Metabolic Liver Diseases		
Wilson disease	Myriad of hepatic and/or neuropsychiatric presentations; hemolysis, renal Fanconi syndrome in some cases	*ATP7B*
Inborn errors of bile acid synthesis	Infants: cholestasis with normal GGT; older patients: neurological symptoms	*HSD3B7, AKRID1, CYP27A1*
α1-antitrypsin deficiency	Varying forms of liver disease in children, rarely chronic disease in adults	*SERPINA1*
NBAS deficiency	Recurrent acute liver crisis or failure in infancy or childhood, triggered by fever	*NBAS*

Please refer to the text for summaries of diagnostic tests and treatment options. All diseases above are autosomal recessive traits except for hypobetalipoproteinemia and familial combined hyperlipidemia, which are autosomal dominant; ATP6AP1-CDG, GSD-IXa, and OTC deficiency are X-linked disorders. AFLP: acute fatty liver of pregnancy, ALP: alkaline phosphatase, CESD: cholesteryl ester storage disease, CMP: cardiomyopathy, FLD: fatty liver disease, FTT: failure to thrive, GGT: γ-glutamyl transferase, GSD: glycogen storage disease, HCC: hepatocellular carcinoma, HELLP: hemolysis - elevated liver enzymes - platelets, HM: hepatomegaly, HSM: hepatosplenomegaly, HTA: hypertransaminasemia, HTG: hypertriglyceridemia, IBD: inflammatory bowel disease, IEMs: Inborn errors of metabolism, LCHAD: long chain 3-hydroxyacyl-CoA dehydrogenase, MCAD: medium chain acyl-CoA dehydrogenase, MTP: mitochondrial trifunctional protein, OTC: ornithine transcarbamylase, RTA: renal tubular acidosis, VLCAD: very long-chain acyl-CoA dehydrogenase.

cle (14). Hepatosteatosis is a common finding demonstrated in different types of hepatic GSDs (15-17). GSD types I, III, VI, and IX usually present in childhood with failure to thrive and significant hepatomegaly, but milder cases can be detected in adulthood and be misdiagnosed as NAFLD or nonalcoholic steatohepatitis (NASH) (14,18). Hypoglycemia is another hallmark of hepatic GSDs and is most profound in GSD-Ia. GSD-Ib additionally features neutropenia and inflammatory bowel disease. In addition to liver disease, 85% of patients with GSD-III also have progressive myopathy. GSD-IV usually manifests as hepatosplenomegaly and cirrhosis in infancy, but nonprogressive milder forms are also reported. GSD-VI and -IX are even more heterogeneous but exhibit marked hepatomegaly as a common feature. GSD-XI (Fanconi-Bickel syndrome) causes generalized renal proximal tubular dysfunction (Fanconi syndrome) and hepatomegaly (14). When hepatic GSD is suspected, identifying glycogen storage and enzyme deficiency in the liver tissue can be a diagnostic tool, but genetic analysis by sequencing of a single candidate gene (if a specific type is suspected) or next-generation sequencing (if GSD is suspected but not specified) is now the method of choice, obviating the need for liver biopsies for diagnosis (19). Dietary interventions are the mainstay of therapy in hepatic GSDs.

Fatty acid oxidation disorders

Fatty acid oxidation disorders (FAODs) arise from the deficiencies of the components of the carnitine cycle or the mitochondrial β-oxidation pathway (20). They comprise a spectrum of phenotypes, which can present from the newborn period to adulthood, all of which may feature FLD, cardiomyopathy, or Reye-like syndrome at any age. Other findings include hypotonia, hyperammonemia, cholestasis, liver failure, and hypoketotic hypoglycemia, particularly in infants and young children. Hypertransaminasemia, hepatosteatosis, and lipid-storage skeletal myopathy with exercise intolerance and rhabdomyolysis are findings that can be encountered in older individuals. One interesting presentation of FAODs is the occurrence of hemolysis, elevated liver enzymes, low platelets (HELLP) syndrome or acute fatty liver of pregnancy in a mother carrying a fetus affected with FAOD (20,21). More detailed diagnostic clues about particular FAODs can be found in Table 2.

The screening test for FAODs is carnitine and acylcarnitine analysis in dried blood spots (DBS). The measurement of free fatty acids in plasma is available only in selected laboratories, but the corresponding dicarboxylic acids are easily detected in urine through organic acid analysis. Samples obtained during an acute decompensation have a higher diagnostic yield than those taken when the patient is well. The results of these tests should be interpreted by a metabolic specialist because the recognition of certain patterns that coincide with the clinical findings are important, rather than normal or abnormal levels of single compounds. Suspected disorders can be confirmed or excluded by enzymatic and/or genetic analysis (21).

Most FAODs are treatable disorders with simple and effective screening tools, mandating clinicians to keep a high index of suspicion. Particularly, acute, severe decompensations that might otherwise be fatal can be successfully managed if recognized early. The cornerstone of emergency treatment is high rates of intravenous glucose infusion (sometimes carefully titrated with insulin) for providing adequate calories and suppressing the metabolic need to degrade fats. In addition, supplementation of riboflavin and coenzyme Q_{10} in the late-onset form of multiple acyl-CoA dehydrogenase deficiency (MADD) and of carnitine in primary carnitine deficiency results in dramatic improvement. However, unless recommended by a metabolic specialist, carnitine should not be empirically administered due to the risk of fatal dysrhythmia in certain types of FAODs. Similarly, medium-chain triglyceride (MCT)-rich formulas, used with success in long-chain fatty acid oxidation defects, can be harmful in other types. Sodium valproate and intravenous lipid emulsions are contraindicated in FAODs (22).

Mitochondrial diseases

The brain and liver are the most commonly affected organs in mitochondrial diseases due to the high demand of energy. Liver involvement affects 10-20% of patients with mitochondrial disease, and is more common in children (23). In addition to neurological and hepatic dysfunction, the signs of mitochondrial disease include multi-system involvement (visual or auditory disturbances, skeletal or cardiac myopathy, renal dysfunction, endocrine disturbances, gastrointestinal dysmotility, etc.) and markedly elevated lactate levels. Significant microvesicular steatosis is a strong indicator of mitochondrial hepatopathy in acute liver failure (10).

Early infantile and severe liver failure is most notable in mitochondrial DNA maintenance defects (MDMDs), which are autosomal recessive traits caused by mutations in genes that encode proteins required for maintaining the quantity and integrity of mitochondrial DNA.

Hepatocerebral MDMDs are often coupled with cholestasis and variable neurological abnormalities, including seizures, hypotonia, psychomotor delay, and abnormal eye movements (24). Some features may be specific to certain defects, such as rotary nystagmus and roving eye movements to *DGUOK*, renal dysfunction to *MPV17*, methylmalonic aciduria to *SUCLG1*, and occipital epilepsy to *POLG* mutations (24,25). Diagnosis may be extremely obscure in patients who have isolated hepatopathy without neurological involvement. Children with *POLG* mutations deserve special consideration because the use of sodium valproate as an antiepileptic drug can trigger or worsen liver disease, and even cause acute liver failure in these patients (24).

Deficiency in aminoacyl-transfer RNA synthetases is another class of mitochondrial hepatopathies in which mitochondrial protein synthesis is impaired. Similar to MDMDs, neurological involvement is often present. Liver disease may become apparent only after the initiation of antiepileptics and liver histology usually reveals micro- and macrovesicular steatosis with fibrosis (26). Disruptions in the assembly of mitochondrial respiratory chain complexes and disorders of pyruvate metabolism can also cause liver disease and sometimes be associated with Reye-like syndrome (23,27).

The diagnosis of mitochondrial diseases is challenging because many genetic defects cause overlapping phenotypes. Blood lactate and alanine elevations and excretion of certain organic acids in urine may be helpful but are not specific. The assessment for multisystem involvement must be thorough, as it could pinpoint to a specific candidate gene. Biopsy of affected organs for analyzing mitochondrial respiratory chain complexes as a first-line diagnostic test is being abandoned in favor of next-generation gene panels or whole exome sequencing, which can detect mutations in genes causing similar phenotypes simultaneously in a single assay (28).

The disease management focuses on the symptomatic treatment of hepatic and other complications. Although various cofactors and nutritional supplements are widely used for the management of mitochondrial diseases, evidence of their effectiveness is limited (24). Liver transplantation is often contraindicated because of neurological involvement. One important exception is reversible infantile liver failure caused by *TRMU* mutations, where patients recover spontaneously after infancy. Since there is no neurological involvement, transplantation is indicated in these patients if liver failure is unresponsive to supportive treatment (23).

LIPID STORAGE DISEASES

Lysosomal acid lipase (LAL) deficiency

LAL deficiency is a treatable storage disease characterized predominantly by hepatosteatosis. The findings of its early-onset form (Wolman's disease) include hepatosplenomegaly, diarrhea, malabsorption, failure to thrive, liver failure, adrenal calcifications, and death in infancy. Patients with the more common late-onset form (cholesteryl ester storage disease [CESD]) may be malnourished and often have hepatomegaly, splenomegaly, dyslipidemia, and hypertransaminasemia and may develop FLD, hepatic fibrosis, liver failure, and early-onset atherosclerosis with cardiovascular disease. However, they can be asymptomatic for decades. Laboratory or sonographic abnormalities can be discovered incidentally (29,30).

CESD is difficult to diagnose due to its insidious onset and nonspecific clinical and laboratory findings; most patients are misdiagnosed with NAFLD, NASH, cryptogenic cirrhosis, or familial dyslipidemia. The lipid profile is nonspecific, and often shows elevated total cholesterol and low-density lipoprotein (LDL)-cholesterol with low high-density lipoprotein (HDL)-cholesterol, and sometimes hypertriglyceridemia. Hypertransaminasemia may prompt a liver biopsy, often misinterpreted as NASH or NAFLD (29,31). Hepatosteatosis in LAL deficiency is microvesicular and intralysosomal, which allows histological discrimination using lysosomal markers (32). Birefringent cholesteryl ester crystals are pathognomonic (30).

Nevertheless, the easiest way to diagnose LAL deficiency is clinical suspicion, followed by measurement of LAL activity in DBS, which is readily available. The introduction of enzyme replacement therapy (sebelipase alfa), which improves transaminases, lipid profile, hepatomegaly, and atherosclerosis in CESD (33,34), has sparked interest in identifying disease groups with higher likelihood of LAL deficiency. For example, LAL deficiency could not be identified any patients in a study screening 1825 individuals with dyslipidemia and hypertransaminasemia, whereas two out of six patients with histological microvesicular steatosis or cryptogenic cirrhosis had LAL deficiency (35). After screening of 663 individuals with suspected familial hypercholesterolemia without a family history of hypercholesterolemia, no patients could be diagnosed (36). In a study of 810 children with unexplained hypertransaminasemia, organomegaly, hepatosteatosis, fibrosis, or cir-

rhosis, screening identified only two siblings with LAL deficiency, making the frequency of the disease only 0.1%, even in this high-risk cohort (37). Considering that LAL deficiency is treatable but rare, LAL activity has been proposed as a second-line test to assess the etiology of FLD (38).

Chanarin-Dorfman syndrome

Chanarin-Dorfman syndrome is a neutral lipid storage disorder characterized by congenital ichthyosis. Lipid vacuoles in granulocytes can be visualized in a peripheral blood smear. Patients may be identified in adulthood due to hepatosteatosis-related hypertransaminasemia. Muscle weakness, cataracts, ataxia, intellectual disability, and neuropsychiatric abnormalities can be additional features (39).

Niemann-Pick disease type C

The impairment of endosomal cholesterol processing caused by mutations in *NPC1* and *NPC2* genes result in a broad-spectrum neurovisceral lysosomal storage disorder termed as Niemann-Pick disease type C (NPC). Liver dysfunction in NPC is confined to the neonatal and early infantile period. Cholestatic jaundice with hepatosplenomegaly occurs in about one-half of NPC patients during this stage (40). Cholestasis often resolves spontaneously within a few months, but high mortality rates are also reported (41). Hepatosplenomegaly or isolated splenomegaly persists for a variably long time, usually into adulthood. Neurological involvement may emerge at any time between early childhood and old age, demonstrating a multitude of progressive signs and symptoms including but not limited to psychomotor delay, ataxia, seizures, gelastic cataplexy, dystonia, psychiatric problems, and vertical supranuclear gaze palsy. Low HDL-cholesterol, elevated chitotriosidase are nonspecific laboratory clues for suspecting NPC (40). Elevated oxysterols, lysosphingomyelins in blood and positive filipin staining in cultured fibroblasts are targeted tests (42). The prominent histological finding in the liver is the lysosomal storage of cholesterol and glycolipids in Kupffer cells, but mild-moderate steatosis may also be present (10). The diagnosis is confirmed by genetic analysis. Miglustat, which inhibits the synthesis of the accumulated lipids in NPC, is indicated for neurological symptoms but is ineffective in visceral manifestations (40).

DISORDERS OF LIPOPROTEIN METABOLISM

Familial hypertriglyceridemias

Familial combined hyperlipidemia (elevation of both triglycerides and LDL-cholesterol) is a very common autosomal dominant trait with a prevalence of 1-2%. FLD has been reported in 75% of patients. Standard lipid-lowering treatment is recommended (43).

Familial chylomicronemia is a rare and severe form of hypertriglyceridemia (>1,000 and sometimes >30,000 mg/dL) resulting from a deficiency of lipoprotein lipase or its activators. It is characterized by lipemic serum, eruptive xanthomas, hepatosplenomegaly, and recurrent pancreatitis (44). Hepatosteatosis due to triglyceride storage is reported (45). Management with lipid-lowering drugs and low-fat diet supplemented by medium-chain triglycerides (MCT) and omega-3 fatty acids can be partially successful.

Hypobetalipoproteinemia and abetalipoproteinemia

Hypobetalipoproteinemia is a common autosomal dominant trait resulting in low blood lipid levels (LDL-cholesterol, 20-50 mg/dL) due to defective transport of triglycerides from the liver to the bloodstream, causing intrahepatic fat accumulation (46). While hypolipoproteinemia is usually asymptomatic and is recognized incidentally in lipid profiles or hepatic ultrasound, abetalipoproteinemia is a rare and severe multisystem disease caused by a defect in the assembly and export of very low density lipoprotein (VLDL)-triglyceride particles. Fat malabsorption resulting in steatorrhea, chronic diarrhea, and failure to thrive are usually apparent by adolescence or young adulthood. Serum triglyceride and total cholesterol levels are extremely low; LDL-cholesterol and apolipoprotein(B) may be absent. The deficiency of fat-soluble vitamins (predominantly vitamin E and A) is responsible for the hallmarks of this disorder, including neurodegeneration, ataxia, peripheral neuropathy, acanthocytosis, hemolysis, night blindness, pigmentary retinopathy, corneal and conjunctival sclerosis, and coagulopathy. Hepatomegaly and cirrhosis may occur due to steatosis. Early diagnosis and treatment with fat-soluble vitamins is critical to prevent irreversible neurological manifestations. The rare autosomal recessive form of hypobetalipoproteinemia is similar to abetalipoproteinemia (46,47).

DISORDERS OF AMINO ACID METABOLISM

Hereditary tyrosinemia type 1

The involvement of liver in hereditary tyrosinemia type 1 (HT1), also known as hepatorenal tyrosinemia, can take almost any form. Infants may develop cholestasis and liver failure a few weeks after birth. Children or adolescents may present with hypertransaminasemia, FLD, cirrhosis,

or hepatocellular carcinoma (HCC) without obvious preceding symptoms. Renal phosphate loss due to proximal tubulopathy causes phosphopenic rickets, which may be the presenting symptom (48). Liver biopsies show steatosis, accompanied by nodules and cirrhosis (49). All individuals with unexplained liver disease and patients with early-onset HCC should be investigated for HT1. Accompanying renal Fanconi syndrome or neurological symptoms (porphyria-like pain in the abdomen and extremities, autonomic dysfunction, or encephalopathy) should also be considered a sign for the clinician to consider HT1.

Although HT1 is caused by a defect in the tyrosine degradation pathway, "tyrosinemia" is a misnomer, as it is not the accumulation of tyrosine but the accumulation of succinylacetone and fumarylacetoacetate that is responsible for the clinical findings. Hypertyrosinemia is only a consequence of liver dysfunction, and its absence does not rule out HT1. Markedly elevated α-fetoprotein should be a sign of HT1. Increased succinylacetone establishes the diagnosis (48). It may be difficult for inexperienced laboratories to detect succinylacetone in urine organic acid analysis, in which case, it may be better to rely on succinylacetone in DBS.

Before the introduction of nitisinone, an oral drug that inhibits the formation of succinylacetone and fumarylacetoacetate, HCC or liver transplantation was inevitable, and survival was low. Nowadays, early diagnosis and treatment with nitisinone, coupled with dietary treatment can provide excellent prognosis for this previously fatal disease. Liver transplantation is reserved for late-treated patients with liver failure or non-metastatic HCC (48).

Disorders of the urea cycle

Ammonia is the toxic end-product of amino acid metabolism, which is converted to urea with the sequential action of six main enzymes of the urea cycle. Inherited deficiencies of these enzymes usually present with hyperammonemic encephalopathy early in life, but some may show late-onset neurological symptoms. Older patients with relatively mild disease may describe nausea and discomfort after high-protein meals and therefore may have adopted a vegetarian lifestyle. Liver involvement can occur in all six enzyme deficiencies, mainly as FLD progressing to cirrhosis or recurrent acute liver failure, which may be the presenting feature (50,51). Reye syndrome can also occur, especially triggered by infections or intake of sodium valproate or aspirin (52,53). The analysis of plasma and urine amino acids, argininosuccinic acid and urine orotic acid can guide the diagnosis of urea cycle enzyme deficiencies, which can be confirmed by genetic testing. Dietary treatment and pharmacological ammonia scavengers are effective; dialysis is used in refractory or severe acute hyperammonemic encephalopathy.

Citrin is a transporter protein located on the mitochondrial membrane, which helps balance the redox state in the cell and provides substrates for the cytosolic enzymes of the urea cycle. Citrin deficiency manifests as different phenotypes at different stages of life and is thus a mimicker of other metabolic diseases and NAFLD (54). Infants may develop intrahepatic cholestasis, hepatomegaly, diffuse steatosis, and liver failure, which spontaneously resolve but rarely may require transplantation. In childhood, patients develop an aversion to carbohydrate-rich foods and a preference for proteins and fats. At this stage, they may present with failure to thrive, anorexia, dyslipidemia, pancreatitis, or FLD. In adult patients with or without symptomatic disease during childhood, recurrent attacks of hyperammonemic encephalopathy may occur, often triggered by the intake of sugar, alcohol or certain medications. In contrast to enzyme deficiencies of the urea cycle, administration of glucose at high concentrations exacerbates hyperammonemia in citrin deficiency (55).

CONGENITAL DISORDERS OF GLYCOSYLATION (CDGs)

CDGs are a rapidly growing class of IEMs containing over 100 known diseases. The common theme among all CDGs is the impairment of glycosylation of proteins or lipids, which is a fundamental cellular process. More than one-half of human proteins require post-translational glycosylation for proper function, and all organs contain glycoproteins or glycolipids. Therefore, CDGs are multisystem disorders, which almost always affect the brain and often other organs, including the liver. Liver histology in CDG usually shows fibrosis, but may also exhibit steatosis, cirrhosis, cholestasis, or bile duct cysts (56). CDGs are designated with the name of the mutated gene, followed by "-CDG".

Because CDGs are so numerous and encompass a vast array of phenotypes, only those with isolated or predominant hepatic disease will be mentioned here. Phosphomannomutase 2 deficiency (PMM2-CDG) is by far the most common CDG and has a myriad of multisystem findings other than hepatic fibrosis, steatosis and hypertransaminasemia, psychomotor delay, microcephaly, strabismus, abnormal fat distribution, inverted nipples, proteinuria, and hyperinsulinism, among others. Liver disease may be mild with slowly-progressing fibrosis or fatal with severe coagulopathy, but is always associated with other systemic features.

In contrast, liver disease is the hallmark of mannose phosphate isomerase deficiency (MPI-CDG), which manifests as hepatomegaly, coagulopathy, hypoglycemia, thrombophilia, protein-losing enteropathy and hypoalbuminemia in infancy, and early death. Neurological involvement is minimal or absent. Mannose supplementation is partially beneficial, but liver disease may still be progressive (56). Similarly, FLD, hepatomegaly, hypertransaminasemia, and coagulopathy are often the presenting findings of patients with phosphoglucomutase 1 deficiency (PGM1-CDG) who may also have failure to thrive, cardiomyopathy, hyperinsulinemic hypoglycemia, and orofacial malformations (mainly cleft palate or bifid uvula) with normal neurological functions. Notably, galactose supplementation seems to be significantly beneficial in PGM1-CDG (57). Transmembrane protein 199 deficiency (TMEM199-CDG) is a rare CDG with pure but mild hepatic involvement. Patients have hepatosteatosis, hypertransaminasemia, dyslipidemia, and remarkably elevated alkaline phosphatase. Copper accumulation and low ceruloplasmin requires differential diagnosis with Wilson disease (58). CCDC115-CDG, ATP6AP1-CDG, different subtypes of ALG-CDGs and COG-CDGs are other CDGs with liver involvement (56).

An easy screening test for the N-glycosylation disorders is the demonstration of abnormal glycosylation of transferrin by isoelectric focusing. A case report of an asymptomatic adult incidentally diagnosed with MPI-CDG using this method suggests that there may be undiagnosed individuals with milder phenotypes (59).

OTHER METABOLIC LIVER DISEASES

Wilson disease

Wilson disease is one of the more common IEMs, with an estimated global prevalence of one in 30,000, and may have a much higher prevalence in highly consanguineous populations. Many cases are believed to be unrecognized. Wilson disease can present in toddlers or the elderly, but liver disease usually starts before the age of 20 years and neurological disease after the age of 10 years. The involvement of the liver encompasses a wide spectrum, ranging from asymptomatic FLD or hypertransaminasemia to liver failure (60,61). Increased hepatic echogenicity on ultrasonography can be the only clinical finding (62). Similarly, neurologic involvement is also diverse, including worsening of school performance, incoordination, gait disturbances, dystonia, behavioral changes, and psychiatric problems. Renal Fanconi syndrome and nonimmune hemolytic anemia are also reported (60,61).

Wilson disease should be considered in individuals with any unexplained hepatic and/or neurological findings, since early diagnosis and treatment with copper chelation and zinc salts is necessary for better prognosis. Symptomatic treatment is also available for the management of various symptoms. Transplantation is usually reserved for patients with liver failure (60).

Inborn errors of bile acid synthesis

Inborn errors of bile acid synthesis arise from deficiencies of enzymes required for the synthesis of cholic and chenodeoxycholic acids from cholesterol. Disorders of bile acid synthesis typically cause cholestatic liver disease during the first months of life with unexpectedly normal gamma-glutamyl transferase.. Liver histology shows giant-cell hepatitis, cholestasis, and occasional steatosis (63). Progressive neurological disease may appear at any age, with or without a history of early infantile liver disease. Rarely, liver disease may develop later in life (64). Establishing the diagnosis of bile acid synthesis defects by demonstrating abnormal bile acids in urine and plasma or by genetic analysis is crucial, as the treatment of severe liver disease and prevention of neurologic complications is possible with cholic or chenodeoxycholic acid therapy in most patients (63,64).

Alpha-1-antitrypsin deficiency

Liver disease in α_1-antitrypsin (AAT) deficiency is mostly associated with homozygosity of the Z allele (PiZZ) and may manifest in children mostly as self-resolving neonatal cholestatic hepatitis or asymptomatic hypertransaminasemia, but some may develop severe cholestasis and liver failure. Progressive liver disease is uncommon in adults, but the risk of chronic hepatitis or cirrhosis may increase with age (65). Apart from the diagnostic periodic acid-Schiff-positive and diastase-resistant globules, liver histology can be variable, exhibiting macrovesicular steatosis, giant cell hepatitis, inflammation, necrosis, or cirrhosis (10,65). Globular inclusions may be misinterpreted in adults as consistent with NAFLD. Although low serum AAT levels may raise suspicion of AAT deficiency, the gold standards for diagnosis are phenotyping the AAT protein or genotyping. Treatment is supportive, but specific therapeutics are under development (65).

NBAS deficiency

NBAS, a protein involved in retrograde transport from the Golgi to the endoplasmic reticulum, was recently shown to be deficient in children with recurrent acute liver failure. The first liver crisis was often triggered by fever in

infancy but could be delayed until school age. Liver biopsies primarily showed microvesicular steatosis and hepatocyte pseudorosettes. Rapid identification of multiple cases after the discovery of the disease suggests that NBAS deficiency may be responsible for a significant part of unexplained recurrent acute liver dysfunction in children. Treatment is supportive; antipyretics, glucose, and lipid infusions are helpful (66,67).

Table 3. Red flags in history, physical examination or basic laboratory tests for suspicion of IEMs in patients with FLD.

General	**Hepatic**	**Neurologic**
Young age	Acute or recurrent LF	Acute encephalopathy
Similar family history	Reye-like syndrome	Intellectual disability
Deceased sibling	Severe hepatomegaly	Developmental delay
Parental consanguinity*	Cholestasis	Microcephaly
Maternal HELLP syndrome	Early cirrhosis	Neurodegeneration
Maternal AFLP	Cryptogenic cirrhosis	Epilepsy
Atypical facial appearance	Microvesicular steatosis	Gelastic cataplexy
Failure to thrive	Early HCC	Ataxia
Malnutrition	Severe valproate toxicity	Spasticity
Resistance to treatment	Elevated AFP without HCC	Dystonia
Sudden death		Tremor
	Gastrointestinal	Early parkinsonism
Metabolic /Endocrine	Aversion to food groups	Peripheral neuropathy
Severe hyperlipidemia	Cleft palate/bifid uvula	Psychiatric disturbances
Hypocholesterolemia	Porphyria-like crises	
Hypoglycemia without LF	Inflammatory bowel disease	**Ocular/Auditory**
Hyperammonemia	Malabsorption	Strabismus
Metabolic acidosis	Steatorrhea	Nystagmus
Elevated lactate	Chronic diarrhea	Roving eye movements
Adrenal calcification	Protein-losing enteropathy	Supranuclear gaze palsy
	Recurrent pancreatitis	Corneal sclerosis
Hematologic		Premature corneal arcus
Lipemic serum	**Musculoskeletal**	Cataracts
Hyperviscosity	Muscle weakness	Retinopathy
Nonimmune hemolysis	Muscle cramps	Optic atrophy
Acanthocytosis	Rhabdomyolysis	Night blindness
Neutropenia	Hypotonia	Hearing loss
Vacuolated cells	Elevated CK	
Splenomegaly	Phosphopenic rickets	**Skin**
		Congenital ichthyosis
Cardiovascular	**Renal**	Eruptive xanthomas
Cardiomyopathy	Proximal tubulopathy	Abnormal fat pads
Dysrhythmia	Hyperuricemia without MS	Inverted nipples
Premature atherosclerosis	Proteinuria	Orange-peel skin

*When inquiring about parental consanguinity, keep in mind that parents from the same or neighboring small villages may deny consanguinity, but may share many common alleles because of inbreeding due to geographic isolation, predisposing their children to autosomal recessive traits. AFLP: acute fatty liver of pregnancy; AFP: α-fetoprotein; CK: creatine kinase; FLD: fatty liver disease, HCC: hepatocellular carcinoma; HELLP: hemolysis, elevated liver enzymes, low platelets; IEMs: Inborn errors of metabolism, LF: liver failure; MS: metabolic syndrome.

DIAGNOSTIC APPROACH TO FATTY LIVER DISEASE WITH RESPECT TO INBORN ERRORS OF METABOLISM

In children, the diagnosis of NAFLD should be given considerable thought and evaluation. The development of hepatosteatosis before the age of 5 years is almost always associated with underlying metabolic, systemic, syndromic, or other genetic conditions (2,10). Therefore, the younger the age at development of FLD, the more thorough the work-up for IEMs should be. IEMs must be rigorously investigated before performing a liver biopsy in young children. Common and treatable IEMs that align with the clinical picture should also be excluded in children aged 5-10 years and in older lean individuals with FLD.

In patients older than 10 years, NAFLD is highly likely if the individual is obese/overweight, especially in the presence of a similar family history, central obesity, insulin resistance, or excessive fructose consumption. Nevertheless, as obesity does not rule out underlying or coexisting conditions, it is recommended to screen this patient population for other common liver diseases, such as infections, autoimmunity, toxic hepatitis, celiac disease, hemochromatosis, AAT deficiency, and Wilson disease (2,68). In older and overweight patients, decisions about how rigorously to investigate IEMs should be made on an individual basis while prioritizing treatable diseases and considering the rarity of each condition together with the likelihood of an IEM and the potential benefit of the diagnosis to the patient and family. A suggested diagnostic approach to IEMs in patients with FLD can be found in Figure 1.

While experienced pathologists can recognize the signs of underlying diagnoses in liver biopsies, it is usually the suspicion of the clinician that initiates the laboratory work-up for IEMs. A comprehensive list of pertinent laboratory investigations is included in Figure 1. This list is

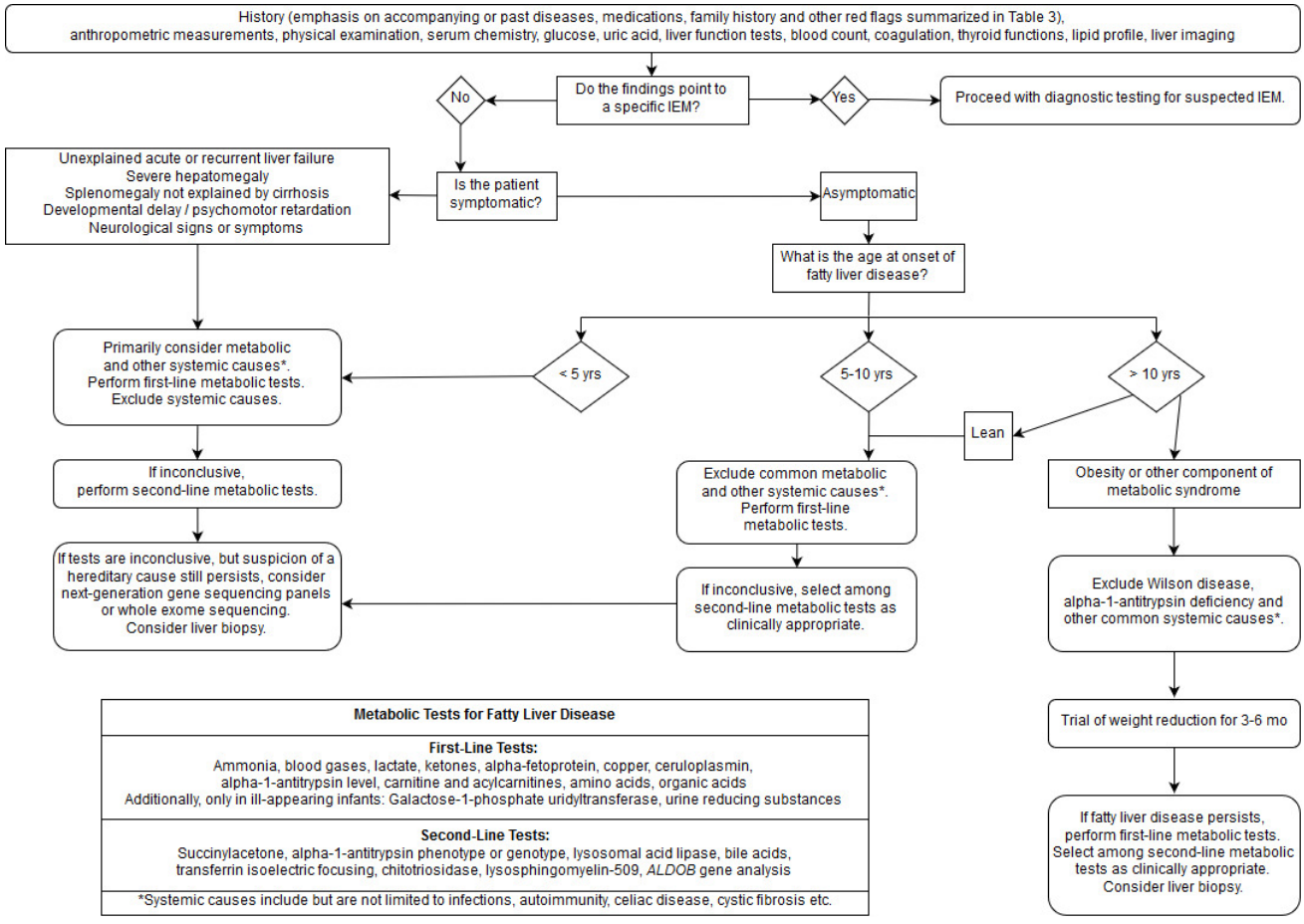

Figure 1. Suggested diagnostic approach for IEMs in patients with fatty liver disease (2,5,10).

not intended to act as a checklist to be applied verbatim to all patients with FLD, but rather as a reminder of possible laboratory tests to be selected in accordance with clinical manifestations. It is of utmost importance to obtain a detailed history and perform a complete physical and neurological examination to formulate possible differential diagnoses, since ordering numerous nontargeted "routine" tests sometimes reveals nonspecific biochemical abnormalities that may be difficult to interpret, leading the clinician down the rabbit hole and away from the actual diagnosis. In other words, laboratory work-up cannot replace a thorough history and physical examination aimed at finding red flags of IEMs (Table 3).

Although most IEMs are clinically rich entities with multiple signs and symptoms, physicians should be aware that serious, but treatable conditions, such as hereditary fructose intolerance, lysosomal acid lipase deficiency, familial dyslipidemias, hereditary tyrosinemia type 1, citrin deficiency, PGM1-CDG, and Wilson disease may present predominantly or solely with FLD.

CONCLUSION

Detailed investigations into IEMs are usually performed in young children with FLD since hepatosteatosis is known to be an important finding of metabolic hepatopathies in this age group. However, in older patients, particularly adults, physicians rarely consider IEMs in the differential diagnosis, if at all. Additionally, the rise in the prevalence of obesity further diminishes the relative abundance of IEMs among patients with FLD. Even so, especially in populations with high rates of inbreeding and consanguineous marriages, gastroenterologists should consider the fact that IEMs may present with FLD later in life with or without associated signs and symptoms, and the road to accurate diagnosis starts with the clinician's suspicion, guided by general knowledge of IEMs and a thorough clinical evaluation.

Peer-review: Externally peer-reviewed.

Author Contributions: Concept - H.S.S., Y.Y.; Design - H.S.S., Y.Y.; Supervision - H.S.S.; Data Collection and/or Processing - Y.Y.; Analysis and/or Interpretation - H.S.S., Y.Y.; Literature Search - Y.Y.; Writing Manuscript - H.S.S., Y.Y.; Critical Review - H.S.S., Y.Y.

Conflict of interest: The authors have no conflict of interest to declare.

Financial Disclosure: The authors declared that this study has received no financial support.

REFERENCES

1. Rinella ME. Nonalcoholic fatty liver disease: a systematic review. JAMA 2015; 313: 2263-73. **[CrossRef]**
2. Vajro P, Lenta S, Socha P, et al. Diagnosis of nonalcoholic fatty liver disease in children and adolescents: position paper of the ESPGHAN Hepatology Committee. J Pediatr Gastroenterol Nutr 2012; 54: 700-13. **[CrossRef]**
3. Goh GB, McCullough AJ. Natural History of Nonalcoholic Fatty Liver Disease. Dig Dis Sci 2016; 61: 1226-33. **[CrossRef]**
4. Schwimmer JB, Deutsch R, Kahen T, Lavine JE, Stanley C, Behling C. Prevalence of fatty liver in children and adolescents. Pediatrics 2006; 118: 1388-93. **[CrossRef]**
5. Chalasani N, Younossi Z, Lavine JE, et al. The diagnosis and management of non-alcoholic fatty liver disease: practice guideline by the American Gastroenterological Association, American Association for the Study of Liver Diseases, and American College of Gastroenterology. Gastroenterology 2012; 142: 1592-609. **[CrossRef]**
6. Ferreira CR, van Karnebeek CDM, Vockley J, Blau N. A proposed nosology of inborn errors of metabolism. Genet Med 2019; 21: 102-6. **[CrossRef]**
7. Waters D, Adeloye D, Woolham D, Wastnedge E, Patel S, Rudan I. Global birth prevalence and mortality from inborn errors of metabolism: a systematic analysis of the evidence. J Glob Health 2018; 8: 021102. **[CrossRef]**
8. Afzal RM, Lund AM, Skovby F. The impact of consanguinity on the frequency of inborn errors of metabolism. Mol Genet Metab Rep 2018; 15: 6-10. **[CrossRef]**
9. European Association for the Study of the Liver, European Association for the Study of Diabetes, European Association for the Study of Obesity. EASL-EASD-EASO Clinical Practice Guidelines for the management of non-alcoholic fatty liver disease. J Hepatol 2016; 64: 1388-402.
10. Hegarty R, Deheragoda M, Fitzpatrick E, Dhawan A. Paediatric fatty liver disease (PeFLD): All is not NAFLD - Pathophysiological insights and approach to management. J Hepatol 2018; 68: 1286-99. **[CrossRef]**
11. Demirbas D, Brucker WJ, Berry GT. Inborn Errors of Metabolism with Hepatopathy: Metabolism Defects of Galactose, Fructose, and Tyrosine. Pediatr Clin North Am 2018; 65: 337-52. **[CrossRef]**
12. Jumbo-Lucioni PP, Hopson ML, Hang D, Liang Y, Jones DP, Fridovich-Keil JL. Oxidative stress contributes to outcome severity in a Drosophila melanogaster model of classic galactosemia. Dis Model Mech 2013; 6: 84-94. **[CrossRef]**
13. Welling L, Bernstein LE, Berry GT, et al. International clinical guideline for the management of classical galactosemia: diagnosis, treatment, and follow-up. J Inherit Metab Dis 2017; 40: 171-6. **[CrossRef]**
14. Ozen H. Glycogen storage diseases: new perspectives. World J Gastroenterol 2007; 13: 2541-53. **[CrossRef]**
15. Gogus S, Kocak N, Ciliv G, et al. Histologic features of the liver in type Ia glycogen storage disease: comparative study between different age groups and consecutive biopsies. Pediatr Dev Pathol 2002; 5: 299-304. **[CrossRef]**
16. Li XH, Gong QM, Ling Y, et al. Inherent lipid metabolic dysfunction in glycogen storage disease IIIa. Biochem Biophys Res Commun 2014; 455: 90-7. **[CrossRef]**
17. Yoo HW, Shin YL, Seo EJ, Kim GH. Identification of a novel mutation in the GLUT2 gene in a patient with Fanconi-Bickel syndrome presenting with neonatal diabetes mellitus and galactosaemia. Eur J Pediatr 2002; 161: 351-3. **[CrossRef]**

18. Shieh JJ, Lu YH, Huang SW, et al. Misdiagnosis as steatohepatitis in a family with mild glycogen storage disease type 1a. Gene 2012; 509: 154-7. [CrossRef]
19. Chou JY, Jun HS, Mansfield BC. Glycogen storage disease type I and G6Pase-beta deficiency: etiology and therapy. Nat Rev Endocrinol 2010; 6: 676-88. [CrossRef]
20. Olpin SE. Pathophysiology of fatty acid oxidation disorders and resultant phenotypic variability. J Inherit Metab Dis 2013; 36: 645-58. [CrossRef]
21. Longo N, Frigeni M, Pasquali M. Carnitine transport and fatty acid oxidation. Biochim Biophys Acta 2016; 1863: 2422-35. [CrossRef]
22. Tein I. Impact of fatty acid oxidation disorders in child neurology: from Reye syndrome to Pandora's box. Dev Med Child Neurol 2015; 57: 304-6. [CrossRef]
23. Rahman S. Gastrointestinal and hepatic manifestations of mitochondrial disorders. J Inherit Metab Dis 2013; 36: 659-73. [CrossRef]
24. El-Hattab AW, Craigen WJ, Scaglia F. Mitochondrial DNA maintenance defects. Biochim Biophys Acta Mol Basis Dis 2017; 1863: 1539-55. [CrossRef]
25. Unal O, Hismi B, Kilic M, et al. Deoxyguanosine kinase deficiency: a report of four patients. J Pediatr Endocrinol Metab 2017; 30: 697-702. [CrossRef]
26. Fuchs SA, Schene IF, Kok G, et al. Aminoacyl-tRNA synthetase deficiencies in search of common themes. Genet Med 2019; 21: 319-30. [CrossRef]
27. Brassier A, Ottolenghi C, Boutron A, et al. Dihydrolipoamide dehydrogenase deficiency: a still overlooked cause of recurrent acute liver failure and Reye-like syndrome. Mol Genet Metab 2013; 109: 28-32. [CrossRef]
28. Paiva Coelho M, Martins E, Vilarinho L. Diagnosis, management, and follow-up of mitochondrial disorders in childhood: a personalized medicine in the new era of genome sequence. Eur J Pediatr 2019; 178: 21-32. [CrossRef]
29. Pericleous M, Kelly C, Wang T, Livingstone C, Ala A. Wolman's disease and cholesteryl ester storage disorder: the phenotypic spectrum of lysosomal acid lipase deficiency. Lancet Gastroenterol Hepatol 2017; 2: 670-9. [CrossRef]
30. Bernstein DL, Hulkova H, Bialer MG, Desnick RJ. Cholesteryl ester storage disease: review of the findings in 135 reported patients with an underdiagnosed disease. J Hepatol 2013; 58: 1230-43. [CrossRef] https://doi.org/10.1016/j.jhep.2013.02.014
31. Burton BK, Deegan PB, Enns GM, et al. Clinical Features of Lysosomal Acid Lipase Deficiency. J Pediatr Gastroenterol Nutr 2015; 61: 619-25. [CrossRef]
32. Hulkova H, Elleder M. Distinctive histopathological features that support a diagnosis of cholesterol ester storage disease in liver biopsy specimens. Histopathology 2012; 60: 1107-13. [CrossRef]
33. Erwin AL. The role of sebelipase alfa in the treatment of lysosomal acid lipase deficiency. Therap Adv Gastroenterol 2017; 10: 553-62. [CrossRef]
34. Wilson DP, Friedman M, Marulkar S, Hamby T, Bruckert E. Sebelipase alfa improves atherogenic biomarkers in adults and children with lysosomal acid lipase deficiency. J Clin Lipidol 2018; 12: 604-14. [CrossRef]
35. Reynolds TM, Mewies C, Hamilton J, et al. Identification of rare diseases by screening a population selected on the basis of routine pathology results-the PATHFINDER project: lysosomal acid lipase/cholesteryl ester storage disease substudy. J Clin Pathol 2018; 71: 608-13. [CrossRef]
36. Ashfield-Watt P, Haralambos K, Edwards R, et al. Estimation of the prevalence of cholesteryl ester storage disorder in a cohort of patients with clinical features of familial hypercholesterolaemia. Ann Clin Biochem 2019; 56: 112-7. [CrossRef]
37. Kuloglu Z, Kansu A, Selbuz S, et al. The Frequency of Lysosomal Acid Lipase Deficiency in Children With Unexplained Liver Disease. J Pediatr Gastroenterol Nutr 2019; 68: 371-6. [CrossRef]
38. Carter A, Brackley SM, Gao J, Mann JP. The global prevalence and genetic spectrum of lysosomal acid lipase deficiency: A rare condition that mimics NAFLD. J Hepatol 2019; 70: 142-50. [CrossRef]
39. Kazemi MH, Taghavi SA, Eshraghian A, Talebzadeh M, Hamidpour L. Education and imaging. Hepatology: Chanarin-Dorfman syndrome, a rare cause of fatty liver and steatohepatitis. J Gastroenterol Hepatol 2015; 30: 803. [CrossRef]
40. Vanier MT. Niemann-Pick disease type C. Orphanet J Rare Dis 2010; 5: 16. [CrossRef]
41. Gumus E, Haliloglu G, Karhan AN, et al. Niemann-Pick disease type C in the newborn period: a single-center experience. Eur J Pediatr 2017; 176: 1669-76. [CrossRef]
42. Deodato F, Boenzi S, Taurisano R, et al. The impact of biomarkers analysis in the diagnosis of Niemann-Pick C disease and acid sphingomyelinase deficiency. Clin Chim Acta 2018; 486: 387-94. [CrossRef]
43. Kneeman JM, Misdraji J, Corey KE. Secondary causes of nonalcoholic fatty liver disease. Therap Adv Gastroenterol 2012; 5: 199-207. [CrossRef]
44. Bamba V. Update on screening, etiology, and treatment of dyslipidemia in children. J Clin Endocrinol Metab 2014; 99: 3093-102. [CrossRef]
45. Kose E, Armagan C, Teke Kisa P, Onay H, Arslan N. Severe hyperchylomicronemia in two infants with novel APOC2 gene mutation. J Pediatr Endocrinol Metab 2018; 31: 1289-93. [CrossRef]
46. Welty FK. Hypobetalipoproteinemia and abetalipoproteinemia. Curr Opin Lipidol 2014; 25: 161-8. [CrossRef]
47. Lee J, Hegele RA. Abetalipoproteinemia and homozygous hypobetalipoproteinemia: a framework for diagnosis and management. J Inherit Metab Dis 2014; 37: 333-9. [CrossRef]
48. Chinsky JM, Singh R, Ficicioglu C, et al. Diagnosis and treatment of tyrosinemia type I: a US and Canadian consensus group review and recommendations. Genet Med 2017; 19. [CrossRef]
49. Fernandez-Lainez C, Ibarra-Gonzalez I, Belmont-Martinez L, Monroy-Santoyo S, Guillen-Lopez S, Vela-Amieva M. Tyrosinemia type I: clinical and biochemical analysis of patients in Mexico. Ann Hepatol 2014; 13: 265-72. [CrossRef]
50. Bigot A, Tchan MC, Thoreau B, Blasco H, Maillot F. Liver involvement in urea cycle disorders: a review of the literature. J Inherit Metab Dis 2017; 40: 757-69. [CrossRef]
51. Faghfoury H, Baruteau J, de Baulny HO, Haberle J, Schulze A. Transient fulminant liver failure as an initial presentation in citrullinemia type I. Mol Genet Metab 2011; 102: 413-7. [CrossRef]
52. Sinatra F, Yoshida T, Applebaum M, Masion Hoogenraad NJ, Sunshine P. Abnormalities of carbamyl phosphate synthetase and ornithine transcarbamylase in liver of patients with Reye's syndrome. Pediatr Res 1975; 9: 829-33. [CrossRef]
53. Yoshida I, Yoshino M, Watanabe J, Yamashita F. Sudden onset of ornithine carbamoyltransferase deficiency after aspirin ingestion. J Inherit Metab Dis 1993; 16: 917. [CrossRef]
54. Komatsu M, Yazaki M, Tanaka N, et al. Citrin deficiency as a cause of chronic liver disorder mimicking non-alcoholic fatty liver disease. J Hepatol 2008; 49: 810-20. [CrossRef]
55. Saheki T, Song YZ. Citrin Deficiency. Adam MP, Ardinger HH, Pagon RA, et al. editors. GeneReviews. Seattle: University of Washington; 2017.

56. Marques-da-Silva D, Dos Reis Ferreira V, Monticelli M, et al. Liver involvement in congenital disorders of glycosylation (CDG). A systematic review of the literature. J Inherit Metab Dis 2017; 40: 195-207. [CrossRef]
57. Wong SY, Gadomski T, van Scherpenzeel M, et al. Oral D-Galactose Supplementation in PGM1-CDG. Genet Med 2017; 19: 1226-1235. [CrossRef]
58. Jansen JC, Timal S, van Scherpenzeel M, et al. TMEM199 Deficiency Is a Disorder of Golgi Homeostasis Characterized by Elevated Aminotransferases, Alkaline Phosphatase, and Cholesterol and Abnormal Glycosylation. Am J Hum Genet 2016; 98: 322-30. [CrossRef]
59. Helander A, Jaeken J, Matthijs G, Eggertsen G. Asymptomatic phosphomannose isomerase deficiency (MPI-CDG) initially mistaken for excessive alcohol consumption. Clin Chim Acta 2014; 431: 15-8. [CrossRef]
60. Czlonkowska A, Litwin T, Dusek P, et al. Wilson disease. Nat Rev Dis Primers 2018; 4: 21. [CrossRef]
61. Roberts EA, Socha P. Wilson disease in children. Handb Clin Neurol 2017; 142: 141-56. [CrossRef]
62. Akpinar E, Akhan O. Liver imaging findings of Wilson's disease. Eur J Radiol 2007; 61: 25-32. [CrossRef]
63. Clayton PT. Disorders of bile acid synthesis. J Inherit Metab Dis 2011; 34: 593-604. [CrossRef]
64. Heubi JE, Setchell KDR, Bove KE. Inborn Errors of Bile Acid Metabolism. Clin Liver Dis 2018; 22: 671-87. [CrossRef]
65. Patel D, Teckman JH. Alpha-1-Antitrypsin Deficiency Liver Disease. Clin Liver Dis 2018; 22: 643-55. [CrossRef]
66. Haack TB, Staufner C, Kopke MG, et al. Biallelic Mutations in NBAS Cause Recurrent Acute Liver Failure with Onset in Infancy. Am J Hum Genet 2015; 97: 163-9. [CrossRef]
67. Staufner C, Haack TB, Kopke MG, et al. Recurrent acute liver failure due to NBAS deficiency: phenotypic spectrum, disease mechanisms, and therapeutic concepts. J Inherit Metab Dis 2016; 39: 3-16. [CrossRef]
68. Abd El-Kader SM, El-Den Ashmawy EM. Non-alcoholic fatty liver disease: The diagnosis and management. World J Hepatol 2015; 7: 846-58. [CrossRef]