Esophageal Mucosal Autograft for Preventing Stricture After Widespread Endoscopic Submucosal Dissection of Superficial Esophageal Lesions

Yu Zhang[1,2,3], Xin-Li Mao[1,2,3], Wei Zhu[1], Hai-Hong Zheng[4], Shen-Kang Zhou[5], Li-Ping Ye[2,3], You-Ming Li[1,*]

[1]Department of Gastroenterology, The First Affiliated Hospital, Zhejiang University School of Medicine, Hangzhou, Zhejiang Province, China
[2]Department of Gastroenterology, Taizhou Hospital of Zhejiang Province, Zhejiang University School of Medicine, Linhai, Zhejiang Province, China
[3]Key Laboratory of Minimally Invasive Techniques & Rapid Rehabilitation of Digestive System Tumor of Zhejiang Province, Linhai, Zhejiang Province, China
[4]Department of Pathology, Taizhou Hospital of Zhejiang Province, Zhejiang University School of Medicine, Linhai, Zhejiang Province, China
[5]Department of Gastrointestinal Surgery, Taizhou Hospital of Zhejiang Province, Zhejiang University School of Medicine, Linhai, Zhejiang Province, China

Cite this article as: Zhang Y, Mao X, Zhu W, et al. Esophageal mucosal autograft for preventing stricture after widespread endoscopic submucosal dissection of superficial esophageal lesions. *Turk J Gastroenterol.* 2022;33(4):312-319.

ABSTRACT

Background: *Although esophageal mucosal autograft prevents esophageal stricture after widespread endoscopic submucosal dissection and has been reported as a new technique, it is relatively unproven in clinical practice. This prospective study was conducted to evaluate our experience using esophageal mucosal autograft to prevent strictures after widespread endoscopic submucosal dissection in patients with widespread superficial esophageal lesions.*

Methods: *Between October 2017 and June 2018, 15 patients with widespread superficial esophageal lesions were consecutively treated with widespread endoscopic submucosal dissection and then underwent esophageal mucosal autograft. The main outcomes measured included esophageal epithelialization and esophageal stricture.*

Results: *The median longitudinal diameter of the widespread superficial esophageal lesions was 5.2 cm. All 15 patients were successfully treated with widespread endoscopic submucosal dissection and esophageal mucosal autograft, and the median procedural time was 182 minutes. During follow-up (median, 23 months), esophageal epithelialization was found in 13 patients (86.7%), and 7 patients experienced esophageal stricture (46.7%). In those 7 patients, the esophageal strictures were successfully relieved after endoscopic balloon dilation or endoscopic radial incision. No complications related to endoscopic balloon dilation/endoscopic radial incision occurred. Additionally, local recurrence was found in 1 patient with poorly differentiated squamous cell carcinoma, and further surgical resection was performed.*

Conclusions: *Esophageal mucosal autograft appears to be an efficient approach to reconstructing local esophageal epithelium and might have a potential role in preventing esophageal stricture after widespread endoscopic submucosal dissection. However, as a new technique, it needs more improvement to enhance its role in preventing esophageal stricture after widespread endoscopic submucosal dissection.*

Keywords: *Endoscopic submucosal dissection, esophageal mucosal autograft, esophageal stricture, superficial esophageal lesion*

INTRODUCTION

Esophageal stricture is a frequently experienced complication following esophageal endoscopic submucosal dissection (ESD) and can be either simple or complex.[1,2] Simple strictures are short (<2 cm), focal, and permit a standard endoscope passage. Complex structures are long (≥2 cm), irregular, angulated, and do not permit a standard endoscope passage.[2] Usually, esophageal strictures that occur after widespread ESD (wESD) are complex and can cause persistent nausea, vomiting, and dysphagia, thus reducing the quality of life.[3,4] Therefore, intervention is required to prevent esophageal stricture after wESD.

Several approaches have been reported to prevent esophageal stricture after wESD, including steroid therapy,[5] esophageal stent placement,[6] and autologous cell transplantation.[7] However, all these approaches have limitations that restrict their further clinical application. In 2014, Hochberger et al. indicated that gastric mucosal autograft might have a potential role in preventing esophageal stricture after esophageal wESD,[8] and

Corresponding author: **You-Ming Li**, e-mail: **lymzju@126.com**
Received: **November 19, 2020** Accepted: **June 14, 2021** Available Online Date: **December 28, 2021**
© Copyright 2021 by The Turkish Society of Gastroenterology · Available online at turkjgastroenterol.org
DOI: **10.5152/tjg.2021.201032**

another study using autologous esophageal mucosa to treat 9 patients after wESD reported a very high rate of esophageal stricture (8/9, 88.9%), even though the graft survival rate was 96.5%.[4] Therefore, further improvement in the use of mucosal autograft is needed for the treatment of patients with esophageal wESD. We describe our experience using esophageal mucosal autograft to prevent stricture in patients with widespread superficial esophageal lesions after wESD.

MATERIALS AND METHODS

Study Population

This study adhered to the Declaration of Helsinki and received approval from the Ethical Committee of Taizhou Hospital of Zhejiang Province (Linhai, China). The widespread superficial esophageal lesion was defined as the extent of the lesion being >75% of the esophageal circumference. The inclusion criteria of this study were: (1) the lesion was histologically diagnosed as esophageal cancer or high-grade intraepithelial neoplasia (HGIN); (2) the extent of the lesion was >75% of the circumference of the esophagus, and invasion did not reach the muscularis propria layer; (3) no evidence of lymph node or distant metastasis detected by computed tomography or endoscopic ultrasonography (EUS); and (4) no blood coagulation disorders (international normalized ratio > 2.0, platelet count < 70 000/mm^3), and the patient could tolerate anesthesia with tracheal intubation.

Between October 2017 and June 2018, 15 consecutive patients with widespread superficial esophageal lesions were prospectively enrolled. Before starting the study, all included patients signed an informed consent form after detailed verbal and written explanations regarding wESD, esophageal mucosal autograft, and other potential forms of treatment. Furthermore, we communicated to every patient that endoscopic balloon dilation (EBD) or surgery might be required if severe esophageal stricture occurred after wESD and esophageal mucosal autograft.

wESD Procedure

We performed wESD via a submucosal tunnel to resect the lesion as follows (Figure 1)[6]: (1) We first evaluated the lesion using white-light endoscopy (Q-260 J; Olympus, Tokyo, Japan) and narrow-band imaging, and then we used iodine staining with 2% Lugol's solution to stain the entire esophagus and determine the extent of the lesion, which was the area of Lugol-negative staining. (2) A high-frequency electronic cutting device (VIO 200D; ERBE, Tübingen, Germany) was set to the forced coagulation mode (effect 2 and output 40 W), and we made marks about 5 mm outside the margin of the lesion with

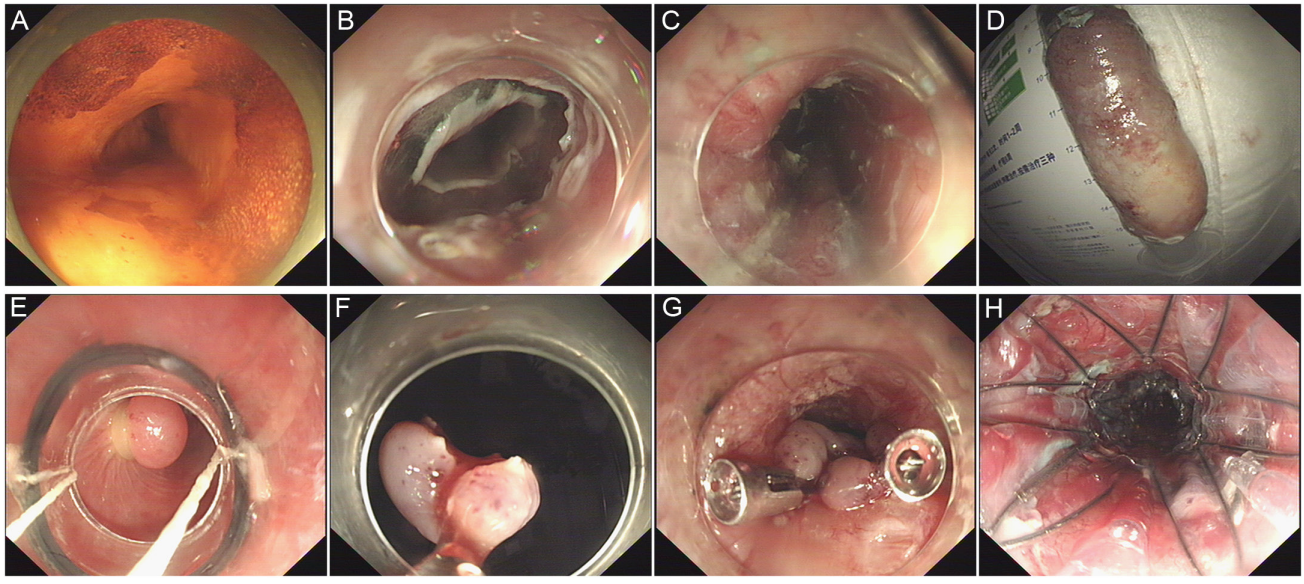

Figure 1. (A) Endoscopy showing a Lugol's-negative circumferential superficial esophageal lesion. (B, C) The lesion was resected by cESD via a submucosal tunnel. (D) The resection specimen is shown spanning the length of a 5-ml syringe. (E, F) The esophageal patch was resected from the patient's own normal esophagus mucosal tissue. (G) The esophageal patch was fixed to the denuded muscular esophageal wall circumferentially with 2 clips. (H) The esophageal patches were fixed with a retrievable, fully covered metal stent. cESD, circumferential endoscopic submucosal dissection.

a hybrid knife (ERBE). (3) Several milliliters of a solution (100 mL saline + 2 mL indigo carmine + 1 mL epinephrine) were injected at the lesion's anal margin, and a circular mucosal resection was made outside the markings in the ENDO CUT Q mode (effect 3, duration 3, and interval 2). During submucosal tunnel creation, care was taken to avoid excessive mucosal separation. (4) In the present study, double-tunnel dissection was used to resect the widespread esophageal lesion, as previously described.[6]

Esophageal Mucosal Autograft Procedure

An esophageal patch was resected with multiband mucosectomy (Duette; Cook Medical) in the ENDO CUT Q mode (effect 3, duration 3, and interval 2) from the patient's own healthy esophageal mucosal tissue, which was the area of Lugol-negative staining. Submucosal injection solution was not required during multiband mucosectomy. At least 0.5 cm of esophageal mucosa was retained between the edges of 2 mucosal defects where the esophageal patches were resected. The esophageal patch diameter was ≈ 1.0 cm, and every esophageal patch was fixed to the denuded muscular esophageal wall circumferentially by 2 clips, with each mucosal patch spaced 0.5 cm vertically away from the others. Next, the esophageal patches were fixed in place with a retrievable, fully covered metal stent (Sigma, China), the length of which exceeded the length of the mucosal defect by 4 cm so that the stent extended past both the proximal and distal borders of the mucosal defect by roughly 2 cm. The stent was removed 1 week after the procedure.

Postoperative Management

After the procedure, all patients were routinely examined by chest X-ray and/or CT scan to determine if subcutaneous emphysema, pneumoperitoneum, or pneumothorax had developed. If there were no serious complications or adverse events, the patient underwent a fasting period for 1 day postoperatively and then maintained a liquid diet for 2 days. After that, the patient was administered a no-residue diet. Intravenous infusion of esomeprazole was administered during the patient's hospital stay and taken orally for 6-8 weeks afterward.

Histopathological Evaluation

Two pathologists performed histopathological evaluation after the procedure. Based on the Paris endoscopic classification of superficial neoplastic lesions, the lesion was classified as type IIa, IIb, or IIc according to the bump height and concavity depth of the lesion. The bump height and concavity depth of the lesion were assessed by comparing the thickness of biopsy forceps.[9] According to the 2007 guidelines of the Japanese Esophageal Society, the lesion was classified as M1, M2, M3, or SM1 according to the invasion depth, which was evaluated by 2 pathology experts.[10] Then, the lesion was also diagnosed as intraepithelial neoplasia, or well-differentiated, moderately differentiated, or poorly differentiated squamous cell carcinoma (SCC) according to the pathological diagnostic criteria of the World Health Organization.[10] Complete resection was considered to have been achieved when the tumor was resected en bloc with tumor-free lateral and basal margins,[6] and esophageal stricture was defined as being the inability to insert a standard endoscope (11 mm diameter).[3]

Follow-up and Esophageal Stricture Management

Patients were routinely followed up with white-light endoscopy and narrow-band imaging at 1, 2, 6, and 12 months, and annually after that. An endoscopic examination was also immediately performed if the patient developed dysphagia with ingestion of solids during the follow-up. In this study, EBD or endoscopic radial incision (ERI) was performed in case of a patient developing esophageal stricture after the procedure. EBD was performed with a dilating balloon (CRE Balloon dilator, Boston Scientific, Marlborough, Mass, USA).

RESULTS

Clinical Characteristics

In this study, 15 patients (female 5; male 10) with widespread superficial esophageal lesions underwent wESD and esophageal mucosal autograft. The patients had a median age of 68 years (range, 59-82 years). Before the procedure, 7 patients had digestive symptoms, including 4 with epigastric pain, 2 with heartburn, and 1 with difficulty in swallowing. The other 8 patients had no specific symptoms or signs.

Of the 15 lesions, 8 lesions were detected in the lower esophagus, 4 in the middle-lower esophagus, and 3 in the middle esophagus. Based on the Paris endoscopic classification, 5 lesions were classified as type IIa, 9 were type IIb, and 1 was type IIc. Chromoendoscopy examination showed that the extent was 100% in 8 lesions. The lesions' median longitudinal diameter was 5.2 cm (range, 4.3-7.0 cm; interquartile range, 4.7-6.2 cm).

Treatment Outcomes and Complications

The details of treatment outcomes and related complications are summarized in Table 1. All 15 lesions were

Table 1. Therapeutic Outcome of 15 Patients with Superficial Esophageal Lesions Treated with cESD and Esophageal Mucosal Autograft

No.	Sex/Age	Lesion Location	Circumferential Range	Endoscopic Morphology	Complete Resection	Histological Depth	Pathology	No. of Patches	Stricture	Endoscopy (Number)	Surgery	Follow-up (Months)
1	F/75	Lower	Whole	Type IIb	Yes	M2	Well-differentiated SCCs	4	No	No	No	28
2	F/70	Middle-Lower	Whole	Type IIb	Yes	M1	HGIN	5	Yes	ERI	No	26
3	M/68	Lower	4/5	Type IIb	Yes	M3	Poorly differentiated SCCs	4	No	No	Yes	26
4	F/70	Lower	3/4	Type IIa	Yes	M1	HGIN	4	No	No	No	25
5	M/72	Middle-Lower	Whole	Type IIb	Yes	M3	Well-differentiated SCCs	5	Yes	EBD (8)	No	25
6	M/60	Middle	3/4	Type IIb	Yes	M3	Well-differentiated SCCs	4	No	No	No	25
7	M/65	Lower	Whole	Type IIa	Yes	M3	Well-differentiated SCCs	6	No	No	No	24
8	M/64	Lower	Whole	Type IIb	Yes	SM1	Well-differentiated SCCs	5	No	No	No	23
9	F/82	Middle	Whole	Type IIa	Yes	M1	Well-differentiated SCCs	4	Yes	ERI	No	22
10	M/59	Lower	3/4	Type IIb	Yes	M3	Well-differentiated SCCs	3	No	No	No	21
11	M/67	Middle-Lower	Whole	Type IIb	Yes	SM1	Well-differentiated SCCs	5	Yes	EBD (7)	No	21
12	M/59	Middle	3/4	Type IIb	Yes	M2	Well-differentiated SCCs	4	No	No	No	20
13	M/61	Lower	3/4	Type IIa	Yes	M2	Well-differentiated SCCs	3	Yes	EBD (2)	No	18
14	M/72	Middle-Lower	3/4	Type IIc	Yes	M2	Poorly differentiated SCCs	3	Yes	EBD (8)	No	16
15	F/71	Lower	Whole	Type IIa	Yes	SM1	Poorly differentiated SCCs	5	Yes	EBD (2)	No	14

SCCs, squamous cell carcinomas; EBD, endoscopic balloon dilation; ERI, endoscopic radial incision.

successfully and completely resected by wESD, with a median procedural time of 182 minutes (range, 142-267 minutes), measured from the time of the initial mucosal incision to the completed placement of the esophageal stent. All 15 patients underwent esophageal mucosal autograft successfully, and the median number of mucosal patches was 4 (range, 3-6 patches). During hospitalization, 1 patient developed acute deep vein thrombosis in the left lower extremity but recovered after anticoagulant therapy. Stent migration was identified in 1 patient by endoscopy 1 week after the procedure. No patient developed anaphylaxis to Lugol's solution, and no patient had other serious adverse events, including death, during hospitalization.

Additional Treatment and Follow-up

Histopathological examination showed that the 15 specimens (M1, 3 cases; M2, 4 cases; M3, 5 cases; and SM1, 3 cases) each displayed lateral and vertical tumor-free margins, and there was complete resection in all patients (100%). There were 2 HGIN lesions, 10 well-differentiated SCCs, and 3 poorly differentiated SCCs. For the patients with poorly differentiated SCC and/or SM1 lesions, further surgical resection, radiotherapy, or chemotherapy was recommended. However, none of the patients with poorly differentiated SCCs and/or SM1 lesions was willing to undergo further surgical resection, radiotherapy, or chemotherapy. However, during the follow-up, local recurrence was found in 1 patient with poorly differentiated SCC 14 months after the wESD procedure, and this patient underwent further surgical resection. The patient is still alive, 12 months after surgical resection.

The median follow-up was 23 months (range, 14-28 months). Esophageal epithelialization could be detected in 13 patients (13/15, 86.7%) by tissue biopsy of the wound at 4 weeks after discharge (Figure 2). During follow-up, 7 patients developed esophageal stricture (7/15, 46.7%). In patients undergoing whole circumferential ESD and partial circumferential ESD, the esophageal stricture rate was 62.5% (5/8) and 28.6% (2/7), respectively. Among the 7 patients with esophageal stricture, 5 were treated with EBD, and the number of EBDs ranged between 2 and 8. The other 2 patients were treated with ERI. The strictures in these 7 patients were successfully relieved after EBD or ERI, and no complications related to EBD/ERI, or adverse events associated with the site of mucosal patches occurred during follow-up in any patients.

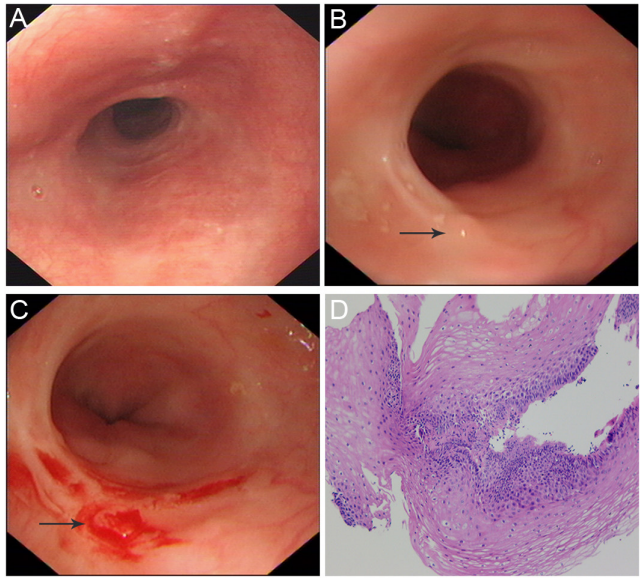

Figure 2. (A, B) The esophageal wound was completely healed with no stricture 6 months after the procedure. (C, D) Esophageal squamous epithelialization could be found.

DISCUSSION

ESD is a minimally invasive procedure that is generally acknowledged as a treatment for superficial esophageal lesions, such as early esophageal cancer or Barrett's esophagus. Compared with endoscopic mucosal resection (EMR), ESD can provide en bloc resection of large lesions, more precise histopathological assessment, and lower local recurrence rates.[11-13] However, the secondary esophageal stricture is often unavoidable in patients whose mucosal defects are ≥ 75% of the esophageal circumference. Several previous studies have proven wESD to be a reliable risk factor for postoperative esophageal stricture.[3,8]

Several approaches have been reported for preventing esophageal stricture after esophageal wESD, including steroid therapy,[5] esophageal stent placement,[6] and autologous cell transplantation.[7] Although these approaches can effectively prevent esophageal stricture, they restore esophageal intraluminal patency rather than recovering the esophageal epithelial structure. Furthermore, they may also cause adverse effects, which hinder their application clinically. The adverse effects of steroid therapy, for example, include delayed wound healing, potential risk of esophageal perforation, and immune suppression. Ishida et al.[14] reported a patient with severe disseminated nocardiosis during steroid therapy for preventing stricture after esophageal ESD. Esophageal stent therapy has

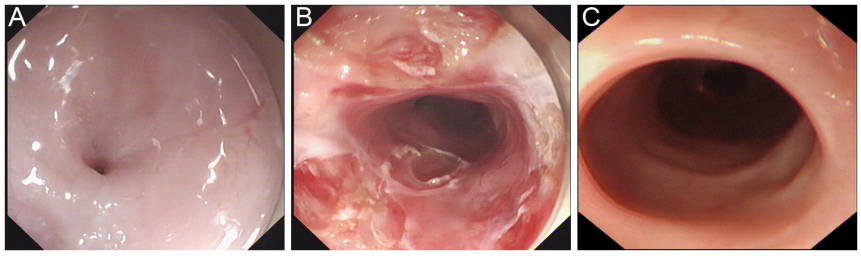

Figure 3. (A) The esophageal stricture after cESD could be observed by endoscopy. (B) ERI was performed to treated the esophageal stricture. (C) The esophageal stricture was relieved successfully 6 months after ERI. cESD, circumferential endoscopic submucosal dissection; ERI, endoscopic radial incision.

also been associated with some adverse effects, including chest pain, stent migration, and the potential risk of esophageal perforation.[1,6] Autologous cell transplantation can significantly decrease inflammation and fibrosis; it is time-consuming, expensive, and still mostly in the experimental stage.[7,15]

Excessive fibrosis and collagen deposition are the main tissue characteristics of esophageal strictures. Thus, the following factors may in part constitute the main mechanisms of esophageal stricture after wESD[1,16]: (1) lack of esophageal epithelial layer to provide a barrier against digestive juices, such as saliva, gastric acid, digestive enzymes, and microorganisms; and (2) inflammatory reaction of the esophageal wound stimulated by physical and chemical factors, such as the use of a high-frequency electric surgical knife and/or digestive juices, which could result in fibrosis and scar formation, and finally contribute to esophageal stricture. Thus, reconstruction of local esophageal epithelium might be the optimal approach to preventing esophageal stricture after wESD.[17]

In this study, 15 patients with wESD underwent esophageal mucosal autograft. The rate of epithelialization in the esophageal wounds was 93.3%. In their recent study that used esophageal mucosal autograft to treat 9 patients with wESD, Liao et al. reported that the esophageal mucosal graft's survival rate was also very high, reaching 96.5%.[4] These results indicate that esophageal mucosal autograft might be a feasible method of promoting local esophageal re-epithelization. However, the esophageal mucosal autograft did not satisfy the purpose of preventing esophageal stricture after wESD. Liao et al[4] reported a relatively high esophageal stricture rate (88.9%) after using esophageal mucosal autograft to prevent stricture after whole circumferential ESD. In our study, the esophageal stricture rate was 62.5% in patients undergoing whole circumferential ESD, which was relatively higher compared with patients undergoing partial circumferential ESD (28.6%). Therefore, some improvements need to be made to enhance the esophageal mucosal autograft's efficacy in preventing esophageal stricture, especially for those patients undergoing whole circumferential ESD.

The limitations above notwithstanding, this approach has a potential role in reducing the number of dilatation sessions needed. In several previous studies in which esophageal mucosal autograft was not used after esophageal wESD, patients regularly underwent several dozens of EBD sessions over a long period.[18] However, in a recent study of 9 patients with early esophageal cancer treated by wESD, a median of 2.7 EBD dilatations (range 0-6) was needed after these patients underwent esophageal mucosal autograft.[4] In this present study, the number of EBDs required in the 7 patients with esophageal stricture ranged between 0 and 8 (median, 2.0 dilatations). Thus, the decrease in the number of dilatation sessions potentially afforded by esophageal mucosal autograft warrants further investigation in a randomized, controlled, multicenter study.

As a new technique for preventing esophageal stricture after wESD, the esophageal mucosal autograft needs further improvement to increase its efficacy in preventing strictures. First, the exact size of the mucosal patch needs to be verified. In their study, Liao et al[4] reported a patch size of ≈3 × 10 mm, whereas the size of each patch in the present study was ≈10 × 10 mm. Thus, the relationship between the size of the mucosal patch and the effect of preventing esophageal stricture should be explored more extensively in future studies. Second, in a recent study using an endoscopic mucosal autograft to treat 3 patients with caustic esophageal strictures, He et al[17] used biological fibrin glue to fix the graft, achieving a satisfactory result. Therefore, whether biological fibrin glue can improve local esophageal re-epithelization also requires verification in future studies. Third, wESD with esophageal mucosal autograft is a time-consuming procedure

that might be associated with a higher risk of complications compared with conventional ESD. Furthermore, attention should also be paid to extraesophageal adverse events rather than those only affecting the esophagus.

Several limitations of this study must be addressed. First, this study had a single-center design, which might have contributed to selection bias. Second, our endoscopic center is the ESD training center of the Chinese Medical Doctors Association, and all procedures were carried out by an experienced clinician, Li-Ping Ye, a tutor at the training center. The results of this study, therefore, may not apply to other endoscopic centers. Thirdly, this study did not investigate the difference between EBD and ERI for treating esophageal stricture, due to the limitation of a small number of patients with esophageal stricture after wESD. Fourthly, in this study, a retrievable, fully covered metal stent was used for fixing the esophageal patches. Although the metal stent was placed for only 8 weeks, the effect of preventing esophageal stricture could not be ignored completely. Finally, other limitations of small sample size and a lack of randomization and control samples also exist.

In conclusion, esophageal mucosal autograft might prove to be an efficient approach to promoting local esophageal re-epithelization, which can form a barrier against digestive juices and prevent esophageal stricture after wESD. However, as a new technique, it must be subjected to further randomized, controlled, and multicenter studies to confirm its safety and efficacy. Moreover, further improvements in the esophageal mucosal autograft must be made to enhance its role in preventing esophageal stricture after wESD.

Ethics Committee Approval: This study was approved by the Ethics Review Committee of Taizhou hospital (No: X20190603).

Informed Consent: Written informed consent was obtained from patients who participated in this study.

Peer Review: Externally peer-reviewed.

Author Contributions: Consept – Y.M.L.; Design – Y.M.L.; Supervision – X.L.M.; Data Collection and/or Processing – X.LM., W.Z., H.H.Z., S.K.Z.; Analysis and/or Interpretation – L.P.Y; Writing Manuscript – Y.Z.

Declaration of Interests: The authors declare that they have no competing interest.

Funding: This study was supported by the Major R&D Project of Zhejiang province (2019C03040) and the project of Taizhou Science and Technology Bureau (1701KY10).

REFERENCES

1. Shi P, Ding X. Progress on the prevention of esophageal stricture after endoscopic submucosal dissection. Gastroenterol Res Pract. 2018;2018:1696849. [CrossRef]

2. Lew RJ, Kochman ML. A review of endoscopic methods of esophageal dilation. J Clin Gastroenterol. 2002;35(2):117-126. [CrossRef]

3. Shi Q, Ju H, Yao LQ, et al. Risk factors for postoperative stricture after endoscopic submucosal dissection for superficial esophageal carcinoma. Endoscopy. 2014;46(8):640-644. [CrossRef]

4. Liao Z, Liao G, Yang X, et al. Transplantation of autologous esophageal mucosa to prevent stricture after circumferential endoscopic submucosal dissection of early esophageal cancer (with video). Gastrointest Endosc. 2018;88(3):543-546. [CrossRef]

5. Hashimoto S, Kobayashi M, Takeuchi M, Sato Y, Narisawa R, Aoyagi Y. The efficacy of endoscopic triamcinolone injection for the prevention of esophageal stricture after endoscopic submucosal dissection. Gastrointest Endosc. 2011;74(6):1389-1393. [CrossRef]

6. Ye LP, Zheng HH, Mao XL, Zhang Y, Zhou XB, Zhu LH. Complete circular endoscopic resection using submucosal tunnel technique combined with esophageal stent placement for circumferential superficial esophageal lesions. Surg Endosc. 2016;30(3):1078-1085. [CrossRef]

7. Ohki T, Yamato M, Ota M, et al. Prevention of esophageal stricture after endoscopic submucosal dissection using tissue-engineered cell sheets. Gastroenterology. 2012;143(3):582-588.e2. [CrossRef]

8. Hochberger J, Koehler P, Wedi E, et al. Transplantation of mucosa from stomach to esophagus to prevent stricture after circumferential endoscopic submucosal dissection of early squamous cell. Gastroenterology. 2014;146(4):906-909. [CrossRef]

9. The Paris endoscopic classification of superficial neoplastic lesions: esophagus, stomach, and colon: November 30 to December 1, 2002. Gastrointest Endosc. 2003;58(suppl 6):S3-S43. [CrossRef]

10. Kitagawa Y, Uno T, Oyama T, et al. Esophageal cancer practice guidelines 2017 edited by the Japan esophageal society: part 2. Esophagus. 2019;16(1):25-43. [CrossRef]

11. Katada C, Muto M, Tanabe S, et al. Surveillance after endoscopic mucosal resection or endoscopic submucosal dissection for esophageal squamous cell carcinoma. Dig Endosc. 2013;25(suppl 1):39-43. [CrossRef]

12. Kitagawa Y, Suzuki T, Hara T, Yamaguchi T. Safety and efficacy of endoscopic submucosal dissection using IT knife Nano with clip traction method for early esophageal squamous cell carcinoma. Surg Endosc. 2018;32(1):450-455. [CrossRef]

13. Kuwai T, Yamaguchi T, Imagawa H, et al. Endoscopic submucosal dissection for early esophageal neoplasms using the stag beetle knife. World J Gastroenterol. 2018;24:1632-1640. [CrossRef]

14. Ishida T, Morita Y, Hoshi N, et al. Disseminated nocardiosis during systemic steroid therapy for the prevention of esophageal stricture after endoscopic submucosal dissection. Dig Endosc. 2015;27(3):388-391. [CrossRef]

15. Zuercher BF, George M, Escher A, et al. Stricture prevention after extended circumferential endoscopic mucosal resection by injecting

autologous keratinocytes in the sheep esophagus. Surg Endosc. 2013;27(3):1022-1028. [CrossRef]
16. Nonaka K, Miyazawa M, Ban S, et al. Different healing process of esophageal large mucosal defects by endoscopic mucosal dissection between with and without steroid injection in an animal model. BMC Gastroenterol. 2013;13:72. [CrossRef]
17. He K, Zhao L, Bu S, et al. Endoscopic mucosal autograft for treating esophageal caustic strictures: preliminary human experience. Endoscopy. 2018;50(10):1017-1021. [CrossRef]
18. Isomoto H, Yamaguchi N, Nakayama T, et al. Management of esophageal stricture after complete circular endoscopic submucosal dissection for superficial esophageal squamous cell carcinoma. BMC Gastroenterol. 2011;11:46. [CrossRef]