THE ANATOLIAN JOURNAL OF CARDIOLOGY

Official journal of the TURKISH SOCIETY OF CARDIOLOGY

High-degree atrioventricular heart block induced by pramipexole

CASE REPORT

INTRODUCTION

Atrioventricular (AV) block may manifest as conduction delay in the AV node, intermittent failure of conduction from the atria to the ventricles, or complete AV block. High degree or complete atrioventricular block often develops in older patients due to degenerative disorders of the communication pathways. In younger individuals, it appears to be due to temporary conduction system suppression such as those owing to drug toxicity or acute myocardial infarction (1). Atrioventricular (AV) block is a common reason for pacemaker implantation, and the number of pacemaker implantations is increasing (2). Pramipexole is a non-ergot dopamine agonist used in Parkinson's disease and restless leg syndromes (3). Although the FDA has reported the risks associated with pramipexole and heart failure, reports related to AV block have recently increased in the literature (4, 5). In this case report, we present a patient who developed AV block induced by pramipexole.

CASE REPORT

A 76-year-old patient, who was being followed up for the diagnoses of diabetes mellitus, hypertension, grade 3 chronic renal failure, hyperlipidemia, and restless leg syndrome, was brought to our policlinic with complaints of palpitation, dyspnea, and dizziness. High degree AV block was detected on the patient's electrocardiogram (ECG) (Fig. 1). His hemodynamics was stable. To exclude causes that lead to

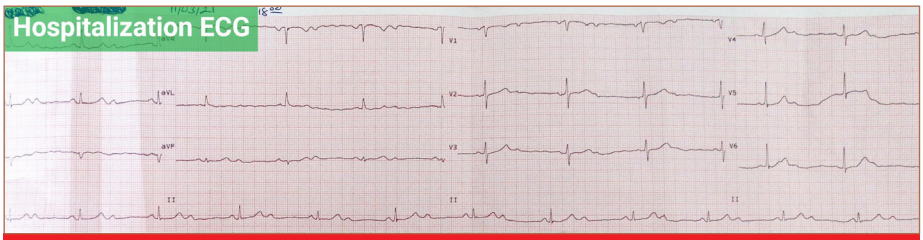

Figure 1. High-grade AV block ECG observed during the patient's admission to our clinic

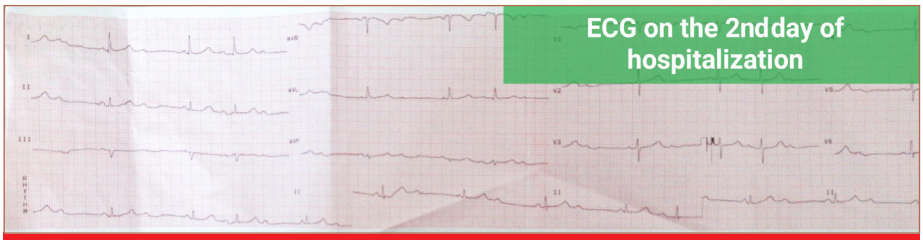

Figure 2. ECG with 2nd degree mobitz type 2 AV block observed on the 2nd day of the patient's admission to our clinic

Copyright@Author(s) - Available online at anatoljcardiol.com.
Content of this journal is licensed under a Creative Commons Attribution-NonCommercial 4.0 International License.

Yücel Kanal
Canan Elif Yıldız
Görkem Ayhan
İdris Yakut[1]
Özcan Özeke[1]

Department of Cardiology, Tokat State Hospital; Tokat-Turkey
[1]Department of Cardiology, Ankara City Hospital; Ankara-Turkey

Corresponding Author:
Yücel Kanal
yucel_kanal@hotmail.com

Cite this article as: Kanal Y, Yıldız CE, Ayhan G, Yakut İ, Özeke Ö. High-degree atrioventricular heart block induced by pramipexole. Anatol J Cardiol 2022; 26: 147-8.

DOI: 10.5152/AnatolJCardiol.2021.274

a temporary high-degree AV block in the patient, the drugs he used were evaluated, and a decision was made to perform coronary angiography. The patient was using metformin 1000 mg 2×1, lercadipine 10 mg 1×1, doxazosin 4 mg 1×1, and pramipexole 0.25 mg 1×1. The patient used additional pramipexole doses when his leg pain did not resolve. Coronary angiography of the patient did not show significant stenosis of the coronary arteries. No significant pathology was observed in the patient's biochemical tests. ECG change was not observed with atropine 1 mg given intravenously. As there were rare reports of transient AV block associated with pramipexole, the dose of pramipexole was gradually discontinued after neurology consultation. The patient was followed up in the cardiology service for 2 weeks. One week after the follow-up, a second-degree AV block was observed in the ECG (Fig. 2, 3). First-degree AV block was observed in the ECG of the patient at the end of 2 weeks (Fig. 4). The patient was discharged. The ECG checked 1 week later showed normal sinus rhythm (Fig. 5).

DISCUSSION

In our country, in addition to the reports of temporary AV block observed after local honey consumption; some drugs used for epilepsy and Parkinson's disease have been observed to cause the development of AV block (1). The adverse effects caused by pramipexole include orthostatic hypotension, worsening of motor and psychiatric symptoms, confusion, and drowsiness. Studies in the literature have shown that pramipexole can also cause heart failure (6). However, there was only one case of AV block owing to pramipexole in the literature review. This was a 68-year-old patient who did not have any pathology in the blood parameters, however, was observed to have pramipexole-induced AV block, which resolved 24 hours after drug withdrawal (4). Our 53-year-old patient, who was previously presented as a poster in a congress, had no pathology found in blood parameters; and the AV block improved 24 hours after drug discontinuation. In our case, the recovery of high-grade AV block took 2 weeks. Age and renal clearance are believed to be the cause of this condition.

CONCLUSION

In patients with complete AV blockade, getting a good anamnesis in terms of the causes of temporary blockade and drug use will prevent unnecessary permanent pacemaker implantation. This case report places emphasis on the importance of close monitoring, early detection, and management of this adverse drug reaction based on the current standard guidelines.

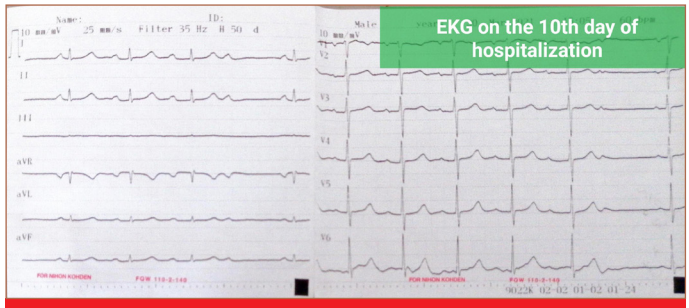

Figure 3. ECG with 2nd degree mobitz type 1 AV block observed on the 10th day of the patient's admission to our clinic

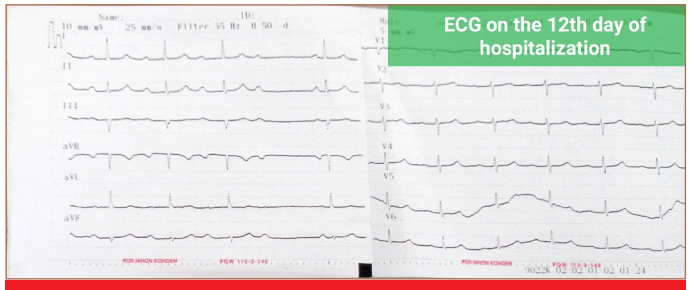

Figure 4. ECG with 1st degree AV block observed on the 12th day of the patient's admission to our clinic

Informed consent: Informed consent was taken from the patient.

REFERENCES

1. Alyan O, Ozdemir O, Soylu M, Demir AD, Topaloğlu S, Kaçmaz F, et al. Classification of patients with complete atrioventricular block according to etiological, demographic and clinical features and pacemaker needs. Anatol J Cardiol 2003; 3: 203-10. [Article in Turkish]
2. Bernstein AD, Parsonnet V. Survey of cardiac pacing and defibrillation in the United States in 1993. Am J Cardiol 1996; 78: 187-96. [Crossref]
3. Aurora RN, Kristo DA, Bista SR, Rowley JA, Zak RS, Casey KR, et al.; American Academy of Sleep Medicine. The treatment of restless legs syndrome and periodic limb movement disorder in adults--an update for 2012: practice parameters with an evidence-based systematic review and meta-analyses: an American Academy of Sleep Medicine Clinical Practice Guideline. Sleep 2012; 35: 1039-62. [Crossref]
4. Cherian S, Tomas P, Sreekrishnan TP, Gireesh KP. Pramipexole Induced Complete Heart Block: A Case Report. Journal of Pharmaceutical Research 2015: 89. [Crossref]
5. Renoux C, Dell'Aniello S, Brophy JM, Suissa S. Dopamine agonist use and the risk of heart failure. Pharmacoepidemiol Drug Saf 2012; 21: 34-41. [Crossref]
6. Mokhles MM, Trifirò G, Dieleman JP, Haag MD, van Soest EM, Verhamme KM, et al. The risk of new onset heart failure associated with dopamine agonist use in Parkinson's disease. Pharmacol Res 2012; 65: 358-64. [Crossref]

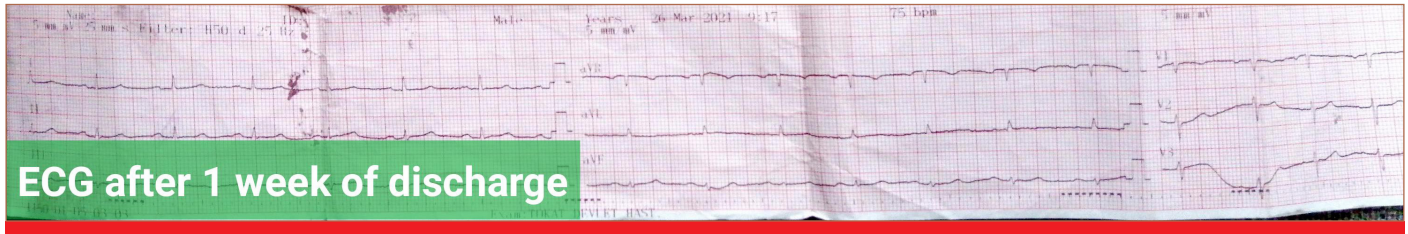

Figure 5. ECG with normal sinus rhythm taken 1 week after the patient's discharge