THE ANATOLIAN JOURNAL OF CARDIOLOGY

Official journal of the TURKISH SOCIETY OF CARDIOLOGY

Asymptomatic Cerebral Emboli Following Carotid Artery Stenting: A Diffusion-Weighted MRI Study

ORIGINAL INVESTIGATION

ABSTRACT

Background: Silent cranial embolism due to carotid artery stenting has been demonstrated to cause dementia, cognitive decline, and even ischemic stroke. The purpose of this study was to compare the periprocedural asymptomatic cranial embolism rates of different stent designs used for extracranial carotid stenosis with diffusion-weighted magnetic resonance imaging.

Methods: A total of 507 consecutive patients who underwent carotid artery stenting at our center from December 2010 to June 2020 (mean age, 66.4 ± 9.5) were analyzed retrospectively. The patients were divided into 3 groups as open-cell stent (334 patients), closed-cell stent (102 patients), and hybrid-cell stent (71 patients) groups. Diffusion-weighted magnetic resonance imaging was performed for the patients before and after carotid artery stenting and compared. The diffusion limitations of 3 stent groups on cranial diffusion-weighted magnetic resonance imaging were compared with one another.

Results: Periprocedural asymptomatic same-side microembolism, which was the primary endpoint of our study, was detected in 58 (17.4%) patients in the open-cell stent group, 6 (5.9%) patients in the closed-cell group, and 8 (11.3%) patients in the hybrid cell group, and overall in 72 (14.2%) patients. On diffusion-weighted magnetic resonance imaging, periprocedural asymptomatic same-side cranial embolism was found to be statistically significantly higher in the open-cell group compared to the other two groups ($P = .011$).

Conclusions: The result of this study showed us that the rate of same-side cranial embolism detected on cranial diffusion-weighted magnetic resonance imaging after carotid artery stenting performed with open-cell stent was higher than those of the carotid artery stenting procedure performed with closed-cell and hybrid-cell stents.

Keywords: Angioplasty, magnetic resonance imaging, stroke

Erkan Köklü[1]
Şakir Arslan[1]
Elif Sarıönder Gencer[2]
Nermin Bayar[1]
Çağın Mustafa Üreyen[1]
Zehra Erkal[1]
Ahmet Genç[1]
Ramazan Güven[3]
Oğuz Kaan Kaya[1]
Muhammed Rıdvan Ersoysal[1]

[1]*Department of Cardiology, University of Health Sciences, Antalya Training and Research Hospital, Antalya, Turkey*
[2]*Department of Neurology, University of Health Sciences, Antalya Training and Research Hospital, Antalya, Turkey*
[3]*Clinic of Emergency Medicine, Başakşehir Çam and Sakura City Hospital, İstanbul, Turkey*

Corresponding author:
Erkan Köklü
✉ drerkankoklu07@gmail.com

Received: September 6, 2021
Accepted: November 25, 2021
Available Online Date: March 30, 2022

Cite this article as: Köklü E, Arslan Ş, Sarıönder Gencer E, et al. Asymptomatic cerebral emboli following carotid artery stenting: A diffusion-weighted MRI study. Anatol J Cardiol 2022;26(4):298-304.

DOI:10.5152/AnatolJCardiol.2021.970

INTRODUCTION

Carotid artery stenting (CAS), which is a less invasive method, is an alternative treatment method to carotid artery endarterectomy (CEA).[1] The most important complications ofcarotid artery stenting include new ischemic cerebral lesions associated with distal embolization and neurological symptoms.[2] In CAS procedures, the use of embolism protection devices (EPD) decreases the incidence of new cranial ischemic lesions caused by the procedure as detected on diffusion-weighted magnetic resonance imaging (DW-MRI).[3] Therefore, cerebral EPD is absolutely recommended to be used during CAS procedures.[4]

New ischemic cerebral lesions due to distal emboli that occur during CAS performed under the guidance of EPD may develop due to several factors. These factors include clinical status of patients, their vasculature, type of aortic arch, devices used (balloon, stent, catheter, etc.), experience of operators, plaque morphology, etc.[5] Therefore, the selection of patients, lesions, and appropriate materials play an important role to decrease the incidence of distal emboli associated with CAS. Periprocedural cranial embolisms associated with CAS are often asymptomatic. It is critical to assess patients who are at high risk of cerebral

Copyright@Author(s) - Available online at anatoljcardiol.com.
Content of this journal is licensed under a Creative Commons Attribution-NonCommercial 4.0 International License.

embolism due to CAS with cranial DW-MRI, which is a sensitive method for the diagnosis of embolism.[6]

Studies on CAS devices investigated different stent designs. Stent designs are categorized according to strut interconnections: larger free cell area with fewer interconnections (open cell) versus smaller free cell area with more interconnections (closed cell). Open-cell stents have a more flexible design, while better plaque coverage can be achieved with closed-cell stents. Hybrid stents merge both designs and theoretically combine the benefits of each in one design. Guidelines, however, do not provide conclusive recommendations.[7] Clinical outcomes, the occurrence of new MR-DWI lesions, or restenosis associated with carotid stent design are still controversial.[8] The purpose of this study was to retrospectively compare the periprocedural asymptomatic cranial embolism rates of different stent designs used to treat symptomatic or asymptomatic extracranial carotid stenosis through DW-MRI.

METHODS

We obtained the approval of the Ethics Board of our facility for this study (no. 2020-183). We included the data of 507 consecutive patients (mean age, 66.4 ± 9.5) who were admitted to our center from December 2010 to June 2020 and for whom CAS was decided after consulting the multidisciplinary carotid committee consisting of neurology, cardiology, cardiovascular surgery, and radiology clinics. Symptomatic patient was defined as having a history of ischemic cerebrovascular disease with or without any sequelae, transient ischemic attack (TIA), and amaurosis fugax within the last 6 months. The evaluation included patients who were symptomatic with more than 50% stenosis in digital subtraction angiography (DSA) according to North American Symptomatic Carotid Endarterectomy Trial (NASCET) formula and those who were asymptomatic with more than 80% stenosis. All patients who had a glomerular filtration rate greater than 60 mL/min/1.73 m^2 underwent computed tomography angiography for the carotid after Doppler ultrasonography. The multidisciplinary team decided on medical follow-up, CAS, or CEA depending on the clinical features, comorbidities, and characteristics of carotid artery lesions of the patients. Table 1 shows the inclusion and exclusion criteria in our study.

Table 1. Inclusion and Exclusion Criteria

Inclusion criteria

- Symptomatic ICA stenosis ≥ 50% on DSA;
- Asymptomatic ICA stenosis ≥80% on DSA;
- The ipsilateral external carotid artery is not totally occluded;
- Patent contralateral ICA;
- A complete circle of Willis (assessed by CTA);
- Filter able to pass through the lesion without the need for predilation (assessed by CTA);
- Presence of adequate landing zone for the filter (4 cm) (assessed by CTA);
- Informed consent form for the procedure signed by patients.

Exclusion criteria

- Patients who are symptomatic after CAS (21 patients);
- Periprocedural haemodynamic instability (>10 minutes) (16 patients);
- Distal ICA spasm (12 patients);
- >30% residual stenosis (11 patients);
- Procedure time >45 minutes (10 patients);
- Diffusion limitation in the watershed area of the collateral carotid artery on cranial DW-MRI after CAS, bilateral diffusion limitation, and watershed diffusion limitation (24 patients);
- Need for repeated pre/postdilation (9 patients);
- Balloon dilation under an atmosphere pressure 20% greater than the nominal balloon pressure (5 patients);
- CEA restenosis, history of radiotherapy, routine use of anticoagulants (34 patients);
- Tip III aortic arch (84 patients);
- Ischemic stroke in the past 48 hours (14 patients);
- Poor image quality of cranial DWMRI, contraindication for DWMRI (pacemaker, claustrophobia) (21 patients.)

CAS, carotid artery stenting; CEA, carotid endarterectomy; CTA, computed tomography angiography; DSA, digital subtraction angiography; ICA, internal carotid artery; DWMRI, diffusion-weighted magnetic resonance imaging.

Preparation of Patients for Carotid Artery Stenting

Patients were informed about the details of CAS and signed informed consent forms. Antihypertensive, antihyperlipidemic, and antiplatelet medications that the patients had been taking were regulated. The procedure was initiated after blood pressure was regulated below 135/80 mm Hg. It was ensured that patients had been receiving dual antiplatelet treatments composed of 100 mg of acetylsalicylic acid (ASA) and 75 mg of clopidogrel for at least 7 days. Otherwise, additional loading (ASA 300 mg and clopidogrel 600 mg) and maintenance antiplatelet treatments were planned. On the morning of the procedure, platelet aggregation test was performed on all patients. Venous blood resistance tests were performed for both antiplatelet agents. We used the PFA-100 test to evaluate platelet aggregation in our patients. Off-label, if there was only resistance to clopidogrel, CAS was performed with a 90-mg loading dose of 2 tablets and a two-by-one maintenance dose of ticagrelor. However, if there was resistance to both antiplatelet agents, CAS was not performed, and CEA was recommended for these patients.

HIGHLIGHTS

- Silent cranial embolism due to carotid artery stenting (CAS) has been demonstrated to cause dementia and even ischemic stroke.
- The rate of same-side cranial embolism detected on cranial diffusion-weighted magnetic resonance imaging after CAS performed with open-cell stent was higher than those of the CAS procedure performed with closed-cell and hybrid-cell stents.

Carotid Artery Stenting Procedure

All procedures were performed by 2 specialists, one an invasive cardiologist and the other an interventional vascular neurologist. They were performed under local anesthesia via percutaneous transfemoral route. Throughout the procedure, oxygen saturation, electrocardiographic, and blood pressure of the patients were monitored. The procedure was initiated using a femoral 8 french (F) sheath. A 9F sheath was used if proximal protection was preferred as an embolism protection method. After inserting the sheath, all patients received 75 IU/kg unfractionated heparin. 5F hydrophilic head hunter or Simson 1,2 diagnostic catheter was preferred according to the type of aortic arch of the patients evaluated by the committee. Carotid artery stenting was performed with the anchor method in most of the patients. The telescopic method was used in only a very few patients. Following bilateral carotid and cererbral DSAs, it was decided as to which embolism protection method to be used, balloon and stent diameters, and whether to perform pre or postdilation. The stent design was not selected due to the lesion or vascular structure. The stent design that was available and actively used was then inserted into the stenotic carotid artery. For predilation, 3.0-5.0 × 20 mm balloons (Invader; Alvimedica, Simpass; Simeks) were used. For postdilation, 5.0-5.5 × 20 mm balloons (Viatrac; Guidant) were preferred. The balloon diameter for predilation was calculated as around 1 mm smaller than the diameter of the distal intact ICA. It was decided not to perform postdilation if the residual stenosis was <30% after stenting. Tapered stents were used for all patients. Self-expandable stent diameter was planned to be 20% larger than the digitally measured diameter of the carotid artery. The stent designs used at our clinic to date are closed-cell stent; XAct carotid stent (Abbott), open-cell stents; Sinnus-carotid-conical RX stent (Optimed), RX Acculink stent (Abbott), protege RX stent; (Ev3), hybrid-cell stent; Cristallo ideale SE stent (Invatec). Proximal blockage system was preferred as EPD (Mo.MA®) if the carotid artery stenosis was symptomatic and >90%, if the collateral carotid artery was not totally occluded, if the cranial collateral circulation is not sufficient, ICAs was tortuous after bulbous, if the lesion was ulcerated, and if the carotid artery was thrombosed. For the other lesions, distal protection method [filter (Emboshield, Filterwire, Spider FX)] was used. An intravenous dose of 1 mg atropine was administered in patients with heart rates <60/min before carotid ballooning, and in other patients if their heart rate went below <60/min after ballooning or stenting. Bilateral cerebral DSA images were taken and compared to pre-CAS images to ensure whether there was post-CAS distal embolization due to the procedure, and patients who did not have coronary artery angiography (CAG) had CAG after CAS.

Post-Carotid Artery Stenting Follow-up

The hemodynamic and clinical parameters of all patients were followed up after the CAS procedure at the coronary intensive care unit for 24 hours. Cranial DW-MRI was performed to observe possible asymptomatic cranial microembolisms in patients 3-7 days before and 12-24 hours after the CAS procedure (Figure 1). Routine cardiac enzyme testing was not performed. Patients were followed up for 24 hours after the procedure by a vascular neurologist for minor and major neurological complications. On discharge, dual antiplatelet and statin therapy was prescribed for all patients [if low-density lipoprotein (LDL) was >70 mg/dL]. Dual antiplatelet therapy was continued for 6-12 months if the patients did not have other specific conditions.

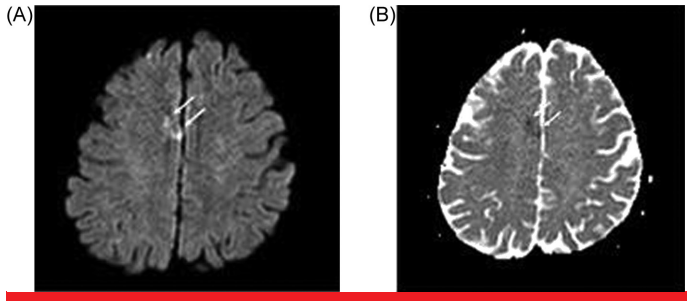

Figure 1. Postinterventional cranial diffusion-weighted magnetic resonance imaging (A) shows an anterior cerebral artery territory with a high signal intensity lesion (arrow). On apparent diffusion coefficient (ADC) map (B), the lesion shows low signal intensity (arrow) indicating its acute nature.

DW-MRI

Cerebral DW-MRI images were obtained using a 1.5 or a 3.0 Tesla Magnetom Sonata (Siemens, Erlangen, Germany). The pre and post-CAS cranial DW-MRI images were analyzed by an independent neurologist (E.S.G). Echo-planar imaging was performed and the following parameters were used: repetition time 3000 ms, echo time 84 ms, 19 slices with a slice thickness of 6 mm, field of view 230 mm, diffusion values b = 0, 500, 1000 s/mm^2, fat-saturation, time of acquisition 71 seconds. Additionally, apparent diffusion coefficient maps were obtained. A new lesion was defined as a focal hyperintense area detected by the fluid-attenuated inversion recovery sequence, corresponding to a restricted diffusion signal in the diffusion-weighted imaging sequence, confirmed by apparent diffusion coefficient mapping to rule out a shine-through artifact.

Statistical Analyses

All statistical analyses (sensitivity, specificity, negative predictive value, and positive predictive value) were performed on MedCalc Statistical Software version v19.4.1 (MedCalc Software, Ostend, Belgium) and Statistical Package for the Social Sciences 25.0 (Armonk, NY: IBM Corp.). Patients' data were expressed as mean ± standard deviation for distributed data and percentage for categorical variables. Shapiro–Wilk test was used for the normally distributed continuous variables. To compare continuous measurements between the groups, one-way analysis of variance (with Bonferroni correction) was used for the normally distributed parameters and Kruskal–Wallis test (with Dunn's posthoc test post hoc analysis) was used for those that were not normally distributed. To analyze the categorical variables, Pearson's chi-square test was used if ≤20% of cells had expected values of <5. Fisher's exact test or Monte Carlo exact test was used if

>20% of cells had expected values of <5. $P < .05$ was considered to be statistically significant.

RESULTS

The baseline and procedural characteristics of all groups were similar (Table 2). The percentage of the patients in the open-cell group who took statins was higher than those of the other groups. The rate of statin use was 93.7% in the open-cell stent group and 90.2% in the closed-cell stent group, while it was 80.3% in the hybrid-cell group. This difference between the groups was statistically significant ($P = .001$). However, there was no statistically significant difference between the LDL levels of the patients.

Periprocedural asymptomatic same-side cranial microembolism was detected in 58 (17.4%) patients in the open-cell group, 6 (5.9%) patients in the closed-cell group, and 8 (11.3%) in the hybrid-cell group, while overall in 72 (14.2%) patients across all groups. On cranial DWI-MRI, periprocedural asymptomatic same-side cranial embolism was detected more in the open-cell group than in the other 2 groups, which was statistically significant ($P = .011$) (Table 3).

DISCUSSION

In this study, periprocedural same-side cranial microembolism rates of different stent designs after the CAS procedure performed for symptomatic or asymptomatic severe carotid artery stenosis were compared retrospectively with cranial DW-MRI findings. The findings of this study demonstrated that open-cell stent design led to a higher rate of periprocedural asymptomatic same-side microembolism compared to the closed-cell and hybrid-cell stent designs.

Despite large-scale randomized trials, the safety of CAS is still controversial.[1,9] Post-CAS stroke and TIA are rare complications observed at high-volume and experienced centers.[10] Symptomatic or asymptomatic periprocedural cranial embolism is one of the most important limitations of CAS.[11,12] Silent cranial embolism due to CAS was demonstrated to cause dementia, cognitive decline,[13] and even ischemic stroke in the subsequent years.[14]

Diffusion-weighted magnetic resonance imaging is a very sensitive method to detect cranial lesions that develop during CAS.[6,15] The rate of silent cranial embolism due to CAS detected on DW-MRI was reported to be up to 70% in some

Table 2. Clinical and Procedural Characteristics of Open-Cell, Closed-Cell, and Hybrid-Cell Groups

Variable	Open-Cell Group (n = 334)	Closed-Cell Group (n = 102)	Hybrid-Cell Group (n = 71)	*P*
Age, years ± SD	66.26 ± 9.7	67.1 ± 9.0	66.3 ± 9.1	.728
Male, n (%)	265 (79.3)	72 (70.6)	52 (73.2)	.141
Hypertension, n (%)	250 (74.9)	72 (70.6)	50 (70.4)	.579
Diabetes mellitus, n (%)	141 (42.2)	40 (39.2)	23 (32.4)	.301
Coronary artery disease, n(%)	242 (73.3)	73 (71.6)	46 (64.8)	.430
Peripheral artery disease, n (%)	14 (4.2)	8 (7.8)	3 (4.2)	.315
Smoking, n (%)	125 (37.4)	34 (33.3)	19 (26.8)	.212
Chronic renal failure, n (%)*	9 (2.7)	3 (2.9)	1 (1.4)	.516
Symptomatic ICA stenosis, n (%)	168 (50.2)	50 (49.0)	36 (50.7)	.786
LDL, mg/dL	106.0 (77.7-136.0)	109.0 (87.5-134.0)	117.0 (89.0-140.0)	.211
Statin, n (%)	313 (93.7)	92 (90.2)	57 (80.3)	.001
Drug Resistance, n (%)**	299 (89.5)	94 (92.2)	65 (91.5)	.170
Absent	7 (2.1)	0.0 (0.0)	0.0 (0.0)	
ASA	28 (7.8)	8 (7.8)	6 (8.5)	
Clopidogrel				
Stent length, n (%)	150 (44.9)	56 (54.9)	31 (43.7)	.178
30 mm	184 (55.1)	46 (45.1)	40 (56.3)	
40 mm				
Filter / MoMA, n (%)	22 (6.6)	4 (3.9)	4 (5.6)	.806
Unprotected	130 (38.9)	38 (37.3)	30 (42.3)	
MOMA	182 (54.5)	60 (58.8)	37 (52.1)	
Filter				
Predilation, n (%)	215 (64.4)	62 (60.8)	52 (73.2)	.227
Plaque, n (%)	132 (39.5)	40 (39.2)	26 (36.6)	.771
Soft	145 (43.4)	48 (47.1)	30 (42.3)	
Mix	29 (8.7)	7 (6.9)	10 (14.1)	
Calcified	28 (8.4)	7 (6.9)	5 (7.0)	
Ulcerated				

*Fisher exact test; **Monte Carlo exact test. ASA, acetylsalicylic acid; DSA, digital subtraction angiography; ICA, internal carotid artery; LDL, low-density lipoprotein; SD, standard deviation.

Table 3. Periprocedural Same-Side Cranial Microembolism Results of All Groups Detected on Cranial DWI-MRI

	Open-Cell Group, n (%)	Closed-Cell Group, n (%)	Hybrid-Cell Group, n (%)	Total, n (%)	*P*
Microemboli absent	276 (82.6)	96 (94.1)	63 (88.7)	435 (85.8)	.011
Microemboli present	58 (17.4)	6 (5.9)	8 (11.3)	72 (14.2)	
Total	334	102	71	507 (100)	

DW-MRI, diffusion-weighted magnetic resonance imaging.

series and[16] 30% of these embolic events are observed in the contralateral hemisphere.[17] Unless an embolism protection method is used (unprotected), the rate of cranial embolism is 45%, which can be reduced to 33% using an embolism protection method.[2,5]

There is a need to find the cause of silent cranial embolism, which is still common and clinically significant in protected CAS procedures, and reduce the prevalence of embolism. A study using DW-MRI showed that age, hypertension, lesion eccentricity, and type III aortic arch caused cerebral ischemic lesion due to the CAS.[5] Xu et al[18] demonstrated in a study they conducted in 2020 that diabetes mellitus, ipsilateral calcified plaque, ulcerated plaque, predilation, and use of open-cell stent were independent risk factors for silent cranial lesions during CAS.[18]

Some variables in CAS may increase the risk of embolism in the brain tissue fed by the stented carotid artery and some others may increase the risk of bilateral cranial embolism. Long-term periprocedural hemodynamic instability may lead to bilateral cranial embolism, especially watershed infarcts. Type III aortic arch, severely atherosclerotic and calcified aortic arch, inappropriate catheter use prolong the procedure time and increase the risk of bilateral embolism.[19] Severely tortuous carotid artery, severe ICA spasm, complex carotid plaques (long, ulcerated, thrombotic plaques), and use of inappropriate antiplatelets increase the risk of embolism on the same side with the stent. In our study, in order to clearly determine the risk of stent designs that cause cranial embolism, we determined several exclusion criteria such as hemodynamic instability during the procedure, difficult and risky aortic arch, severely tortuous carotid arteries, severely ulcerated, thrombosed, and severely calcified circular carotid artery plaques, watershed infarcts, and history of repeated ballooning. The goal was to detect the emboli in the brain fed by the stented artery in a more isolated way and find more significant associations between these emboli and the stent designs. Our study is different from others as statin was initiated for most of the patients before CAS and dual antiplatelet therapy was adjusted according to the antiplatelet resistance test results. Multidisciplinary committee is crucial to select the right patients, right lesions, and right procedure. All CAS procedures decided by the multidisciplinary committee were performed by the same specialists with the same method using similar materials, which is considered to have kept the procedure-associated cranial embolism rate at a very low level (14.2%) and increased the reliability of our results.

The most important step in CAS to decrease cranial embolism is to use an embolism protection device. Most of the studies investigating cranial embolism with DW-MRI used the distal protection method. Contrary to other studies, we used the proximal blockage method for embolism protection in 39% of the study group. Before the proximal blockage system was preferred, intracranial blood circulation was evaluated and balloon intolerance test was performed. Prevention of Cerebral Embolization by Proximal Balloon Occlusion Compared to Filter Protection During Carotid Artery Stenting (PROFI) trial demonstrated that proximal blockage system was more advantageous than the distal protection method to reduce cranial embolism in CAS.[17] If filters are smaller than the diameter of the vessel, distal particle embolization may occur between the vessel wall and filter. If it is larger than the vessel diameter, it may lead to spasm in the distal carotid artery. Filters cannot hold particles that are smaller than the pore sizes. Besides, they may also pour back their content if the technique is not applied properly while retracting the filters. All the above-mentioned factors may lead to diffusion limitation in the brain tissue on the distal side of the stented artery. Such a filter-related risk can be minimized at high-volume and experienced centers.

As the self-expandable carotid stent design is modified, its mechanical features also change.[20] An ideal stent should be able to cross tortuous and hard plaques, have good coverage of plaques, and have fewer embolic and restenosis complications. A self-expandable carotid stent with all these properties has not been developed yet, though. There are sequential aligned annular rings interconnected by bridges in stents. According to the density of the bridges between different rings, nitinol stents can be classified into stents with a closed-cell or an open-cell configuration.[21] Hybrid-cell design is another one that has open-cell design at the proximal and distal ends of the stent and closed-cell design at the middle. All available stent designs have varying degrees of stiffness, radial force, flexibility, adaptability, conformity to the vessel wall, and scaffolding effect to reduce plaque prolapse and embolization.[22] Carotid stents' strut structure and connections between struts influence their rates of periprocedural cerebral embolization rates.[15] Studies demonstrated that closed-cell stents were apparently more advantageous than open-cell stents in plaque coverage and consecutively cerebral embolization, whereas the lack of flexibility in tortuous vessel anatomy is their main disadvantage.[23] No matter which stent design is used, similar results are obtained in 75% of patients

undergoing CAS. The problems observed in the remaining 25% are estimated to be solved through a careful preoperative assessment.[21]

In a study conducted by Park et al[24] in 2013, the rate of new ischemic lesions detected by cranial DW-MRI after CAS performed with open-cell stent design was found to be significantly higher than that in those procedures performed with closed-cell stent design. Observational studies comparing the open-cell and closed-cell stent designs found fewer neurological complications in the closed-cell groups (3.4% vs. 1.3%). As the space between stent struts increases, the risk of late neurologic events also rises. The risk of late neurologic events in those with free cell areas of <2.5 mm^2 and those with free cell areas of >7.5 mm^2 is 1.2% and 3.4%, respectively ($P < .05$).[25] Moreover, the risk of stroke/mortality/TIA within 30 days after CAS with open-cell design was found to be 4 times higher than in closed-cell design (odds ratio, 4.1; 95% CI, 1.4-12; $P = .0136$).[26] In a study conducted by G. De Donato et al[27] on carotid stent designs using optical coherence tomography reported that stent malapposition was higher in closed-cell stents than in both open and hybrid cell designs, while plaque prolapse was higher in open-cell design than in the closed and hybrid cell designs.[27] One of the most common complications of closed-cell stents is vasospasm at the distal side of the carotid artery, leading to slow flow.[28]

The only statistically significant difference between the study groups was that the rate of statin use was higher in the open-cell stent group than in the other groups. We do not think, however, that this difference between the groups had a negative effect on the result of the study as the use of statins does not prevent plaque stabilization and embolic outcomes.

Limitations of Study

Our study had certain limitations. It was a non-randomized, retrospective, single-center study. In this study, 3 different open-cell stents were used, rather than one type, in the open-cell group and the only difference between these stents was the diameter of the space between the struts. Patients who had post-CAS spasm in their carotid arteries were not included in the study. As a result, the negative effect of the closed-cell group that causes vasospasm might be excluded from the assessment and thus the results might be influenced in favor of the closed-cell stent design. Periprocedural > 10 minutes hemodynamic instability was an exclusion criterion in our study. Due to this criterion, hypotension, bradycardia, and cerebral hypoperfusion effect of the closed-cell stent due to the carotid baroreceptor pressure could not be assessed. However, hypotension due to baroreceptor pressure usually leads to bilateral cranial hypoperfusion.

CONCLUSIONS

Open-cell carotid stents used to treat symptomatic or asymptomatic carotid stenosis cause more periprocedural asymptomatic ipsilateral cranial embolism than closed-cell or hybrid cell carotid stents. There is a need for further prospective, multi-center studies with a higher number of patients on this matter.

Ethics Committee Approval: Ethical committee approval was received from the Ethics Committee of Antalya Training and Research Hospital, (Approval No: 2020-183).

Informed Consent: Written informed consent was obtained from all participants who participated in this study.

Peer-Review: Externally peer-reviewed.

Author Contributions: Concept – E.K., Ş.A., E.S.G., N.B., Ç.M.Ü., Z.E., A.G., R.G., O.K.K., M.R.E.; Design – E.K., Ş.A., E.S.G., N.B., Ç.M.Ü., Z.E., A.G., R.G., O.K.K., M.R.E.; Supervision – E.K., Ş.A., E.S.G., N.B., Ç.M.Ü., Z.E., A.G., R.G., O.K.K., M.R.E.; Funding – None; Materials – E.K., Ş.A., E.S.G., N.B., Ç.M.Ü., Z.E., A.G., R.G., O.K.K., M.R.E.; Data Collection and/or Processing – E.K., Ş.A., E.S.G., N.B., Ç.M.Ü., Z.E., A.G., R.G., O.K.K., M.R.E.; Analysis and/or Interpretation – X.X., X.X.; Literature Review – E.K., Ş.A., E.S.G., N.B., Ç.M.Ü., Z.E., A.G., R.G., O.K.K., M.R.E.; Writing – E.K., Ş.A., E.S.G., N.B., Ç.M.Ü., Z.E., A.G., R.G., O.K.K., M.R.E.; Critical Review – E.K., Ş.A., E.S.G., N.B., Ç.M.Ü., Z.E., A.G., R.G., O.K.K., M.R.E.

Acknowledgments: None.

Declaration of Interests: The authors declare that they have no competing interest.

Funding: This study received no funding.

REFERENCES

1. Brott TG, Hobson RW, Howard G, et al. Stenting *versus* endarterectomy for treatment of carotid-artery stenosis. *N Engl J Med*. 2010;363(1):11-23. [CrossRef]
2. Schnaudigel S, Gröschel K, Pilgram SM, Kastrup A. New brain lesions after carotid stenting *versus* carotid endarterectomy: a systematic review of the literature. *Stroke*. 2008;39(6):1911-1919. [CrossRef]
3. Macdonald S, Evans DH, Griffiths PD, et al. Filter-protected *versus* unprotected carotid artery stenting: a randomised trial. *Cerebrovasc Dis*. 2010;29(3):282-289. [CrossRef]
4. Kastrup A, Gröschel K, Krapf H, Brehm BR, Dichgans J, Schulz JB. Early outcome of carotid angioplasty and stenting with and without cerebral protection devices: a systematic review of the literature. *Stroke*. 2003;34(3):813-819. [CrossRef]
5. Bijuklic K, Wandler A, Varnakov Y, Tuebler T, Schofer J. Risk factors for cerebral embolization after carotid artery stenting with embolic protection: a diffusion-weighted magnetic resonance imaging study in 837 consecutive patients. *Circ Cardiovasc Interv*. 2013;6(3):311-316. [CrossRef]
6. Jaeger HJ, Mathias KD, Hauth E, et al. Cerebral ischemia detected with diffusion-weighted MR imaging after stent implantation in the carotid artery. *AJNR Am J Neuroradiol*. 2002;23(2):200-207.
7. Naylor AR, Ricco JB, de Borst GJ, et al. Editor's choice - management of atherosclerotic carotid and vertebral artery disease: 2017 clinical practice guidelines of the European Society for Vascular Surgery (ESVS). *Eur J Vasc Endovasc Surg*. 2018;55(1):3-81. [CrossRef]
8. Stabile E, Giugliano G, Cremonesi A, et al. Impact on outcome of different types of carotid stent: results from the European Registry of Carotid artery stenting. *EuroIntervention*. 2016;12(2):e265-e270. [CrossRef]
9. International Carotid Stenting Study investigators, Ederle J, Dobson J, et al. Carotid artery stenting compared with endarterectomy in patients with symptomatic carotid stenosis (International Carotid stenting Study): an interim analysis of a randomised controlled trial. *Lancet*. 2010;375(9719):985-997. [CrossRef]

10. Arslan S, Köklü E, Yüksel İÖ, et al. Two-year results of carotid artery stenting. *Turk Kardiyol Dern Ars*. 2014;42(5):429-434. [CrossRef]
11. Garami ZF, Bismuth J, Charlton-Ouw KM, Davies MG, Peden EK, Lumsden AB. Feasibility of simultaneous pre- and postfilter transcranial Doppler monitoring during carotid artery stenting. *J Vasc Surg*. 2009;49(2):340-344, 345.e1-345.e2. [CrossRef]
12. Bonati LH, Jongen LM, Haller S, et al. New ischaemic brain lesions on MRI after stenting or endarterectomy for symptomatic carotid stenosis: a substudy of the International Carotid Stenting Study (ICSS). *Lancet Neurol*. 2010;9(4):353-362. [CrossRef]
13. Pendlebury ST, Rothwell PM. Prevalence, incidence, and factors associated with pre-stroke and post-stroke dementia: a systematic review and meta-analysis. *Lancet Neurol*. 2009;8(11):1006-1018. [CrossRef]
14. Gensicke H, van der Worp HB, Nederkoorn PJ, et al. Ischemic brain lesions after carotid artery stenting increase future cerebrovascular risk. *J Am Coll Cardiol*. 2015;65(6):521-529. [CrossRef]
15. Schlüter M, Tübler T, Steffens JC, Mathey DG, Schofer J. Focal ischemia of the brain after neuroprotected carotid artery stenting. *J Am Coll Cardiol*. 2003;42(6):1007-1013. [CrossRef]
16. Bendszus M, Koltzenburg M, Burger R, Warmuth-Metz M, Hofmann E, Solymosi L. Silent embolism in diagnostic cerebral angiography and neurointerventional procedures: a prospective study. *Lancet*. 1999;354(9190):1594-1597. [CrossRef]
17. Bijuklic K, Wandler A, Hazizi F, Schofer J. The PROFI study (Prevention of Cerebral Embolization by Proximal Balloon Occlusion compared to filter protection during carotid artery stenting): a prospective randomized trial. *J Am Coll Cardiol*. 2012;59(15):1383-1389. [CrossRef]
18. Xu X, Feng Y, Bai X, et al. Risk factors for silent new ischemic cerebral lesions following carotid artery stenting. *Neuroradiology*. 2020;62(9):1177-1184. [CrossRef]
19. Kim HJ, Lee HJ, Yang JH, et al. The influence of carotid artery catheterization technique on the incidence of thromboembolism during carotid artery stenting. *AJNR Am J Neuroradiol*. 2010;31(9):1732-1736. [CrossRef]
20. Schillinger M, Minar E. Matching carotid anatomy with carotid stents. *J Cardiovasc Surg (Torino)*. 2008;49(6):723-727.
21. Bosiers M, Deloose K, Verbist J, Peeters P. Carotid artery stenting: which stent for which lesion? *Vascular*. 2005;13(4):205-210. [CrossRef]
22. Müller-Hülsbeck S, Preuss H, Elhöft H. *CAS*: which stent for which lesion. *J Cardiovasc Surg (Torino)*. 2009;50(6):767-772.
23. Hopf-Jensen S, Marques L, Preiß M, Müller-Hülsbeck S. Initial clinical experience with the micromesh Roadsaver carotid artery stent for the treatment of patients with symptomatic carotid artery disease. *J Endovasc Ther*. 2015;22(2):220-225. [CrossRef]
24. Park KY, Kim DI, Kim BM, et al. Incidence of embolism associated with carotid artery stenting: open-cell *versus* closed-cell stents. *J Neurosurg*. 2013;119(3):642-647. [CrossRef]
25. Bosiers M, de Donato G, Deloose K, et al. Does free cell area influence the outcome in carotid artery stenting? *Eur J Vasc Endovasc Surg*. 2007;33(2):135-143. [CrossRef]
26. Hart JP, Peeters P, Verbist J, Deloose K, Bosiers M. Do device characteristics impact outcome in carotid artery stenting? *J Vasc Surg*. 2006;44(4):725-731. [CrossRef]
27. de Donato G, Setacci F, Sirignano P, Galzerano G, Cappelli A, Setacci C. Optical coherence tomography after carotid stenting: rate of stent malapposition, plaque prolapse and fibrous cap rupture according to stent design. *Eur J Vasc Endovasc Surg*. 2013;45(6):579-587. [CrossRef]
28. Tatli E, Tokatli A, Vatan MB, et al. Comparison of closed-cell and hybrid-cell stent designs in carotid artery stenting: clinical and procedural outcomes. *Postepy Kardiol Interwencyjnej*. 2017;13(2):135-141. [CrossRef]