ANATOL J FAMILY MED
The Anatolian Journal of Family Medicine

Case Report

DOI: 10.5505/anatoljfm.2021.88942
Anatol J Family Med 2022;5(1):62–65

Tumor D'emblee Variant of Mycosis Fungoides

Manoj Kumar Nayak,[1] Aditi Dhanta,[1] Naveen Kumar Kansal,[1] Ashok Singh,[2] Prashant Durgapal[2]

[1]Department of Dermatology, All India Institute of Medical Sciences, Rishikesh, India
[2]Department of Pathology, All India Institute of Medical Sciences, Rishikesh, India

ABSTRACT

Mycosis fungoides (MF) is a rare lymphoid malignancy and accounts for about 2% of new cases of non-Hodgkin's lymphoma. MF is known to have extensive clinical variability, usually progressing from patch stage to plaque, nodules, tumors, and generalized erythroderma. In this report, the rare presentation of sudden onset of tumor stage of MF (i.e., MF d'emblee variant) is presented.

Keywords: Cutaneous T-cell lymphoma, mycosis fungoides, immunophenotyping

Please cite this article as: Kumar Nayak M, Dhanta A, Kumar Kansal N, Singh A, Durgapal P. Tumor D'emblee Variant of Mycosis Fungoides. Anatol J Family Med 2022;5(1):62–65.

Address for correspondence: Dr. Naveen Kumar Kansal. Department of Dermatology, All India Institute of Medical Sciences, Rishikesh-249203, India

Phone: +9463963305

E-mail: kansalnaveen@gmail.com

Received Date: 23.04.2021
Accepted Date: 12.10.2021
Published online: 28.04.2022

©Copyright 2022 by Anatolian Journal of Family Medicine - Available online at www.anatoljfm.org

OPEN ACCESS

This work is licensed under a Creative Commons Attribution-NonCommercial 4.0 International License.

INTRODUCTION

Mycosis fungoides (MF) is lymphoid neoplasia of the mid-to-late adult group with extensive clinical variability in presentation.[1] The de novo tumor-onset MF (tumor d'emblee) is one of the atypical and rare clinical presentations in which the patient presents with acute onset of skin tumors. Tumor d'emblee MF is a very aggressive disease with a poor prognosis even with proper treatment. The objective of this report is to present this rare clinical presentation of the sudden onset of the tumor stage of MF (i.e., MF d'emblee variant).

CASE REPORT

A 49-year-old male presented with rapidly progressing multiple infiltrated nodules and tumors of 5 months duration over the scalp, face, trunk, and upper and lower extremities. The patient had complaints of associated itching over the lesions. There was no history of episodes of fever, weight loss, or anorexia. On mucocutaneous examination, a huge number of infiltrated nodules and tumors of varying sizes were present on the scalp, trunk, and upper and lower limbs, with few erosions and pus discharging superficial ulcers. The head and neck area showing infiltrative nodules and tumors are shown in Figure 1. Bilateral cervical, axillary, inguinal, and posterior occipital lymph nodes were enlarged, discrete to matted, varying in size from 2.0 cm × 2.0 cm to 5.0 cm × 4.0 cm, mobile, and firm inconsistency. The infiltrating nodules and tumors originating from diffusely infiltrated skin, anterior surface of the trunk, and upper extremities are shown in Figure 2. Systemic examination was within normal limits. Investigations revealed a total leucocyte count of 4900 cells/mm^3 with 5.3% lymphocytes and lactate dehydrogenase of 600 u/L. The rest of the routine investigations, including hemoglobin, liver, and kidney function tests, blood glucose, glycated hemoglobin, urine examination, venereal disease research laboratory test, and viral serologic markers (including human immunodeficiency virus-1 and -2) were within normal limits. A chest X-ray and ultrasonography of the abdomen and pelvis were also noncontributory. The main differential diagnoses of tumor

d'emblee MF, progressive nodular histiocytosis, and cutaneous Rosai-Dorfman syndrome were considered. Fine needle aspiration cytology (FNAC) of right posterior cervical lymph nodes showed monomorphic atypical lymphoid cells. The atypical cells were scattered mostly singly with a high nucleocytoplasmic ratio, prominent nucleoli, and moderate cytoplasm. FNAC is shown in Figure 3. Biopsies were performed from three cutaneous lesions, two nodules over the left and right arm, respectively, and one from a nodule over the right leg. Pathologic examination revealed a pandermal infiltration by discohesive atypical monomorphic lymphoid cells dispersed in sheets. Lymphocytes were 2–5 times the size of normal mature lymphocytes with oval nuclei, coarse chromatin, irregular to conspicuous nucleoli with scanty cytoplasm in few cells, and brisk mitosis. Cells were dissecting through and separating the dermal collagen. A biopsy sample from a nodule is shown in Figure 4. Immunohistochem-

Figure 1. Head and neck area showing infiltrative nodules and tumors. *One tumor on the scalp is ulcerated with crusting.*

Figure 2. Infiltrating nodules and tumors originating from diffusely infiltrated skin, anterior surface of the trunk, and upper extremities.

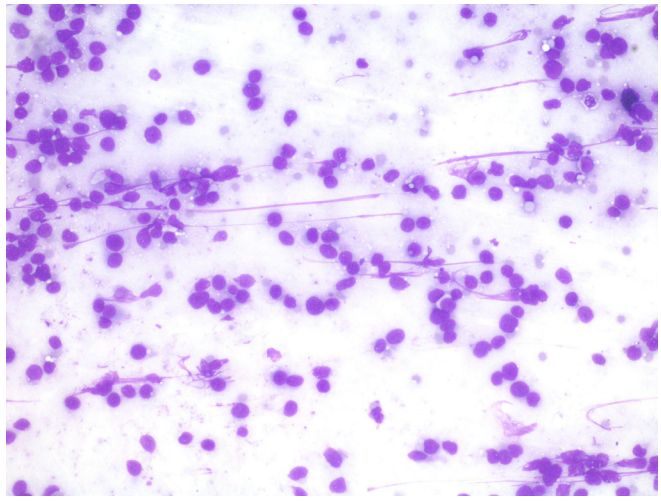

Figure 3. Fine needle aspiration cytology.
Atypical lymphoid cells with high nucleocytoplasmic ratio and prominent nucleoli. (H&E stain; original magnification 100×).

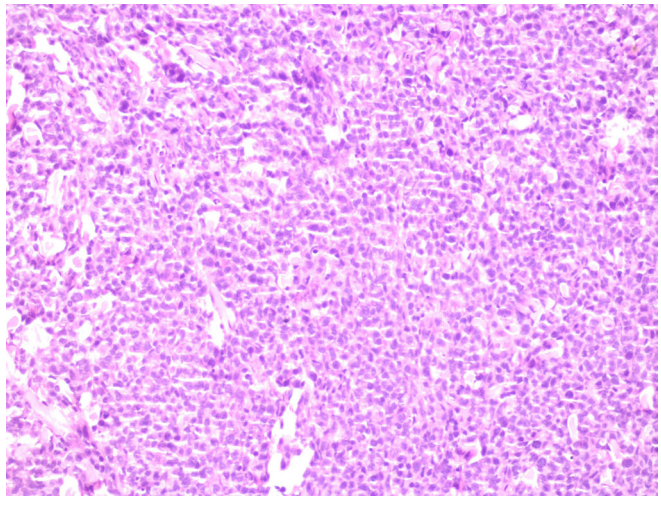

Figure 4. Biopsy sample from a nodule.
Pandermal dense infiltration by atypical monomorphic lymphoid cells. The cells are discohesive, dispersed in sheets, and demonstrate brisk mitosis. (H&E stain; original magnification 40×).

istry showed positive CD3, CD4, and leukocyte common antigen markers. Immunohistochemistry staining of a biopsy sample from a nodule is shown in Figure 5. Occasional scattered background cells were positive for CD20. The cells were negative for CD8 with the loss of CD7. Based on the clinical, FNAC, pathologic findings, and immunophenotyping, a final diagnosis of tumor d'emblee MF (T3N1M0B0 [stage II-B]) was made.

DISCUSSION

MF is considered an uncommon lymphoma, accounting for about 2% of new cases of non-Hodgkin's lymphoma.[1–3] However, it is still the commonest primary cutaneous T-cell lymphoma (CTCL) and can be distinguished from other CTCLs by its unique clinicopathologic features.[3] MF is known to have extensive clinical variability, usually progressing from patch stage to plaque, nodules, tumors, and rarely generalized erythroderma.[4] Tumor d'emblee variant of MF, first reported by Vidal and Brocq in 1885, represents the de novo stage of nodules/tumors arising directly without a preceding patch or plaque stage.[5] Tumors as an initial presentation of MF may be seen in up to 10% of the cases.[4] However, it is important to consider that MF is itself an uncommon disease (incidence of MF in the USA is about 0.36–0.46 per 100000 per year), indicating that tumor d'emblee MF itself is quite rare.[2] According to some workers, tumor d'emblee MF is a controversial entity, and this presentation may be classified as a peripheral T-cell lymphoma.[6] However, most authorities consider that a final diagnosis of these disorders should only be considered after excluding MF by clinical history.[1]

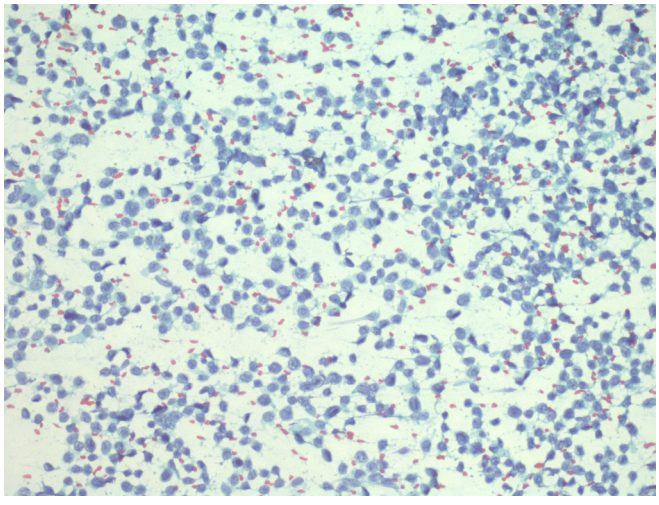

Figure 5. Immunohistochemistry staining of a biopsy sample. *Lymphoid cells positive for the CD4 marker. (Original magnification 100×).*

Usually, the time interval between the origin of cutaneous lesions and definitive diagnosis in MF may be up to even decade(s), but in patients with tumor d'emblee MF, it may only be a few months.[7] In our index case, the clinical history of cutaneous lesions was only about 5 months. Tumor d'emblee MF is considered a very aggressive disease with a poor prognosis.[7,8] Unfortunately, after the diagnosis, our patient was lost to follow up. Later, on contact tracing, it was found that the patient died of the disease 3 months after the diagnosis.

The management of tumor d'emblee MF presents a difficult therapeutic challenge.[9] Multiple treatment modalities are known for the treatment of MF, but the options are limited for the tumor stage. Interferon-α, retinoids, denileukin diftitox, histone deacetylase inhibitors (vorinostat, romidepsin), and the CHOP (cyclophosphamide, doxorubicin, vincristine, and prednisone) regimen alone or in combination have been used. Newer drugs and therapies (e.g., pentostatin, gemcitabine, pegylated liposomal doxorubicin, and allogenic hematopoietic stem cell transplantation) have also been used.

CONCLUSION

This case illustrates the acute camouflaged presentation of MF astutely and recapitulates the known fact that CTCLs may present a significant diagnostic challenge. Besides, recognition of this type of clinical presentation is vital in primary care because of the prime significance and requirement of prompt referral. This is likely to improve the prognosis of these patients as well.

Disclosures

Informed Consent: The authors certify that they have obtained all appropriate patient consent. The patient's kin has given consent for the patient's images and other clinical information reported in the journal. The patient's kin understands that the names and initials will not be published and due efforts will be made to conceal their identity.

Conflict of Interest: The authors declare no conflicts of interest.

Funding: The authors received no financial support for the research, authorship, and/or publication of this article.

Peer-review: Externally peer-reviewed.

Financial Disclosure: No funding was received for this research.

Authorship contributions: Concept – M.K.N., A.D., N.K.K., A.S.; Design – A.D., N.K.K., A.S., P.D.; Supervision – N.K.K.; Materials – M.K.N., N.K.K., A.S.; Data collection and/or processing – M.K.N., N.K.K., A.S., P.D.; Analysis and/or interpretation – A.D., N.K.K., A.S., P.D.; Literature search – A.D., N.K.K., A.S.; Writing – M.K.N., N.K.K., P.D.; Critical review – M.K.N., N.K.K., A.S.

REFERENCES

1. Morgan EA, Murphy GF. Cutaneous lymphomas and leukemias. In: Elder DE, Elenitsas R, Rosenbach M, Murphy GF, Rubin AI, Xu X, editors. Lever's histopathology of the skin. 11th ed. Philadelphia, PA: Wolters Kluwer; 2015.
2. Reddy K, Bhawan J. Histologic mimickers of mycosis fungoides: a review. J Cutan Pathol 2007;34:519–25.
3. Hoppe RT, Advani R, Kim YH. Mycosis fungoides. In: Hoppe RT, Phillips TL, Roach M, eds. Leibel and Phillips' textbook of radiation oncology. 3rd ed. Philadelphia, PA: Elsevier Saunders; 2010. p. 1380–93.
4. Jawed SI, Myskowski PL, Horwitz S, Moskowitz A, Querfeld C. Primary cutaneous T-cell lymphoma (mycosis fungoides and Sézary syndrome): part I. Diagnosis: clinical and histopathologic features and new molecular and biologic markers. J Am Acad Dermatol 2014;70(2):205.e1–16; quiz 221–2.
5. Vidal E, Brocq L. Etude sur le mycosis fungoide. Fr Med 1885;2:946–1085.
6. O'quinn RP, Zic JA, Boyd AS. Mycosis fungoides d'embleé: CD30-negative cutaneous large T-cell lymphoma. J Am Acad Dermatol 2000;43:861–3.
7. Bagot M, Stadler R. Cutaneous lymphoma. In: Kang S, Amagai M, Bruckner AL, Enk AH, Margolis DJ, McMichael AJ, Orringer JS, editors. Fitzpatrick's dermatology. 9th ed. New York: McGraw-Hill; 2019. p. 2072–107.
8. Chokoeva AA, Tchernev G. Mycosis fungoides: The multicentric tumor d'emblee. Mayo Clin Proc 2015;90:1746–47.
9. Jawed SI, Myskowski PL, Horwitz S, Moskowitz A, Querfeld C. Primary cutaneous T-cell lymphoma (mycosis fungoides and Sézary syndrome): part II. Prognosis, management, and future directions. J Am Acad Dermatol 2014;70:223.e1–17.