Turk Neurosurg 30(6):787-792, 2020

Original Investigation

DOI: 10.5137/1019-5149.JTN.23064-18.1

Received: 27.02.2018
Accepted: 09.04.2018

Published Online: 20.04.2018

Systematic Evaluation of Desmopressin Administered to Patients with Aneurysmal Subarachnoid Hemorrhage in the Light of the Literature

Numan KARAARSLAN[1], Ibrahim YILMAZ[2], Feride Sinem AKGUN[3], Tezcan CALISKAN[1], Hanefi OZBEK[2], Ozkan ATES[4]

[1]Namık Kemal University, Scholl of Medicine, Department of Neurosurgery, Tekirdağ, Turkey
[2]Istanbul Medipol University, School of Medicine, Department of Medical Pharmacology, Istanbul, Turkey
[3]Istanbul Maltepe University, School of Medicine, Department of Emergency Medicine, Istanbul, Turkey
[4]Istanbul Esenyurt University, Esencan Hospital, Neurosurgery Clinic , Istanbul, Turkey

Corresponding author: Numan KARAARSLAN ✉ numikara@yahoo.com

ABSTRACT

AIM: To discuss the management of patients with the syndrome of inappropriate antidiuretic hormone secretion (SIADH) developing after subarachnoid hemorrhage, in a comparative manner in the light of the literature.

MATERIAL and METHODS: Without country or language restrictions, articles with high evidential value found in electronic databases were compared to our patients' data.

RESULTS: After the literature review, three articles were included for systematic evaluation. Desmopressin was administered to the patients for the treatment of hyponatremia, volume contraction, and negative sodium balance caused by SIADH. However, it was not used for preventing re-bleeding.

CONCLUSION: To prevent the development of this complication (SIADH), the use of desmopressin, an analogue of vasopressin, is important in routine clinical practice.

KEYWORDS: Desmopressin, Sodium, Subarachnoid hemorrhage, Syndrome of inappropriate antidiuretic hormone secretion, Urine osmolality

INTRODUCTION

Spontaneous subarachnoid hemorrhage (SAH), which is a major cause of morbidity and mortality in the middle and advanced age groups, is a pathologic condition in which the blood extravasates into the subarachnoid space. The primary goal of the surgery performed for the treatment of aneurysmal SAH is to safely occlude the entire aneurysm sac without leaving any residue. In such cases, it is not sufficient to occlude only the aneurysmal sac; complications such as recurrent hemorrhage due to SAH, vasospasm, parenchymal hematoma, the syndrome of inappropriate antidiuretic hormon secretion (SIADH), intraventricular hemorrhage, hydrocephalus, and intracranial pressure increase should be treated carefully (6,14,16,19).

SAH is a pathology with high mortality and morbidity, which is encountered in neurosurgery and emergency departments. Management of affected patients at the moment of admission to the hospital, during surgical treatment, and to prevent postoperative complications is of great importance. SIADH is one of the major complications occurring after SAH, and its diagnosis and treatment may significantly reduce patient mortality and morbidity.

Numan KARAARSLAN : 0000-0001-5590-0637
Ibrahim YILMAZ : 0000-0003-2003-6337
Feride Sinem AKGUN : 0000-0001-6537-866X
Tezcan CALISKAN : 0000-0001-7735-0584
Hanefi OZBEK : 0000-0002-8084-7855
Ozkan ATES : 0000-0002-2985-518X

In the treatment of aneurysmal SAH, what is administered to the patients admitted to the emergency department by the emergency physician prior to the intervention by the consultant neurosurgeon is as important as the surgical intervention. According to the Anatomical Therapeutic Chemical Classification System, desmopressin, which is a synthetic analogue of the antidiuretic hormone vasopressin that affects the posterior lobe of the pituitary gland, is used in the treatment of primary nocturnal enuresis and central diabetes insipidus (2,22).

This pharmaceutical agent reduces urine flow, increases urine osmolality, and decreases plasma osmolality. As a result, the frequency of urination and nocturia are decreased. Desmopressin may thus be administered to patients with aneurysmal SAH to ensure both preoperative and postoperative management of the fluid and electrolyte balance (3,27).

This study was performed to systematically evaluate, in the light of the literature, a patient with aneurysmal SAH who received both preoperative and postoperative desmopressin and underwent surgery in 2011.

CASE REPORT

In 2011, a 59-year-old male patient was referred to the emergency department with a speech disorder and loss of strength in the left hand and left leg. Except for chronic headache complaints, the patient had no history of disease or co-morbidities such as diabetes mellitus or hypertension and no history of alcohol consumption. However, the patient presented with a history of smoking (1.5 packs/day for 44 years). The patient's body mass index was 22.1 kg/m^2, and the laboratory tests revealed no hematological malignancies.

The neurological examination at the time of the patient's admission to the hospital revealed that he responded to simple commands, his eyes were spontaneously open, and he was cooperative, disoriented, and dysphasic. His Glasgow Coma Scale (GCS) score was 12. A muscle strength examination revealed left hemiparesis (the muscle strength was grade 2/5). An eye examination confirmed the presence of papilledema, while the electrocardiographic findings were within normal limits. Cranial computed tomography (CT) revealed a right temporal intracerebral hematoma and extensive SAH (Figure 1).

At the time of admission to the hospital, the patient's World Federation of Neurosurgical Societies Grading scale (WFNS) grade for SAH was 3 and his Fisher grade was 4. At the end of the three-hour follow-up period, the GCS score declined (GCS=5), and the control cranial CT revealed an increase in the intracerebral hematoma size (Figure 2). The patient then immediately underwent surgery.

During surgery, the right temporal inferior cerebral hematoma was removed through a right pterional craniotomy, the right middle cerebral artery aneurysm was clipped, and the bone flap was replaced (Figure 3).

On postoperative day 1, the thyroid-stimulating hormone level of the patient, who was in the intensive care unit, was 0.185 U/mL; the free tyrosine level was 1.17 ng/dL and the free triiodothyronine level was 1.48 pg/dL. In the follow-up control, these levels were 1.36, 0.98, and 3.34, respectively, while the anti-thyroid peroxidase (anti-TPO) value was 9.

On postoperative day 4, nimodipine (180 mg/day) treatment was started due to the detection of clinical vasospasm, and laboratory tests were performed due to the observation of a volume deficit during the follow-up period. The patient's negative fluid deficit was defined as 1505 cc per day, and his hourly urine output varied between 150 cc and 600 cc.

After the laboratory tests, the following results were obtained: blood sodium level: 125 mmol/L; potassium: 4.50 mmol/L; urea: 33 mg/dL; creatinine: 0.62 mg/dL; uric acid: 0.70 mg/dL. The patient's urine density increased from 1015 to 1023. Serum osmolality was less than 280 mmol/kg, urine sodium was 30 mEg/L, and urine osmolality was higher than plasma osmolality. After the patient was diagnosed with SIADH, a daily desmopressin dose of 4 mcg/mL was administered through a systemic route. Treatment then continued with the application of 10 mcg/0.1 mL nasal spray (4x1 puff/day) for four days. After the treatment, the following results were obtained: control blood sodium: 134 mmol/L; potassium: 3.9 mmol/L; urea: 23 mg/dL; creatinine: 0.59 mg/dL; uric acid: 1.30 mg/dL; urine density: 1014.

The patient was discharged on the 50th day of the follow-up and treatment period. At the time of discharge, the patient obeyed simple commands, his eyes were spontaneously open, and he was conscious, cooperative, and disoriented. His GCS score was 13–14. A muscle strength examination again revealed left hemiparesis (the muscle strength was grade 2/5). Follow-up and treatment of the patient is continuing.

Search Strategy

The Cochrane Collaboration, Cochrane Library, Ovid MEDLINE, ProQuest, National Library of Medicine, and PubMed electronic databases were searched for studies conducted between July 1926 and February 2018 using the terms "OR" and "AND" without language and country restrictions. The following keywords were used: "Subarachnoid hemorrhage" (OR "Subarachnoid hemorrhage"), "Aneurysmal subarachnoid hemorrhage," "Neurosurgery," "Emergency medicine," and "Desmopressin."

The percentage distribution of articles by year was recorded, and the study of Lijmer et al. was used to determine the level of evidence of the studies (15,24). Subsequently, the obtained data were checked considering the Transparent Reporting of the Systematic Review (PRISMA) (15,24). All bibliographies thought to have been missed during the database search were reviewed again. Unpublished gray literature, including articles, comments, letters, editorials, protocols, guides, meta-analyses, and collections, were not included. The most highly cited articles were identified and re-examined to avoid possible repetitions (1,13,25).

Data Collection and Evaluation

Data on the operated patient were obtained from the electronic patient program and archive file. The data obtained from this case were compared with the data obtained from the literature review (performed as mentioned in Section 2.2.1).

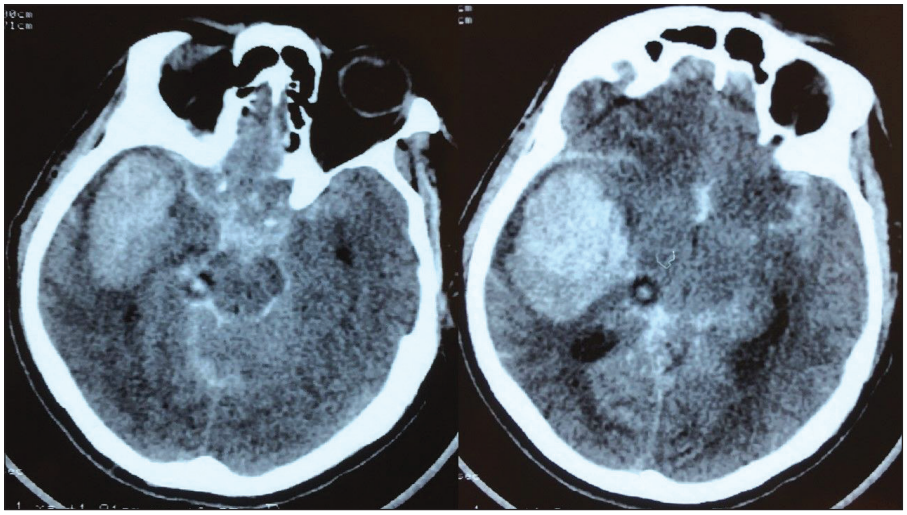

Figure 1: The patient's pre-operative, unenhanced axial cranial CT images at admission to the hospital.

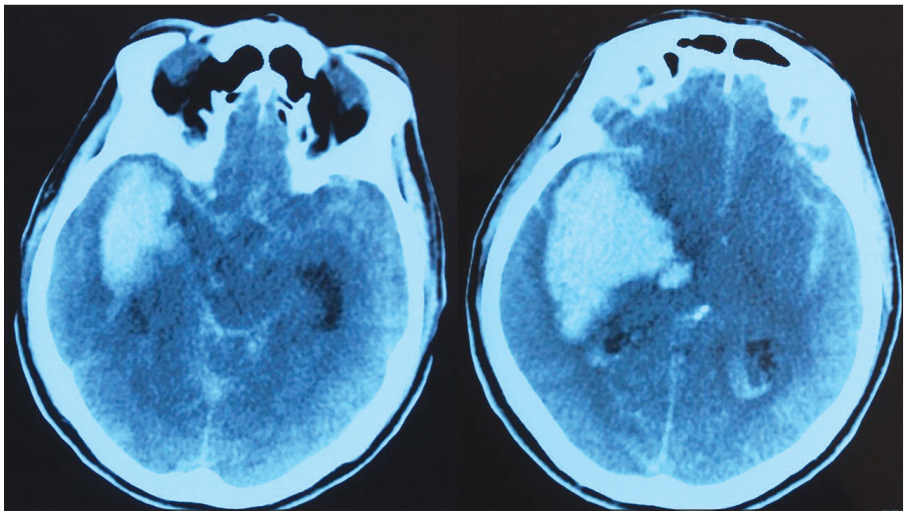

Figure 2: The patient's control, pre-operative, unenhanced axial cranial CT images during the follow-up period.

The authors selected the included studies independently. To minimize the risk of selection bias, the studies were also reviewed by all authors. In the event of conflicting results, the final decision was made by FSA, TC, IY, and NK, who had the most experience about the subject. Finally, the senior authors (HO and OA) were consulted, and the topics were revised if necessary. We compared this research with the findings related to our patient.

Statistical Analysis

Non-pragmatic statistical methods were used. However, given the lack of common findings, statistical analyses could not be performed, and so descriptive statistical methods (such as frequency or mean ± standard deviation) were applied. Microsoft Office Excel (2013) was used.

RESULTS

After the literature review, the full texts of four articles were examined (7-9,12). The article of the Frontera et al. was then excluded from the study (Table I) (9).

DISCUSSION

One of the most important factors affecting the mortality and morbidity of patients with aneurysmal SAH is cerebrovascular spasm resulting from aneurysm rupture (23). Cerebral arterial vasospasm may be focal, segmental, diffuse, symptomatic, or asymptomatic. Laboratory findings of vasospasm may include hyponatremia (5), leukocytosis (11), electrocardiographic changes (10), and hyponatremia and volume deficit, all of which are associated with poor prognosis (5,18). Hyponatremia develops in 10–34% of the cases after SAH (19). In such patients, osmotic diuresis, which decreases blood volume, develops along with increased natriuresis (4,17,18).

Hyponatremia observed in cases with SAH is thought to be a form of SIADH caused by hypothalamic dysfunction. Unlike SIDAH, hyponatremia is associated with volume contraction and a negative sodium balance after SAH. In cases with SIADH, serum sodium is above 135 mEq/L, serum osmolality is below 280 mmol/kg, urine sodium is above 25 mEq/L, and urinary osmolality is higher than plasma osmolality (20). Hyponatremia, which increases the risk of cerebral vasospasm

in patients with SAH, is an important cause of morbidity and mortality. Therefore, it is crucial to monitor the daily serum sodium levels in patients with SAH (4,21,26).

This systematic review was performed to evaluate systematically, in the light of the literature, a patient undergoing surgery due to aneurysmal SAH, who received both preoperative and postoperative desmopressin. After the literature review, the full text of four articles were examined (7-9,12). The article of Frontera et al.(9) was then excluded from the scope of study.

Francoeur et al.(8) reported that re-bleeding after SAH was associated with a decrease in blood platelet function. In their study, they emphasized that recent guidelines recommend the use of desmopressin, a well-known hemostatic agent, for individuals exposed to antiplatelet drugs. The authors carried out a cohort study of patients diagnosed with SAH who were admitted to Columbia University between August 1996 and July 2015. They tested the hypothesis that the administration of desmopressin to patients admitted to the emergency department with a diagnosis of SAH was likely to result in lower re-bleeding rates. The authors compared the re-bleeding rates of patients who were treated with desmopressin with those of patients who were not. They reported that of 1639 patients with SAH, 12% were treated with desmopressin, and only 1% of those patients had recurrent bleeding; meanwhile, 8% of the patients not treated with desmopressin experienced

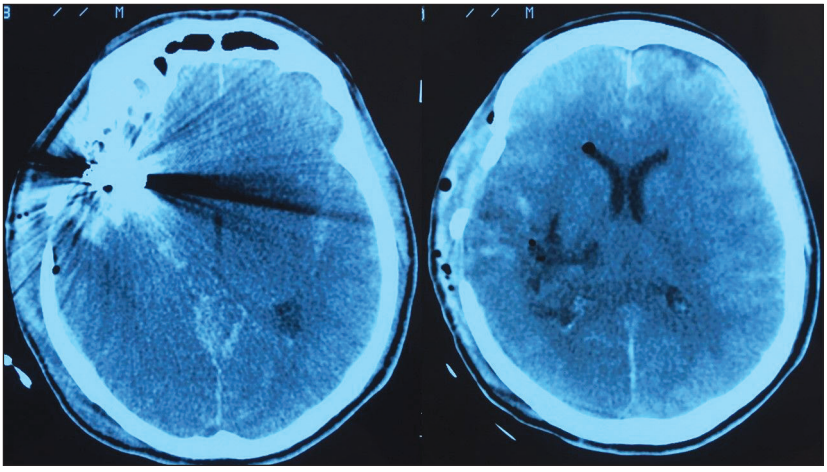

Figure 3: Postoperative, unenhanced axial cranial CT images.

Table I: The Frequency of the Studies by Years

Keywords	Total	Clinical trial	Review	Date range	
Subarachnoid hemorrhage	27.964	942	3.345	2018 Feb 1	1926 Jul
Subarachnoid hemorrhage + Neurosurgery	10.718	451	1253	2018 Feb 1	1952 Dec
Subarachnoid hemorrhage + Emergency medicine	603	17	91	2018 Feb 2	1975 Oct 1
Aneurysmal subarachnoid hemorrhage	26.908	916	3.164	2018 Feb 1	1945
Aneurysmal subarachnoid hemorrhage + Neurosurgery	10.421	445	1.213	2018 Feb 1	1952 Dec
Aneurysmal subarachnoid hemorrhage + Emergency medicine	582	17	90	2018 Feb 2	1975 Oct 1
Desmopressin	5.300	502	936	2018 Feb 2	1950 Nov
Subarachnoid hemorrhage + Desmopressin	15	0	2	2018 Feb 2	1982 Sep
Aneurysmal subarachnoid hemorrhage + Desmopressin	14	0	2	2018 Feb 2	1982 Sep
Aneurysmal subarachnoid hemorrhage + Neurosurgery + Desmopressin	5	0	1	2018 Feb 2	1982 Sep
Aneurysmal subarachnoid hemorrhage + Emergency medicine + Desmopressin	2	0	1	2018 Feb 2	2016 Feb

re-bleeding. The authors concluded that desmopressin was related to the higher incidence of hyponatremia but not with thrombotic events or delayed cerebral ischemia. They also indicated that treatment with desmopressin was associated with a lower risk of re-bleeding in patients with SAH (8).

In our case, the patient's negative fluid deficit was defined as 1505 cc per day, and his hourly urine output varied between 150 cc and 600 cc. When the laboratory tests were examined, the blood sodium level was 125 mmol/L, the serum osmolality was below 280 mmol/kg, the urine density was 1023, the urine sodium was 30 mEg/L, and the urine osmolality was higher than the plasma osmolality. Subsequently, desmopressin was used for the treatment of hyponatremia, volume contraction, and the negative sodium balance caused by SIADH. However, it was not used for preventing re-bleeding.

Jovanovic et al. evaluated the risk of developing hypopituarism due to growth hormone (GH) and corticotrophin deficiencies in patients who survived more than one year after SAH (12). In this study, 30 male and 63 female patients with a mean age of 48 years were evaluated by the authors. The Glasgow Outcome Scale scores of the patients ranged from 4.0 to 5.2. The authors reported that in the acute phase, SAH was complicated by vasospasm in eighteen patients and by hydrocephalus in nine patients. They indicated that there were no hormonal abnormalities in 47 patients, according to baseline hormonal evaluation. Multiple pituitary hormone deficiencies were reported in seven patients (7.5%): four patients (4.3%) had two deficiencies (GH and cortisol), one patient had three (gonadal, adrenal and GH), and two patients had deficiencies of all pituitary axes. Thirty-nine patients (42%) had one abnormal axis, two of whom had a thyroid abnormality. None of the patients treated with desmopressin exhibited symptomatic polyuria. Thus, the authors argued that cerebral vasospasm and hydrocephalus were associated with the abnormal pituitary status. They also concluded that IGF-1 and cortisol values should be controlled strictly in cases with SAH in the emergency or neurosurgery department (12).

In our case, the patient's preoperative GSC score was 7, and cerebral vasospasm was observed on postoperative day 4. The patient is still alive, with a GCS of 13/14. The patient's preoperative and postoperative growth hormones and cortisol levels could not be tested since the hospital to which the patient was admitted was a small state hospital. However, the following results were obtained on postoperative day 1: TSH: 0.185 uIU/mL; FT4: 1.17 ng/dL; FT3: 1.48 pg/dL. In the postoperative follow-up, the following results were observed: TSH: 1.36; Free T4: 0.98; Free T3: 3.34; Anti TPO value: 9.

Dóczi et al., in research carried out on live mammals, found that intraventricular administration of vasopressin or desmopressin acetate increased the water content of the animals' brains from 79.2–79.5% to 79.2–79.5%, and this was achieved without an accompanying water load (7). They also reported that there was no significant difference in the water content of the brains of animals treated with intraventricular vasopressin and an intravenous water load and those of animals treated only with intraventricular vasopressin. As a result of this research, the authors suggested that although no vasopressin tissue or cerebrospinal fluid concentration that could be compared with clinical pathological conditions was measured, the increased release of vasopressin into the cerebrospinal fluid in conditions such as SAH or intracranial hypertension of various origins might play a role in the formation of edema (7).

CONCLUSION

From the moment the patient is admitted to the emergency department with a diagnosis of SAH, one must be careful to reduce the mortality and morbidity that can arise due to the possible development of SIADH within the treatment protocol. The importance of desmopressin administration for the prevention of such complications should not be overlooked by branch physicians. It is important to raise awareness about this issue.

REFERENCES

1. Akgun FS, Karaarslan N, Yilmaz I, Ozbek H, Caliskan T, Ates O: Systematic evaluation of adverse reactions that may occur after injection of type-A botulinum toxin in patients with spasmodic torticollis admitted to emergency department. Merit Res J Med Med Sci 6: 68-72, 2018
2. Boldt C, Röschel T, Himmerkus N, Plain A, Bleich M, Labes R, Blum M, Krause H, Magheli A, Giesecke T, Mutig K, Rothe M, Weldon SM, Dragun D, Schunck WH, Bachmann S, Paliege A: Vasopressin lowers renal epoxyeicosatrienoic acid levels by activating soluble epoxide hydrolase. Am J Physiol Renal Physiol 311: 1198-1210, 2016
3. Chen SL, Huang YH, Hung TW, Ou YC: Comparison of nocturia response to desmopressin treatment in elderly men with and without nocturnal polyuria in real-life practice. Int J Clin Pract 70: 372-379, 2016
4. Cort JH: Cerebral salt wasting. Lancet 10: 752-754, 1954
5. Crowley RW, Dumont AS: Hyponatremia and cerebral vasospasm following subarachnoid hemorrhage. Neurol India 54: 247, 248, 2016
6. Diringer MN, Zazulia AR: Aneurysmal subarachnoid hemorrhage: Strategies for preventing vasospasm in the intensive care unit. Semin Respir Crit Care Med 38: 760-767, 2017
7. Dóczi T, Szerdahelyi P, Gulya K, Kiss J: Brain water accumulation after the central administration of vasopressin. Neurosurgery 11: 402-407, 1982
8. Francoeur CL, Roh D, Schmidt JM, Mayer SA, Falo MC, Agarwal S, Connolly ES, Claassen J, Elkind MSV, Park S: Desmopressin administration and rebleeding in subarachnoid hemorrhage: Analysis of an observational prospective database. J Neurosurg 2018 (Epub Ahead of Print)
9. Frontera JA, Lewin JJ 3rd, Rabinstein AA, Aisiku IP, Alexandrov AW, Cook AM, del Zoppo GJ, Kumar MA, Peerschke EI, Stiefel MF, Teitelbaum JS, Wartenberg KE, Zerfoss CL: Guideline for reversal of antithrombotics in intracranial hemorrhage: A statement for healthcare professionals from the Neurocritical Care Society and Society of Critical Care Medicine. Neurocrit Care 24: 6-46, 2016

10. Ibrahim GM, Macdonald RL: Electrocardiographic changes predict angiographic vasospasm after aneurysmal subarachnoid hemorrhage. Stroke 43: 2102-2107, 2012
11. Inagawa T: Risk factors for cerebral vasospasm following aneurysmal subarachnoid hemorrhage: A review of the literature. World Neurosurg 85: 56-76, 2016
12. Jovanovic V, Pekic S, Stojanovic M, Tasic G, Djurovic B, Soldatovic I, Doknic M, Miljic D, Djurovic M, Medic-Stojanoska M, Popovic V: Neuroendocrine dysfunction in patients recovering from subarachnoid hemorrhage. Hormones (Athens) 9: 235-244, 2010
13. Karaarslan N, Kaya YE, Yılmaz I, Ozbek H, Ekiz BB, Şirin DY, Akyuva Y, Gurbuz MS, Oznam K, Akkaya S, Mutlu CA, Guler O, Ates O, Mahiroğulları M: Will it be possible to prevent lumbar degenerative disc diseases in the future by means of vitamin D receptor gene manipulation? Merit Res J Med Med Sci 5: 500-510, 2017
14. Kivelev J, Tanikawa R, Noda K, Hernesniemi J, Niemelä M, Takizawa K, Tsuboi T, Ohta N, Miyata S, Oda J, Tokuda S, Kamiyama H: Open surgery for recurrent intracranial aneurysms: Techniques and long-term outcomes. World Neurosurg 96: 1-9, 2016
15. Lijmer JG, Mol BW, Heisterkamp S, Bonsel GJ, Prins MH, van der Meulen JH, Bossuyt PM: Empirical evidence of design-related bias in studies of diagnostic tests. JAMA 282: 1061-1066, 1999
16. Liu F, Yuan W, Liao D, Zhang T, Wang Z: Association of chronic hydrocephalus after aneurysmal subarachnoid hemorrhage with transforming growth factor-β1 levels and other risk factors. Nan Fang Yi Ke Da Xue Xue Bao 33: 382-385, 2013 (In Chinese)
17. Maroon JC, Nelson PB: Hipovolemi in patients with subarachnoid hemorhage: Therapeatic implications. Neurosurgery 4: 223-226, 1979
18. Mayberg MR, Batjer HH, Docey R, Diringer M, Halley EC, Heros RL, Sternaus LL, Torner J, Adams HP Jr, Feinberg W, Thies W: Guidelines for the management of aneurysmal subarachnoid hemorrhage: A statement for healthcare professionals from a special writing group of the stroke, American Heart Association. Stroke 25: 2315-2328, 1994
19. Nagashima H, Miwa T, Horiguchi T, Tomio R, Nakagawa Y, Yoshida K: Hyperperfusion after clipping of aneurysm: A rare entity. J Stroke Cerebrovasc Dis 27(5):1425-1430, 2018
20. Nelson PB Seif SM Marron JL, Robinson AG: Hyponatremia in intracranial disease, perhaps not the syndrome of inappropriate secretion of antidiuretic hormone (SIADH). J Neurosurg 55: 938- 941, 1981
21. Okazaki T, Hifumi T, Kawakita K, Shishido H, Ogawa D, Okauchi M, Shindo A, Kawanishi M, Tamiya T, Kuroda Y: Target serum sodium levels during intensive care unit management of aneurysmal subarachnoid hemorrhage. Shock 48: 558-563, 2017
22. Oiso Y, Robertson GL, Nørgaard JP, Juul KV: Clinical review: Treatment of neurohypophyseal diabetes insipidus. J Clin Endocrinol Metab 98: 3958-3967, 2013
23. Pluta RM, Hansen-Schwartz J, Dreier J, Vajkoczy P, Macdonald RL, Nishizawa S, Kasuya H, Wellman G, Keller E, Zauner A, Dorsch N, Clark J, Ono S, Kiris T, Leroux P, Zhang JH: Cerebral vasospasm following subarachnoid hemorrhage: Time for a new world of thought. Neurol Res 31: 151-158, 2009
24. PRISMA (Preferred Reporting Items for Systematic Review and Meta - Analysis Protocols) 2015 checklist: Recommended items to address in a systematic review protocol. Available at: http://www.prisma-statement.org/documents/PRISMA-P-checklist.pdf. Accessed April 2, 2018
25. Topuk S, Akyuva Y, Karaaslan N, Mutlu CA, Yilmaz I, Isyar M, Sirin DY, Akkaya S, Özbek H, Mahirogullari M: Is it possible to treat osteosarcoma using oligonucleotides confined into controlled release drug delivery systems? Curr Pharm Biotechnol 18: 516-522, 2017
26. Wijdicks EF, Vermeluen M, Hijdra A, van Gijn J: Hyponatremia and cerebral infarction in patients with ruptured intracranial aneurysm: Is fluid restriction harmful? Ann Neurol 17: 137-140, 1985
27. Yao C, Anderson MO, Zhang J, Yang B, Phuan PW, Verkman AS: Triazolothienopyrimidine inhibitors of urea transporter UT-B reduce urine concentration. J Am Soc Nephrol 23: 1210-1220, 2012