Turkish Journal of Vascular Surgery 2021;30(3):249-253

DOI: 10.9739/tjvs.2021.906
www.turkishjournalofvascularsurgery.org

Zone 2 landing at different aortic pathologies: Surgeon-modified fenestrated stent graft

Ertekin Utku Ünal[1], Hakkı Zafer İşcan[2], Hayrettin Levent Mavioğlu[2], Mehmet Ali Özatik[2]

[1]*Department of Cardiovascular Surgery, Hitit University Erol Olçok Training and Research Hospital, Çorum, Turkey*
[2]*Department of Cardiovascular Surgery, Ankara City Hospital, Ankara, Turkey*

ABSTRACT

The treatment of aortic pathologies is always challenging for vascular surgeons. Currently, thoracic endovascular aortic repair (TEVAR) is the first treatment option for thoracic aortic pathologies. Left subclavian artery (LSA) coverage during TEVAR can be selectively done; however, revascularization is preferred to reduce the risk of neurological or ischemic complications according to current guidelines. The chimney technique, hybrid operations, back table or *in situ* fenestrations are assistive TEVAR techniques. Herein, we present three different scenarios in zone 2 landing treated with surgeon-modified fenestrated stent graft (SMFSG). The use of SMFSG for LSA revascularization during TEVAR is feasible, cost-effective, fast, and effective. Durability is of great concern, and the most suitable treatment modality for zone 2 landing necessitates randomized-controlled studies and long-term durability issues.

Keywords: Aortic aneurysm, aortic dissection, endovascular procedures, subclavian artery.

The treatment of aortic dissections and aneurysms is always challenging for vascular surgeons. Non-invasive nature of thoracic endovascular aortic repair (TEVAR) with low morbidity-mortality rates makes this technique as the first treatment option today.

Herein, we describe the surgeon-modified fenestrated stent graft (SMFSG) technique to perform endovascular revascularization of the left subclavian artery (LSA) for three different thoracic aortic pathologies: in a complicated subacute Type B aortic dissection, aortic transection, and elective but symptomatic thoracic aortic aneurysm.

SURGICAL TECHNIQUE

Case 1- A 74-year-old male patient with a symptomatic thoracic aortic aneurysm (85 mm) who also had coronary artery bypass grafting (CABG) 10 years ago. A fenestrated TEVAR (46×46×200 mm) was deployed preserving the LSA flow with an additional implanted balloon-expandable covered stent (9×37 mm) at LSA from the brachial access. Oversizing was 15 to 20%.

Case 2- A 52-year-old male symptomatic patient diagnosed with Type B aortic dissection (TBAD) with 5-mm growth within one month between two consecutive computed tomographies and intractable pain and uncontrollable hypertension in the subacute phase. A tapered 34×26×200-mm stent graft was deployed. Oversizing was approximately 5 to 10% for both proximal and distal ends.

Case 3- A 40-year-old male patient experiencing isthmic aortic transection after traffic accident with multiple trauma. As an emergency operation, we implanted a TEVAR endograft with surgeon-modified fenestration to preserve the LSA flow and aortic repair. We also implanted a balloon-expandable covered stent (9×58 mm) at LSA from the brachial access. Oversizing was 10 to 15%.

Received: December 20, 2020 ***Accepted:*** February 09, 2021 ***Published online:*** April 28, 2021

Correspondence: Ertekin Utku Ünal, MD. Hitit Üniversitesi Erol Olçok Eğitim ve Araştırma Hastanesi Kalp ve Damar Cerrahisi Kliniği, 19040 Çorum, Türkiye.
e-mail: utkuunal@gmail.com

Citation:
Ünal EU, İşcan HZ, Mavioğlu HL, Özatik MA. Zone 2 landing at different aortic pathologies: Surgeon-modified fenestrated stent graft. Turk J Vasc Surg 2021;30(3):249-253

©2021 Turkish National Vascular and Endovascular Surgery Society. All rights reserved.
This is an open access article under the terms of the Creative Commons Attribution-NonCommercial License, which permits use, distribution and reproduction in any medium, provided the original work is properly cited and is not used for commercial purposes (http://creativecommons.org/licenses/by-nc/4.0/).

Ankura™ TAA stent graft

All commercial stent grafts may be used for SMFSG. However, we used Ankura™ TAA stent graft (Lifetech Scientific, Shenzhen, China), as it has two differently shaped radiopaque markers "8" and "0" on each side of the proximal landing zone, facilitating the orientation and positioning. The most familiar endograft for the surgeon should be used. Ankura™ TAA stent graft has expanded polytetrafluoroethylene (e-PTFE) dual membrane material for biocompatibility and durability with a nitinol endoskeleton. The graft material is of great concern for graft integrity and durability. This endograft has a connecting bar on the great aortic curvature side positioned under radiopaque marker "8", avoiding shortening and providing axial support. The non-identical radiopaque markers increase the accuracy for orientation.

Endovascular procedure

Procedure planning and device sizing were performed using a three-dimensional (3D) vascular imaging workstation (Horos™ version Horos v3.3.6, The Horos Project, Public License). The diameters of proximal and distal aortic landing zones, LSA diameter, left common carotid artery (LCCA), and LSA distance, clockwise origin of aortic branches, angulations, and placement of aortic entry tears were carefully measured.

All procedures were performed under general anesthesia. Through a right femoral surgical access, a left percutaneous femoral sheath was inserted. Also, the left brachial access was prepared for an additional angiography and/or insertion of a balloon-expendable covered stent. A pigtail catheter was inserted up to the aortic arch for the true-false lumen control. Subsequently, the Ankura™ TAA stent graft was unsheathed 5 to 6 cm approximately under sterilized manners on the table. The e-PTFE endograft material was fenestrated using an 11-sized scalpel and, after the fenestration, the struts were cauterized for remnants of fabric material. (Figure 1a-f). This procedure was performed on the table after the first angiography of

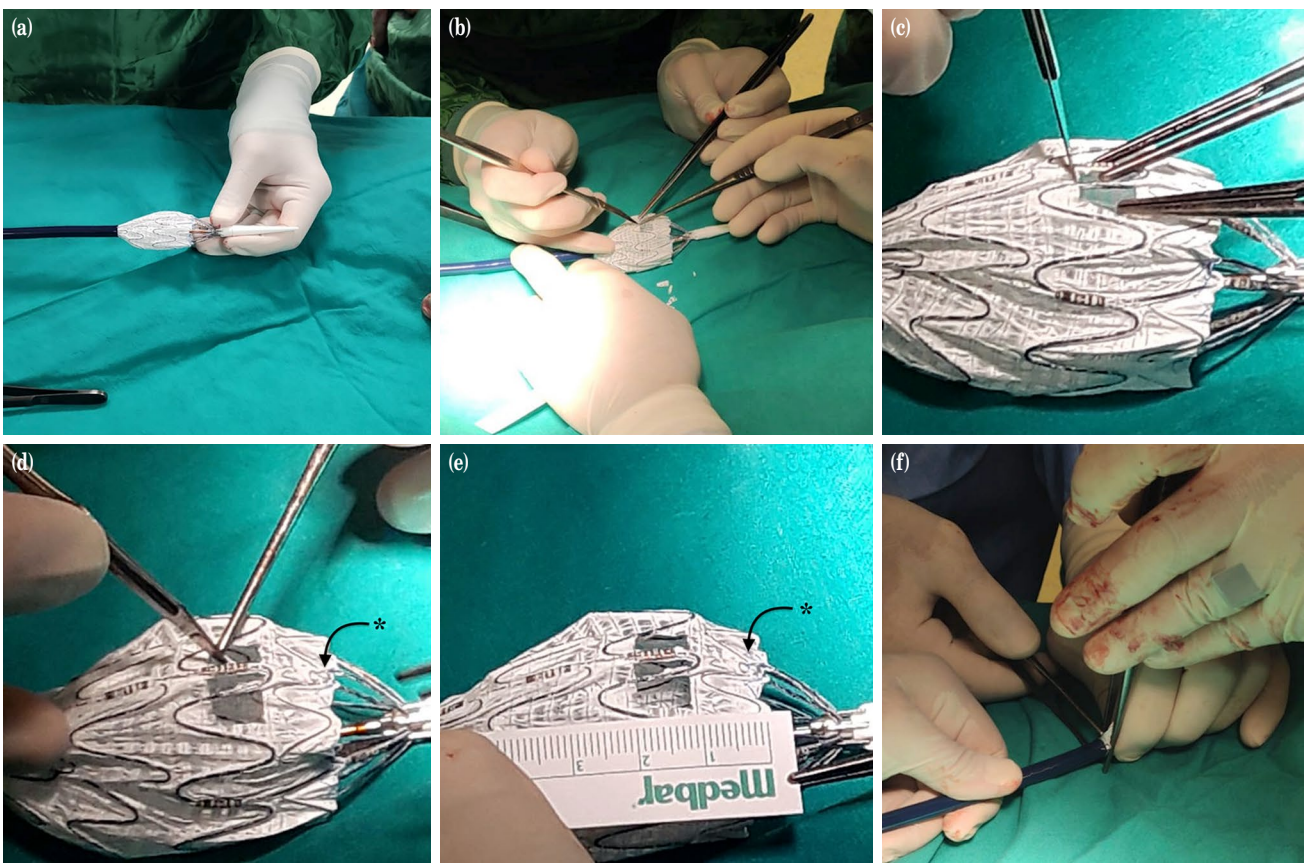

Figure 1. Step-by-step back-table fenestration technique. **(a)** Unsheating the endograft approximately 5-6 cm. **(b-e)** Fenestration of the e-PTFE clothing was performed with a 11-sized scalpel 1 cm distal to the marker "8". The stent material of the endograft was remained intact to preserve the integrity of the endograft. **(f)** Resheating the endograft. Asterix shows the marker "8" of the endograft body.

e-PTFE: Expanded polytetrafluoroethylene.

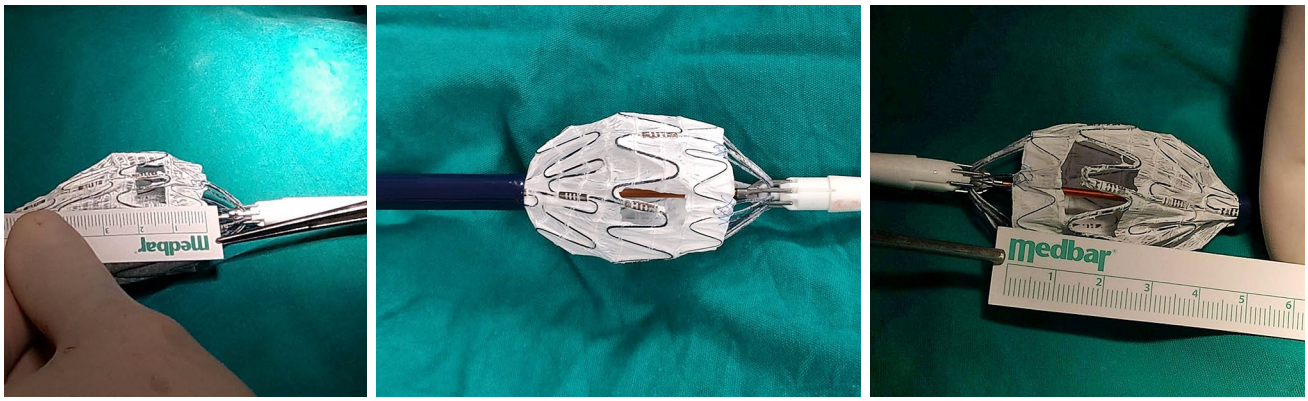

Figure 2. Back-table fenesterations of stent-grafts were performed (Case 1, Case 2, and Case 3, respectively).

the aortic arch was taken. As this unsheath fenestration and resheath procedure took only around 5 to 15 min, the timing of this fenestration is not important whether it is to be performed before or during the anesthesia.

The fenestrations were made just a little larger than the measured size of LSA diameter, paying a particular attention to preserve the endograft integrity. In Case 1 having a thoracic aortic aneurysm, the fenestration was different in shape to facilitate the orientation which was obscured by the angulations on the road to aortic arch. Figure 2 shows the different shapes and sizes of the fenestrations. The LSA was originating from the superior aspect of arch and, therefore, the fenestration was always opened distal to the "8" radiopaque marker that was always positioned at the greater aortic curvature. The distance between the "8" radiopaque marker and the proximal side of the fenestration was the distance between LCCA and LSA. Reading the "8" or "0" refers to the malpositioning of the endograft. In such cases, pulling back the endograft to the descending thoracic aorta and reloading up with a proper rotation for orientation are always mandatory. Angiographic runs were taken through a pigtail catheter introduced percutaneously from the contralateral femoral artery and, sometimes, from the brachial access with 40 to 50 degrees of the left anterior oblique position. The perfect positioning would be the 8-shaped marker appearing as a line and the connecting bar on the greater curvature. Once the fenestration is ensured to be oriented toward LSA, the deployment can be achieved. In our cases, the mean arterial blood pressure was lowered to 60 to 80 mmHg during deployment to optimize accuracy of the positioning. For all patients, the radiopaque "8" marker was positioned at the distal end of LCCA which allowed to orient the beginning of the fenestration to the beginning of the target vessel LSA.

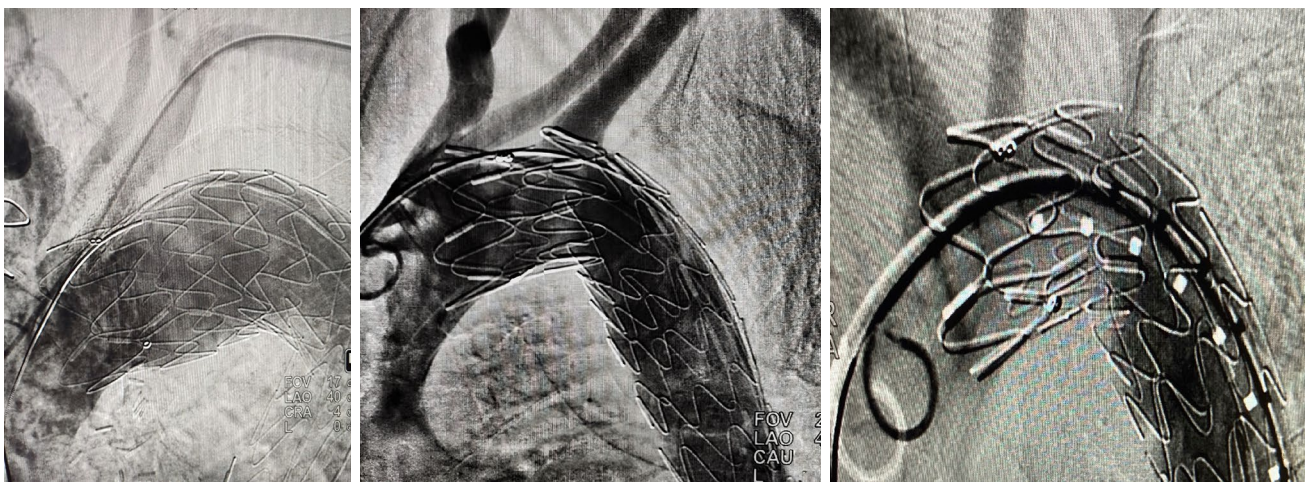

Figure 3. Completion angiography images of Case 1, Case 2, and Case 3, respectively.

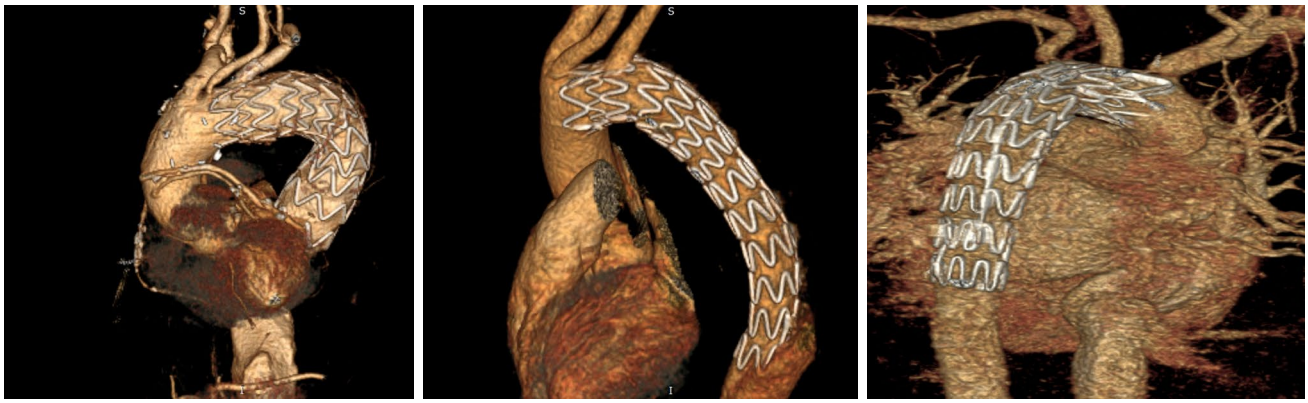

Figure 4. Postoperative three-dimensional computed tomography images of Case 1, Case 2, and Case 3, respectively.

Completion angiography showed patency of LSA and no Type 1a endoleak for any patients. The completion angiographies are shown in Figure 3 and the control computed tomography images of the patients at the first month are shown in Figure 4.

DISCUSSION

Revascularization of the LSA during TEVAR has led to various controversies among the vascular organizations and guidelines.[1] The alternative techniques for revascularization of LSA consists of two main treatment modality, totally endovascular approach like chimney, periscope, SMFSG, in situ laser or balloon fenestrations, and custom-made fenestrated or branched endografts or hybrid operations including open conventional caroticosubclavian bypass or transposition.[2-6] Endovascular LSA revascularization increased the utility of TEVAR by advancing seal to zone 2 in the aortic arch.

The chimney technique carries the advantage of being readily available, but also has the drawback of possibility of perigraft channel endoleaks. The incidence of early Type 1a endoleak has been reported to be 0 to 44% in thoracic chimney grafts.[7] On the other hand, the fragile aortic tissue is not suitable for extreme oversizing for acute or subacute TBAD and transection patients. Moreover, there has to be a balance between the gutter channels and endoleak possibility and the radial force of TEVAR graft over branch covered stent and fragile aortic tissue. Additionally, the unfavorable proximal landing zone may increase the risk of retrograde dissection extending to the aortic arch (RTAD). On the other hand, in situ needle fenestration is a potential revascularization technique; however, it is costly and currently not available in Turkey. Moreover, branched endografts has the disadvantages of waiting time and high-cost value that limits its use in the daily practice.

Among the wide variety of revascularization for LSA, SMFSG seems to be the cost-effective and easy way to perform endovascular LSA revascularization. No sophisticated instruments are needed, except for a sterile ruler, cautery, and scalpel. Of note, the SMFSG requires experience and a learning curve for accurate planning to position fenestrations. The experience of Canaud et al.[2] with 24 patients treated by homemade fenestrations for native LSA demonstrated excellent early and midterm results with 100% technical success. The indications for stenting of LSA depends on poor preservation, difference of bilateral blood pressure, or angiographically demonstrated poor blood flow in the brachial way or completion angiography.[3]

Fenestrated stent graft technology requires preoperative accurate measurements to ensure precise matching of the native vessel and endograft fenestration. Using this technique, a proper patient selection is the key to success. The anatomic limitations must be recognized, as the greatest concern should be given to the length between LCCA and LSA. It should be ≥10 mm to ensure endograft integrity and create a healthier proximal landing zone. Based on our experiences, fenestrations both for LCCA and LSA seem to be feasible with this technique. Therefore, the distance is not a contraindication, but may change the strategy.

Despite the current experiences, a margin of error in placing fenestrations always exists and the mismatch possibility may lead to complications. Aortic 3D printing has been widely described in

medicine for simulation, training, and surgical planning. Also, there are studies creating fenestrations over 3D templates, all should be studied for standardization for this technique. These procedures may facilitate the precise location of fenestrations for a rapid, efficient procedure and wider use of this technique with better long-term results.[8]

The limitations for back table fenestration are the potential risk for contamination, the possibility of spoiling the endograft integrity, and durability concerns. A left brachial access for a bailout stenting or a surgical bypass can be performed in case of misorientation. Another limitation is the absence of bench testing of SMFSG prior to clinical use. The question of fabric durability and endograft integrity still needs to be evaluated, as there is no standard protocol. The main anatomical limitation of the SMFSG appears, when there is no overlap between the endograft and the aortic wall around the target vessels.

The legal concerns regarding the SMFSG seem to be evaluated. In the literature, there is a limited number of data on this issue; however, according to Starnes' report,[9] the procedure is legal, although it needs to be standardized. If a modification is made on an endograft, then, the legal issues are transferred to the physician performing the modification from the manufacturer.[9]

In conclusion, surgical or endovascular revascularization of the LSA depends on the surgeon and patient. Until in situ needle fenestration is available on the local market and fenestrated or branched custom-made endografts are available without delay with lower costs, the SMFSG seems to be an effective, cost-effective, fast and readily available technique for LSA revascularization.

Declaration of conflicting interests

The authors declared no conflicts of interest with respect to the authorship and/or publication of this article.

Funding

The authors received no financial support for the research and/or authorship of this article.

REFERENCES

1. Schermerhorn ML, Jones DW. Management of descending thoracic aorta disease: evolving treatment paradigms in the TEVAR Era. Eur J Vasc Endovasc Surg 2017;53:1-3.
2. Canaud L, Morishita K, Gandet T, Sfeir J, Bommart S, Alric P, et al. Homemade fenestrated stent-graft for thoracic endovascular aortic repair of zone 2 aortic lesions. J Thorac Cardiovasc Surg 2018;155:488-93.
3. Shu C, Fan B, Luo M, Li Q, Fang K, Li M, et al. Endovascular treatment for aortic arch pathologies: chimney, on-the-table fenestration, and in-situ fenestration techniques. J Thorac Dis 2020;12:1437-48.
4. Zhang L, Wu MT, Zhu GL, Feng JX, Song C, Li HY, et al. Off-the-shelf devices for treatment of thoracic aortic diseases: midterm follow-up of TEVAR with chimneys or physician-made fenestrations. J Endovasc Ther 2020;27:132-42.
5. Küçüker A, Hıdıroğlu M, Çetin L, Kunt A, Sağlam F, Bayram H, et al. The results of carotid-subclavian bypass in a single institute. Damar Cer Derg 2013;22:285-91.
6. İşcan HZ, Ünal EU. Surgeon-modified fenestrated stent graft deployment in type B aortic dissection. Turk Gogus Kalp Dama 2021;29:285-9.
7. Kuo HS, Tsai KC, Chen JS. Endovascular aortic arch reconstruction with parallel grafts: a dilemma of excessive endograft oversizing. Acta Cardiol Sin 2020;36:351-9.
8. Rynio P, Kazimierczak A, Jedrzejczak T, Gutowski P. A 3-dimensional printed aortic arch template to facilitate the creation of physician-modified stent-grafts. J Endovasc Ther 2018;25:554-8.
9. Starnes BW. A surgeon's perspective regarding the regulatory, compliance, and legal issues involved with physician-modified devices. J Vasc Surg 2013;57:829-31.