Turkish Archives of Pediatrics

ORIGINAL ARTICLE
DOI: 10.5152/TurkArchPediatr.2021.21140

Clinical Features and Outcomes of Children Admitted to the PICU due to Rotavirus Infection

Emrah Gün[1], Tanıl Kendirli[1], Ahmet Gökcan Öztürk[2], Edin Botan[1], Göksel Vatansever[3], Gül Arga[4], İhsan Özdemir[3], Halil Özdemir[4], Deniz Tekin[3], Ergin Çiftçi[4], Erdal İnce[4]

[1]Department of Pediatrics, Division of Pediatric Critical Care Medicine, Ankara University School of Medicine, Ankara, Turkey
[2]Department of Pediatrics, Ankara University School of Medicine, Ankara, Turkey
[3]Department of Pediatrics, Division of Pediatric Emergency Medicine, Ankara University School of Medicine, Ankara, Turkey
[4]Department of Pediatrics, Division of Pediatric Infectious Diseases, Ankara University School of Medicine, Ankara, Turkey

What is already known on this topic?

- *Rotavirus gastroenteritis (RVGE) is a common cause for hospitalization in children under 3 years of age. Most children have rotavirus (RV) infection before the age of 5. While 80% of RV-associated deaths occur in developing countries, it is also an significant cause of morbidity and rarely, mortality, even in developed countries.*

What this study adds on this topic?

- *RV infections may lead to seizures and encephalopathy in children. The other rare complications of RVGE are secondary bacteremia and candidemia. Both community-acquired rotavirus (CA-RV) and hospital-acquired rotavirus (HARV) sometimes present with a severe clinical course, and may cause morbidity and even death, especially in infants.*

ABSTRACT

Objectives: In this study, we aimed to evaluate the clinical and laboratory features of the patients with rotavirus (RV) antigen positivity on or following admission to the pediatric intensive care unit (PICU).

Methods: Patients admitted to the PICU due to community-acquired rotavirus (CA-RV) or hospital-acquired rotavirus (HA-RV)-induced gastroenteritis between January 1, 2013, and December 31, 2019 were evaluated.

Results: Thirty-four patients with a mean age of 14.00 ± 19.17 months were enrolled. Forty-four percent were girls. Twenty (58.8%) patients had a history of chronic diseases. Nine (26.5%) patients had CA-RV and 25 (73.5%) patients had HA-RV infection. RV antigens were simultaneously found in 44.1% (n = 14) of the other patients at the time of diagnosis. In the study sample, 5 patients had hyponatremia, 8 had hypernatremia, 6 had hypokalemia, 4 had hypoalbuminemia, 21 had leukocytosis, 2 had leukopenia and 3 had thrombocytopenia, and 17 had elevated C-reactive protein (CRP) levels. Three patients had seizures, 1 patient had cardiac arrest, and 2 patients had secondary bacteremia. The mean (SD) PICU length of stay was 6 (6.02) with CA-RV gastroenteritis. All CA-RV patients survived, but 8 of the HA-RV patients succumbed to causes other than RV.

Conclusion: RV-related PICU admission is not rare, and occasional severe clinical consequences occur, especially in young children, with both CA-RV and HA-RV gastroenteritis. Appropriate timely intervention and meticulous follow-up improve survival.

Keywords: Rotavirus, pediatric intensive care, encephalopathy, severe complication

INTRODUCTION

Rotavirus gastroenteritis (RVGE) is a common cause for hospitalization in children under 3 years of age.[1] Most children have rotavirus (RV) infection before the age of 5. While 80% of RV-associated deaths occur in developing countries, it is also an important cause of morbidity and rarely, mortality, even in developed countries.[2] Although mortality due to RVGE is rare in developed countries, it causes significant morbidity and economic burden on the healthcare system.[3] Approximately 453 000 children yearly succumb to RVGE worldwide due to the lack of adequate healthcare.[3]

RV is transmitted by fecal–oral contact and droplets in the air, and even a small inoculum is infectious (<100 virus particles). Gastric acid cannot neutralize RV, which adheres to the proximal small intestine. During the 18-36 hour incubation period, the virus enters the intestinal

Corresponding author:
Emrah Gün
✉emrhgn@hotmail.com
Received: May 3, 2021
Accepted: June 7, 2021

Content of this journal is licensed under a Creative Commons Attribution-NonCommercial 4.0 International License.

Cite this article as: Gün E, Kendirli T, Öztürk AG, et al. Clinical features and outcomes of children admitted to the picu due to rotavirus infection. *Turk Arch Pediatr.* 2021; 56(6): 591-595.

epithelial cells, where non-structural protein (NSP4), a powerful enterotoxin that can cause diarrhea, is produced.[4] Although the symptoms of RVGE are vomiting, diarrhea, and fever, it is typically self-limiting and complete recovery is the norm with adequate hydration.[5] However, it can occasionally cause serious complications such as encephalopathy and encephalitis.[3]

The aim of this study was to evaluate the clinical course and complications of children admitted to the pediatric intensive care unit (PICU) for community-acquired or hospital-acquired RVGE.

METHODS

Study Design

This was a retrospective study, conducted between January 1, 2013 and January 1, 2020 in our tertiary PICU. Patients between 1 month and 18 years of age presented with RV antigen positivity (detected in stool samples with enzyme-linked immunosorbent assay [ELISA]) on PICU admission or during hospitalization. This study was carried out at a tertiary academic center, in accordance with international ethical standards and the World Medical Association's Declaration of Helsinki. Written approval for this study was obtained from the Ankara University Faculty of Medicine Clinical Research Ethical Committee.(Decision No: İ6-360-20). Informed consent was obtained from the legal guardians of all patients. The demographic and disease-related information of the patients who were admitted to the PICU and had RV antigen positivity were recorded, as presented below.

Definitions

Hospital-acquired RV (HA-RV) was defined as disease occurring between 48 hours and 72 hours after admission. Community-acquired (CA-RV) was defined as RV gastroenteritis starting before hospitalization.[6]

Data Collection and Analysis

Age, gender, season of presentation, hospital length of stay (LOS), underlying medical conditions, presence of central venous catheter and urinary catheter, mechanical ventilation, blood count, biochemistry and acute-phase reactant results, and the findings of computed tomography (CT), magnetic resonance imaging (MRI), and electroencephalography were extracted from patient charts and electronic hospital records. Complications due to RV, such as electrolyte imbalance, prerenal acute kidney injury, seizures, and altered mentation were recorded. A serum sodium level of >145 mmol/L was evaluated as hypernatremia, <135 mmol/L as hyponatremia, serum potassium level of <3.5 mmol/L as hypokalemia, serum albumin level of <2.5 g/L as hypoalbuminemia, thrombocyte count of $<150 \times 10^3/\mu L$ as thrombocytopenia, C-reactive protein (CRP) level of >5 mg/L as high CRP, white blood cell count of $<4 \times 10^3/\mu L$ as leucopenia and $>10 \times 10^3/\mu L$ as leukocytosis, aspartate aminotransferase (AST) >35 as high AST, and alanine aminotransferase (ALT) >40 as high ALT.

Statistical Analysis

The data were analyzed using Statistical Package for the Social Sciences (SPSS) version 23.0 (IBM SPSS Corp.; Armonk, NY, USA). The expression *n* (%) was used for categorical variables, mean ± SD for continuous variables showing normal distribution, and when normal distribution was not seen, the median (lower–upper limit) was used. The demographic and clinical data of the patients were subjected to descriptive analyses, and the mean values and standard deviations were identified.

RESULTS

Study Population

The mean age of the 34 patients diagnosed with RV was 14.00 ± 19.17 months. In the study, 44% of the patients were girls (*n* = 15) and 56% of the patients were boys (*n* = 19). Thirty-four patients with complaints of gastroenteritis, tested positive for RV antigen (24 patients in the first test, 4 patients in the second test, and 6 patients in the third test). None of the patients had received the RV vaccine. The patients' demographic features are given in Table 1.

A total of 5 patients had hyponatremia, 8 had hypernatremia, 6 had hypokalemia, 3 had seizures, 21 had leukocytosis, 2 had leukopenia, 3 had thrombocytopenia, 17 had high CRP levels, 23 had high AST levels, and 9 had high ALT levels. The median (minimum-maximum) values of the laboratory parameters are given in Table 2.

Clinical Findings of Patients with CA-RV

There were 9 cases with CA-RV on admission to the PICU. Of these, 7 had hypovolemic shock on admission, 7 had fever, 7 had hypernatremia, 3 had seizures, 6 had electrolyte abnormalities, 4 had acute kidney injury, and 6 had altered mental status. In the study, 7 patients had leukocytosis, 5 had elevated CRP, 7 had elevated AST, 8 had elevated ALT, 4 had elevated creatinine levels, 6 had elevated lactate dehydrogenase levels, and 1 had hypokalemia. The median (SD) LOS in the PICU was 6 (6.02) days. Three patients needed mechanical ventilation and 6 patients needed central venous lines. All patients survived.

Clinical Findings of Patients with HA-RV

Of the 25 patients who had HA-RVGE, 14 were already in the PICU due to respiratory failure. Three patients had congenital

Table 1. Patients' Clinical and Demographic Features.

	Mean ± Standard Deviation
Weight (kg)	7.74 ± 3.79
Age (months)	14.00 ± 19.17
PICU LOS (days)	25.44 ± 29.46
	n (%)
Gender	
Girls	15 (44.1)
Boys	19 (55.9)
Community-acquired	9 (26.5)
Hospital-acquired	25 (73.5)
Mechanical ventilation	20 (58.8)
Central venous catheter	27 (79.4)
Urinary catheter	27 (79.4)
Season	
Winter	9 (26.5)
Spring	20 (58.8)
Summer	3 (8.8)
Autumn	2 (5.9)
Comorbidity	20 (58.8)

PICU, pediatric intensive care unit; LOS, length of stay.

Table 2. Laboratory Findings of All Patients

	Median (50 percentile)	25 percentile	75 percentile	Minimum	Maximum
White blood cells (10^3/µL)	11.980	7.942	16.107	100	42.700
Hemoglobin (g/L)	9.95	9.20	11.07	7.80	13.00
Platelets (10^3/µL)	291500	211750	397000	64000	601000
CRP (mg/L)	16	1.8	54	0.1	223
AST (U/L)	45.5	34	59.25	21	1009
ALT (U/L)	25	19,5	41.75	0	930
BUN (mg/dL)	11	7	24.25	1	56
Creatinine (mg/dL)	0.23	0,15	0.40	0.05	1.33
LDH (U/L)	435	300	554	138	1420
Sodium (mmol/L)	138	136.75	145.25	128	177
Potassium (mmol/L)	4.10	3.68	4.60	2.80	5.20
Albumin (g/L)	2.70	3.30	3.70	2.00	4.53

CRP, C-reactive protein; AST, aspartate aminotransferase; ALT, alanine aminotransferase; BUN, blood urea nitrogen; LDH, lactate dehydrogenase.

heart disease, 3 patients had chronic liver disease, 1 patient each had an intracranial mass, metabolic disorder, immunodeficiency, neurologic disorder, and burns. Sixteen patients (47.1%) had fever on admission. Twenty patients (58.8%) had history of a chronic disease. There was 1 other patient with simultaneous RV antigen positivity at the time of diagnosis of 14 patients (44.1%). Totally 58% (n = 20) of the patients were intubated, and 79.4% (n = 27) had a central venous catheter and urinary catheter. Three patients were intubated due to findings of shock during hospitalization, due to CA-RV gastroenteritis.

Seasonal Variation in Hospitalization

Ten patients were admitted in March, 6 were admitted in April, and 4 patients were admitted in May (Figure 1). Twenty patients (58.8%) were admitted in spring, 9 patients (26.5%) were admitted in winter, 3 (8.8%) were admitted in summer, and 2 (5.9%) were admitted in fall, respectively.

Clinical Findings

Three patients had RV-induced seizures. A 9-month-old boy who had seizures had an electroencephalogram (EEG) showing generalized slow wave activity, which was consistent with encephalopathy. The cranial MRI showed bilateral subdural effusion and frontotemporal atrophy. Metabolic screening did not reveal any specific error of metabolism in this patient. He was not started on chronic antiepileptic A 5-month-old girl had shock, cardiac arrest, and seizure at the time of admission. Cardiopulmonary resuscitation (CPR) was performed for 5 minutes. She was started on levetiracetam. She had viral pneumonia due to coronavirus HKU and human metapneumovirus, at the time of admission. The cerebrospinal fluid (CSF) glucose level was 80 mg/dL, simultaneous blood glucose level was 125 mg/dL, and CSF protein level was 40 mg/dL. She had a normal EEG. Cranial CT showed slight focal increase in the extra-axial CSF distance in the basal region of the left temporal lobe. A 10-month-old infant with fever, diarrhea, and seizures had a normal head CT and EEG. CSF culture was negative. He had stool RV antigen positivity. Four patients with epilepsy were RV positive on PICU, and their antiepileptic doses were increased during the time of RV positivity.

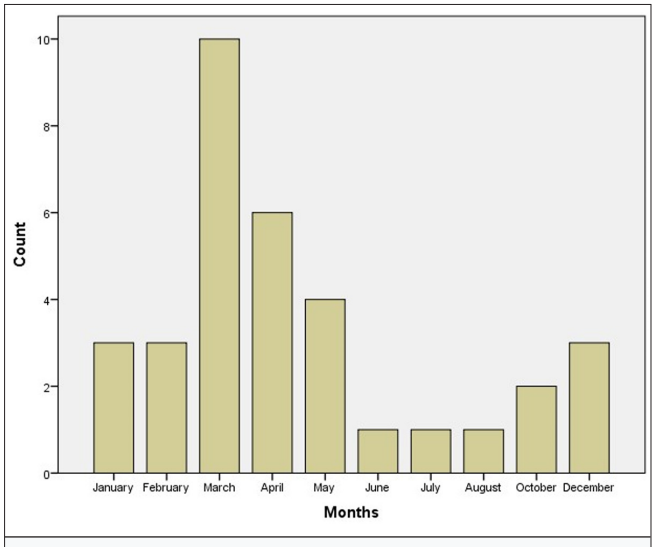

Figure 1. The comparison of patients according to the months in admission PICU.

Two patients with HA RVGE had secondary bacteremia. Blood cultures were obtained due to fever. The culture for the 10 month-old boy with congenital heart disease was positive for alpha hemolytic *Streptococcus*, and he was consequently started on piperacillin–tazobactam. The blood culture of the 22-month-old girl with metabolic disease yielded and she was started on ciprofloxacin. Both patients improved with antibiotics.

Outcomes

The mean (SD) PICU LOS was 25.44 (29.46) days (3 patients had a LOS of 95, 101, and 110 days, respectively) (Table 1). The mean (SD) PICU LOS was 6 (6.02) days for patients with CA-RV gastroenteritis and 30.64 (30.97) for those with HA-RV gastroenteritis. Twenty-six patients (76.5%) survived to PICU discharge, but unfortunately, 8 patients (23.5%) died in the PICU. Their deaths were not caused by RV infection.

DISCUSSION

RV vaccines have been developed and are licensed in many countries. Both vaccines, one produced from the weakened human strain and one produced from bovine–human strains, are effective in decreasing severity of infection.[4] Although the RV vaccines are administered only to infants, a decrease in

the hospital admission numbers due to RV was mostly seen in children of a slightly older age group, and in alignment with previous studies, this may indicate that it has an important protective effect in non-immunized children.[7] In our study, no patient had been vaccinated, demonstrating the impact of RV vaccination. RVGE is mostly seen between 6 and 24 months of age.[8] In our study, only 4 cases out of 34 were in this age range.

In a study conducted by Johansen et al.,[2] 12 of the 723 RVGE cases were admitted to the intensive care unit due to severe dehydration. Ten patients had been previously healthy, one patient was premature, and one patient had primary immune deficiency (PID). There was no patient with PID.[2] Persistent RV infection and lymphopenia are well-known features of severe combined immune deficiency. RV infection usually does not occur before the third month in immunocompetent patients. Spontaneous occurrence of RV infection may also indicate an immune deficiency.[9] In the same study, 60.5% of the nosocomial RVGE cases had a chronic medical condition.[2] Similarly, in our study, 58.8% (n = 20) of the patients had history of chronic illness. In the same aforementioned study, 9.1% of the patients had hypernatremic dehydration.[2] In a study by Kocabaş et al.,[10] the frequency of hyponatremia was 23.9%, the frequency of hypernatremia was 8.3%, and the frequency of hypokalemia was 8.3%, in the pediatric infectious diseases ward. In our study, 23.5% (n = 8) of the patients had hypernatremic dehydration, while the frequency of hypokalemia was 17.6% (n = 6), and the frequency of hyponatremia was 14.7% (n = 5).

The extraintestinal complications of RVGE are febrile seizures, afebrile seizures, encephalopathy, meningoencephalitis, and cerebellitis.[11-16] The frequency of afebrile seizure in children with RVGE was reported as 2% by Hung et al.,[17] and as 0.9% by Lloyd et al.[18] The frequency of febrile seizures was reported as 4.6% by Lloyd et al.[18] In our study, 2 patients had febrile seizures. These patients were encephalopathic after the seizure, and were thus started on levetiracetam.

Hosino et al.[19] reported that out of 983 patients with acute encephalopathy, 4% had RV infection. Complications of the central nervous system occur in about 2-4% of RV infections.[15] Reversible signal changes in the splenium of the corpus callosum were detected on MRI in patients with RV-associated encephalitis or encephalopathy.[13,15,16] The mechanism of this reversible lesion may be the development of intramyelinic axonal edema and/or the development of an inflammatory infiltrate.[13] Recently, Takanashi et al.[20] reported that mild hyponatremia occurred in patients with RV-induced encephalopathy. In hyponatremia, water enters the brain, resulting in cerebral edema.[13] Another possible explanation for neurological symptoms may be related to the secondary involvement of the central nervous system.[16] It has also been noted that 33% of patients with RV-induced encephalopathy may develop seizures.[15] Similarly, 2 of the 3 patients with RV-induced encephalopathy in our study had prolonged seizures.

Secondary bacteremia and candidemia are some rare complications of RVGE.[21] Bacterial translocation of enteric flora through the intestinal epithelium damaged by RV is thought to predispose to secondary bacteremia.[21] However, septicemia due to RV infection is not fully understood.[21] This life-threatening complication of RVGE can be diagnosed with early blood cultures.[22] In our study, 2 patients with HA-RV had secondary bacteremia. The blood cultures yielded *Streptococcus viridans* and *Pseudomonas aeruginosa* in these patients. Candidemia was not seen in our patients.

During infection, non-structural protein-4 (NSP-4) destroys the enterocytes, and toxins enter the bloodstream through the damaged intestinal epithelium. Besides, RV infection destroys the healthy intestinal mucosa through its enzymes. NSP-4 has a direct toxic effect on the lamina propria and the gastrointestinal epithelium.[16]

The other extraintestinal complications of RV involve the kidney, liver, respiratory tract, lymph node, and pancreas.[23,24] In our study, 1 patient had ischemic hepatitis (possibly related to cardiac arrest). Four patients had hypovolemic shock-related acute kidney injury. Three of these patients needed inotropic support due to fluid resistant hypotension. All of the 34 patients needed fluid boluses during admission, with 18 patients needing 1 bolus, 11 patients needing 2 boluses, and 5 patients needing 3 boluses. Nine patients needed the bolus for shock, while others were given bolus fluids for deficit replacement due to severe dehydration. In our study, gastrointestinal bleeding, urinary stone, and pancreatic involvement were not observed.

Fischer et al.[25] reported that 14 of the 54 immunocompetent patients with acute diarrhea were found to have RV antigen positivity, and 9 patients had serum RV RNA. Whether or not these patients were in PICU was not stated. Extraintestinal findings were more common in patients with RV RNA positivity.[25] Unfortunately, the equipment for serum-RV RNA testing was not available in our hospital.

Our study is limited in that it is a retrospective study, with a limited number of patients, and RV RNA assays and serotyping of RV were not performed.

CONCLUSION

RVGE sometimes presents with a severe clinical course and is a significant cause of mortality and morbidity, particularly in infants. Our national vaccination program does not contain the RV vaccine, which leads to an increase in severe RVGE, sometimes with extraintestinal complications, which may necessitate long hospital admissions and increase healthcare costs. The low socioeconomic level of our study group also resulted in the lack of vaccination. Administering the RV vaccine to infants will have a positive impact in protecting children from hospital and PICU admissions due to RV-related disease.

Ethical Committee Approval: Ethical committee approval was received from the Ethics Committee of Ankara University School of Medicine, (Approval No: İ6- 360-20).

Informed Consent: Written informed consent was obtained from the legal guardians of all patients who participated in this study.

Peer Review: Externally peer-reviewed.

Author Contributions: Concept - T.K., E.G., A.G.Ö., E.B.; Design - T.K., E.G., A.G.Ö.; Supervision - T.K., H.Ö., E.Ç., E.İ.; Resource - E.G., A.G.Ö.; Materials - E.G., E.B., G.A., G.V., İ.Ö.; Data Collection and/or Processing - E.G., E.B., G.A., G.V.; Analysis and/or Interpretation - T.K., E.G., A.G.Ö.; Literature Search - T.K., E.G.; Writing - E.G., A.G.Ö.; Critical Reviews - T.K., D.T., H.Ö., E.Ç., E.İ.

Conflict of Interest: The authors have no conflicts of interest to declare.

Financial Disclosures: The authors declared that this study has received no financial support.

REFERENCES

1. Kaiser P, Borte M, Zimmer KP, Huppertz HI. Complications in hospitalized children with acute gastroenteritis caused by rotavirus: a retrospective analysis. *Eur J Pediatr*. 2012;171(2):337-345. [CrossRef]
2. Johansen K, Hedlund KO, Zweygberg-Wirgart B, Bennet R. Complications attributable to rotavirus-induced diarrhoea in a Swedish paediatric population: report from an 11-year surveillance. *Scand J Infect Dis*. 2008;40(11-12):958-964. [CrossRef]
3. Hoshi SL, Kondo M, Okubo I. Economic evaluation of routine infant rotavirus immunisation program in Japan. *Hum Vaccin Immunother*. 2017;13(5):1115-1125. [CrossRef]
4. Glass RI, Parashar UD, Bresee JS, et al. Rotavirus vaccines: current prospects and future challenges. *Lancet*. 2006;368(9532):323-332. [CrossRef]
5. Solomon IH, Milner Jr DA. Histopathology of vaccine-preventable diseases. *Histopathology*. 2017;70(1):109-122. [CrossRef]
6. Ogilvie I, Khoury H, Goetghebeur MM, El Khoury AC, Giaquinto C. Burden of community-acquired and nosocomial rotavirus gastroenteritis in the pediatric population of Western Europe: a scoping review. *BMC Infect Dis*. 2012;12:62. [CrossRef]
7. Forrest R, Jones L, Willocks L, Hardie A, Templeton K. Impact of the introduction of rotavirus vaccination on paediatric hospital admissions, Lothian, Scotland: a retrospective observational study. *Arch Dis Child*. 2017;102(4):323-327. [CrossRef]
8. Dickey M, Jamison L, Michaud L, et al. Rotavirus meningoencephalitis in a previously healthy child and a review of the literature. *Pediatr Infect Dis J*. 2009;28(4):318-321. [CrossRef]
9. Hennewig U, Schulz A, Adams O, et al. Severe combined immunodeficiency signalized by eosinophilia and lymphopenia in rotavirus infected infants. *Klin Padiatr*. 2007;219(6):343-347. [CrossRef]
10. Aldemir-Kocabaş B, Karbuz A, Özdemir H, et al. Complications with rotavirus: a single center experiences. *Turk J Pediatr*. 2016;58(6):602-608. [CrossRef]
11. Kehle J, Metzger-Boddien C, Tewald F, et al. First case of confirmed rotavirus meningoencephalitis in Germany. *Pediatr Infect Dis J*. 2003;22(5):468-470. [CrossRef]
12. Kobayashi S, Negishi Y, Ando N, et al. Two patients with acute rotavirus encephalitis associated with cerebellar signs and symptoms. *Eur J Pediatr*. 2010;169(10):1287-1291. [CrossRef]
13. Mori T, Morii M, Kuroiwa Y, et al. Rotavirus encephalitis and cerebellitis with reversible magnetic resonance signal changes. *Pediatr Int*. 2011;53(2):252-255. [CrossRef]
14. Kato Z, Sasai H, Funato M, Asano T, Kondo N. Acute cerebellitis associated with rotavirus infection. *World J Pediatr*. 2013;9(1):87-89. [CrossRef]
15. Ohnishi T, Mishima Y, Shinozuka S, Shikoro N, Kamimaki I. Apnea and delirious behavior caused by mild encephalitis/encephalopathy with reversible splenial lesion complicated with rotavirus infection. *Pediatr Int*. 2018;60(6):602-604. [CrossRef]
16. Laizane G, Smane L, Nokalna I, Gardovska D, Feemster KA. Rotavirus-associated seizures and reversible corpus callosum lesion. *Acta Med Litu*. 2019;26(2):113-117. [CrossRef]
17. Hung JJ, Wen HY, Yen MH, et al. Rotavirus gastroenteritis associated with afebrile convulsion in children: clinical analysis of 40 cases. *Chang Gung Med J*. 2003;26(9):654-659.
18. Lloyd MB, Lloyd JC, Gesteland PH, Bale Jr JF. Rotavirus gastroenteritis and seizures in young children. *Pediatr Neurol*. 2010;42(6):404-408. [CrossRef]
19. Hoshino A, Saitoh M, Oka A, et al. Epidemiology of acute encephalopathy in Japan, with emphasis on the association of viruses and syndromes. *Brain Dev*. 2012;34(5):337-343. [CrossRef]
20. Takanashi J, Tada H, Maeda M, et al. Encephalopathy with a reversible splenial lesion is associated with hyponatremia. *Brain Dev*. 2009;31(3):217-220. [CrossRef]
21. Scheier E, Aviner S. Septicemia following rotavirus gastroenteritis. *Isr Med Assoc J*. 2013;15(3):166-169.
22. Ciftçi E, Tapisiz A, Ozdemir H, et al. Bacteraemia and candidaemia: a considerable and underestimated complication of severe rotavirus gastroenteritis. *Scand J Infect Dis*. 2009;41(11-12):857-861. [CrossRef]
23. Giordano S, Serra G, Dones P, et al. Acute pancreatitis in children and rotavirus infection. Description of a case and minireview. *New Microbiol*. 2013;36(1):97-101.
24. Hattori F, Kawamura Y, Kawada JI, et al. Survey of rotavirus-associated severe complications in Aichi Prefecture. *Pediatr Int*. 2018;60(3):259-263. [CrossRef]
25. Fischer TK, Ashley D, Kerin T, et al. Rotavirus antigenemia in patients with acute gastroenteritis. *J Infect Dis*. 2005;192(5):913-919. [CrossRef]