THE MEDICAL BULLETIN OF
SISLI ETFAL HOSPITAL

DOI: 10.14744/SEMB.2020.33349
Med Bull Sisli Etfal Hosp 2021;55(1):42–48

Original Research

Discussion of Histopathological Findings of 954 Breast Reduction Specimens

Soysal Bas,[1] Cagatay Oner,[1] Ali Can Aydin,[1] Ramazan Ucak,[2] Selami Serhat Sirvan,[1] Semra Karsidag[1]

[1]Department of Plastic, Reconstructive and Aesthetic Surgery, University of Health Sciences Turkey, Sisli Hamidiye Etfal Teaching and Research Hospital, Istanbul, Turkey
[2]Department of Pathology, University of Health Sciences Turkey, Sisli Hamidiye Etfal Teaching and Research Hospital, Istanbul, Turkey

Abstract

Objectives: Breast reduction is a frequently sought procedure by patients and one of the most commonly performed operations by plastic surgeons. Follow-up of histopathological results after reduction mammoplasty is very important. This study aimed to evaluate the histopathological results of patients undergoing bilateral reduction mammoplasty to determine the incidence of breast lesions and risk factors of high-risk breast lesions.

Methods: 477 patients who underwent reduction mammoplasty in the plastic surgery department between October 2013 and January 2020 were included in this study. Patients were evaluated according to age, body mass index (BMI), comorbidity factors, tobacco use, family history and histopathological findings.

Results: The mean age of patients was 42.43±12.05 years. Body mass index ranged from 23 to 34.6. As for comorbidity factors, 12 patients had hypertension, five patients had asthma and six patients had diabetes mellitus. Seventeen patients (3.6%) were smokers, and 25 (5.2%) patients had a family history of breast cancer. Among the patients, 2.3% were 20 years and under, 17.1% were between 21 and 30 years old, 21.5% were between 31 and 40 years old, 33.1% were between 41 and 50 years old, 18.2% were between 51 and 60 years old, and 7.5% were 60 years and above. 85.4% of histopathological findings consisted of normal breast tissue and nonproliferative breast lesion breast lesions. The incidences of proliferative breast lesions, atypical hyperplasia and in situ lesions were calculated as 5.7%, 2% and 0.4%, respectively. The mean follow-up period was 3.8±1.6 years.

Conclusion: Although preoperative breast cancer screening methods are used before the reduction mammoplasty, high-risk lesions may be encountered afterwards. One of the biggest advantages of reduction mammoplasty in addition to psychophysiological recovery is breast cancer risk reduction.

Keywords: Breast reduction; histopathologic result; nonproliferative breast lesion; proliferative breast lesion.

Please cite this article as "Bas S, Oner C, Aydin AC, Ucak R, Sirvan SS, Karsidag S. Discussion of Histopathological Findings of 954 Breast Reduction Specimens. Med Bull Sisli Etfal Hosp 2021;55(1):42–48".

Reduction mammoplasty is a surgical procedure correcting congenital or acquired breast asymmetries as in postmastectomy cases. Mammary hypertrophy may cause neck and back pain, shoulder grooving, inframammary skin maceration and dermatosis. The age of patients admitted for breast reduction surgery range from pubertal to postmenopausal period.

There is a significant decrease in physical pain and a notable improvement in psychosocial activities of patients following reduction mammoplasty.[1] Significant improvement in thoracic kyphosis, lumbar lordosis and also of respiratory functions is observed proportionally to the amount of breast tissue excised.[2, 3] Thus, breast reduction is a frequently sought procedure by patients and one of the

Address for correspondence: Soysal Bas, MD. Saglik Bilimleri Universitesi, Sisli Hamidiye Etfal Tibbi Uygulama ve Arastirma Merkezi, Plastik, Rekonstruktif ve Estetik Cerrahi Bolumu, Istanbul, Turkey
Phone: +90 536 898 21 17 **E-mail:** soysalbas@gmail.com

Submitted Date: April 14, 2020 **Accepted Date:** June 07, 2020 **Available Online Date:** March 17, 2021

©Copyright 2021 by The Medical Bulletin of Sisli Etfal Hospital - Available online at www.sislietfaltip.org
OPEN ACCESS This is an open access article under the CC BY-NC license (http://creativecommons.org/licenses/by-nc/4.0/).

most commonly performed operations by plastic surgeons. For instance, more than 100 000 reduction mammoplasties were performed in the U.S.A. in 2018.[4]

Apart from that, one in eight women will develop breast cancer during her lifetime.[5] Among the patients undergoing reduction mammoplasty procedure, between 0.05 and 4.5% of patients are diagnosed with occult breast cancer.[5] Moreover, proliferative breast lesions (PBL) increase breast cancer risk 1.5-2-fold, whereas atypical hyperplasia (AH) and in situ lesions (CIS) increase 4-5 and 8-10-fold, respectively.[6] Consequently, follow-up of histopathological results after reduction mammoplasty is very important.

This study aimed to evaluate the histopathological results of patients undergoing bilateral reduction mammoplasty, to determine the incidence of breast lesions and risk factors of high-risk breast lesions.

Methods

This study was approved by the ethics committee of our institution (11.02.2020; approval number: 2670). Four hundred seventy-seven patients who underwent reduction mammoplasty in the plastic surgery department between October 2013 and January 2020 were included in this study. All the included patients were operated on due to symptomatic bilateral breast hypertrophy. Patients who had breast asymmetry due to unilateral congenital or acquired hypertrophy and following mastectomy were not included in this study. All the patients were preoperatively screened for breast cancer; a breast ultrasound (US) was performed under age 40 and a mammogram was performed at age 40 and above. Only patients having a normal physical examination and a Breast Imaging-Reporting and Data System (BI-RADS) score 3 and under were operated. The patient with BI-RADS 0 on mammography was re-evaluated with breast ultrasound. In addition, patients with intense breast parenchyma were evaluated by contrast-enhanced breast magnetic resonance imaging and tissue sampling was performed for suspicious lesions. These patients without malignancy in imaging and tissue sampling were included in the study. Patients were evaluated according to age, body mass index (BMI), comorbidity factors, tobacco use, family history and histopathological findings.

For pathological evaluation, tissue samples were fixed 24 hours in 10% formalin after excision. Tissues were macroscopically evaluated for palpable masses and areas with increased density. Additional samples were taken from different areas for parenchymal evaluation and from any palpable mass and increased density zone if present. Tissues were then embedded in paraffin, 7-µm sections were cut and stained with hematoxylin-eosin (H&E). An average of ten sections was obtained from each breast. Analysis was performed under light microscopy by a pathologist. Breast tissue samples were categorized according to the guidelines and consensus recommendations of the College of American Pathologists' Committee (CAPC).[6] Findings were categorized according to patient and breast specimens. Only a single diagnosis was statistically counted whenever both breasts of a patient had a common diagnostic report. In addition, patients who had more than one different histopathological finding were classified in the high-risk group.

Statistical Analysis

Statistical analyses were performed using SPSS 26.0 for Windows. In descriptive statistics, numeric and percent values were used for categorical variables, mean and standard deviation values were used for numeric variables. Shapiro-Wilk test was used to assess if numeric variables were normally distributed in groups. Age and BMI values were assessed with chi-squared test, whereas comorbidity factors, tobacco use and family history with the Mann-Whitney U test. Multivariate logistic regression analyses were performed to assess risk factors associated with proliferative and non-proliferative lesions. Statistical significance was accepted at $p<0.05$.

Results

The age of patients varied between 17 and 70 (mean: 42.43±12.05). BMI ranged from 23 to 34.6 (mean 28.48±2.41). As for comorbidity factors, 12 patients had hypertension, five patients had asthma and six patients had diabetes mellitus. Seventeen patients (3.6%) were smokers and 25 (5.2%) patients had a family history of breast cancer. The mean follow-up period was 3.8±1.6 years.

Among the patients, 2.3% were 20 years and under, 17.1% were between 21 and 30 years old, 21.5% were between 31 and 40 years old, 33.1% were between 41 and 50 years old, 18.2% were between 51 and 60 years old and 7.5% were 60 years and above. Among all the patients, nonproliferative breast lesion (NPBL) was the most common diagnosis (n=290), followed by normal breast tissue (n=137), PBL (n=37), AH (n=11) and CIS (n=2) (Fig. 1). No lesions associated with an increased risk of breast cancer were detected in patients under 20 years of age. NPBL were the most frequently encountered lesion in other age groups. PBL was most commonly seen in the second and fourth decades of life. AH started to appear in the third decade and was most commonly seen in the fifth decade and above. Two patients were diagnosed with CIS: one in the third and the other in the fifth-decade group. No patients were diagnosed with breast cancer (Fig. 2). Seven hundred nineteen histopatho-

logical findings obtained from 954 breast tissue samples were summarized in Table 1 and Figure 3. 85.4% of histopathological findings consisted of normal breast tissue and

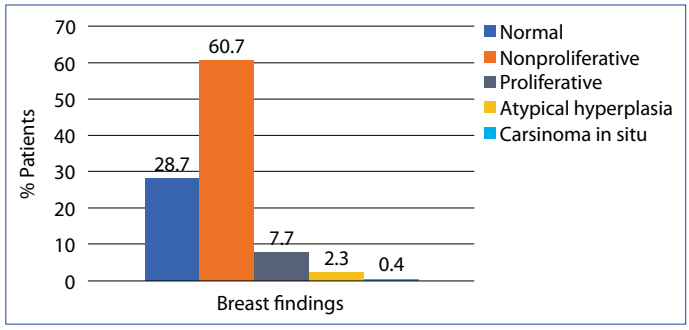

Figure 1. Incidence of histopathological findings.

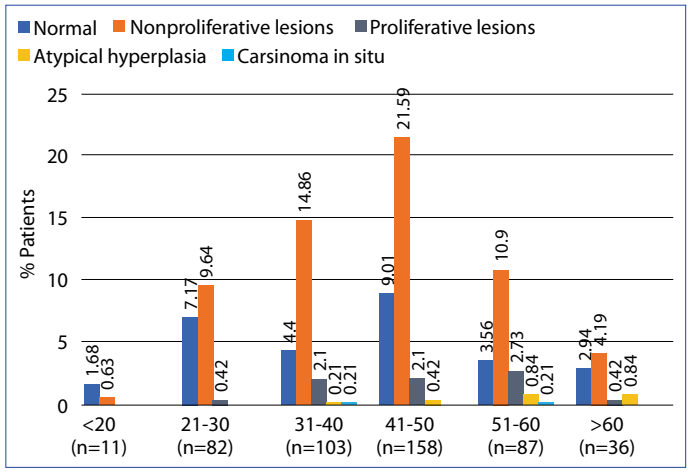

Figure 2. Incidence of histopathological findings by ages.

NPBL, which do not increase breast cancer risk. It was seen that NPBL and PBL peaked in the fifth decade and then decreased. The incidences of PBL, AH and CIS were respectively calculated as 5.7%, 2% and 0.4%. Histopathological images of breast lesions are shown in Figure 4.

Atypical hyperplasia was seen at an older age than PBL (p=0.004). A positive family history of breast cancer accompanied AH cases more frequently (p=0.004). No statistically significant relationship was found between comorbidity factors, smoking and the occurrence of lesions (Table 2). Risk factors associated with PBL were determined as age (p=0.041) and family history (p=0.039). Similarly, risk factors associated with AH were found as age (p=0.045) and family history (p=0.009) (Table 3). The mean age and BMI of two patients diagnosed with CIS were respectively 47.50±16.26 and 29.20±0.84. Ductal CIS was found in one breast, who had a positive family history of breast cancer. Lobular CIS was found in both breasts of one patient in the fifth decade. In the histopathology of the patient with ductal CIS, nuclear grade 2, surgical margins were negative and microinvasion was not detected. 35-year-old patient was referred to oncology and radiotherapy was applied. Surgical margins were negative in the patient with lobular CIS and no additional treatment protocol was applied. Active surveillance with annual mammography and ultrasound was recommended for both patients. No local recurrence was detected these patients.

There was no statistically significant relationship between the BI-RADS classification and histopathological findings of the patients. 15.7% of patients had BI-RADS 0 (p=0.215),

Table 1. Distribution of the 719 different histopathological diagnoses from 954 breast specimens by age

	Age						
	<20	21-30	31-40	41-50	51-60	>60	Total
Pathologic findings							
Normal	9	35	23	45	21	15	148
Nonproliferative lesions	4	66	12	154	97	19	470
Proliferative lesions		2	12	16	20	5	55
Fibroadenoma (with complex features)			4	9	11	3	27
Moderate or florid hyperplasia		2	2	4	7	2	17
Sclerosing adenosis			3		2		5
Solitary papilloma without coexisting atypical hyperplasia			3	3			6
Atypical hyperplasia				2	9	4	15
Atypical ductal hyperplasia				2	2	1	5
Atypical lobular hyperplasia					7	3	10
Carcinoma in situ			1		2		3
Ductal carcinoma in situ			1				1
Lobular carcinoma in situ					2		2
Total	14	110	169	227	152	48	719*

*Each specimen provides at least one histopathological finding.

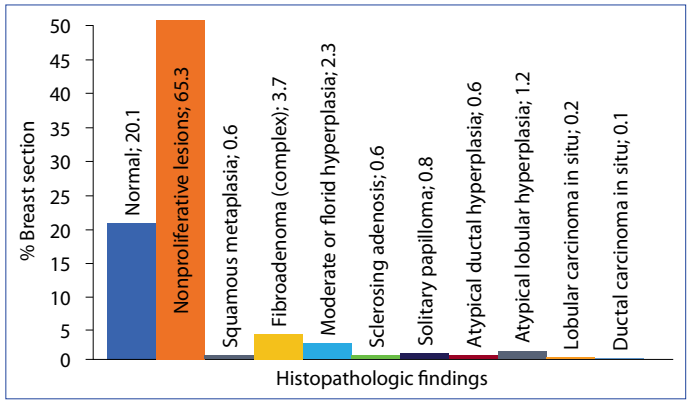

Figure 3. Incidence of histopathologic findings from specimens.

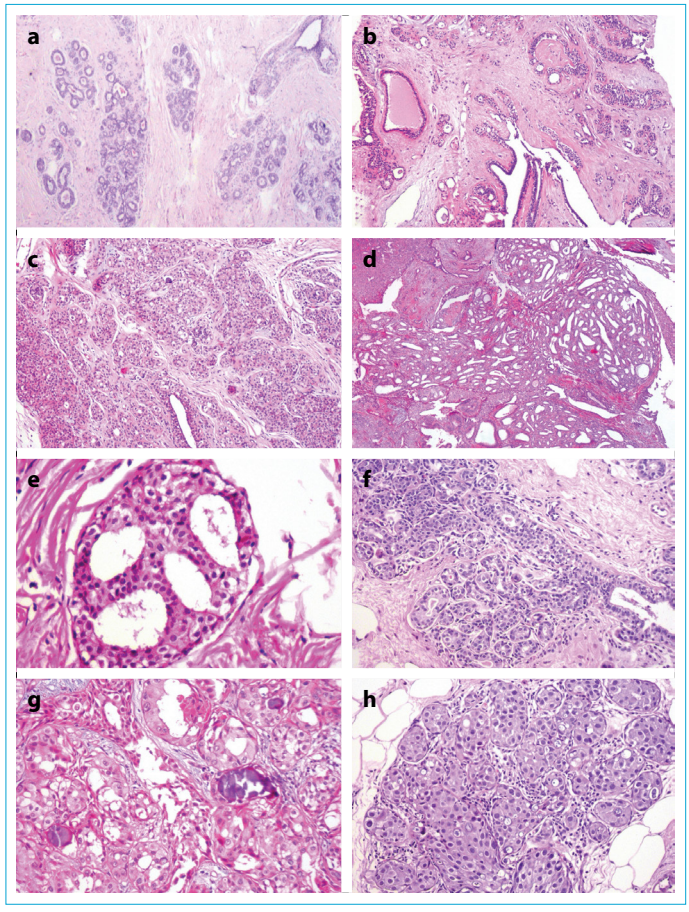

Figure 4. Histopathological images of breast lesions. **(a)** Normal breast parenchyma, Terminal ductal lobular unit (H&E, X40). **(b)** Fibroadenoma with complex features (H&E, X100). **(c)** Sclerosing adenosis with focal microcalcification (H&E, X100). **(d)** Solid intraductal papilloma intertwined with simple hyperplasia and adenosis (H&E, X100). **(e)** Fibrous breast parenchyma with atypical ductal hyperplasia focus (H&E, X200). **(f)** Atypical lobular hyperplasia (H&E, X100). **(g)** Ductal carcinoma in situ, Intermediate grade (Grade II) (H&E, X200). **(h)** Lobular carcinoma in situ (HE, X200).

63.5% had BI-RADS 1 (p=0.546), 18.7% had BI-RADS 2 (p=0.361) and 10% had BI-RADS 3 (p=0.634). Both patients with CIS had a BI-RADS 3.

Table 2. Analysis of risk factors for proliferative lesions and atypical hyperplasias

	Pathologic Findings		p
	Proliferative lesions (n=37)	**Atypical hyperplasias (n=11)**	
Yaş (Mean±SD)	**46.54±11.02**	**57.45±8.99**	**0.004**
BMI (Mean±SD)	28.72±2.33	28.07±2.24	0.419
Comorbity			
Hypertension	1	2	0.065
Asthma	1		0.586
Diabetes	1	1	0.357
Smoking	2	2	0.183
Family history	**3**	**5**	**0.004**

Discussion

According to the National Cancer Institute's (NCI) data, the median age at which women were diagnosed with breast cancer was 61 and 89.1% of them were above 45 years of age.[7] In this study, the mean age of patients undergoing reduction mammoplasty in the last seven years was found 42.4 and 74% of patients were under 50 years of age. Blansfield et al. reported in their study that the mean age of patients undergoing reduction mammoplasty was 37, Ayhan et al. found 35.9 and Pitanguy et al. found 34.9.[8-10] Since reduction mammoplasty is frequently performed in the third and fourth decades, it provides a screening tool for breast cancer at early ages and an opportunity to perform a random biopsy from the breast.

Among the histopathological findings, 28.7% of patients had normal breast tissue (no morphologic change of glandular, ductal and connective tissue) and 60.7% had NPBL (morphologic change of glandular, ductal and interstitial tissue but no increase in malignancy risk). The lesions forming a risk for breast cancer development in this study were determined as 10.4%. Albayrak et al. reported that these lesions represented 5.6% of reduction mammoplasty specimens in their study, while Merkkola-von Schantz et al. and Acevedo et al. reported 10% and 6.26% respectively.[5, 11, 12] The difference in these values in the literature is explained with the difference of the surgeon, pathologist, the number of patients and patient bias. Moreover, the number of tissue sample for histopathological evaluation is also a factor affecting the incidence rate. In 2009, Ambaye et al.[13] performed a prospective study in which they compared the number of tissue sections analyzed with the rate of pathological findings. They analyzed 12 breast tissue sections in total, which included one sample from breast skin. They reported high-risk lesion rate as 12.4% and showed that the

Table 3. Multivariable logistic regression analysis for proliferative lesions and atypical hyperplasia

	Proliferative lesions			Atypical hyperplasias		
Risk Factor	**OR**	**95% CI**	**p**	**OR**	**95% CI**	**p**
Age (Mean±SD)	**0.879**	**0.777-0.995**	**0.041**	**1.278**	**1.006-1.629**	**0.045**
BMI (Mean±SD)	1.413	0.018-12.555	0.121	0.484	0.244-0.961	0.132
Comorbidity						
Hypertension	0.477	0.077-819.992	0.657	1.586	0.038-65.647	0.808
Asthma	3.489	0.000-	1.000	0.000	0.000-	1.0
Diabetes	0.785	0.008-72.995	0.916	2.063	0.006722.524	0.809
Smoking	0.118	0.005-2.755	0.184	23.486	0.348-1585.616	0.142
Family history	**0.045**	**0.006-0.361**	**0.039**	**52.884**	**2.633-1062.207**	**0.009**

CI: Confidence interval; BMI: Body mass index.

probability of detecting a pathological finding increased proportionally with the number of tissue sections analyzed. In another study, in 2017, Ambaye et al.[14] showed that gross evaluation of breast tissue samples was sufficient under 35 years, but they emphasized the necessity of increasing tissue sampling for patients over 40 years of age.

PBL consists of fibroadenoma with complex features (a prolific stroma of connective fibrosis and one epithelial element accompanying at least one of the lesions, such as epithelial calcifications, apocrine metaplasia, sclerosing adenosis, and large cysts), moderate or florid hyperplasia (least five cell layers above the basement membrane and bridging and distention of the ducts), sclerosing adenosis (increased fibrous tissue and interspersed glandular cells), solitary papilloma without coexisting atypical hyperplasia (growing structure from the canal wall to the lumen around the fibrovascular core) according to CAPC.[6, 10, 15-17] The incidence of PBL, which increases slightly the risk of breast cancer, was found 7.7%. When evaluated according to specimens, complex fibroadenomas were the most common lesion with 3.7%. The mean age of the patients diagnosed with PBL was 46.5. Besides, age and family history were found as risk factors. Clark et al.[18] found a similar incidence rate in a study in which they evaluated 562 patients. The most common lesion in their study was moderate or florid hyperplasia, which constituted 7.3% of specimens. As in this study, age and family history were emphasized as being risk factors.

AH is uniform cells and loss of the apical-basal cellular orientation in the duct or lobule.[19] In this study, the incidence of AH (uniform cells and loss of the apical-basal cellular orientation in the duct or lobule) was found at 2.3%. The mean age of patients diagnosed with AH was 57.4 and it peaked in the fifth decade. When evaluated according to specimens, atypical ductal hyperplasia (ADH) was found 0.6%, while atypical lobular hyperplasia was found at 1.2%. Thomas et al.[20] reported in their meta-analysis, studying biopsy specimens, that the incidence of AH was 3.4%. Genco et al.[21] found in their study analyzing 10340 specimens that the incidence of ADH and ALH were 0.72% and 0.85%,respectively.

Ductal CIS is characterized histopathologically by the atypical proliferation of papillary epithelium intraductally. Lobular CIS, on the other hand, is the lesion manifested by proliferation in one or more terminal channels or channels.[19] The incidence of CIS in patients undergoing bilateral reduction mammoplasty varies between 0.3% and 2.6%.[5, 12, 22, 23] In this study, CIS was diagnosed in two patients; the incidence rate was 0.4%. Albayrak et al. and Bondeson et al.[11, 24] reported lobular CIS incidence rates as 11.1% and 8%, respectively; all the cases were detected over 40 years of age. The incidence of ductal CIS in patients undergoing bilateral reduction mammoplasty is lower than lobular CIS and varies between 0.2% and 0.5%.[12, 25, 26] In this study, lobular CIS was lower than the result in the literature.

Obesity is a risk factor increasing breast cancer, especially in the postmenopausal period.[27] When obesity, which increases breast cancer risk 1-2.5-fold, combines with family history, the overall risk significantly increases.[28] Insulin-like growth factor and insulin have both mitogenic activity over normal and neoplastic breast epithelial cells. Serum leptin levels, which increase with obesity, directly increase the secretion of insulin. Furthermore, insulin and leptin increase the risk of estrogen receptor-positive breast cancer in postmenopausal women using increasing estrogen and sex hormone-binding globulin levels.[27, 29]

The mean BMI of patients was 28.4. Thus, several patients are in the pre-obesity category according to the World Health Organization obesity classification. Therefore, it can be predicted that high-risk lesions may further increase the likelihood of breast cancer in obese patients with breast hypertrophy compared to the normally weighted population. Reduction mammoplasty was shown to decrease insulin

resistance by decreasing leptin and increasing adiponectin levels.[30, 31] According to these data, it can be deduced that reduction mammoplasty may decrease breast cancer risk by decreasing the perturbations in the insulin signal transduction pathways. In addition, it has been previously shown that reduction mammoplasty can decrease breast cancer risk by the excision of potential malignancy foci.[22-34]

Although there is no consensus on routine screening of patients preoperatively to reduction mammoplasty, it is recommended to evaluate patients over 40 years with a preoperative mammogram.[35] Meanwhile, no correlations have been found in many studies between postoperatively detected occult high-risk lesions and preoperative mammogram.[5, 36, 37] No statistically significant relationships were found between high-risk histopathological findings and BI-RADS scores in this study. Therefore, it can be deduced that reduction mammoplasty may help detect occult high-risk lesions.

In this study, occult breast cancer was not detected in reduction mammoplasty specimens. However, occult breast cancer after reduction mammoplasty can be seen among 0.7% and 0.9%.[36, 37] Re-orientation of the breast is impaired due to the anatomical and structural change of breast tissue after reduction mammoplasty. This situation makes it difficult to follow-up with both clinical and imaging methods. In the presence of high risk-lesions that increase the risk of breast cancer in postoperative specimens, conditions, such as positive family history and the presence of intense breast parenchyma require close monitoring. With the regression of postoperative changes in the breast tissue, it is recommended to repeat imaging methods according to the age and breast structure of the patient in the sixth month. In addition, preoperative and postoperative imaging methods should be evaluated together, and the patient should be followed closely.[38]

Breast tissue specimens obtained from reduction mammoplasty are classified according to CAPC classification and criteria of Dupont and Page.[6, 18, 23, 39] CAPC classification is more extensive and provides more data for incidence studies. Besides, it also includes the criteria of Dupont and Page. In this study, CAPC classification was preferred to present more detailed incidence rates of data obtained from reduction mammoplasties.

This study has some limitations. Firstly, this is a retrospective study. Secondly, histopathological findings may have been interpreted differently from one pathologist to another, and it was not possible to determine the maximum section number analyzed from one breast tissue sample. Thus, the data in this study represent the minimum possible incidence. Thirdly, the mean follow-up period of patients was 3.8 years, and no new high-risk lesions or breast cancer diagnoses were made in this period. However, this could change with a longer follow-up period.

Conclusion

Although preoperative breast cancer screening methods are used before the reduction of mammoplasty, high-risk lesions may be encountered afterwards. One of the biggest advantages of reduction mammoplasty in addition to psychophysiological recovery is breast cancer risk reduction.

Disclosures

Ethics Committee Approval: This study was approved by the ethics committee of our institution (11.02.2020; approval number: 2670).

Peer-review: Externally peer-reviewed.

Conflict of Interest: No conflict of interest is declared by the authors.

Financial Disclosure: The authors declare that this study received no financial support.

Authorship Contributions: Concept – S.B., S.S.S.; Design – S.B., A.C.A.; Supervision – S.K., R.U.; Materials – A.C.A., S.B.; Data collection &/or processing – S.B., R.U., A.C.A.; Analysis and/or interpretation – S.B., A.C.A., S.S.S.; Literature search – S.S.S., S.B., C.O.; Writing – S.B., C.O., A.C.A.; Critical review – S.K., S.B., S.S.S.

References

1. Eggert E, Schuss R, Edsander-Nord A. Clinical outcome, quality of life, patients' satisfaction, and aesthetic results, after reduction mammaplasty. Scand J Plast Reconstr Surg Hand Surg 2009;43:201–6.
2. Findikcioglu K, Findikcioglu F, Bulam H, Sezgin B, Ozmen S. The impact of breast reduction surgery on the vertebral column. Ann Plast Surg 2013;70:639–42.
3. Sood R, Mount DL, Coleman JJ 3rd, Ranieri J, Sauter S, Mathur P, et al. Effects of reduction mammaplasty on pulmonary function and symptoms of macromastia. Plast Reconstr Surg 2003;111:688–94.
4. Ameican Society of Plastic Surgeons. ASPS plastic surgery statistics report 2018. Available at: https://www.plasticsurgery.org/documents/News/Statistics/2018/plastic-surgery-statistics-full-report-2018.pdf. Accessed Jan 06, 2021.
5. Merkkola-von Schantz PA, Jahkola TA, Krogerus LA, Hukkinen KS, Kauhanen SM. Should we routinely analyze reduction mammaplasty specimens? J Plast Reconstr Aesthet Surg 2017;70:196–202.
6. Fitzgibbons PL, Henson DE, Hutter RV. Benign breast changes and the risk for subsequent breast cancer: an update of the 1985 consensus statement. Cancer Committee of the College of American Pathologists. Arch Pathol Lab Med 1998;122:1053–5.
7. Percent of new cases by age group: Female breast cancer. Available at: http://seer.cancer.gov/statfacts/html/breasthtml. Ac-

cessed Feb 1, 2016.
8. Blansfield JA, Kukora JS, Goldhahn RT Jr, Buinewicz BR. Suspicious findings in reduction mammaplasty specimens: review of 182 consecutive patients. Ann Plast Surg 2004;52:126¬–30.
9. Ayhan S, Başterzi Y, Yavuzer R, Latifoğlu O, Cenetoğlu S, Atabay K, et al. Histologic profiles of breast reduction specimens. Aesthetic Plast Surg 2002;26:203–5.
10. Pitanguy I, Torres E, Salgado F, Pires Viana GA. Breast pathology and reduction mammaplasty. Plast Reconstr Surg 2005;115:729–34.
11. Albayrak A, Mesci CG, Güler G. Histopathological findings obtained from reduction mammoplasty specimens. Turk J Med Sci 2015;45:1374–9.
12. Acevedo F, Armengol VD, Deng Z, Tang R, Coopey SB, Braun D, et al. Pathologic findings in reduction mammoplasty specimens: a surrogate for the population prevalence of breast cancer and high-risk lesions. Breast Cancer Res Treat 2019;173:201–7.
13. Ambaye AB, MacLennan SE, Goodwin AJ, Suppan T, Naud S, Weaver DL. Carcinoma and atypical hyperplasia in reduction mammaplasty: increased sampling leads to increased detection. A prospective study. Plast Reconstr Surg 2009;124:1386–92.
14. Ambaye AB, Goodwin AJ, MacLennan SE, Naud S, Weaver DL. Recommendations for pathologic evaluation of reduction mammoplasty specimens: a prospective study with systematic tissue sampling. Arch Pathol Lab Med 2017;141:1523–8.
15. Brown TA, Wall JW, Christensen ED, Smith DV, Holt CA, Carter PL, et al. Atypical hyperplasia in the era of stereotactic core needle biopsy. J Surg Oncol 1998;67:168–73.
16. Jensen RA, Page DL, Dupont WD, Rogers LW. Invasive breast cancer risk in women with sclerosing adenosis. Cancer 1989;64:1977–83.
17. Orr B, Kelley JL 3rd. Benign breast diseases: evaluation and management. Clin Obstet Gynecol 2016;59:710–26.
18. Clark CJ, Whang S, Paige KT. Incidence of precancerous lesions in breast reduction tissue: a pathologic review of 562 consecutive patients. Plast Reconstr Surg 2009;124:1033–9.
19. Viana GA, Pitanguy I, Torres E. Histopathological findings in surgical specimens obtained from reduction mammaplasties. Breast 2005;14:242–8.
20. Thomas ET, Del Mar C, Glasziou P, Wright G, Barratt A, Bell KJL. Prevalence of incidental breast cancer and precursor lesions in autopsy studies: a systematic review and meta-analysis. BMC Cancer 2017;17:808.
21. Genco IS, Steinberg J, Caraballo Bordon B, Tugertimur B, Dec W, et al. The rate of incidental atypical and malignant breast lesions in reduction mammoplasty specimens. Histopathology 2020;76:988–96.
22. Desouki MM, Li Z, Hameed O, Fadare O, Zhao C. Incidental atypical proliferative lesions in reduction mammoplasty specimens: analysis of 2498 cases from 2 tertiary women's health centers. Hum Pathol 2013;44:1877–81.
23. Dreifuss SE, Landfair AS, De La Cruz C. A risk-stratified comparison of high-risk findings in reduction mammoplasty. Ann Plast Surg 2018;81:36–8.
24. Bondeson L, Linell F, Ringberg A. Breast reductions: what to do with all the tissue specimens? Histopathology 1985;9:281–5.
25. Ishag MT, Bashinsky DY, Beliaeva IV, Niemann TH, Marsh WL Jr. Pathologic findings in reduction mammaplasty specimens. Am J Clin Pathol 2003;120:377–80.
26. Kakagia D, Fragia K, Grekou A, Tsoutsos D. Reduction mammaplasty specimens and occult breast carcinomas. Eur J Surg Oncol 2005;31:19–21.
27. Stephenson GD, Rose DP. Breast cancer and obesity: an update. Nutr Cancer 2003;45:1–16.
28. Carpenter CL, Ross RK, Paganini-Hill A, Bernstein L. Effect of family history, obesity and exercise on breast cancer risk among postmenopausal women. Int J Cancer 2003;106:96–102.
29. Magoffin DA, Weitsman SR, Aagarwal SK, Jakimiuk AJ. Leptin regulation of aromatase activity in adipose stromal cells from regularly cycling women. Ginekol Pol 1999;70:1–7.
30. Uzun H, Bitik O, Baltu Y, Sönmez Ç, Öztürk Kaymak A. The effects of reduction mammaplasty on serum leptin levels and insulin resistance. Int J Endocrinol 2015;2015:719824.
31. Vinci V, Valaperta S, Klinger M, Montanelli A, Specchia C, Forcellini D, et al. Metabolic implications of surgical fat removal: increase of adiponectin plasma levels after reduction mammaplasty and abdominoplasty. Ann Plast Surg 2016;76:700–4.
32. Baasch M, Nielsen SF, Engholm G, Lund K. Breast cancer incidence subsequent to surgical reduction of the female breast. Br J Cancer 1996;73:961–3.
33. Brown MH, Weinberg M, Chong N, Levine R, Holowaty E. A cohort study of breast cancer risk in breast reduction patients. Plast Reconstr Surg 1999;103:1674–81.
34. Kececi Y, Tasli FA, Yagcı A, Sır E, Canpolat S, Vardar E. Histopathologic findings in breast reduction specimens. J Plast Surg Hand Surg 2014;48:122–5.
35. Klement KA, Hijjawi JB, Neuner J, Kelley K, Kong AL. Discussion of preoperative mammography in women undergoing reduction mammaplasty. Breast J 2019;25:439–43.
36. Slezak S, Bluebond-Langner R. Occult carcinoma in 866 reduction mammaplasties: preserving the choice of lumpectomy. Plast Reconstr Surg 2011;127:525–30.
37. Colwell AS, Kukreja J, Breuing KH, Lester S, Orgill DP. Occult breast carcinoma in reduction mammaplasty specimens: 14-year experience. Plast Reconstr Surg 2004;113:1984–8.
38. Tang R, Acevedo F, Lanahan C, Coopey SB, Yala A, Barzilay R, et al. Incidental breast carcinoma: incidence, management, and outcomes in 4804 bilateral reduction mammoplasties. Breast Cancer Res Treat 2019;177:741–8.
39. Dupont WD, Page DL. Risk factors for breast cancer in women with proliferative breast disease. N Engl J Med 1985;312:146–51.