Original Article

CYP4F22 Gene Mutations in Patients with Autosomal Recessive Congenital Ichthyosis: Identification of Two Novel Mutations

Esra Arslan Ateş, Hüseyin Onay[1], Ilgen Ertam[2], Esra Ataman[3], Filiz Hazan[4], Asude Durmaz[1], Tugrul Dereli[2], Ferda Özkinay[1]

Department of Medical Genetics, Marmara University Pendik Training and Research Hospital, Istanbul, Departments of [1]Medical Genetics and [2]Dermatology, Ege University Faculty of Medicine, [3]Department of Medical Genetics, Dokuz Eylul University Faculty of Medicine, [4]Department of Medical Genetics, Dr. Behcet Uz Children's Hospital, Izmir, Turkey

Abstract

Background: Autosomal recessive congenital ichthyosis (ARCI) is a genetically heterogeneous keratinization disorder, which is clinically classified into five main forms: Lamellar ichthyosis, congenital ichthyosiform erythroderma, harlequin ichthyosis, self-healing collodion baby, and bathing suit ichthyosis. Mutations in *TGM1, ABCA12, ALOX12B, ALOXE3, NIPAL4, CYP4F22, PNPLA1, LIPN,* and *CERS3* genes have been described in patients with ARCI. However, in 20% of the ARCI patients, the genetic defect remains unknown. **Materials and Methods:** In this study, we investigated the mutations in the *CYP4F22* gene in ARCI patients who do not have mutations in two common ARCI genes, *NIPAL4* and *TGM1.* Twenty-two patients diagnosed with ARCI and having no mutations in *TGM1* and *NIPAL4* genes were included in the study. Their *CYP4F22* genes were sequenced using the Sanger sequencing method. **Results:** In 5 of 22 (22.7%) ARCI patients, four different mutations, of which two were previously reported, were found. The two novel mutations were c.976C> T and c.1189C> T. The c.727C> T and c.1303C>T mutations were previously reported. **Conclusions:** This study expands the *CYP4F22* mutation spectrum and to provide more accurate genetic counseling for patients at risk.

Keywords: Autosomal recessive, CYP4F22, genetic diseases/mechanisms, ichthyosis, sanger sequencing

Introduction

Ichthyosis is a group of cornification disorders, which affects a part or all of the skin. It is characterized by widespread dryness and scaling. A number of etiological factors (drugs, malignancies, and autoimmune diseases) may be responsible for acquired ichthyosis.[1] Genetically determined or hereditary ichthyosis shows high genetic heterogeneity.[2] The most common hereditary form is ichthyosis vulgaris caused by the mutations in *FLG* gene.[3] This is followed by X-linked recessive ichthyosis (XLRI) with a prevalence of 1/6000 males.[4] Another form of hereditary ichthyosis is autosomal recessive congenital ichthyosis (ARCI) which affects 1 in 300,000 newborns worldwide.[5] The prevalence is higher in some populations due to the founder effect. ARCI patients are affected *in utero* and show clinical findings, such as collodion membrane, at birth.[6] There are three major clinical forms of ARCI: Lamellar ichthyosis (LI), congenital ichthyosiform erythroderma (CIE), and harlequin ichthyosis (HI). HI, the most severe form, shows hyperkeratosis characterized by thick plaques separated by fissures and is caused by large deletions or mutations resulting in premature stop codon in *ABCA12* gene.[7,8] LI patients present with large, dark, plate-like scales covering the whole body surface, eclabium, and ectropion.[6] CIE patients show whitish, fine, semi-adherent scales with erythrodermia.[9] The major problems in the last two forms of ARCI are the risk of severe dehydration and infections leading to morbidity and mortality.[10] Both forms of ARCI are caused by the mutations in eight different genes in 80% of patients: *TGM1* and *NIPAL4* gene mutations account for 50% of ARCI patients, while *ALOX12B, ALOXE3, CYP4F22, ABCA12, PNPLA1, LIPN,* and *CERS3* gene mutations are responsible

Submission: 12-08-2020 **Revision:** 31-08-2020
Acceptance: 22-09-2020 **Web Publication:** XXX

Access this article online

Quick Response Code:

Website: www.tjdonline.org

DOI: 10.4103/tjd.tjd_91_20

Address for correspondence: Dr. Esra Arslan Ateş, Department of Medical Genetics, Marmara University Pendik Training and Research Hospital, Pendik, Istanbul, Turkey.
E-mail: esraarslan.md@gmail.com

This is an open access journal, and articles are distributed under the terms of the Creative Commons Attribution-NonCommercial-ShareAlike 4.0 License, which allows others to remix, tweak, and build upon the work non-commercially, as long as appropriate credit is given and the new creations are licensed under the identical terms.

For reprints contact: WKHLRPMedknow_reprints@wolterskluwer.com

How to cite this article: Arslan Ateş E, Onay H, Ertam I, Ataman E, Hazan F, Durmaz A, *et al*. CYP4F22 gene mutations in patients with autosomal recessive congenital ichthyosis: Identification of two novel mutations. Turk J Dermatol 2020;XX:XX-XX.

for the rest of patients.[11-14] Eight percent of patients with ARCI have mutations in *CYP4F22* gene located at 19p13.1.12. The *CYP4F22* gene encodes for a protein that is a member of cytochrome P450 family and plays a role in the fatty acid metabolic pathway.[15,16]

In this study, *CYP4F22* mutations were investigated in 22 patients diagnosed with ARCI and previously shown that they did not have *TGM1* and *NIPAL4* mutations. In five patients four different mutations, two of them being novel were defined.

Materials and Methods

The present study was approved by the institutional ethics review board of our institution (Decision Number: 11-6.1/3). Twenty-two patients recruited from Ege University Faculty of Medicine, Department of Dermatology and Department of Medical Genetics were included in the study. Medical history, physical examination, and pedigree analysis were evaluated to determine the heredity pattern and ichthyosis type. The type of ichthyosis was verified histopathologically only when the patient's consent was provided. Twenty-two patients (aged between 5 months and 36 years) studied had a pedigree suggestive of ARCI and did not have a mutation in *TGM1* and *NIPAL4* genes which are the two most common ARCI causing genes. These two genes are routinely tested as a first step in ARCI patients in our laboratory. In this study, 22 patients were sequenced for the gene *CYP4F22* described as an ARCI causing gene previously. Parents of all patients having *CYP4F22* mutations were screened for the mutations. A hundred control chromosomes were evaluated for novel mutations.

Molecular genetic analysis

DNA isolation was performed from peripheral blood lymphocytes using MagNa Pure LC DNA Isolation Kit I (Product No: 0300039900001; Roche, USA). In 22 patients, all exons and exon-intron boundaries of *CYP4F22* gene were sequenced by ABI 3130 using the instrument protocols. When a mutation was detected, parents were analyzed. The primers used for *CYP4F22* gene amplification are listed in Table 1. All variations detected were evaluated using Ensembl Genome Bowser and HGMD mutation database.

In slico analysis

Genomic variations which had not been reported previously were evaluated by protein sorting intolerant from tolerant (SIFT) and PolyPhen.

Results

This study included 22 ARCI patients who do not have mutations in their *TGM1* and *NIPAL4* genes. In 5 (22.7%) out of 22 ARCI patients, homozygous *CYP4F22* mutations were detected. Two patients had a known mutation, c.1303C<T and one another known mutation c.727C>T, whereas two patients had two different novel homozygous mutations [Figure 1 and Table 2]. Novel mutations were not detected in 100 healthy control chromosomes. Parental consanguinity was declared in 4 of 5 patients. One patient had parents from a small village, but no consanguinity was described. All parents were heterozygous for the mutations detected in their children. Clinical features and the mutations detected in these five patients are given in Table 2. Five ARCI patients having *CYP4F22* mutations presented with palmoplantar involvement, ectropion, and erythema [Figure 2]. One had a pigmentation defect in the retina. Ocular examinations of other patients were normal, and one of them had been discussed in another study.[17] A skin biopsy was performed in three mutation-positive patients, one patient showed hyperkeratosis, parakeratosis and thickened stratum corneum and one patient showed acanthosis, spongiosis in the epidermis, and perivascular eosinophilic infiltration. One patient histopathological examination showed nonspecific findings.

Discussion

ARCI is a rare form of ichthyosis with an estimated prevalence of 1:300,000 newborns.[5] It is expected more common in populations with a high rate of consanguineous marriages such as Turkey.

In this study, parents of four patients with homozygous *CYP4F22* gene mutations were consanguineous. In the studies by Lefèvre *et al*. and Lugassy *et al*., high parental consanguinity rates in ARCI patients were also reported.[15,18]

Table 1: Primers used for *CYP4F22* gene amplification

Exon	Forward primer	Reverse primer	PCR product (bp)	Annealing temperature (F/R) °C
1	5'GTGTGCTGGGAACCTTCTGT3'	5'AAACTGCTTGCCCTCTCTGA3'	492	56
2	5'AGCCAACTGCCTGAAATCAT3'	5'TCAAATGACCCTTCCTCTGG3'	374	56
3	5'TGGATGACAGAGCAAGACTCC3'	5'TCCACTTGTCACCTTTGCTG3'	269	56
4	5'GGCTGGGGCTTTAGAGAAGA3'	5'AGCCTAACAAGGACCCGACT3'	382	56
5	5'GGTCCAGGCTCCAACTCAT3'	5'TCCCATAGGCCAGAGTTGTC3'	388	56
6	5'AATGGGGACAGGAGGCTTAT3'	5'CACCACGCCTAATGGAGTTT3'	457	56
7	5'TGCAGTTAGCCGAGATTGTG3'	5'TGGATGTTGTGTCGTGACCT3'	373	56
8	5'TGTTTGAGGGTGAGGATGTG3'	5'CCCCCATTTTGTAGCTGAAG3'	398	56
9-10	5'GTGGCTCGGCCTCTAGTTAT3'	5'AAATGGCTAAATGCGGAGTG3'	1260	55
11-12	5'TGCTCCCCATCCATCTTTAC3'	5'CTATGCCCTCGGGATCTTTG3'	987	55

PCR: Polymerase chain reaction

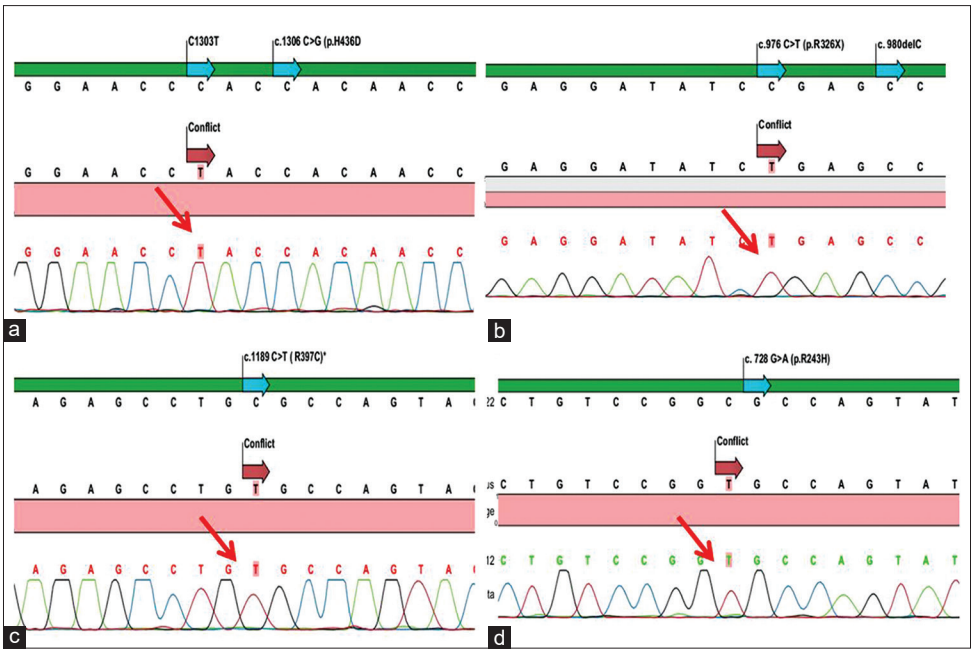

Figure 1: Electropherogram of detected CYP4F22 gene mutations. (a) c.1303C>T(H435Y) homozygous mutation (b) c.976C>T(p.R326X) homozygous mutation (c) c.1189C>T(p.R397C) homozygous mutation (d) c.727C>T(p.R243C) homozygous mutation

Table 2: Clinical findings of autosomal recessive congenital ichthyosis patients with *CYP4F22* gene mutations

	Case 1	Case 2	Case 17	Case 20	Case 22
Involvement of the body region	Periumbilical region and extremities extensor surfaces	Face and extremities extensor surfaces	Suprapubic lower umbilical region and extremities extensor surfaces	Face and extremities extensor surfaces	Face, body and extremities extensor surfaces
Scaling properties	Whitish, semiadherent scaling	Gray-Whitish, semiadherent scaling	Brown, adherent, fine, lamellar, and scaling	Gray-whitish and semiadherent scaling	Whitish, semi adherent scaling
Erythema	+	+	+ (at birth)	+	+
Collodion membrane	-	-	+	-	+
Ocular findings	Ectropion (at birth)	Ectropion	Ectropion	Ectropion and dry eyes	Ectropion and retinal pigment defect
Eclabium	+ (at birth)	-	-	-	+ (at birth)
Palmoplantar involvement	Hyperlinearity	Hyperkeratosis hyperlinearity	Hyperlinearity	Hyperlinearity	Hyperkeratosis
Scalp involvement	-	+	-	-	-
Nail involvement	-	-	+ (hyperkeratosis)	-	-
An/hypohydrosis	-	-	-	-	-
Systemic involvement	-	-	-	-	-
Histopathologic	Nonspecific	-	Hyperkeratosis, parakeratosis, and thickening of the stratum corneum	Acanthosis and spongiosus, dermal lymphocyte infiltration, and perivascular edema	-
Mutation	c.1303C>T/ c.1303C>T*	c.1303C>T/1303C>T*	c.976C>T/c.976C>T**	c.1189C>T/c.1189C>T**	c.727C>T/ c.727C>T*

*Known mutation, reported by LeFevre *et al*. and Pigg *et al*.,[15,20] **Novel mutations, reported in this study

Mutations in eight different genes in almost 80% of ARCI patients have been identified so far. Among these genes, *CYP4F22* gene mutations were detected in 8% of all ARCI patients.[19] *TGM1* and *NIPAL4* genes have been described

Figure 2: Clinical findings of case 20. (a) Erythema and fine scaling on the face. (b and c) Palmoplantar keratoderma and hyperlinearity

as the two most common mutated genes in ARCI patients. Therefore, these two genes were analyzed in our ARCI patients in the first step. In our study population, *CYP4F22* gene was responsible for the 22.7% (5/22) of ARCI patients who did not have mutations in *TGM1* and *NIPAL4* genes.

Homozygous c.1303C>T mutation defined in our two patients was reported by Lefèvre *et al*. previously.[15] Our two patients were from the Mediterranean Region of Turkey. The cases reported by LeFevre were also from the coastal Mediterranean region. Therefore, there may be a founder effect for this mutation.

In one patient, we detected homozygous c.727C>T (p. Arg243Cys) mutation which was reported previously in compound heterozygous state with a frameshift variant in an ARCI patient by Pigg *et al*.[20]

One of our patients was homozygous for the novel c.976C > T (p. Arg326X) mutation which causes stop codon in exon 7. The other novel homozygous mutation (c.1189C > T) affects well conserved arginine residues in ichtyn protein [Figure 3]. These two mutations were not reported previously and not detected in 100 control chromosomes. In addition, PolyPhen and SIFT analysis indicated that they were damaging mutations, which supports their causative roles.

Phenotypic features of our patients were very similar to the features of previously reported patients with *CYP4F22* mutations. In the study by Lefèvre *et al*., patients carrying *CYP4F22* mutation presented with a CIE phenotype at birth, progressing later to a more lamellar aspect of the skin, and palmoplantar hiperlinearity which is the characteristic feature of this ichthyosis form.[15] In our study, a 21-year-old patient presented with LI at the time of examination; however, CIE was described during her newborn and childhood period.

It has been reported that most of the ARCI patients are not born as collodion babies.[15] Our two patients with *CYP4F22* mutations had a history of collodion baby at birth.

Ectropion, one of the most common features of ARCI, was noted in all of our patients and eclabium was observed in two patients at birth [Table 2]. As the ARCI is classified in nonsyndromic ichthyosis forms, systemic findings are not expected.[11] Our ARCI patients did not have systemic involvement either. Only one patient had defective retinal



```
XP_003644077.1     137   CRQEVRELLKGRNVEEIEWEDLSLLPFTTMCIKESLRLHPPVTAVSRRCT   186
NP_796281.1        362   CREEIQEVMKGRELEELDWDDLTQLPFTTMCIKESLRQFPPVTLISRRCT   411
XP_234837.3        362   CREEIQEVMKGRELEELDWDDLTQLPFTTMCIKESLRQFPPVTLISRRCT   411
XP_001111971.1     361   CREEIQEVMKGRELEELEWDDLTQLPFTTMCIKESLRQYPPVTLVSRQCT   410
NP_775754.2        361   CREEIQEVMKGRELEELEWDDLTQLPFTTMCIKESLRQYPPVTLVSRQCT   410
XP_512456.2        361   CREEIQEVMKGRELEELEWDDLTQLPFTTMCIKESLRQYPPVTLVSRQCT   410
XP_002688603.1     361   CREEIQEVMKGRELEELEWDDLTQLPFTTMCIKESLRQFPPVTLVSRRCT   410
XP_541984.2        361   CREEIQEVMKGRELEELEWDDLTQLPFTTMCIKESLRQFPPVTLVSRRCT   410
NP_001175823.1     368   ARTEVAAVCG-DHPPSA--DHLSKLTVLQMIIQETLRLYPPATLLPRMAF   414
NP_176882.1        348   VRDEVRQVCGQDGVPSV--EQLSSLTSLNKVINESLRLYPPATLLPRMAF   395
NP_198661.1        354   VREEVREVFGRNGLPSV--DQLSKLTSLSKVINESLRLYPPATLLPRMAF   401
```

Figure 3: Amino acid sequence of *CYP4F22* in different organisms (397. Arginine Residue)

pigmentation on ophthalmological examination. Retinal involvement has not been reported in ichthyosis patients previously. Among CYP 450 superfamily members, *CYP27A1* and *CYP11A1* have an important role in retinal cholesterol metabolism.[21] *CYP4V2* mutations have been shown in Bietti's crystalline corneoretinal dystrophy which is a form of hereditary retinal degeneration.[22] However, there has been no report about retinal expression of *CYP4F22* in the literature. Further studies are needed to determine whether it is coincidental or a part of the disease.

We were able to perform histopathological examination on three of five patients with *CYP4F22* mutations. One patient showed hyperkeratosis, parakeratosis, and thickened stratum corneum which were consistent with the histopathological findings seen in previously reported ARCI patients.[15] In another patient, biopsy showed acanthosis spongiosis in the epidermis and perivascular eosinophilic infiltration, which were interpreted in favor of atopic dermatitis. Atopic dermatitis has been reported to be associated with ichthyosis vulgaris and XLRI.[23,24] Oji *et al*. revealed that the corneodesmosin is the important for integrity of the epidermal barrier and loss of corneodesmosin causes peeling skin syndrome leading to atopy.[25] Regarding the data reported previously, it has been considered that atopic dermatitis could be a part of ichthyosis caused by *CYP4F22* mutations or perhaps, it is a coincidence in this case.

Conclusion

To the best of our knowledge, this is the first study investigating the molecular etiology of ichthyosis in the Turkish population and one of the few examples of molecular genetic screening of *CYP4F22* gene in ARCI patients. We have reported two novel *CYP4F22* gene mutations. Further studies will expand the mutation spectrum of *CYP4F22* gene mutations in the

etiopathogenesis of ARCI in the Turkish population. Further molecular analysis should be planned to reveal the molecular genetic etiology of the disease in ARCI patients who did not have mutations in the genes analyzed.

Declaration of patient consent

The authors certify that they have obtained all appropriate patient consent forms. In the form the patient (s) has/have given his/her/their consent for his/her/their images and other clinical information to be reported in the journal. The patients understand that their names and initials will not be published and due efforts will be made to conceal their identity, but anonymity cannot be guaranteed.

Financial support and sponsorship

This work was supported by Ege University Scientific Research Projects Coordination Unit.

Conflicts of interest

There are no conflicts of interest.

References

1. Patel N, Spencer LA, English JC 3rd, Zirwas MJ. Acquired ichthyosis. J Am Acad Dermatol 2006;55:647-56.
2. Akiyama M, Shimizu H. An update on molecular aspects of the non-syndromic ichthyoses. Exp Dermatol 2008;17:373-82.
3. Smith FJ, Irvine AD, Terron-Kwiatkowski A, Sandilands A, Campbell LE, Zhao Y, *et al*. Loss-of-function mutations in the gene encoding filaggrin cause ichthyosis vulgaris. Nat Genet 2006;38:337-42.
4. Kerr CB, Wells R. X-Linked Ichthyosis and the Xg Groups. Lancet 1964;2:1369-70.
5. Oji V, Traupe H. Ichthyoses: Differential diagnosis and molecular genetics. Eur J Dermatol 2006;16:349-59.
6. Williams ML, Elias PM. Heterogeneity in autosomal recessive ichthyosis. Clinical and biochemical differentiation of lamellar ichthyosis and nonbullous congenital ichthyosiform erythroderma. Arch Dermatol 1985;121:477-88.
7. Kelsell DP, Norgett EE, Unsworth H, Teh MT, Cullup T, Mein CA, *et al*. Mutations in ABCA12 underlie the severe congenital skin disease harlequin ichthyosis. Am J Hum Genet 2005;76:794-803.
8. Akiyama M. ABCA12 mutations and autosomal recessive congenital ichthyosis: A review of genotype/phenotype correlations and of pathogenetic concepts. Hum Mutat 2010;31:1090-6.
9. Fischer J, Faure A, Bouadjar B, Blanchet-Bardon C, Karaduman A, Thomas I, *et al*. Two new loci for autosomal recessive ichthyosis on chromosomes 3p21 and 19p12-q12 and evidence for further genetic heterogeneity. Am J Hum Genet 2000;66:904-13.
10. Kundu RV, Garg A, Worobec SM. Lamellar ichthyosis treated with tazarotene 0.1% gel. J Am Acad Dermatol 2006;55:S94-5.
11. Oji V, Tadini G, Akiyama M, Blanchet Bardon C, Bodemer C, Bourrat E, *et al*. Revised nomenclature and classification of inherited ichthyoses: Results of the First Ichthyosis Consensus Conference in Sorèze 2009. J Am Acad Dermatol 2010;63:607-41.
12. Israeli S, Khamaysi Z, Fuchs-Telem D, Nousbeck J, Bergman R, Sarig O, *et al*. A mutation in LIPN, encoding epidermal lipase N, causes a late-onset form of autosomal-recessive congenital ichthyosis. Am J Hum Genet 2011;88:482-7.
13. Grall A, Guaguère E, Planchais S, Grond S, Bourrat E, Hausser I, *et al*. PNPLA1 mutations cause autosomal recessive congenital ichthyosis in golden retriever dogs and humans. Nat Genet 2012;44:140-7.
14. Radner FP, Marrakchi S, Kirchmeier P, Kim GJ, Ribierre F, Kamoun B, *et al*. Mutations in CERS3 cause autosomal recessive congenital ichthyosis in humans. PLoS Genet 2013;9:e1003536.
15. Lefèvre C, Bouadjar B, Ferrand V, Tadini G, Mégarbané A, Lathrop M, *et al*. Mutations in a new cytochrome P450 gene in lamellar ichthyosis type 3. Hum Mol Genet 2006;15:767-76.
16. Lefèvre C, Bouadjar B, Karaduman A, Jobard F, Saker S, Ozguc M, *et al*. Mutations in ichthyin a new gene on chromosome 5q33 in a new form of autosomal recessive congenital ichthyosis. Hum Mol Genet 2004;13:2473-82.
17. Palamar M, Onay H, Ertam I, Ates EA, Dereli T, Ozkinay F, *et al*. Genotype and anterior segment phenotype in a cohort of turkish patients with lamellar ichthyosis. Ophthalmic Genet 2015;36:229-33.
18. Lugassy J, Hennies HC, Indelman M, Khamaysi Z, Bergman R, Sprecher E. Rapid detection of homozygous mutations in congenital recessive ichthyosis. Arch Dermatol Res 2008;300:81-5.
19. Fischer J. Autosomal recessive congenital ichthyosis. J Invest Dermatol 2009;129:1319-21.
20. Pigg MH, Bygum A, Gånemo A, Virtanen M, Brandrup F, Zimmer AD, *et al*. Spectrum of autosomal recessive congenital ichthyosis in scandinavia: clinical characteristics and novel and recurrent mutations in 132 patients. Acta Derm Venereol 2016;96:932-7.
21. Heo GY, Liao WL, Turko IV, Pikuleva IA. Features of the retinal environment which affect the activities and product profile of cholesterol-metabolizing cytochromes P450 CYP27A1 and CYP11A1. Arch Biochem Biophys 2012;518:119-26.
22. Xiao X, Mai G, Li S, Guo X, Zhang Q. Identification of CYP4V2 mutation in 21 families and overview of mutation spectrum in Bietti crystalline corneoretinal dystrophy. Biochem Biophys Res Commun 2011;409:181-6.
23. Nomura T, Akiyama M, Sandilands A, Nemoto-Hasebe I, Sakai K, Nagasaki A, *et al*. Specific filaggrin mutations cause ichthyosis vulgaris and are significantly associated with atopic dermatitis in Japan. J Invest Dermatol 2008;128:1436-41.
24. Al-Akloby OM. Association of atopic dermatitis with primary hereditary ichthyoses. Saudi Med J 2004;25:1097-9.
25. Oji V, Eckl KM, Aufenvenne K, Nätebus M, Tarinski T, Ackermann K, *et al*. Loss of corneodesmosin leads to severe skin barrier defect, pruritus, and atopy: Unraveling the peeling skin disease. Am J Hum Genet 2010;87:274-81.