TURKISH JOURNAL OF UROLOGY
Turk J Urol 2019; 45(4): 302-6 • DOI: 10.5152/tud.2018.08784
GENERAL UROLOGY
Original Article

Is there a difference in the number of interstitial cells, neurons, presence of fibrosis and inflammation in ureteropelvic junction tissues of patients with ureteropelvic junction obstruction with and without crossing vessels?

Hayriye Tatlı Doğan[1], Abdullah Erdem Canda[2], Bahri Gök[3], Ural Oğuz[4], Sinem Gümüştaş[5], Ali Fuat Atmaca[2], Erdem Vargöl[6]

Cite this article as: Tatlı Doğan H, Canda AE, Gök B, Oğuz U, Gümüştaş S, Atmaca AF, et al. Is there a difference in the number of interstitial cells, neurons, presence of fibrosis and inflammation in ureteropelvic junction tissues of patients with ureteropelvic junction obstruction with and without crossing vessels? Turk J Urol 2019; 45(4): 302-6.

ORCID IDs of the authors:
A.E.C. 0000-0002-5196-653X;
A.F.A. 0000-0002-0794-2135;
B.G. 0000-0002-2295-234X;
U.O. 0000-0003-0652-7957;
S.G. 0000-0002-8794-5431;
E.V. 0000-0003-1000-1050

[1]Department of Pathology, Ankara Yıldırım Beyazıt University, Ankara, Turkey

[2]Department of Urology, Ankara Yıldırım Beyazıt University, Ankara, Turkey

[3]Department of Urology, Ankara Atatürk Training and Research Hospital, Ankara, Turkey

[4]Department of Urology, Giresun University, Giresun, Turkey

[5]Department of Pathology, Çukurova Dr. Aşkım Tüfekçi State Hospital, Adana, Turkey

[6]Department of Pathology, Sakarya Training and Research Hospital, Sakarya, Turkey

Submitted:
28.12.2017

Accepted:
10.04.2018

Available Online Date:
27.07.2018

Correspondence:
Hayriye Tatlı Doğan
E-mail:
hayriyetatli@gmail.com

©Copyright 2019 by Turkish Association of Urology

Available online at
www.turkishjournalofurology.com

ABSTRACT

Objective: We compared the number of interstitial cells (ICs), nerves, presence of fibrosis and inflammation at the level of full-thickness human ureteropelvic junction (UPJ) tissues obtained from normal subjects, and patients with UPJ obstruction with and without crossing vessels.

Material and methods: Normal UPJ tissues (n=12) histopathologically confirmed to be without tumor involvement were obtained from subjects who underwent radical nephrectomy for kidney mass. Additional UPJ tissues were obtained from patients who underwent pyeloplasty due to UPJ obstruction. Crossing vessel was identified in 17 patients. In 57 patients, no crossing-vessel was noted. ICs were stained immunohistochemically with anti–human CD117 (c–kit) antibody. Neural tissue was stained with S-100. The numbers of ICs and neurons were compared between the groups: controls with normal UPJ (Group I), Ureteropelvic junction obtruction (UPJO) with crossing vessel (Group II) and UPJ obstruction without crossing vessel (Group III). Groups were also compared in terms of the presence of fibrosis and inflammation.

Results: The mean age of total population included in the study was 30.5±18.5 years. No significant differences were detected between the three groups regarding mean and median numbers of ICs at the level of UPJ (lamina propria and muscle layer) and mean and median numbers of neurons at the level of lamina propria ($p>0.05$). Likewise, no significant differences were detected between the three groups regarding the presence of fibrosis and inflammation ($p>0.05$).

Conclusion: Number of ICs, neurons, presence of fibrosis and inflammation seem to be similar in the intact UPJ and UPJ with obstruction with and without crossing vessel. Cellular function rather than the number ICs might play a role that warrants further research.

Keywords: Fibrosis; inflammation; interstitial cells; neurons; UPJ obstruction

Introduction

Ureteropelvic junction obstruction (UPJO) is a frequently seen condition with different etiologies accompanying intrinsic and/or extrinsic causes of obstruction. Intrinsic factors causing UPJO are stenosis, valves or fibroepithelial polyps. There are also extrinsic factors such as presence of crossing vessels and fibrous bands that may cause UPJO.[1] Although numerous studies investigating the molecular structures of obstructed segment have been performed, the principal mechanisms are still unclear. The abnormal nerve innervation patterns and abnormalities of collagen composition, reduction in interstitial cells of Cajal (ICs) and inflammation in the region of stenosis have been demonstrated in previous studies.[2-5]

After Ramon Y. Cajal defined ICs for the first time in the gastrointestinal tract in 1893, Koleda et al.[6] have demonstrated the relationship between ICs and UPJO, recently. ICs express a tyrosine kinase receptor c-kit (CD117) on the

Table 1. Clinicopathologic features of the study groups

	Group I (Control)	Group II UPJO (with crossing vessel)	Group III UPJO (without crossing vessel)	p
N	12 (14%)	17 (19.8%)	57 (66.3%)	
M/F	7/5	8/9	39/18	
Mean age (years) (range)	58.6 (32-75)	27.3 (1-54)	25.5 (2-51)	<0.05[a]
c-kit (+) (CD117) ICs (mean±SD)				
Lamina propria	20.8±10.9	19.9±10.8	18.1± 10.6	0.463[b]
Muscle layer	26.4±12.7	27.8±13.3	26.1±13.3	0.852[c]
S-100 (+) nerves (mean±SD)				
Lamina propria	4.8±4.4	5.4± 4.9	5.6±4.6	0.742[d]
Fibrosis				
No	n=7 (58.3%)	n=9 (52.9%)	n=26 (45.6%)	0.727[e]
Yes	n=5 (41.7%)	n=8 (47.1%)	n=31 (54.4%)	
Inflammation				
No	n=6 (50%)	n=14 (82.4%)	n=45 (78.9%)	0.117[f]
Yes	n=6 (50%)	n=3 (17.6%)	n=12 (21.1%)	

[a, b, c, d]Kruskal Wallis test, [e]Pearson Chi-square test, [f]Fisher's Exact Test, SD: standard deviation; UPJO: ureteropelvic junction obstruction; M: male; F: female

surface of the cells that is well known by immunohistochemistry.[7] ICs have been defined as one of the possible pacemaker cells for contractile activity, which is essential for the urine transport from renal pelvis to the ureter by peristaltism. Thus, it was considered that the lack of CD117 (+) ICs might lead to the loss of peristaltic waves in the UPJ. Therefore, the transport of urine into the ureter may be reduced and an UPJO may develop.[8]

The reason of pyeloplasty failure is still unclear and the role of the histopathological pattern of the UPJ in this failure is controversial. In the present study, we have analyzed the number of ICs, nerves, presence of fibrosis and inflammation at the level of full-thickness UPJ tissues obtained from normal subjects and patients with UPJO with and without crossing vessel.

Material and methods

The study was conducted at Ankara Yıldırım Beyazit University, and approved by the Yıldırım Beyazit University Clinical Research Ethics Committee (Date: 25/06/2012, no:2012/29). A total of 74 patients who underwent UPJ resection for UPJO in our institution between January 2006 and November 2014 and normal UPJ tissues obtained from 12 patients were included in this study. Histopathologically confirmed normal UPJ tissues without tumor involvement (n=12) in patients aged between 32-75, (median 58.6 years) were obtained from subjects who underwent radical nephrectomies due to renal masses (Group I). Patients with UPJO and with presence of crossing vessel (aged 1-54, mean 27.3 years) constituted Group II, n=17. Patients with UPJO and without crossing vessel (n=57) aged between 2-51, (median 25.5 years) constituted Group III. Clinicopathologic features of the study groups are presented in Table 1.

Five-micrometer sections were taken from paraffin blocks obtained from UPJ samples of the patients with UPJO with or without crossing vessels, and controls.

Inflammation was assessed in hematoxylin-eosin stained sections. Thepresence of inflammation was evaluated as the presence of at least a lymphoid aggregate in lamina propria. The presence of fibrosis was histochemically assessed as dense green staining of collagen in lamina propria with Masson's trichrome stain.

Immunohistochemical analysis for the C-kit (CD117) antibody (rabbit polyclonal, 1:400, Dako, Agilent, US) and S-100 (rabbit polyclonal, 1:500, ThermoFisher, US) was performed with 5-micrometer-thick tissue sections. After deparaffinization, rehydration and antigen retrieval, tissue sections were incubated with antibody according to manufacturer's protocol. Slides were then developed by use of chromogen DAB (Thermo-Fisher, US) and counterstained with hematoxylin. C-kit positive cell counts were assessed separately in lamina propria and muscularis propria. The total number of C-kit positive ICs was counted in 10 consecutive high-power fields under a light microscope (Nikon 80i, Japan). C-kit is also expressed by mast cells. ICs were counted in areas where there was no inflammation as much as possible. ICs had a fusiform cell body with a thin cytoplasm, a large oval nucleus and dendritic processes, whereas mast cells had a round central

Turk J Urol 2019; 45(4): 302-6
DOI:10.5152/tud.2018.08784

Table 2. Summary of the published studies

	Year	Group I	Group II	Group III	Neurons	ICs in UPJO	Inflammation	Fibrosis
Murakumo et al.[4]	1997	7	4	7	+	NS	NS	NS
Solari et al.[11]	2003	7	NS	19	+	+	NS	NS
Yang et al.[16]	2009	21	NS	24	NS	+	NS	NS
Ozel et al.[5]	2010	14	NS	22	NS	+	+	NS
Koleda et al.[6]	2012	5	NS	20	NS	+	NS	NS
Senol et al.[8]	2015	12	NS	19	NS	+	NS	NS
Our study	2017	12	17	57	+	+	+	+

NS: not studied; UPJO: ureteropelvic junction obstruction; ICs: interstitial cells of Cajal

nucleus. ICs in muscle layers were identified in the inner border of the circular muscle layer. The number of neurons stained with S100 was similarly counted in 10 consecutive high-power fields.

Statistical analysis

Statistical Package for Social Sciences (SPSS Inc.; Chicago, IL, USA) version 15.0 was used for statistical analysis. The distribution of Cajal cells in the UPJO patients with and without crossing vessels, and control groups were evaluated by the Kruskal-Wallis test. The Kruskal-Wallis test was used for the median number of nerve cells in every 3 groups. Fisher's Exact Test and Pearson Chi Square test were used to statistically evaluate presence of inflammation, and fibrosis respectively. We considered $p<0.05$ as statistically significant.

Results

Eighty six patients (32 female and 54 male) were included in the present study. The mean age of total population included in the study was 30.5±18.5 years. The mean ages and male:female ratios of each study group were 58.6, 27.3, 25.5 years and 1.4, 0.9, 2.2 in Group I, II and III, respectively. Clinicopathologic features of all cases are summarized in Table 1. There was no statistically significant difference in mean numbers of c-kit (+) ICs which had a fusiform cell body with a thin cytoplasm, oval nucleus and dendritic processes at the level of UPJ (lamina propria & muscle layer) among the groups (p=0.463 and 0.852 respectively) (Figure 1a, b). Similarly, no statistically significant differences were detected in the mean and median numbers of neurons at the level of lamina propria between the three groups (p=0.742) (Figure 1c). When the dense green collagen deposition with Masson's trichrome in lamina propria was accepted as presence of fibrosis, 5 cases from group I, 8 from group II and 31 from group III were positive for fibrosis while others were negative (Figure 1e, f). When presence of inflammation was assessed as the formation of at least a lymphoid aggregate in lamina propria, 6 cases from group I, 3 from group II, 12 from group III showed inflammation (Figure 1d). No significant differences were detected among the groups about the presence of fibrosis and inflammation (p=0.727 and 0.117 respectively) (Figure 1).

Discussion

Interstitial cells were firstly defined in the gastrointestinal system. Tyrosine kinase surface receptors were detected on ICs and these receptors had C-kit positivity. Thus, ICs having proto-oncogene c-kit can be labeled with antibodies.[9-12] The peristaltic activity in the upper urinary system is induced by ICs. Therefore, we hypothesized that peristaltic activity might be reduced due to the decrease in the number of ICs in UPJ leading to impaired urine transport from the renal pelvis into the ureter and bladder.[11] In addition to the assessment of the number of ICs in lamina propria and muscle layers, we analyzed neuron count in lamina propria and presence of fibrosis and inflammation in present study. Many studies published up to now have been performed in the pediatric age group. Compared to the published literature, our study is more heterogeneous in that it included different age groups. In addition to the literature, we compared UPJ tissues obtained from normal subjects, UPJO patients with and without crossing vessels. Most of the previous studies compared two groups as UPJO without crossing vessel and the control group. Our study is one of the rare studies including a crossing vessel subgroup. To the best of our knowledge, our study is the first study comparing ICs, nerves, fibrosis and inflammation in three groups.

Solari et al.[11] first indicated that IC counts decreased in specimens obtained from UPJO group using c-kit antibodies and immunohistochemical methods. They compared 19 patients who underwent pyeloplasty due to UPJO and 7 patients in the control group. In their study, the control group had a large number of c-kit positive ICs, whereas the number of c-kit positive ICs in the UPJO group was significantly reduced.[11] In our study, we compared 57 patients in Group III, 17 patients in Group II and 12 patients in Group I. All cases were compared according to number of ICs at the level of lamina propria and muscle layer,

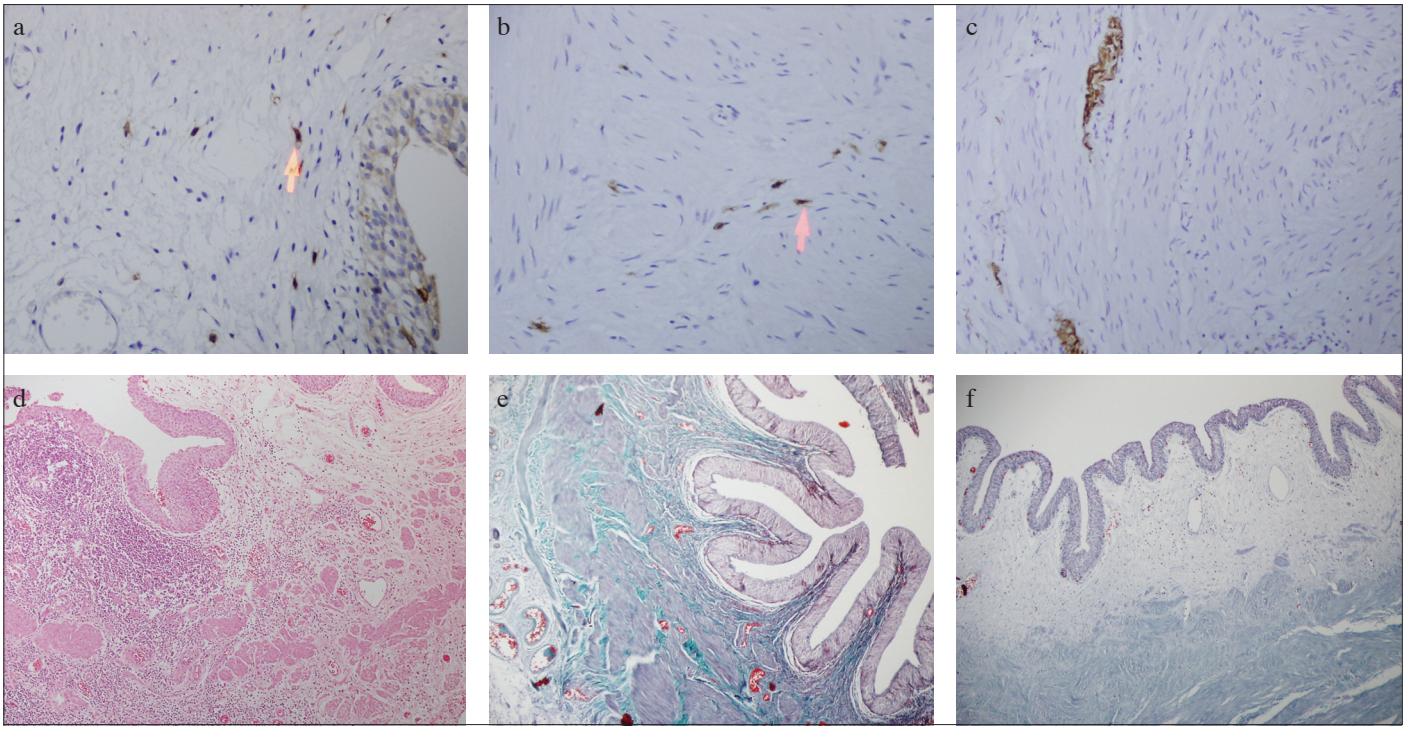

Figure 1. a-f. (a) C-kit positive interstitial cell at the level of human UPJ lamina propria (x400). (b) C-kit positive interstitial cell at the level of human UPJ muscularis propria (x400). (c) Neurons at the level of human UPJ lamina propria (S-100 X100). (d) Inflammation at the level of human UPJ lamina propria (H&EX100). (e) Fibrosis at the level of human UPJ lamina propria (M. Trichrome x100). (f) Lack of any fibrosis at the level of human UPJ lamina propria (M. Trichrome x 100)

number of neurons at the level of lamina propria, presence of fibrosis and inflammation. We could not find a significant difference between the three groups in terms of all parameters. Mehrazma et al.[13] compared number of ICs, number of neurons and collagen deposition in 25 patients with UPJO and 19 patients with normal UPJ. While deposition of the collagen was found to be higher, the number of ICs was statistically lower than those of the control group. The number of nerve fibers was not statistically different for the two groups. Issi et al.[14] evaluated the histopathological specimens obtained following pyeloplasty from 52 patients without crossing vessel with UPJO at 6 months after surgery. The patients were separated into successful (Group I) and unsuccessful surgery (Group II) groups. $T_{1/2}$ time over 20 minutes was defined as unsuccessful surgery. $T_{1/2}$ time under 20 minutes was defined as successful surgery. There were not any significant differences for collagen type 3, elastin, fibrosis, and ICs between the 2 groups ($p>0.05$).[14] Similarly, we did not find significant differences for the presence of fibrosis between the groups ($p=0.727$). We evaluated the ICs in UPJ in separated layers. There was no significant difference for the number of c-kit (+) (CD117) ICs in the lamina propria and muscle layer between the three groups ($p>0.05$). Apoznanski et al.[15] in their study investigated the distribution of ICs of the 20 patients in the intrinsic UPJO group and 5 patients in the control group. Similar to our study, they did not find a statistically significant difference in IC distribution between UPJO and control group.

Ozel et al.[5] showed nonspecific evidences of inflammation in the region of UPJO. In our study, we did not find any difference in terms of the presence of inflammation between the groups. Comparison of the published literature on this subject is presented in Table 2. Most of the studies published about this topic have been designed to have only two groups (UPJO without crossing vessel and control). All of the parameters that we included in our study with 3 different groups have not been investigated in any other study yet. In the present study, patients with UPJO and crossing vessel were also included in contrast to the previous studies in the literature. The main limitation of the previous studies was decreased number of patients.

The limitations of our study include limited numbers of patients in each group, its retrospective design and the nonhomogenous distribution of the age in groups. Therefore, further studies are needed to exhibit more clear outcomes.

In conclusion, according to our findings, number of ICs, neurons, presence of fibrosis and inflammation do not play a role in the etiology of the UPJO. Cellular function rather than the number of ICs might play a role that warrants further research.

Turk J Urol 2019; 45(4): 302-6
DOI:10.5152/tud.2018.08784

Ethics Committee Approval: Ethics committee approval was received for this study from the ethics committee of Yıldırım Beyazıt University School of Medicine (Date:25/06/2012, no:2012/29).

Informed Consent: Additional informed consent was not required for this retrospective study.

Peer-review: Externally peer-reviewed.

Author Contributions: Concept - A.E.C., H.T.D.; Design - H.T.D.; Supervision - A.F.A.; Resources - A.E.C.; Materials - S.G., E.V.; Data Collection and/or Processing - S.G.; Analysis and/or Interpretation - B.G., H.T.D.; Literature Search - B.G., H.T.D.; Writing Manuscript - B.G., H.T.D., A.E.C.; Critical Review - A.F.A., U.O., A.E.C.

Conflict of Interest: No conflict of interest was declared by the authors.

Financial Disclosure: The authors have declared that they did not receive any financial support for this study.

References

1. Villemagne T, Fourcade L, Camby C, Szwarc C, Lardy H, Leclair MD. Long-term results with the laparoscopic transposition of renal lower pole crossing vessels. J Pediatr Urol 2015;11:174 e1-7.
2. Kajbafzadeh AM, Payabvash S, Salmasi AH, Monajemzadeh M, Tavangar SM. Smooth muscle cell apoptosis and defective neural development in congenital ureteropelvic junction obstruction. J Urol 2006;176:718-23. [CrossRef]
3. Kim WJ, Yun SJ, Lee TS, Kim CW, Lee HM, Choi H. Collagen-to-smooth muscle ratio helps prediction of prognosis after pyeloplasty. J Urol 2000;163:1271-5. [CrossRef]
4. Murakumo M, Nonomura K, Yamashita T, Ushiki T, Abe K, Koyanagi T. Structural changes of collagen components and diminution of nerves in congenital ureteropelvic junction obstruction. J Urol 1997;157:1963-8. [CrossRef]
5. Ozel SK, Emir H, Dervisoglu S, Akpolat N, Senel B, Kazez A, et al. The roles of extracellular matrix proteins, apoptosis and c-kit positive cells in the pathogenesis of ureteropelvic junction obstruction. J Pediatr Urol 2010;6:125-9. [CrossRef]
6. Koleda P, Apoznanski W, Wozniak Z, Rusiecki L, Szydelko T, Pilecki W, et al. Changes in interstitial cell of Cajal-like cells density in congenital ureteropelvic junction obstruction. Int Urol Nephrol 2012;44:7-12. [CrossRef]
7. Maeda H, Yamagata A, Nishikawa S, Yoshinaga K, Kobayashi S, Nishi K, et al. Requirement of c-kit for development of intestinal pacemaker system. Development 1992;116:369-75.
8. Senol C, Onaran M, Gurocak S, Gonul, II, Tan MO. Changes in Cajal cell density in ureteropelvic junction obstruction in children. J Pediatr Urol 2016;12:89-e1-5.
9. Metzger R, Schuster T, Till H, Franke FE, Dietz HG. Cajal-like cells in the upper urinary tract: comparative study in various species. Pediatr Surg Int 2005;21:169-74. [CrossRef]
10. Metzger R, Schuster T, Till H, Stehr M, Franke FE, Dietz HG. Cajal-like cells in the human upper urinary tract. J Urol 2004;172:769-72. [CrossRef]
11. Solari V, Piotrowska AP, Puri P. Altered expression of interstitial cells of Cajal in congenital ureteropelvic junction obstruction. J Urol 2003;170:2420-2. [CrossRef]
12. Wang Y, Puri P, Hassan J, Miyakita H, Reen DJ. Abnormal innervation and altered nerve growth factor messenger ribonucleic acid expression in ureteropelvic junction obstruction. J Urol 1995;154:679-83. [CrossRef]
13. Mehrazma M, Tanzifi P, Rakhshani N. Changes in Structure, Interstitial Cajal-like Cells and Apoptosis of Smooth Muscle Cells in Congenital Ureteropelvic Junction Obstruction. Iran J Pediatr 2014;24:105-10.
14. Issi O, Deliktas H, Gedik A, Ozekinci S, Bircan MK, Sahin H. Does the histopathologic pattern of the ureteropelvic junction affect the outcome of pyeloplasty. Urol J 2015;12:2028-31.
15. Apoznanski W, Koleda P, Wozniak Z, Rusiecki L, Szydelko T, Kalka D, et al. The distribution of interstitial cells of Cajal in congenital ureteropelvic junction obstruction. Int Urol Nephrol 2013;45:607-12. [CrossRef]