TURKISH JOURNAL OF UROLOGY
Turk J Urol 2020; 46(4): 288-96 • DOI: 10.5152/tud.2020.19265
UROONCOLOGY
Original Article

Single-center experience of robot-assisted radical cystectomy (RARC) and extended pelvic lymph node dissection

Mehmet Salih Boğa[1], Çağatay Özsoy[1], Yasin Aktaş[1], Arif Aydın[2], Murat Savaş[3], Mutlu Ateş[1]

Cite this article as: Boğa MS, Özsoy Ç, Aktaş Y, Aydın A, Savaş M, Ateş M. Single-center experience of robot-assisted radical cystectomy (RARC) and extended pelvic lymph node dissection. Turk J Urol 2020; 46(4): 288-96.

ABSTRACT

Objective: To report the outcomes of robot-assisted radical cystectomy (RARC) and extended pelvic lymph node dissection (ePLND) series for bladder cancer.

Material and methods: Between October 2016 and June 2019, overall 57 patients (50 men, 7 women) were included in the study. Patient demographics, operative data, and postoperative pathological outcomes were evaluated. Patients who had a history of pelvic or intraabdominal surgery due to other concurrent malignancy, radiation therapy, or lacked data were excluded from the study.

Results: The mean age of the patients was 64.72±9.09 years. The mean operation time, intraoperative estimated blood loss, and hospitalization time were 418.58±85.66 minutes, 313.00±79.16 mL, and 13.44±5.25 days, respectively. The postoperative pathological stages were reported as pT0 (n=8), pTis (n=4), pT1 (n=4), pT2 (n=22), pT3a (n=11), pT3b (n=2), pT4a (n=4), pT4b (n=1), and other (n=1). The mean lymph node (LN) yield was 23.45±9.43. Positive LNs were found in 16 (28.1%) patients. Surgical margins were positive in 3 (5.26%) patients. The mean follow-up period was 15.42±8.31 months. According to the modified Clavien-Dindo system, minor (Clavien 1-2) and major (Clavien 3-5) complications occurred in 18 (31.58%) and 9 (15.78%) patients during the early (0-30 days) period and in 4 (7.02%) and 5 (8.77%) patients in the late (31-90 days) period.

Conclusion: RARC and ePLND are complex but safe procedures with acceptable morbidity and excellent surgical and oncologic outcomes in muscle-invasive or high-risk bladder tumors.

Keywords: Bladder tumors; cystectomy; lymphadenectomy; robotics; urinary diversion.

ORCID IDs of the authors:
M.S.B. 0000-0001-7979-8075;
Ç.Ö. 0000-0002-2124-865X;
Y.A. 0000-0001-5255-3780;
A.A. 0000-0001-8691-090X;
M.S. 0000-0002-3068-4699;
M.A. 0000-0003-3951-4271

[1]Department of Urology, Health Sciences University, Antalya Training and Research Hospital, Antalya, Turkey
[2]Department of Urology, Necmettin Erbakan University, Meram School of Medicine, Konya, Turkey
[3]Private Memorial Antalya Hospital, Antalya, Turkey

Submitted:
13.12.2019

Accepted:
13.03.2020

Available Online Date:
14.03.2020

Corresponding Author:
Mehmet Salih Boğa
E-mail:
msalihboga@yahoo.com

©Copyright 2020 by Turkish Association of Urology

Available online at
www.turkishjournalofurology.com

Introduction

Radical cystectomy and pelvic lymphadenectomy are the gold standard treatment for muscle-invasive or nonmuscle invasive high-risk bladder tumors.[1] Postoperative oncologic results were similar in open and robotic cystectomies.[2] The utilization of robot-assisted radical cystectomy (RARC) is increasing in Turkey as well as all over the world because of the less bleeding, short duration of hospitalization, and better cosmetic results compared with open radical cystectomy (ORC).

Many publications have reported the technique of the surgery, oncologic and functional outcomes, and complication rates in open cystectomies, but the number of publications on robotic cystectomy remains limited. Although RARC is performed successfully in several centers in Turkey, the number of RARC-related publications in PubMed indexed journals is limited compared to other countries.[3,4]

In this study, we report the outcomes of our experience with 57 cases who underwent RARC and extended pelvic lymph node dissection (ePLND) for bladder tumor.

Material and methods

After the approval of institutional review board for this retrospective study, we identified 57 patients for review who underwent radical cystectomy and ePLND by using a four-arm *daVinci XI robotic system* (Intuitive Surgical, CA, USA) between October 2016 and June 2019. Demographics, operative data,

postoperative outcomes, and complications were recorded for each patient.

Patients who had a history of pelvic or intraabdominal surgery due to other concurrent malignancy, radiation therapy, or lacked data were excluded from the study.

Robotic surgery was performed at our center by two experienced surgeons (MA and MS). The surgeons began to perform RARC after >100 robotic radical prostatectomies. Intracorporeal diversions were started after >20 extracorporeal ileal loop diversions. After adequate experience, all cases were completed intracorporeally.

The decision of RARC and the types of diversion were determined according to comorbidities, functioning of the gastrointestinal system, presence of urethral or bladder neck tumor, chronic renal failure, adaptation of the patients, and preference of the surgeons. We performed ePLND along with cystectomy for all patients.[5]

The lymph node (LN) was dissected as a level of extended template for all patients including the removal of the obturator, external iliac, common iliac, and presacral LNs.[6] In ileal conduit, a segment of the ileum of approximately 15 to 20 cm was isolated and used for urinary diversion. The distal ends of both ureters were anastomosed to the ileum by the Wallace or Bricker technique.[7,8] Ileal construction was performed according to the Studer reservoir[9] for orthotopic neobladder. In cutaneous ureterostomy technique, the left ureter was crossed to the right side, and then two ureters were placed side by side, anastomosed to the stoma created on the skin.[10] Our RARC technique is described in detail below. Postoperative early (0-30 days) and late (31-90 days) complications were evaluated using the modified Clavien-Dindo system. Minor complications were placed in Clavien category 1-2 and major complications were placed in category 3-5.[11]

Written informed consent of each patient was obtained before the surgery, and our study was conducted according to the principles of Helsinki Declaration. Institutional ethics committee approval (No. 24/12) was obtained on November 7, 2019 for this retrospective study.

Main Points:

- **Safety:** RARC has excellent surgical and oncologic outcomes with acceptable complication rates.
- **Comfortable:** RARC provides advantages of low blood loss, shorter hospitalization, and earlier return to daily life.
- **Experience:** Radical cystectomy has high morbidity and mortality, RARC should be performed in advanced centers and after sufficient experience.

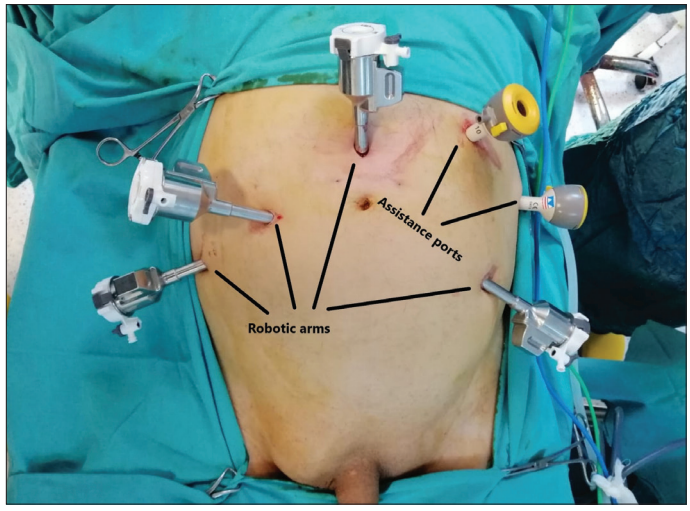

Figure 1. Demonstration of port placement

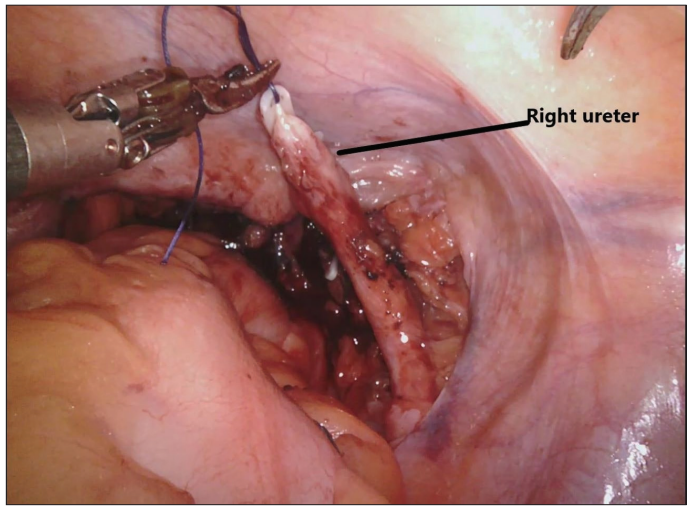

Figure 2. Demonstration of the ureter after dissection and hemoclipping

Surgery technique

Pneumoperitoneum was created with a Veress needle from the midline 4 cm superior to the umbilicus in the supine position under general anesthesia. A total of six ports were placed, including an 8-mm port for the camera in the position of entrance of the Veress needle and two 8-mm ports on the right side for robotic arms. Two assistance ports were placed at the end laterally (8 mm) and medially (10 mm) on the left side, and an 8-mm port was placed for robotic arm between the assistance ports (Figure 1).

The patient was then moved to a 30° Trendelenburg position, and docking of the robot arms was done. In the retroperitoneal area at the iliac cross level, the right and left ureters were found, dissected up to the bladder entrance, and cut after ligation by hemoclipping (Figure 2).

Turk J Urol 2020; 46(4): 288-96
DOI: 10.5152/tud.2020.19265

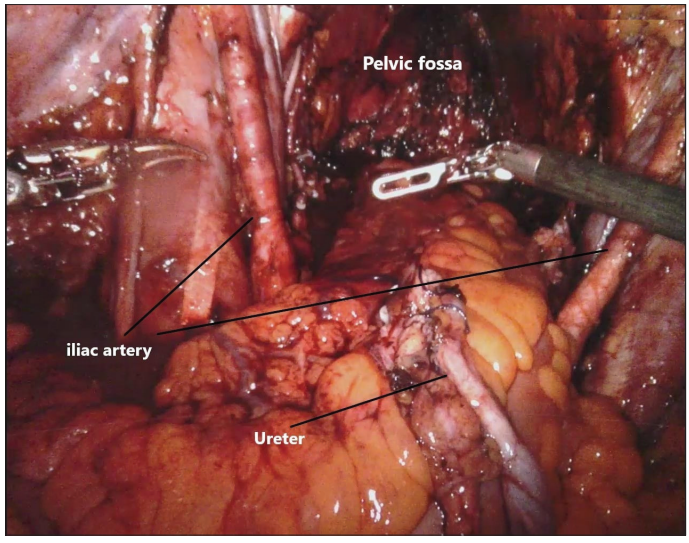

Figure 3. Appearance of the pelvic fossa after cystoprostatectomy and ePLND

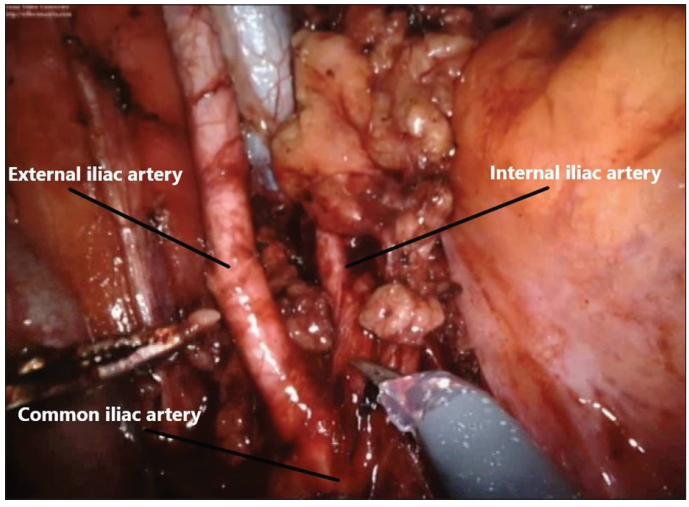

Figure 4. Demonstration of ePLND

The peritoneum was incised over the Douglas pouch, than posterior of the bladder, seminal vesicles, and ducts were dissected. The bladder pedicles were dissected and cut after ligation by hemoclipping, which reached the endopelvic fascia, and the bilateral endopelvic fascia were opened. In the anterior side, the deep dorsal vein was ligated with 3.0 vicryl and cut. After the prostate was released from the surrounding tissues, the prostate urethra junction was cut by marking the catheter balloon; the prostate was elevated using the catheter and dissected posteriorly; and the bladder and prostate were removed together (Figure 3).

Lymphadenectomy was performed to cover the external, internal, and common iliac; obturator, and presacral LNs (bilateral ePLND) (Figure 4). The specimens were placed in the endobag.

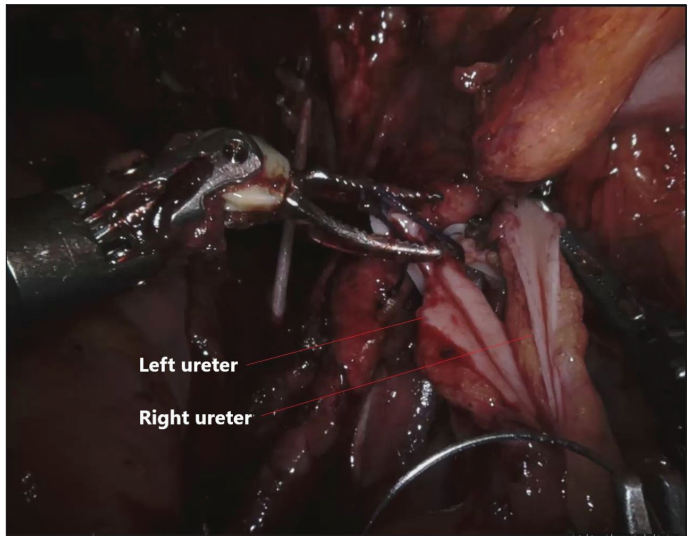

Figure 5. Demonstration of the Wallace-type ureteroileal anastomosis

The left ureter was crossed to the right side from under the sigmoid colon.

Urinary diversions

Ileal conduit: The ileal pouch was formed using the 15 to 20 cm ileal segment 20 cm proximally from the ileocecal valve, and the remaining intestinal segment was anastomosed with a stapler. Mono J ureter catheters were placed in both ureters, and the ileal pouch was anastomosed to the ureters by the Wallace[7] or Bricker[8] technique using 4/0 vicryl (Figure 5). The robotic part was terminated after bleeding control, and the distal end of the ileal conduit was brought to the right lower abdomen and sutured to the stoma on the skin, which was prepared previously.

Orthotopic neobladder: A 50 cm ileal segment was isolated approximately 20 cm from the ileocecal valve to reconstruct the Studer orthotopic ileal reservoir. The remnant urethra was anastomosed to the isolated ileal segment from the antimesenteric border at 10 cm distally. Then, the isolated 50-cm ileal segment was resected distally and proximally by a laparoscopic intestinal stapler. The distal and proximal ileal ends were opened, the opened ends were brought side by side, and side-to-side ileoileostomy was performed with a 60-mm Echelon linear stapler. The proximal 10 cm of the segregated ileal segment was left in the form of a chimney for ureter anastomosis. The other parts of the segregated ileum were detubularized from the antimesenteric border with a cold scissors. First the posterior part and then the anterior part of the segregated ileal segment were spherically closed. After the anastomosis leak test, additional sutures were applied to the leak points. Bricker-type ureteroileal

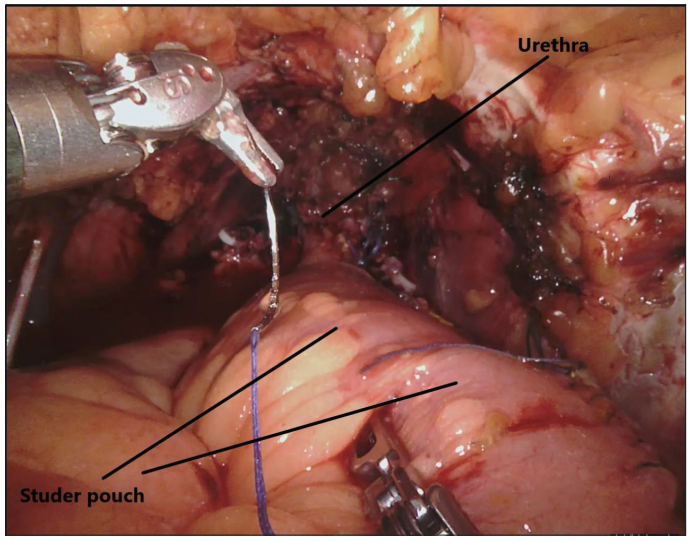

Figure 6. Appearance of the Studer pouch anastomosed to the urethra

anastomosis was performed to the chimney-shaped proximal part of the Studer pouch with 4/0 vicryl. Before the ureteroileal anastomoses were completed, 6 F JJ stents were inserted in both ureters. The urethral catheter was removed 21 days after cystography, and JJ stents were removed 3 months after surgery. Appearances of the Studer pouch anastomosed to the urethra are shown in Figure 6.

Statistical analysis

Statistical analysis was carried out by using IBM Statistical Package for the Social Sciences soft version 23.0 (IBM SPSS Corp.; Armonk, NY, USA). The variables were analyzed whether they were compatible with normal distribution. Descriptive statistics were given as the number of cases and categorical variables as percentages, and the Chi square test was used to evaluate these variables. Descriptive statistics were given as mean±SD for continuous variables, and one-sample t test was used to analyze these variables.

Results

A total of 57 patients (50 men, 7 women) who underwent RARC and ePLND were included in the study. Of the 57 patients, 23 (40.35%) received extracorporeal ileal conduit, 15 (26.34%) received intracorporeal ileal conduit, 17 (29.8%) received intracorporeal orthotopic neobladder, and 2 (3.5%) received ureterocutaneostomy.

The mean age of the patients was 64.72±9.09 years. The mean operation time (OT) was 418.58±85.66 minutes, and the mean estimated blood loss (EBL) was 313.00±79.165 mL. The mean lodge drain and hospitalization time were 12.05±4.71 and 13.44±5.25 days, respectively. Demographics and operative parameters are shown in Table 1.

Table 1. Demographic and operative parameters

Variable	
Number of patients, n	57
Sex M/F, n	50/7
Mean age, years (±SD)	64.72±9.09
ASA score, n (%)	
ASA I	5 (8.77%)
ASA II	31 (54.38%)
ASA III	17 (29.82%)
ASA IV	4 (7.02%)
Mean BMI, kg/m^2 (±SD)	27.42±2.71
Urinary diversion type, n (%)	
Ileal loop (extracorporeal)	23 (40.35%)
Ileal loop (intracorporeal)	15 (26.34%)
Neobladder (extracorporeal)	0 (0%)
Neobladder (intracorporeal)	17 (29.8%)
Ureterocutaneostomy	2 (3.5%)
Mean operative time, minutes (±SD)	418.58±85.66
Mean EBL, mL (±SD)	313.00±79.165
Mean hospitalization time, days (±SD)	13.44±5.25
Mean removal drain time, days (±SD)	12.05±4.71
Mean follow-up, months (±SD)	15.42±8.31

ASA: American Society of Anesthesiologists; BMI: body mass index; EBL: estimated blood loss

Precystectomy clinical stages were included: 7 (12.28%) patients in pT1, 46 (80.70%) patients in pT2, and 4 (7.02%) patients in pT3. Four of the pT1 patients had urothelial carcinoma in situ (CIS) coexistence and one had pure plasmacytoid variant. Postoperative pathologic stages were included: pT0 (n=8), pTis (n=4), pT1 (n=4), pT2 (n=22), pT3a (n=11), pT3b (n=2), pT4a (n=4), pT4b (n=1), and one case was pure plasmacytoid variant in a focal area. Of the patients, 39 (68.42%) had organ-confined disease (pT2) and 18 (31.58%) had nonorgan-confined disease (pT3-4). In pT4a patients, invasions were seen in the prostate (n=1), vagina (n=1), tuba uterina (n=1), and seminal vesicle (1), while in 1 patient with pT4b, invasion was observed in the abdominal wall.

Turk J Urol 2020; 46(4): 288-96
DOI: 10.5152/tud.2020.19265

Table 2. Distribution of pathologic outcomes

Clinical stage, n (%)	
pT1	7 (12.28%)
pT2	46 (80.70%)
pT3	4 (7.02%)
pT4	0 (0%)
Pathological stage, n (%)	
pT0	8 (14.04%)
pTis	4 (7.02%)
pT1	4 (7.02%)
pT2	22 (38.60%)
pT3a	11 (19.30%)
pT3b	2 (3.51%)
pT4a	4 (7.02%)
pT4b	1 (1.75%)
Other (pure plasmacytoid variant)	1 (1.75%)
Lymph node yield, mean (±SD)	23.45±9.43
Lymph node positivity, n (%)	
N0	41 (71.93%)
N1	11 (19.3%)
N2	5 (8.77%)
Organ-confined disease (≤pT2), n (%)	39 (68.42%)
Nonorgan-confined disease (pT3-4), n (%)	18 (31.58%)
Surgical margin positivity, n (%)	
Negative	54 (94.74%)
Positive	3(5.26%)

Postoperative pathology specimen results of 14 patients showed different variants such as squamous differentiation (n=15), adenocarcinoma (n=1), von Brunn nests and cystitis cystica (n=1), sarcomatoid component (n=1), and micropapillary pattern (n=1) coexistence with transitional cell cancer (TCC). One case was pure plasmacytoid variant. CIS coexistence was observed in 2 patients with pT3a pathology.

In the cystectomy specimens, four patients had concomitant prostate cancer, and all of them scored 3+3 according to the Gleason scoring system. Four patients who had pT3 (pathology before the cystectomy) underwent neoadjuvant chemotherapy prior to cystectomy. Adjuvant chemotherapy was offered to patients who had pT3-4 and/or LN metastasis if neoadjuvant chemotherapy has not been given. The mean LN yield was 23.45± 9.43 (range, 7-63). Positive surgical margin (SM) was detected in three patients whose pathologic stage were pT2 (1), pT4a (1), and pT4b (1). The distribution of pathology outcomes is presented in Table 2.

Table 3. Presentation of complication rates

Grade of complication according to the Clavien system	Early (0–30 days) period N=27 (Overall)	Late (31–90 days) period N=9 (Overall)
Minor complication (Clavien 1–2)	18	4
Major complication (Clavien 3–5)	9	5

The mean follow-up period was 15.42±8.31 (range, 3-36) months. Overall, 8 patients died during follow-up. Of those, five died due to bladder cancer and three died due to cardiac (1) and pulmonary (2) diseases. Overall, 9 patients had local or distant metastasis.

Local recurrence and lung metastasis were observed in one patient who had T2N0 urothelial carcinoma with positive SM on postoperative 4th month and received chemotherapy. Patients had pT4N1, T3N0, T3N2, T3N1, and T4N0 urothelial carcinoma with clear SM who refused postoperative adjuvant chemotherapy; lung metastasis on postoperative 12th month, paraaortic LN metastasis on postoperative 13th month, lung metastasis on postoperative 5th month, LN metastasis on postoperative 8th month, lung and bone metastasis on postoperative 20th month were observed, respectively, in these patients. All these patients received chemotherapy for metastasis.

In one patient who had T2N0 urothelial carcinoma with clear SM, urethral tumor was observed at postoperative 18th month and left renal pelvis tumor occurred at postoperative 27th month. He underwent urethrectomy for urethral tumor and left nephroureterectomy for renal pelvis tumor. In another patient who had T2N0 pathological stage with sarcomatoid component and clear SM, robotic port metastasis occurred at postoperative 3rd month, and the patient received chemotherapy and radiation therapy to this site. In another patient who had T2N0 pathological stage with clear SM, bone metastasis occurred at postoperative 13th month, and the patient received chemotherapy.

Minor (Clavien 1-2) and major (Clavien 3-5) complications occurred in 18 (31.58%) and 9 (15.78%) patients during the

Table 4. Distribution and management of complications

Complications	Early (0–30 days) period, n	Late (31–90 days) period, n	Management
Urinary infection	5 (Clavien 2)[a]	4 (Clavien 2)[b]	[a]Five patients in the early period and [b]4 patients in the late period received parenteral antibiotic treatment due to complicated urinary infection.
Blood transfusion	4 (Clavien 2)		Blood transfusion was performed for four patients due to a decrease in hematocrit values in the preoperative period.
Ileus	2 (Clavien 2)[c]	1 (Clavien 4)[d]	[c]In two patients, ileus was observed on the 5th and 17th days, symptoms were regressed with oral stop medical follow-up. [d]Laparotomy was required to one patient due to bowel obstruction.
Ureteroileal anastomosis leak	1 (Clavien 4)[e] 3 (Clavien 3)[f]		[e]Reanastomosis was performed due to the drainage did not decrease and significant leakage was observed at the left ureteroileal anastomosis in the cystography on postoperative 10th day. [f]Cystography showed leakage in the ureteroileal anastomosis in three patients on postoperative 15th–20th days. The leakages were regressed with nephrostomy catheter insertion (left side for two patients, right side for one patient) by interventional radiology.
Neobladder leak		1 (Clavien 4)	Acute abdomen developed due to neobladder rupture on postoperative 35th day and repair was provided by laparotomy. No additional problem was observed during the follow-up period.
Incisional hernia		1 (Clavien 3)	Symptomatic incisional hernia was observed in one patient at 3rd month postoperatively. This patient underwent hernia repair.
Wound infection	3 (Clavien 1)[g] 1 (Clavien 3)[h]		[g]Wound infections were observed in three patients, and no additional pharmacological or surgical interventions were required. [h]Resuturation of the wound site was required with local anesthesia due to opening of the wound.

Turk J Urol 2020; 46(4): 288-96
DOI: 10.5152/tud.2020.19265

Table 4. Distribution and management of complications (Continue)

Complications	Early (0–30 days) period, n	Late (31–90 days) period, n	Management
Delirium	1 (Clavien 2)		Delirium symptoms occurred in one patient on postoperative 6th day. Neurological consultation was performed and pharmacological treatment was given.
Death	1 (Clavien 5)		One perioperative death occurred due to pulmonary embolism 3 days after the operation.
Pulmonary embolism	1 (Clavien 2)		Pulmonary embolism occurred in postoperative 7th day, consulted to Department of Lung and Chest Diseases and regressed by pharmacological intervention.
Early removal of the catheter	1 (Clavien 3)		Nephrostomy catheter was inserted by interventional radiology on postoperative 5th day due to the early removal of ureter catheter.
Hydronephrosis/Ureteroileal anastomosis stricture	2 (Clavien 3)[i]	2 (Clavien 3)[j]	[i]Nephrostomy and antegrade JJ stenting were required for two patients in the early period and 2 patients in the late period due to hydronephrosis / ureteroileal anastomosis stricture.
Electrolyte imbalance	1 Clavien 1)		Hypernatremia was observed in one patient in postoperative 1st week, and no additional intervention was required in follow-up.
Major depression	1 (Clavien 2)		Major depression symptoms observed in the first control of the patient. Consulted to Department of Psychiatry, and symptoms were regressed by pharmacological intervention.

early (0-30 days) period and in 4 (7.02%) and 5 (8.77%) patients in the late (31-90 days) period. Complication rates according to the modified Clavien system and management of the complications are presented in Tables 3 and 4, respectively.

Discussion

RARC has oncologic and complication results similar to those of ORC; it also has the advantages of lower blood loss, shorter hospitalization, decreased analgesic use, and better cosmetic appearance compared to ORC.[12]

SM negativity and adequate LN yield are important predictors for oncologic success in radical cystectomy. The LN yield should be >16 for an adequate evaluation and a good oncologic result.[13,14].

The mean LN yield was 23.45±9.43 in the current study. The mean LN yield during LN dissection reported in a previous study was between 10 and 43.[15] The overall LN yield was reported as 18 in a study of International Robotic Cystectomy Consortium (IRCC) group, which compared the intracorporeal and extracorporeal cystectomy groups with 2123 patients.[16] Richards et al.[17] reported

the LN yield as 17 in their RARC series with 60 patients. The LN yield in the first 18 cases of RARC from our center was 14.[18]

A previous studies reported LN positivity rate as between 6% and 42% in the RARC series.[15] In the current study, the LN positivity rate was 28.07%, which is similar to that in the literature.

SM positivity rates of 0-12% and 0-26% were reported in different RARC series.[15,19] The Robotic Section of European Urology reported an SM positivity rate of 4.8% in a multicenter study with 717 patients.[20] An SM positivity of 7% was reported by IRCC in 2123 cases.[16] Yuh et al.[15] reported an SM positivity of 5.6%. Porreca et al.[21] reported an SM positivity of 3% in their first 100 case series. In a study of 1589 patients who underwent radical cystectomy at Memorial Sloan Kettering Cancer Center, the SM positivity was 4.2%, and they reported that female sex, higher pathologic stage, vascular invasion, mixed histology, and LN involvement were risk factors for SM positivity.[20] In our study, the SM positivity was 5.26%, consistent with the literature.

In the current study, the mean OT was 418.58±85.66 minutes and EBL was 313.00±79.165 mL. IRCC[16] reported OT and EBL as 371 minutes and 300 mL, respectively, whereas Khan et al.[22] reported 389 minutes and 585 mL, respectively. Porreca et al.[21,23] reported that OT and EBL decreased depending on the experience at the learning curve: OT decreased from 399 to 373 minutes and EBL from 425 to 250 mL compared with the first 24 cases and the last 34 cases.

Shorter lodge drain and hospitalization time and lower complication rates are important advantages of RARC compared to ORC. A hospitalization time of 4-17.1 days was reported in the literature.[17,24] In the current study, the hospitalization time was 13.35±3.99 days, and the duration of the lodge drain was 11.11±2.53 days, which are similar to the literature data.

The studies have shown that the low complication rates are important advantages of the RARC.[25] Canda et al.[26] reported their minor and major complication rates as 33.3% and 14.81% in 0-30 days period and as 14.81% and 11.11% in 30-90 days period. Schumacher et al.[27] reported 40% (17.78% minor, 22.22% major) complications in early period and 30% (13.33% minor, 17.77% major) complication rates in late period in their RARC series. IRCC reported any complication and major complication rates as 50% and 11%, respectively, in their multicenter study.[16] Gok et al.[3] reported 30.61% minor and 20.41% major complications in the perioperative (0-30 days) period, and 6.12% minor and 7.14% major complications in the postoperative (31-90 days) period in their study. Our minor and major complications were 31.58% and 15.78% in the early period and 7.02% and 8.77% in the late period.

There were some limitations of the study. One of the important limitations of this study was that it was a retrospective study. Another important limitation was the absence of functional data such as continence and erectile function outcomes of the study.

Although RARC is a complex procedure, it is a safe surgical method for muscle-invasive or high-risk bladder tumors with acceptable morbidity, excellent surgical and oncologic outcomes, and advantages of low blood loss, shorter hospitalization, and earlier return to daily life. Further randomized prospective studies are needed to evaluate the long-term outcomes of RARC in bladder tumors.

Ethics Committee Approval: Ethics committee approval was received for this study from the ethics committee of Health Sciences University, Antalya Training and Research Hospital (Date: 07.11.2019, No: 24/12).

Informed Consent: Written informed consent was obtained from patients who participated in this study.

Peer-review: Externally peer-reviewed.

Author Contributions: Concept - M.S.B., M.A.; Design - M.S.B., Ç.Ö., M.A., A.A.; Supervision - M.S.B., M.A.; Materials - M.S.B., M.S., M.A.; Data Collection and/or Processing - M.S.B., Ç.Ö., Y.A.; Analysis and/or Interpretation - M.S.B., A.A.; Literature Search - M.S.B., Ç.Ö., Y.A.; Writing Manuscript - M.S.B., M.A.; Critical Review - M.S.B., M.A., A.A.

Acknowledgements: Thanks to Assoc. Prof. Mehmet Giray Sönmez for the support of statistical analysis and interpretation.

Conflict of Interest: The authors have no conflicts of interest to declare.

Financial Disclosure: The authors declared that this study has received no financial support.

References

1. Huang G.J, Stein JP. Open radical cystectomy with lymphadenectomy remains the treatment of choice for invasive bladder cancer. Curr Opin Urol 2007;17:369-75. [Crossref]
2. Moschini M, Zamboni S, Soria F, Mathieu R, Xylinas E, Tan WS, et al. Open Versus Robotic Cystectomy: A Propensity Score Matched Analysis Comparing Survival Outcomes. J Clin Med 2019;8:1192. [Crossref]
3. Gok B, Atmaca AF, Canda AE, Asil E, Koc E, Ardicoglu A, et al. Robotic Radical Cystectomy with Intracorporeal Studer Pouch Formation for Bladder Cancer: Experience in Ninety-Eight Cases. J Endourol 2019;33:375-82. [Crossref]
4. Fujimura T. Current status and future perspective of robot-assisted radical cystectomy for invasive bladder cancer. Int J Urol 2019;11:1033-42. [Crossref]

Turk J Urol 2020; 46(4): 288-96
DOI: 10.5152/tud.2020.19265

5. Witjes JA, Bruins M, Compérat E, Cowan NC, Gakis G, Hernández V. EAU Guidelines: Muscle-invasive and Metastatic Bladder Cancer. Arnhem: EAU; 2018.p.78.
6. Bi L, Huang H, Fan X, Li K, Xu K, Jiang C, et al. Extended versus non- extended pelvic lymph node dissection and their influence on recurrence- free survival in patients undergoing radical cystectomy for bladder cancer: a systematic review and meta- analysis of comparative studies. BJU Int 2014;113:E39-E48. [Crossref]
7. Wallace DM. Ureteric diversion using a conduit: a simplified technique. Br J Urol 1966;38:522-7. [Crossref]
8. Bricker EM. Bladder substitution after pelvic evisceration. Surg Clin North Am 1950;30:1511-21. [Crossref]
9. Studer UE, Turner WH. The ileal orthotopic bladder. Urology 1995;45:185-9. [Crossref]
10. Lusuardi L, Lodde M, Pycha A. Cutaneous ureterostomy. BJU Int 2005;96:1149-59. [Crossref]
11. Dindo D, Demartines N, Clavien PA. Classification of surgical complications: a new proposal with evaluation in a cohort of 6336 patients and results of a survey. Ann Surg 2004;240:205-13. [Crossref]
12. Nix J, Smith A, Kurpad R, Nielsen ME, Wallen EM, Pruthi RS. Prospective randomized controlled trial of robotic versus open radical cystectomy for bladder cancer: perioperative and pathologic results. Eur Urol 2010;57:196-201. [Crossref]
13. May M, Herrmann E, Bolenz C, Brookman-May S, Tiemann A, Moritz R, et al. Association between the number of dissected lymph nodes during pelvic lymphadenectomy and cancer-specific survival in patients with lymph node–negative urothelial carcinoma of the bladder undergoing radical cystectomy. Ann Surg Oncol 2011;18:2018-25. [Crossref]
14. Perera M, McGrath S, Sengupta S, Crozier J, Bolton D, Lawrentschuk N. Pelvic lymph node dissection during radical cystectomy for muscle-invasive bladder cancer. Nat Rev Urol 2018;15:686-92. [Crossref]
15. Yuh B, Wilson T, Bochner B, Chan K, Palou J, Stenzl A, et al. Systematic review and cumulative analysis of oncologic and functional outcomes after robot-assisted radical cystectomy. Eur Urol 2015;67:402-22. [Crossref]
16. Hussein AA, May PR, Jing Z, Ahmed YE, Wijburg CJ, Canda AE, et al. Outcomes of intracorporeal urinary diversion after robot-assisted radical cystectomy: results from the International Robotic Cystectomy Consortium. J Urol 2018;199:1302-11. [Crossref]
17. Richards KA, Kader K, Pettus JA, Smith JJ, Hemal AK. Does initial learning curve compromise outcomes for robot-assisted radical cystectomy? A critical evaluation of the first 60 cases while establishing a robotics program. J Endourol 2011;25:1553-8. [Crossref]
18. İslamoğlu E, Anıl H, Erol İ, Taş S, Ateş M, Savaş M. Robotic radical cystectomy for the management of bladder cancer: Analysis of operative and pathological outcomes of eighteen patients. Turk J Urol 2018;44:311-5.
19. Luchey AM, Agarwal G, Poch MA. Robotic-assisted radical cystectomy. Cancer Control 2015;22:301-6. [Crossref]
20. Parekh D. PNFLBA-18: a prospective, multicenter, randomized trial of open versus robotic radical cystectomy (RAZOR). J Urol 2017;197:e918. [Crossref]
21. Porreca A, Bianchi FM, Romagnoli D, D'Agostino D, Corsi P, Giampaoli M, et al. Robot-assisted radical cystectomy with totally intracorporeal urinary diversion: surgical and early functional outcomes through the learning curve in a single high-volume center. J Robot Surg 2019;1-9. [Crossref]
22. Khan MS, Gan C, Ahmed K, Ismail AF, Watkins J, Summers JA, et al. A single-centre early phase randomised controlled three-arm trial of open, robotic, and laparoscopic radical cystectomy (CORAL). Eur Urol 2016;69:613-21. [Crossref]
23. Porreca A, Chessa F, Romagnoli D, Salvaggio A, Cafarelli A, Borghesi M, et al. Robot assisted radical cystectomy with totally intracorporeal urinary diversion: initial, single-surgeon's experience after a modified modular training. Minerva Urol Nefrol 2018;70:193-201.
24. Sim A, Balbay MD, Todenhöfer T, Aufderklamm S, Halalsheh O, Mischinger J, et al. Robot–assisted radical cystectomy and intracorporeal urinary diversion–safe and reproducible?. Cent Eur J Urol 2015;68:18. [Crossref]
25. Kader AK, Richards KA, Krane LS, Pettus JA, Smith JJ, Hemal AK. Robot-assisted laparoscopic vs open radical cystectomy: comparison of complications and perioperative oncological outcomes in 200 patients. BJU Int 2013;112:E290-4. [Crossref]
26. Canda AE, Atmaca AF, Altinova S, Akbulut Z, Balbay MD. Robot-assisted nerve-sparing radical cystectomy with bilateral extended pelvic lymph node dissection (PLND) and intracorporeal urinary diversion for bladder cancer: initial experience in 27 cases. BJU Int 2012;110:434-44. [Crossref]
27. Schumacher MC, Jonsson MN, Hosseini A, Nyberg T, Poulakis V, Pardalidis NP, et al. Surgery-related complications of robot-assisted radical cystectomy with intracorporeal urinary diversion. Urology 2011;77:871-6. [Crossref]