TURKISH JOURNAL OF UROLOGY
Turk J Urol 2019; 45(Supp. 1): S166-S169 • DOI: 10.5152/tud.2018.21605
GENERAL UROLOGY
Case Report

Management of ureteral endometriosis and review of the literature

Fuat Kızılay, Adnan Şimşir, Oktay Nazlı

Cite this article as: Kızılay F, Şimşir A, Nazlı O. Management of ureteral endometriosis and review of the literature. Turk J Urol 2019; 45(Supp. 1): S166-S169.

ABSTRACT

Endometriosis can affect 10-15% of the women in their reproductive age and it is characterized with the presence of the functional endometrium tissue outside the uterine cavity. Up to 10% of the cases with urinary system endometriosis may involve the ureter. Left distal ureter is the most common site of involvement. The differentiation between intrinsic and extrinsic endometriosis is very substantial for the selection and application of definitive treatment. Medical and surgical treatment alternatives are available for endometriosis management and histopathologic examination is required for definitive diagnosis. In this case report, a 33-year-old patient underwent segmental ureter excision and ureteroureteral anastomosis due to endometriosis causing obstruction in the left distal ureter. The operation was performed through a left Gibson incision and a 6 Fr double J stent was implanted in the ureter. The stent was removed after 4 weeks and the control magnetic resonance imaging-urography was performed at 3 months postoperatively. Obstruction and hydroureteronephrosis were observed to be completely regressed in control. If there is no other obvious etiology for the presence of unilateral hydroureteronephrosis in women in their reproductive age, the diagnosis of endometriosis should be considered.

Keywords: Endometriosis; hydronephrosis; magnetic resonance imaging; open surgery; ureter.

Introduction

Endometriosis is an estrogen-dependent disease characterized by the presence and growth of functional endometrium tissue outside the uterus.[1,2] Ten percent of women in their reproductive age are affected by the disease and the most common symptoms are acute or chronic pelvic pain, abnormal bleeding and infertility.[3] Endometriosis can affect the urinary system as well as the whole body, and the bladder and ureter are the most frequently affected organsin the urinary system endometriosis. Approximately 1% of women with pelvic endometriosis have a urinary system endometriosis.[4] Ureteral endometriosis is very rare with an estimated prevalence of 0.1%. Within the entire urinary system endometriosis, the prevalence of ureteral endometriosis is approximately 10%.[5] Up to 50% of women with ureteral endometriosis are asymptomatic, 25% have colicky pain, and 15% have gross hematuria.[6] Tissue biopsy and histopathological examination is the gold standard method for the diagnosis of ureteral endometriosis. The primary treatment for ureteral endometriosis is surgery. Although successful medical treatment outcomes have been reported in the literature, it is not enough to cure the fibrotic component of the lesion, and there is a risk of deterioration in renal function in case of medical treatment failure.[7,8]

Herein, we report our treatment management and outcome for a patient diagnosed with left ureteral endometriosis.

Case presentation

A 33-year-old woman was admitted to a urology clinic due to complaints of cyclic hema-

Department of Urology, Ege University School of Medicine, İzmir, Turkey

Submitted: 06.03.2018
Accepted: 30.03.2018
Available Online Date: 19.12.2018

Corresponding Author: Fuat Kızılay
E-mail: fuatkizilay@gmail.com

©Copyright 2019 by Turkish Association of Urology

Available online at www.turkishjournalofurology.com

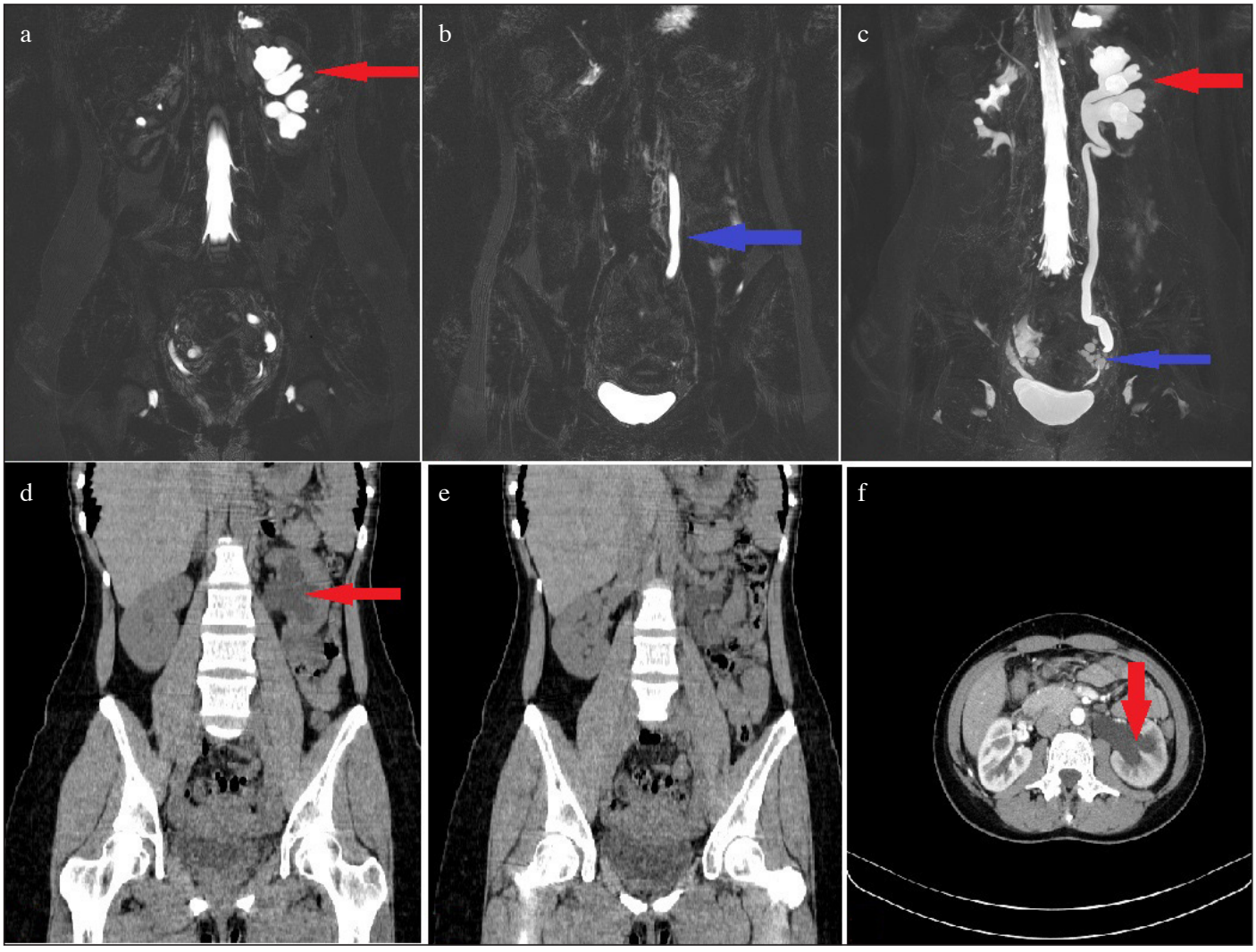

Figure 1. a-f. Preoperative MRI and CT images of the patient. Images a, b and c show dilated pelvicalyceal system (shown with red arrows), ureter and its stenotic segment (shown with blue arrows). Non-contrast CT images of the left dilated urinary tract are shown in images d, e and f

turia, nausea, vomiting, diarrhea and left groin pain starting on the honeymoon after geting married in October 2017. Physical examination revealed left costovertebral angle tenderness. No abnormality was found in biochemical tests. Thereupon, the patient underwent non-contrast and contrast -enhanced computed tomography (CT) and magnetic resonance imaging (MRI) of the left kidney pelvicalyceal system, and ureteral dilation until distal ureter and subsequent 1.5-2 cm stenotic area were detected. In the non-contrast CT, any opacity suggesting stone in the urinary system was not observed. The patient's preoperative non-contrast CT and MR-urography images are shown in Figure 1. Ureteroscopy revealed suspicious tumor formation in the left distal ureter and biopsy of the lesion was performed. Double J stent was implanted after left ureteral biopsy. After 3 weeks, the stent was removed and the patient underwent a control MRI. The patient was referred to us after this stage and we recommended an open operation to the patient upon the continuation of the left hydroureteronephrosis in MRI and mention of ureteral endometriosis in the ureteral biopsy report. Meanwhile, the patient underwent a gynecological consultation and no pathological finding was found in gynecological examination and tumor markers were normal.

The patient was scheduled for a definitive open surgery. The patient's informed consent was obtained and the patient was operated after the necessary preparations were completed. A left Gibson incision was made. The ureter was suspended from the middle, dissected toward the distal ureter and the ureter was observed to be dilated until the distal end. The left distal ureter had a narrow segment of about 3.5-4 cm nearby the left over, and thereafter the ureter was observed in normal width. The area of the narrow ureter segment was quite fibrotic and stiff. The nar-

Turk J Urol 2019; 45(Supp. 1): S166-S169
DOI:10.5152/tud.2018.21605

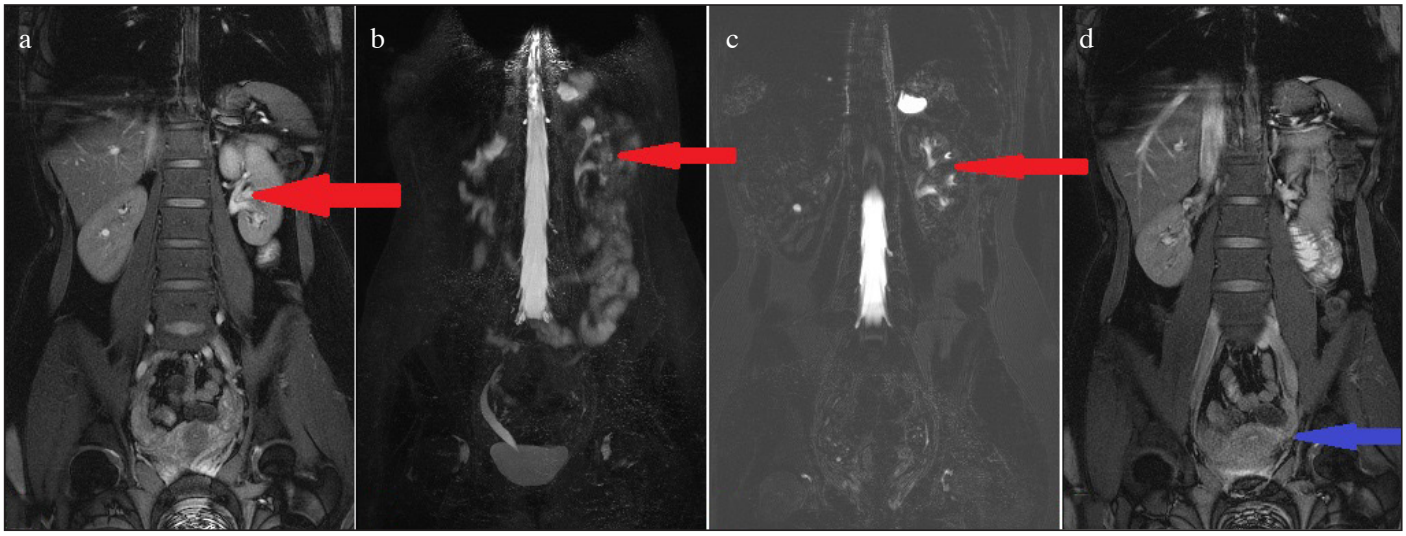

Figure 2. a-d. Postoperative MRI images of the patient. Images a, b and c show the pelvicalyceal system (shown with red arrows) and ureter (shown with blue arrow) in normal width, and image d shows distal ureter in normal calibre

row segment was excised, and a 6 Fr double J stent was inserted into the ureter, and the ureter was anastomosed end-to-end with a 4-0 polyglactin suture. A Jackson-Pratt drain was placed in the operation field and the operation was terminated. The patient's drain was removed on the first postoperative day and the patient was discharged on the second day without any problems.

Histopathological examination of the ureteral segment was consistent with endometriosis in ureteral serosa. The patient was consulted with gynecology and early pregnancy was recommended. The patient's ureteral stent was removed after 4 weeks and a control MRI was performed at 3 months postoperatively. MRI revealed that the pelvicalyceal system and the entire ureter were in normal width and the ureterovesical junction was in normal caliber. Postoperative MR-urography images of the patient are shown in Figure 2.

Discussion

Endometriosis is defined as the presence of functional endometrial tissue elsewhere outside the uterine fundus. It is defined in almost 10% of women in reproductive age and particularly peaks in the mid-20s.[9] Ureter may be involved in 15-20% of cases with urinary system endometriosis and this involvement may be intrinsic or extrinsic. Intrinsic endometriosis is characterized by stroma and endometrial glands in lamina propria, tunica muscularis, or ureteral lumen; while extrinsic endometriosis is localized only to ureteral adventitia and periureteral tissues. The most common form of ureteral endometriosis is the extrinsic form observed in 80% of the patients. The left side is involved in 64%, while the both sides in 19% of the cases.[10] All of the 6 cases reported by Vercellini et al.[10], had obstruction in the distal ⅓ of the left ureter secondary to endometriosis as in our case.

Slightly more than half of the patients with ureteral obstruction secondary to endometriosis have symptoms. Symptoms such as lumbar pain, dysuria, urgency, urinary tract infections and hematuria may be seen in these patients. These symptoms are more common in patients with intrinsic endometriosis than those in the extrinsic disease group.[11]

The goal in the treatment of ureteral endometriosis is to relieve obstruction and maintain renal function. In addition, obtaining a definitive histopathological diagnosis of the disease and planning advanced treatment are the secondary targets. Maintaining the fertility of the patient and alleviating the symptoms of the patient with the least invasive available methods are also substantial. Ureterolysis may be the first option for patients with mild hydronephrosis, but segmental ureter excision followed by ureteroureteral anastomosis or ureteroneocystostomy may be necessary for patients with moderate or severe hydronephrosis. Our patient had severe hydronephrosis and associated flank pain. Ureterolysis could not be performed due to severe fibrosis in the area where the narrow ureter segment was located, but a ureteroureteral anastomosis was performed without the necessity of ureteroneocystostomy by using the normal structured ureter after the narrow segment.

Asymmetric involvement of the distal segment of mostly left ureter has been reported in many cases of ureteral endometriosis. Hematuria is seen in 15% of the patients and cyclic hematuria is frequently seen in intrinsic type.[12] Our patient also had cyclic hematuria and the site of involvement was the left distal ureter in accordance with the literature.

Ultrasound, CT, MRI and intravenous urography are commonly used imaging methods for the diagnosis of ureteral endometriosis. Although imaging modalities, particularly including

urographic components, provide detailed information about the anatomy and function of the urinary tract, they provide limited information about the preoperative diagnosis of the endometriosis. The definitive diagnosis of the disease is based on histopathological examination. In other words, surgery is essential for diagnosis. Diagnostic laparoscopy may reveal endometrial foci but may be insufficient for the diagnosis of intrinsic endometriosis.[13] Both medical and surgical treatment methods can be utilized.[14] Patient age, symptom severity, grade of hydronephrosis, experience of the surgeon and the preference of the patient are important factors in determining the treatment method. A multidisciplinary approach is crucial for the optimization of treatment. For patients with moderate-to-severe hydronephrosis, an end-to-end anastomosis or a neocystostomy after excising the narrow ureter segment is more appropriate. The severe hydroureteronephrosis and left distal ureteral stricture demonstrated by MRI-urography in our patient was suggestive of the ureteral endometriosis. We did not consider medical treatment due to the presence of advanced hydronephrosis and severe symptoms of the patient. We preferred open surgery because of our intention to make a histopathological diagnosis and having more experience with this method. The patient's postoperative control revealed that our decision was appropriate.

Endometriosis is a devastating disease that is common in women in the reproductive age group and may affect the urinary tract. Diagnosis of endometriosis should be considered in women who have a colicky pain and hydronephrosis which is detected in imaging methods and not caused by a urological etiology and further examinations should be performed in these patients.

Informed Consent: Written informed consent was obtained from patient who participated in this case.

Peer-review: Externally peer-reviewed.

Author Contributions: Concept – F.K., A.Ş., O.N.; Design – F.K., A.Ş., O.N.; Supervision – A.Ş., O.N.; Resources – F.K., A.Ş., O.N.; Materials – F.K., A.Ş., O.N.; Data Collection and/or Processing – F.K., A.Ş., O.N.; Analysis and/or Interpretation – F.K., A.Ş., O.N.; Literature Search – F.K.; Writing Manuscript – F.K.; Critical Review – A.Ş., O.N.

Conflict of Interest: The authors have no conflicts of interest to declare.

Financial Disclosure: The authors have declared that they did not receive any financial support for this study.

References

1. Giudice LC, Kao LC. Endometriosis. Lancet 2004;364:1789-99. [CrossRef]
2. Lagana AS, Sturlese E, Retto G, Sofo V, Triolo O. Interplay between Misplaced Mullerian-Derived Stem Cells and Peritoneal Immune Dysregulation in the Pathogenesis of Endometriosis. Obstet Gynecol Int 2013;527041.
3. Marana R, Lecca A, Biscione A, Muzii L. Endometriosis: the gynecologist's opinion. Urologia 2012;79:160-6. [CrossRef]
4. Berlanda N, Vercellini P, Carmignani L, Aimi G, Amicarelli F, Fedele L. Ureteral and vesical endometriosis. Two different clinical entities sharing the same pathogenesis. Obstet Gynecol Surv 2009;64:830-42. [CrossRef]
5. Yohannes P. Ureteral endometriosis. J Urol 2003;170:20-5. [CrossRef]
6. Comiter CV. Endometriosis of the urinary tract. Urol Clin North Am 2002;29:625-35. [CrossRef]
7. Rivlin ME, Krueger RP, Wiser WL. Danazol in the management of ureteral obstruction secondary to endometriosis. Fertil Steril 1985;44:274-6. [CrossRef]
8. Maccagnano C, Pellucchi F, Rocchini L, Ghezzi M, Scattoni V, Montorsi F, et al. Diagnosis and treatment of bladder endometriosis: state of the art. Urol Int 2012;89:249-58. [CrossRef]
9. Eskenazi B, Warner ML. Epidemiology of endometriosis. Obstet Gynecol Clin North Am 1997;24:235-58. [CrossRef]
10. Vercellini P, Pisacreta A, Pesole A, Vicentini S, Stellato G, Crosignani PG. Is ureteral endometriosis an asymmetric disease? BJOG 2000;107:559-61.
11. Kumar S, Tiwari P, Sharma P, Goel A, Singh JP, Vijay MK, et al. Urinary tract endometriosis: Review of 19 cases. Urol Ann 2012;4:6-12. [CrossRef]
12. Hsieh MF, Wu IW, Tsai CJ, Huang SS, Chang LC, Wu MS. Ureteral endometriosis with obstructive uropathy. Intern Med 2010;49:573-6. [CrossRef]
13. Muse K. Clinical manifestations and classification of endometriosis. Clin Obstet Gynecol 1988;31:813-22. [CrossRef]
14. Nishihara K, Kawai N, Hibino M, Tozawa K, Sasaki S, Hayashi Y, et al. Clinical evaluation of ureteral endometriosis: report of 8 cases. Hinyokika Kiyo 2003;49:185-7.