Turk J Endocrinol Metab. 2020;24:163-167

The Case of a Multi-Locular Bronchogenic Cyst Found in Periadrenal Fatty Tissue

Periadrenal Yağlı Dokuda Saptanan Multiloküle Bronkojenik Kist

Yasemin EMÜR GÜNAY, Savaş Volkan KİŞİOĞLU, Emel ÇAKIR*, Selçuk AKKAYA**, Hülya COŞKUN

Karadeniz Technical University Faculty of Medicine, Division of Endocrinology and Metabolism Diseases, Trabzon, TURKEY
*Karadeniz Technical University Faculty of Medicine, Department of Medical Pathology, Trabzon, TURKEY
**Karadeniz Technical University Faculty of Medicine, Department of Radiology, Trabzon, TURKEY

Abstract

Bronchogenic cysts are rare congenital cystic lesion formed during the migration of embryonic primitive foregut buds during early embryogenesis. Although they are most commonly located in the mediastinum, in some rare cases, they are found localized in the periadrenal area. In our male patient in 22 year old who had no symptomps, a multiloculated bronchogenic cyst was detected incidentally in the periadrenal area. The lesion was located in the left adrenal area as observed using imaging techniques. The large mass was extracted by laparoscopy to confirm the diagnosis. Histopathological examination described the cyst as multilocular and bronchogenic. The case was presented to us because of the rare occurrence of bronchogenic cysts in the periadrenal area, and an accompanying ectopic kidney condition.

Keywords: Bronchogenic cysts; periadrenal mass; ectopic kydney

Özet

Bronkojenik kistler embriyojenik primitif ön bağırsağın tomurcuklarının göçü sırasındaki kalıntılarından oluşan, nadir görülen konjenital kistik lezyonlardır. Lokalizasyon olarak daha çok mediastende yer alırken, az sayıda periadrenal alanda da rapor edilmiştir. Herhangi bir semptomu olmayan 22 yaşındaki erkek hastamızda, rastlantısal olarak periadrenal alanda multiloküle bronkojenik kist saptanmıştır. Görüntüleme yöntemleri ile sol adrenal alanda saptanan büyük kitle, tanıyı kesinleştirmek amacıyla laparoskopik olarak çıkarılmıştır. Histopatolojik inceleme sonucunda multiloküle bronkojenik kist olarak rapor edilmiştir. Bu olgu çalışması, periadrenal alanda bronkojenik kistlerin nadir görülmesi ve ektopik böbrek ile birliktelik göstermesi nedeni ile sunulmuştur.

Anahtar kelimeler: Bronkojenik kist; periadrenal kitle; ektopik böbrek

Introduction

Bronchogenic cysts (BC) are rare congenital cystic lesions formed during the migration of embryonic primitive foregut buds during early embryogenesis (1). They are usually found in the posterior mediastinum, but they may rarely be found in adrenal glands (2). Morphologically, they have the same characteristics as the tracheobronchial system. Most BC are asymptomatic in the early stages, but they can become symptomatic because of pressure caused by the cyst in the surrounding area.

Additionally, BC can cause bleeding, rupture or infections (3). Malignant transformation is very rare, with only 0.7% risk (4). A case study, in which a bronchogenic cyst was located in the adrenal area, was presented to us.

Address for Correspondence: Yasemin EMÜR GÜNAY, Karadeniz Technical University Faculty of Medicine, Division of Endocrinology and Metabolism Diseases, Trabzon, TURKEY/TÜRKİYE
Phone: :+90 533 039 12 90 **E-mail:** yaseminemur@hotmail.com

Peer review under responsibility of Turkish Journal of Endocrinology and Metabolism.

Received: 06 Nov 2019 **Received in revised form:** 03 Feb 2020 **Accepted:** 09 Mar 2020 **Available online:** 09 Apr 2020

1308-9846 / ® Copyright 2020 by Society of Endocrinology and Metabolism of Turkey.
Publication and hosting by Turkiye Klinikleri.
This is an open access article under the CC BY-NC-SA license (https://creativecommons.org/licenses/by-nc-sa/4.0/)

DOI: 10.25179/tjem.2019-71985

Case Report

A 22-year old male patient with known ectopic kidney condition was referred to a urologist while having a routine assessment for work. Ultrasonography showed a suspicious mass in the left adrenal area. Abdominal magnetic resonance imaging (MRI) produced axial pre-contrast T1-weighted in-phase and out-of-phase images that showed a left adrenal cystic mass with hyperintense nodular components and no signal reduction. Axial post-contrast T1-weighted images showed no enhancement of these nodular components. Coronal T2-weighted images showed a hyperintense left adrenal cystic mass with hypointense nodular components (Figure 1A-E).

The urologist referred the patient to our clinic for adrenal mass evaluation. The patient had no symptoms on his first visit. The physical examination report was normal. He was admitted to our clinic to assess whether the adrenal mass secreted hormones or not. His blood pressure was 110/70 mmHg, pulse 80 beats per minute, and EKG was normal. No abnormalities were found in his hemogram or biochemical marker test results. All hormonal test results were within the normal range. The results of the patient's tests are shown in Table 1. To test for congenital adrenal hyperplasia (CAH), 17-OH progesterone test was done. 17-OHP levels were elevated (2,49 ng/mL); therefore, Synacten® stimulation test was performed by intravenous injection of 250 mcg Synacthen. Based on the test results, CAH was ruled out. The mass was of a non-secretory type, but it was not clear whether the mass was separate from the left adrenal gland.

An abdominal computerized tomography (CT) scan detected a 78x39 mm-sized heterogenic dense lesion, which may have been caused by calcification or hemorrhage in the left adrenal gland. The density of lesion ranged from 18 HU in contrast-free sequences, 15 HU in portal venous phase, to 16 HU in post-contrast sequences. The 15th minute mass was evaluated, and washout amount was calculated as 33%. Radiologists reported it as lipid-poor adenoma, non-adenomatous mass, or cystic mass (Figure 2A-C). Since it could not be clearly determined as adenoma or non-adenoma by CT, positron emission computerized tomography (PET-CT) was performed. PET-CT showed the left kidney in the pelvic location and on the left of midline (ectopic kidney). It also showed a 69x35x90 mm sized hypodense lesion in the lower regions of hyperdense

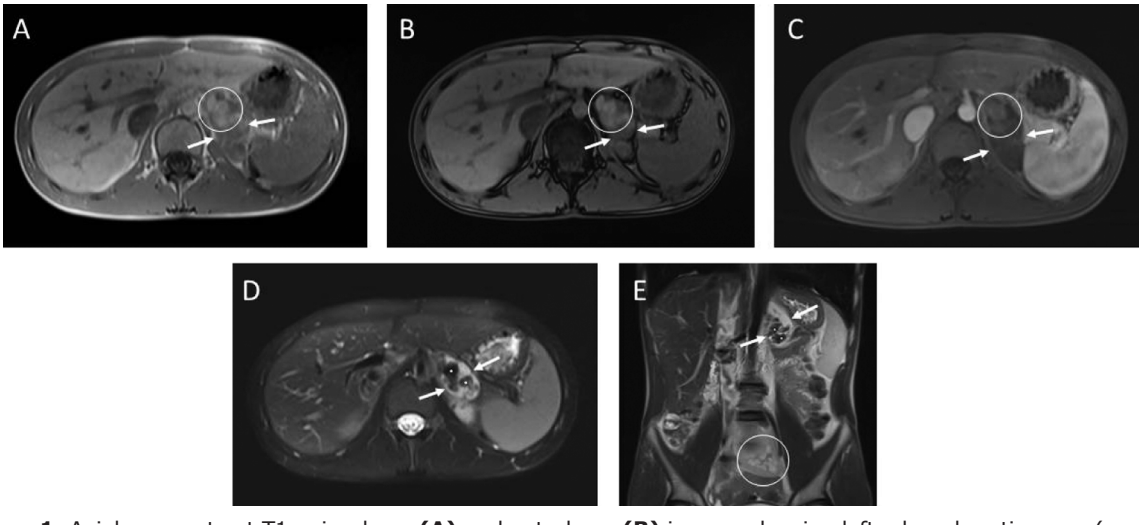

Figure 1: Axial pre-contrast T1-w in-phase **(A)** and out-phase **(B)** images showing left adrenal cystic mass (arrows) with hyperintense nodular components (circles) and no signal reduction. Axial post-contrast T1-w image **(C)** showing no enhancement of these nodular components. Coronal **(D)** T2-w images showing left adrenal hyperintense cystic mass (arrows) with hypointense nodular components (stars). The left kidney is also seen in the pelvis on coronal T2-w image (circle) **(E)** (informed consent was taken for the image from the patient).

Table 1. Results of the hormone evaluation.

Test	Patient's value	Reference values
ACTH	21.3 ng/L	6.7-22.6 ng/L
Cortisol	13.67 µg/dL	≤46 µg/dL
Dexamethasone Suppression Test (1 mg)	0.63 µg/dL	
Dehydroepiandrosterone Sulfate	215 µg/dL	
Testosterone	5.18 µg/dL	
Aldosterone (ALD)	18 ng/dL	7-30 ng/dL
Plasma Renin Activity (PRA)	3.68 ng/mL/h	0.98-4.18 ng/mL/h
ALD/PRA	4.89	
Plasma Metanephrine Level	31.74 pg/mL	≤90 pg/mL
Plasma Normetanephrine Level	54.66 pg/mL	≤180 pg/mL
Urine Metanephrine	101.67 µg/24 h	50-250 µg/24 h
Urine Normetanephrine	218.69 µg/24 h	100-500 µg/24 h

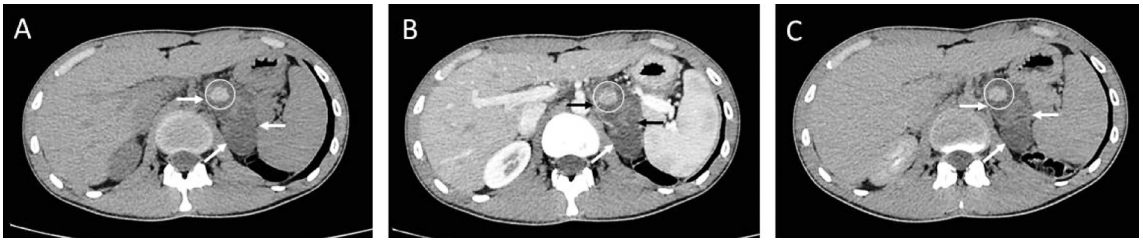

Figure 2: Pre-contrast **(A)** axial abdominal CT image showing left adrenal cystic mass (arrows) with hyperdense nodular component (circle). Post-contrast portal venous phase **(B)** and post-contrast delayed phase **(C)**.

areas with minimally elevated FDG absorbance (SUV_{max}: 1,59) in the left adrenal area. It was assumed to be a benign lesion. Even though PET-CT and MRI reported the lesion as benign, the mass was still surgically removed due to its large size and non-adenomatous type, as reported by CT scan. Therefore, the patient underwent laparoscopic left adrenalectomy and mass excision. There were no complications during or after surgery. The extracted mass weighed 116 grams. The pathology report described the mass as a 9x6x3 cm-sized specimen that appeared to be yellow-cream in color

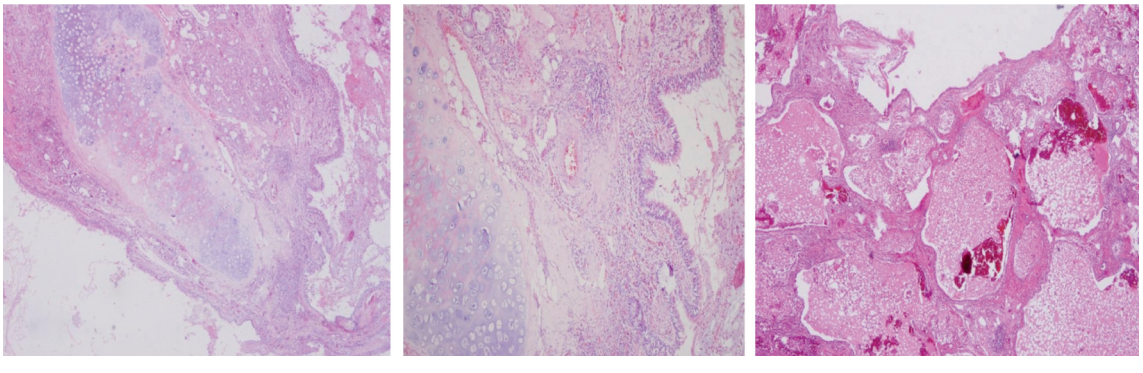

Figure 3: (A) Histomorphology showing cystic areas like normal bronchia; respiratory type epithelium covered mature cartilage and mucous glands (HE, x40). **(B)** Pseudostratified ciliary columnar epithelium containing epithelial mucous secreting goblet cells (HE, x100). **(C)** Multi locular bronchogenic cyst. The cystic areas containing lots of macrophages and pink homogenous fluid (HE, x40).

and wholly cystic. The peripheral sections showed hard adrenal tissue. In summary, the specimen was evaluated to be periadrenal fatty tissue with a multilocular bronchogenic cyst that was removed by left adrenalectomy (Figure 3A-C). The patient was discharged after one week and has been followed up regularly.

Discussion

Bronchogenic cysts (BC) are congenital abnormalities that can occur in a person of any age. They generally tend to be benign and are seldom found in non-thoracic areas (5). Most retroperitoneal BC are found in the left adrenal gland, like in the case study of Govarts et al. (2) Clinical symptoms vary according to the size and location of the cyst. These lesions are mostly asymptomatic. In otherwise rare cases, the most common symptom is a persistent stomachache. Diagnosing BC preoperatively is challenging; they may be misdiagnosed as adrenal tumors, hemorrhagic cysts or pancreatic lesions (5). Adrenal carcinomas stand out with irregular shapes, vague borders, heterogeneity, and hemorrhages inside the tumor in imaging techniques. In our case study, heterogeneity of the mass, and size greater than 6 cm indicated the possibility of adrenal carcinoma. However, the presence of clean and clear borders in tomography contradicted this idea.

Laboratory tests in adrenal masses tend to be normal. Approximately 40% of adrenal carcinomas are non-functional (6). In our case study, there were no abnormalities in hormonal level tests.

There is no specific imaging technique to identify BC. Ultrasonography cannot provide sufficient information for adrenal area. The most valuable imaging techniques to locate BC are computerized tomography (CT) and magnetic resonance imaging (MRI). CT images show well-formed, non-contrast, mono- or multilocular lesions. Calcification can be seen on borders. However, protein-rich lesions can imitate solid lesions (7). If CT is unable to exclude solid mass, then T2 sequence of MRI images show cystic lesions as hyperintense. In our case study, failure to exclude malignancy with CT led us to perform PET-CT. SUV_{max} rate was found to be low; therefore, malignancy was excluded. Though malignancy was excluded, the cyst was removed by surgery due to its large size and insufficient information on differential diagnosis by PET-CT.

Histological analysis of BC showed respiratory epithelium (pseudostratified ciliary and cuboidal), smooth muscle, goblet cells, and rarely cartilage. This indicated abnormal budding of tracheobronchial tree and migration to retroperitoneum before the closure of the diaphragm. It is imperative to find out whether BC had differentiated from primary or metastatic teratoma, but most BC tend to differentiate in parallel with normal tracheobronchial structures. Immature components, atypia, and necrotic tumors do not exist (8). In our case study, histological analysis showed that cystic areas of BC were like normal bronchia, covered with respiratory type epithelium, mature cartilage, and mucous glands.

Surgical resection is usually advised, whether condition is symptomatic or not, to confirm the diagnosis, and to prevent further complications (9). Chung et al. reported retroperitoneal laparoscopic surgery to be effective and safe (10). In our case study, surgery was performed laparoscopically, and no complications were encountered.

In conclusion, as rare as they are, BC should be considered in the differential diagnosis of adrenal masses. It is remarkable that in our case study, the ectopic kidney was found along with BC. Therefore, if ectopic kidney condition is present with a retroperitoneal mass, BC should be considered. Retroperitoneal surgery is required for both diagnosis and treatment. Post-operative results are mostly successful.

Source of Finance

During this study, no financial or spiritual support was received neither from any pharmaceutical company that has a direct connection with the research subject, nor from a company that provides or produces medical instruments and materials which may negatively affect the evaluation process of this study.

Conflict of Interest

No conflicts of interest between the authors and / or family members of the scientific and medical committee members or members of

the potential conflicts of interest, counseling, expertise, working conditions, share holding and similar situations in any firm.

Authorship Contributions

Idea/Concept: Design: Control/Supervision: Data Collection and/or Processing: Analysis and/or Interpretation: Literature Review: Writing the Article: Critical Review: References and Fundings: Materials:

References

1. Sarper A, Ayten A, Golbasi İ, Demircan A, Isin E. Bronchogenic cyst. Tex Heart Inst J. 2003;30:105-108. [PubMed]
2. Govaerts K, Van Eyken P, Verswijvel G, Van der Speeten K. A bronchogenic cyst, presenting as a retroperitoneal cystic mass. Rare Tumors. 2013;4:e13. [Crossref] [PubMed] [PMC]
3. Farag M, Naguib N, Izzidien A. Bronchogenıc cyst, case report and review of literature. The West London Medical Journal. 2010;2:1-4.
4. Kirmani B, Kirmani B, Sogliani F. Should asymptomatic bronchogenic cysts in adults be treated conservatively or with surgery? Interact Cardiovasc Thorac Surg. 2010;11:649-659. [Crossref] [PubMed]
5. Haddadin WJ, Reid R, Jindal RM. A retroperitoneal bronchogenic cyst: a rare cause of a mass in the adrenal region. J Clin Pathol. 2001;54:801-802. [Crossref] [PubMed] [PMC]
6. Wang SE, Tsai YF, Su CH, Shyr YM, Lee EC, Tsai WC, Li FY, Chen TH, Wu CW, Lui WY. Retroperitoneal bronchogenic cyst mimicking pancreatic cystic lesion. J Chin Med Assoc. 2006;69:538-542. [Crossref] [PubMed]
7. Tokuda N, Naito S, Uozumi J, Shimura H, Takayanagi R, Kumazawa J. A retroperitoneal bronchogenic cyst treated with laparoscopic surgery. J Urol. 1997;157:619. [Crossref] [PubMed]
8. Roma A, Varsegi M, Magi-Galluzzi C, Ulbright T, Zhou M. The distinction of bronchogenic cyst from metastatic testicular teratoma: a light microscopic and immunohistochemical study. Am J Clin Pathol. 2008;130:265-273. [Crossref] [PubMed]
9. Ishikawa T, Kawabata G, Okada H, Arakawa S, Kamidono S, Fujisawa M. Retroperitoneal bronchogenic cyst managed with retroperitoneoscopic surgery. J Urol. 2003;169:1078-1079. [Crossref] [PubMed]
10. Chung JM, Jung MJ, Lee W, Choi S. Retroperitoneal bronchogenic cyst presenting as adrenal tumor in adult successfully treated with retroperitoneal laparoscopic surgery. Urology. 2009;73:442.e13-15. [Crossref] [PubMed]