Intercaval bundle connecting posterosuperior right atrium to right superior pulmonary vein detected during catheter ablation for atrial fibrillation

Emir Baskovski, Başar Candemir, Kerim Esenboğa, Ali Timuçin Altın, Durmuş Eralp Tutar
Department of Cardiology, Faculty of Medicine, Ankara University; Ankara-*Turkey*

Introduction

Catheter ablation of atrial fibrillation (AF) is one of the most complex interventional electrophysiologic procedures. Since the ectopic supraventricular beats and paroxysms of AF originating from pulmonary veins (PV) was first observed (1), pulmonary vein isolation (PVI) became the primary treatment target of AF catheter ablation. The entrance and exit blocks in the PVs confirm successful PVI. Inability to achieve PVI and PV reconnection, which can be observed very early after procedure (2), are frequent causes of AF recurrence and necessitate a repeat procedure (3). When circumferential PV antral ablation fails to achieve PVI, it is usually due to a gap in the ablation line. When the gap is mapped and successfully ablated, durable PVI is usually achieved. Another possible cause of persistent PV conduction is an interesting and probably rare phenomenon, in which the designated exit and entrance site for conduction is an intercaval bundle (IB), an anatomical structure that connects one of the PVs to the right atrium (4). IC has been previously defined in anatomical studies of the heart (5). In this case report, we start with a description of an AF ablation procedure where the persistent PV conduction could not be abolished with PV antral ablation, leading to identification of an IB, whose entry site at right atrium had to be ablated to achieve a durable PVI. Thereafter, we discuss the importance and differential diagnosis of persistent PV electrograms along with the necessity for confirming the position of the entrance and exit block in AF ablation.

Case Report

A 60-year-old female patient with highly symptomatic paroxysmal AF episodes was admitted to our clinic for catheter ablation and subsequent AF. Under general anesthesia, a double transseptal puncture was performed, following which the left atrial voltage and anatomic map was created and merged with computerized tomography data using the CARTO3 mapping system (Biosense-Webster, Diamond Bar, CA, USA). The left atrial anatomy was unremarkable and the left-sided PVs were easily isolated using an irrigated-tip RF ablation catheter. The position of the entrance and exit block were confirmed for each of the left-sided veins.

During the isolation of the right-sided veins, a persistent PV-like potential in the distal anterior part of the right superior pulmonary vein (RSPV) (Fig. 1: earliest in Lasso pair 5-6) was noted to be remaining, despite the completion of an ablation index-guided encirclement lesion-set and subsequent multiple ablation attempts in the anterior part of the RSPV antrum. We noted that the PV-like potential originated much earlier while the catheter was inserted into the distal part of RSPV. During low-output (5 mA, 1 millisecond) high-right atrium (HRA) pacing, the potentials were minimally advanced but remained separate. On the other hand, the RSPV and both atria were consistently being captured during low-output pacing with Lasso pair 5-6 (5 mA, 1 millisecond) as HRA signals were pulled in and CS signals became significantly delayed with a concentric activation pattern, similar to what is routinely seen in sinus rhythm. These observations suggested that an exit block was present between the right-sided veins and the left atrium. However, the stimulus that was activating the right atrium first was also subsequently activating the left atrium through the CS, a phenomenon which indicated the presence of a bypass tract or an IB connecting the HRA- SVC (superior vena cava) to RSPV.

Following this observation, we initially tried to target the earliest site inside the vein (Fig. 2; white dot) with a touch-up ablation lesion of 25 Watts, which failed to abolish the signal but transiently decreased its amplitude, while the vein contin-

Figure 1. Intracardiac electrogram obtained during the ablation procedure. Surface electrocardiograms (I, II), electrograms from distal high-right atrium (HRAd), coronary sinus distal-to-proximal electrograms (CSD, CS2, CS3, CS4, CSP), electrograms within pulmonary veins (obtained using the Lasso catheter, L1-2 to 19-20), and mapping catheter electrograms are depicted. Persistent pulmonary vein potentials observed in Lasso pair 5-6 (and probably pair 3-4) are marked by blue ovals

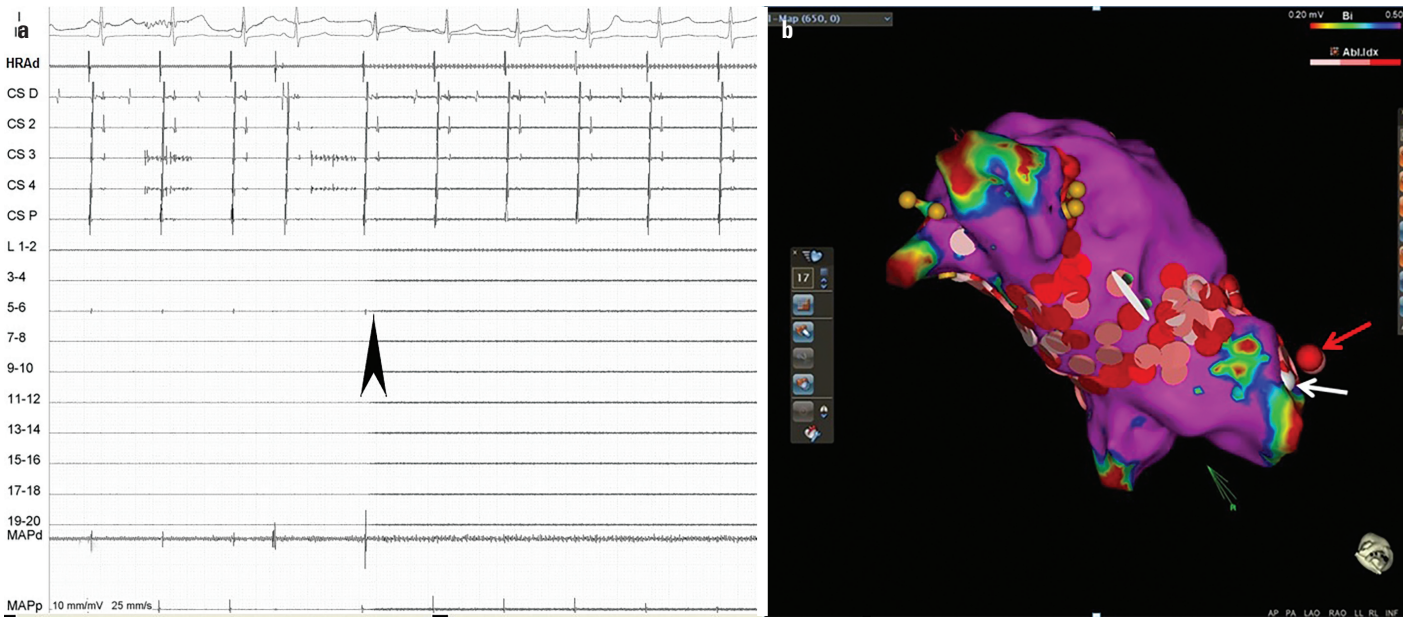

Figure 2. (a) Local electrograms recorded in the right superior pulmonary vein using a Lasso catheter. Left to the arrowhead are local electrograms recorded during radiofrequency energy delivery in Lasso pair 5-6. Local signals are abolished 2 seconds after energy delivery. (b) 3-D electro-anatomic map. The white dot represents the earliest activation site during pulmonary vein pacing. The site of radiofrequency energy delivery is marked by a red arrow

ued to get captured (Fig. 1). Afterwards, we targeted the right atrial posterior wall counterpart with the earliest signal during PV pacing (Fig. 2; white dot). Rf at 35 Watts (Fig. 2; red arrow) rapidly abolished the small electrograms after 2 seconds (Fig. 2) and successfully completed the isolation of RSPV with a durable exit and entrance block, confirmed after a waiting period of 20 minutes and subsequent testing with adenosine (Fig. 3). Posterior wall isolation and cavotricuspid isthmus ablation were also performed afterwards at the discretion of the operator, due to an ongoing clinical trial. The follow-up period was uneventful and the patient was discharged the next day. Ambulatory electrocardiography recordings taken 24-hourly at 1 month, 2 months, 3 months, and 6 months were normal, and the patient self-reported as being completely asymptomatic at the follow-up visits.

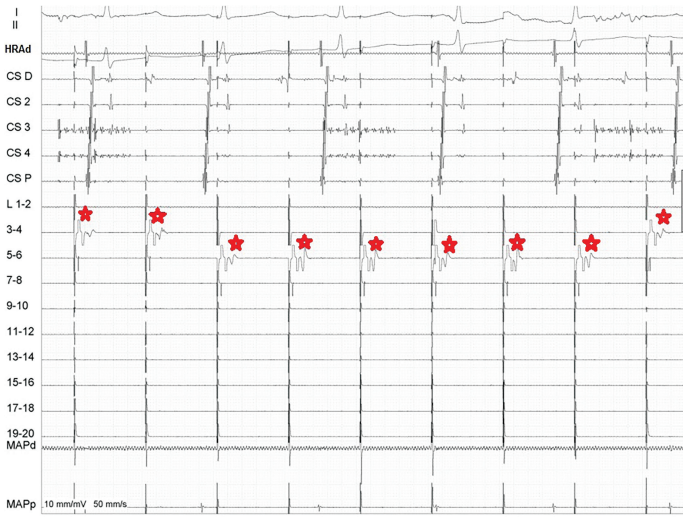

Figure 3. Intracardiac electrogram during pacing using Lasso (*) catheter inside pulmonary veins reveals an exit block

Discussion

In the early 20th century, extensive anatomical studies performed by Keith et al. (5). revealed that direct fibers connecting left and right atrium existed, including the Bachmann bundle, CS bundle, and IB. Electrophysiologic properties of these connections continue to be elucidated with advanced electro-anatomic mapping systems. While the Bachmann bundle is the best-defined structure, IB runs posteriorly between the left atrial and right PV region and the intercaval region on right atrium. This anatomical variant has been previously observed while performing a AF ablation procedure (4).

Any PV potentials observed during circumferential PV antral ablation should be extensively investigated before attributing them as being far-field signals. In our case, pacing within the PV failed to demonstrate an exit block, however, it is important to note that concentric CS activation was delayed as compared to high-right atrial activation, which could point to activation with a bypass tract. We presumed that an IB was conducting signals from the RSVP to posterior-superior RA (location of HRA catheter). RF ablation of earliest RA activation region eliminated PV potentials and also resulted in a successful exit block.

When analyzing persistent signals following antral ablation, the operator must differentiate PV potentials from far-field signals that commonly originate from structures such as the left atrial ap-

pendix and the superior vena cava (6). Both activation mapping and differential pacing maneuvers are useful in PV electrogram analysis. One of distinguishing features of far-field PV signals is that as the recording catheter is advanced distally, the amplitude of the signal decreases. This feature contrasts with signals obtained in our case, where signals became more accentuated as the catheter was advanced distally into the vein. IB fibers, inserted into the PV region that is distal to the antrum, give rise to PV potentials that become earlier and have higher amplitude as the recording catheter is advanced distally inside the PV.

In this case, we would like to emphasize the importance of investigating PV potentials before attributing them as far-field signals, as this may be an important determinant in the ablation success.

Conclusion

This case illustrates the presence of an electrical connection tract, i.e., the IB, between the posterior right atrium and anterior aspect of RSPV which could only be abolished by right atrial ablation.

Informed consent: Written informed consent was obtained from this patient.

References

1. Haïssaguerre M, Jaïs P, Shah DC, Takahashi A, Hocini M, Quiniou G, et al. Spontaneous initiation of atrial fibrillation by ectopic beats originating in the pulmonary veins. N Engl J Med 1998; 339: 659-66.
2. Cheema A, Dong J, Dalal D, Marine JE, Henrikson CA, Spragg D, et al. Incidence and time course of early recovery of pulmonary vein conduction after catheter ablation of atrial fibrillation. J Cardiovasc Electrophysiol 2007; 18: 387-91.
3. Kim TH, Park J, Uhm JS, Joung B, Lee MH, Pak HN. Pulmonary vein reconnection predicts good clinical outcome after second catheter ablation for atrial fibrillation. Europace 2017; 19: 961-7.
4. Patel PJ, D'Souza B, Saha P, Chik WWB, Riley MP, Garcia FC. Electroanatomic Mapping of the Intercaval Bundle in Atrial Fibrillation. Circ Arrhythm Electrophysiol 2014; 7: 1262-7.
5. Keith A, Flack M. The Form and Nature of the Muscular Connections between the Primary Divisions of the Vertebrate Heart. J Anat Physiol 1907; 41(Pt 3): 172-89.
6. Kircher S, Sommer P. Electrophysiological Evaluation of Pulmonary Vein Isolation. J Atr Fibrillation 2013; 6: 934.

Address for Correspondence: Dr. Emir Baskovski,
Ankara Üniversitesi Tıp Fakültesi,
Kardiyoloji Anabilim Dalı,
06340, Ankara-*Türkiye*
Phone: +90 534 329 44 09
E-mail: emirbaskovski@gmail.com
©Copyright 2020 by Turkish Society of Cardiology - Available online at www.anatoljcardiol.com
DOI:10.14744/AnatolJCardiol.2019.06709

Giant cell arteritis presenting with pericardial effusion, hoarseness, and amaurosis

Blanka Morvai-Illés*, Gergely Ágoston*, Ágnes Séllei[1], László Kovács, Albert Varga***
Departments of *Family Medicine, and **Rheumatology and Immunology, Faculty of Medicine, University of Szeged; Szeged-*Hungary*
[1]Department of Radiology, Affidea Diagnosztika Kft.; Szeged-*Hungary*

Introduction

Although pericardial effusion is a common finding, in most of the cases, its etiology remains unclear (1). Sometimes, however, by using a multidisciplinary approach, a treatable condition can be diagnosed.

Case Report

A 68-years-old woman with a 1-year-long history of dyspnea occurring at minimal exertion and complaining of dizziness was admitted to our hospital. She reported a weight loss of 66 lbs (30 kg) in a year. Diffuse articular complaints were intermittently present. No fever, nocturnal sweating, headache, or any other symptoms were present. Her physical examination was unremarkable, and no tenderness or enlargement of the temporal artery could be detected.

The year before, due to difficulty at breathing, an emergency chest computed tomography (CT) was performed in this patient. An intramural hematoma of the ascending aorta was described, which was treated conservatively. During the same year, the hoarseness occurred. Left-sided recurrent nerve paralysis was discovered, and endoscopic arytenoid lateropexy was performed. The patient's medical history was remarkable for diabetes mellitus, hypertension, and cataract on both eyes. Despite the cataract extraction, her left eye's visual acuity remained restricted for 4 years.

These symptoms could point toward several different diseases, such as cardiac failure, coronary disease, aortic dissection, renal disease, malignancy, autoimmune disease, and panic syndrome.

Upon admission, the patient's blood pressure was in the normal range, and the electrocardiography (ECG) and the chest X-ray did not indicate any anomalies. The blood test showed only an elevated erythrocyte sedimentation rate (52 mm/h). The blood count, C-reactive protein, and renal and thyroid functions were within normal limits. During the 6-minute walk test, the patient could barely walk for 120 meters, and her oxygen saturation dropped from 97% to 82%. TTE revealed a dilated ascending aorta (35 mm) and pericardial effusion near