An extreme case of vasospastic angina mimicking acute STEMI: Severe three-vessel disease with critical stenoses

Çağlar Kaya, Servet Altay
Department of Cardiology, Faculty of Medicine, Trakya University; Edirne-*Turkey*

Introduction

Acute coronary syndromes generally result from the atherosclerotic plaque rupture or chronic stenosis. However, they may also be caused by vasospasm resulting from vasoactive peptides released from the endothelium around the plaques. The frequency of coronary vasospasm or variant angina may actually be higher than originally thought. Variant angina is a clinical condition that generally occurs after a triggering event and resolves spontaneously or after nitrate treatment, usually within 5 minutes. Clinical manifestations have also been reported to occur after coronary spasm due to a transient increase in the arterial tonus on the background of coronary plaques (1, 2). The male-to-female ratio is 5 to 1 (3). A normal electrocardiogram (ECG) recorded during chest pain may obscure a three-vessel vasospasm. Multi-vessel spasms are known to increase the risk of death, and therefore, angiography or provocative tests have been recommended (4, 5). An early and correct diagnosis may allow proper management with medications.

Case Report

A 35-year-old male patient presented to the emergency room 1 hour after the onset of chest pain. He was a current smoker with no history of coronary artery disease, hypertension, or diabetes. He was reported to undergo a diagnostic work-up for possible diagnoses of lymphoma and sarcoidosis in the past 3-month period. He decided to visit the emergency room due to sudden and recurrent chest pain. At admission, his blood pressure (BP) was 95/69 mm Hg, his heart rate was 150 bpm, respiratory rate was 26/min, and oxygen saturation was 94%. An ECG showed a normal sinus rhythm with 75 heart bpm, and negative T-waves at III, aVF, and V4–6 leads (Fig. 1a). In the laboratory results, the high-sensitive-troponin-I value was 200 ng/L. He was referred to the coronary intensive care unit with a diagnosis of non-ST elevation myocardial infarction. He was administered 300 mg of acetylsalicylic acid, 300 mg of clopidogrel, and 5000 U of IV heparin. In the first hour of the intensive care follow-up, the patient had no chest pain, and his hemodynamic parameters were stable. One hour into his follow-up, the ST segment elevation was detected in the inferolateral leads of ECG (Fig. 1b), and emergency coronary angiography was performed due to a diagnosis of acute inferolateral myocardial infarction. At the time of angiography, BP was 90/60 mm Hg, and the heart rate was 108 bpm. Angiography of the right and left coronary systems showed multiple stenotic images in the right coronary artery, left descending coronary artery, and circumflex coronary artery (Fig. 2). Despite the presence of hypotension, intra-coronary nitrate was given to both coronary systems in sequence on the basis of the suspicion of vasospasm, and this was followed by the flushing of both systems with physiological

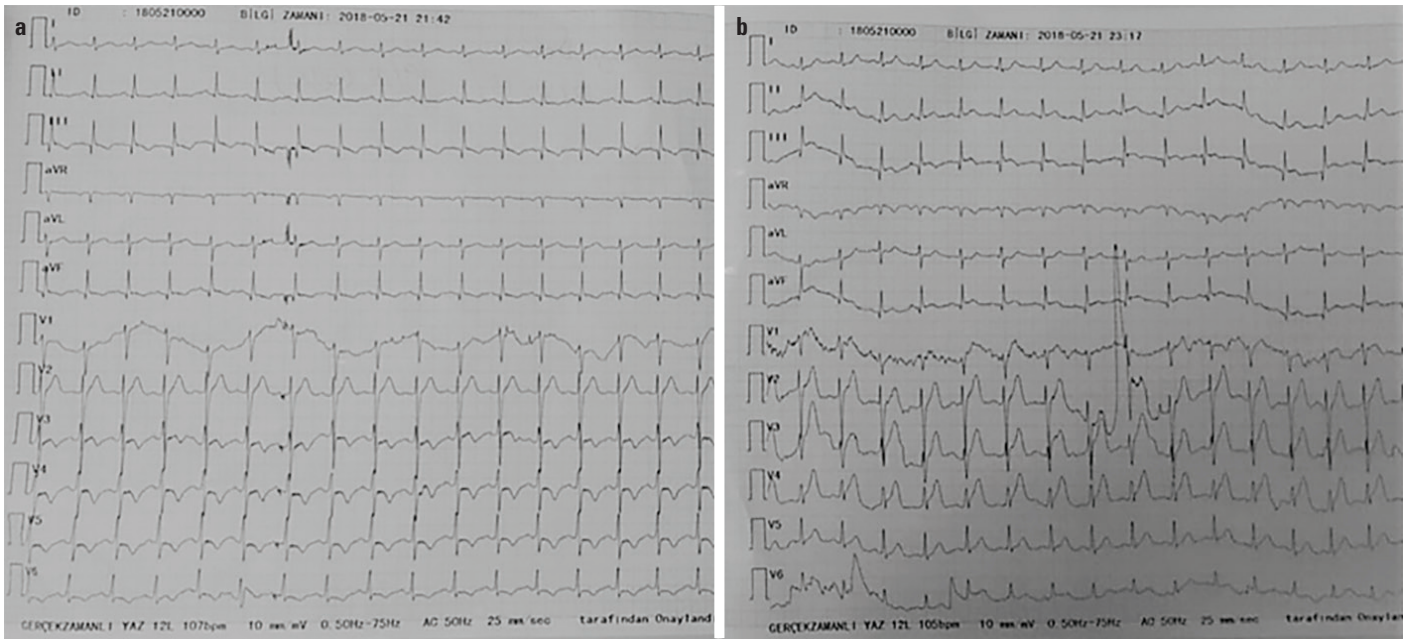

Figure 1. (a) Negative T-waves in leads III, aVF, and V4–6 at presentation, (b) ST segment elevations during recurrent pain (1-hour onset)

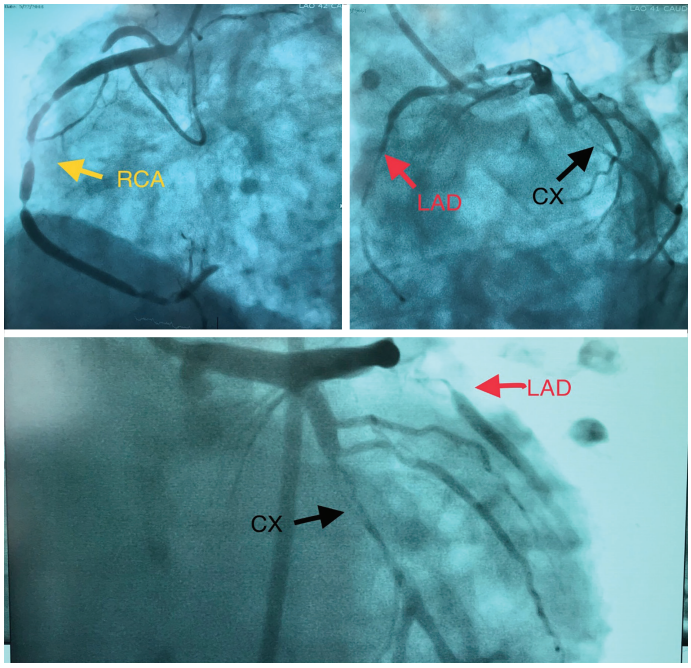

Figure 2. Multiple stenoses in the right and left coronary circulation in angiographic images
CX - circumflex artery; LAD - left anterior descending artery; RCA - right coronary artery

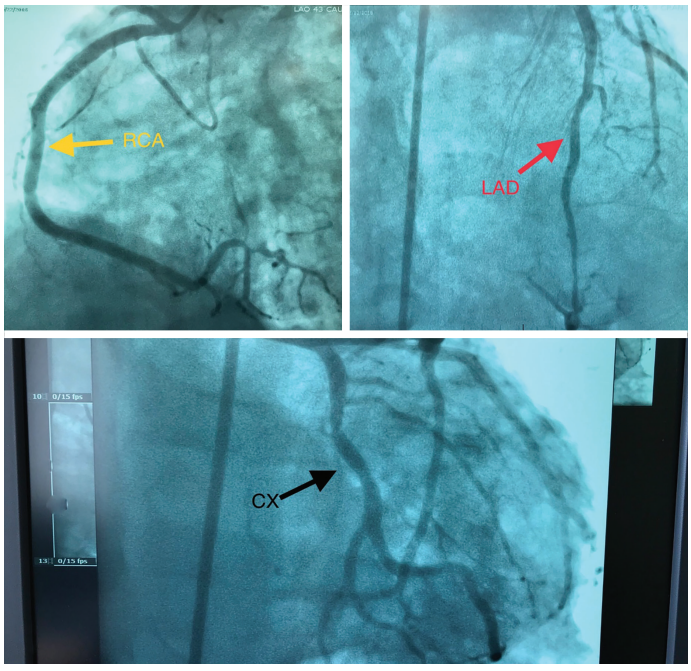

Figure 3. Control angiography after nitrate administration
CX - circumflex artery; LAD - left anterior descending artery; RCA - right coronary artery

saline. During the course of his management, analgesics were administered to reduce symptoms and prevent vasospasm. Control angiography showed disappearance of the lesions in all three vessels (Fig. 3). Due to the chest pain resolution and the absence of critical lesions in control angiography, the procedure was terminated. Nitrates and Ca-channel blockers were added to the routine treatment of the patient, and follow-up exams were scheduled.

Discussion

Vasospastic angina is defined as a variant form of angina pectoris characterized by a transient ST elevation at rest and occurring mostly in the morning hours (1). Many factors influencing the coronary arterial tonus have been implicated in the pathogenesis of this condition. It has been well established that a fine balance between vasoconstrictor and vasodilator substances is responsible for the vessel tonus. An imbalance between constrictors such as endothelin, angiotensin II, and thromboxane 2, and dilators such as nitric oxide and prostacyclin, which maintain a balance under normal conditions, may trigger endothelial dysfunction or coronary vasospasm (6, 7). A spasm developing in coronary vessels itself also triggers the release of another potent vasoconstrictor, that is, the platelet-derived growth factor, resulting in a vicious cycle. Reduced blood flow at the site of spasm and its surroundings as well as the impaired endothelial functions may accelerate the atherosclerotic process, which in turn may lead to an imbalance between vasodilators and vasoconstrictors causing a wide spectrum of clinical presentations, including stable angina, unstable angina, myocardial infarction, and even death (8). Although electrocardiography may provide some guidance in the diagnosis of vasospastic angina, it may not allow a definitive diagnosis in all cases. Frequently, patients have ST segment changes in conjunction with chest pain. ST segment elevations occurring during the hyper-acute phase of an acute myocardial infarction may resemble those occurring during the pain. Although patients generally exhibit alterations such as a ST segment elevation, a normal ECG may lead to a missed diagnosis of three-vessel spasm. Thus, provocative tests and coronary angiography are recommended, with a consideration of clinical and triggering factors (5). Vasospasm attacks may be induced by a number of physiological or pharmacological factors such as smoking, drinking cold water, dobutamine stress test, exercise testing, alcohol intake, mental stress, cocaine, or nicotine (9). Commonly, this may also happen in patients with normal coronary angiographies. In others, it may occur around the atherosclerotic plaques. Right coronary artery is frequently involved. If the involvement is tiny and affects a distal vessel, the ST segment depression may be seen. While the spasm may be observed in a single vessel, it may also affect multiple vessels. In such cases, vasospasm may occur simultaneously in more than one segment, or sequentially in different segments (2). Although it appears as a mild condition, clinically it may lead to serious complications, such as fatal arrhythmia, myocardial infarction, AV block, or sudden death. Multi-vessel vasospasm may be associated with an increased risk of mortal complications, and sudden death (4). Therefore, the diagnosis should be supported with a coronary angiography, and prompt treatment should be given to prevent these complications. Intra-coronary nitrate or intravenous nitrate administration during the procedure may rapidly and effectively resolve the spasm. Morphine and similar

agents may be used to alleviate the pain. Standard oral treatment after the procedure includes a calcium-channel blocker and oral nitrate combination. Aspirin and beta-blockers are generally not recommended in patients without severe atherosclerosis, as these agents are thought to increase the spasm in patients with vasospastic angina (2). Coronary vasospasm was suspected in our patient on the basis of relative age and presence of severe stenosis in three vessels. The presence of a single vessel disease in this patient could have led to an unnecessary interventional procedure. In all patients with critical coronary artery disease, the clinical should not rush to perform an interventional treatment, and vasospasm should be assessed with intra-coronary nitrate during the procedure to prevent unnecessary stent implantations. This case suggests that intra-coronary nitrate should be considered as a routine procedure prior to percutaneous coronary interventions.

Conclusion

Coronary artery spasm is a condition that may mislead physicians prior to angioplasty procedure.

Therefore, re-evaluation of the lesions and control with the vasodilator agents should be kept in mind in order to avoid wrong practices.

Informed consent: Written informed consent was obtained from the patient for the publication.

References

1. Prinzmetal M, Kennamer R, Merliss R, Wada T, Bor N. Angina pectoris. I. A variant form of angina pectoris; preliminary report. Am J Med 1959; 27: 375-88.
2. Braunwald E. Heart Disease: A Textbook of Cardiovascular Medicine. 6th ed. Philadelphia: WB Saunders Company; 2001.
3. Vandergoten P, Benit E, Dendale P. Prinzmetal's variant angina: three case reports and a review of the literature. Acta Cardiol 1999; 54: 71-6.
4. Nakamura M, Takeshita A, Nose Y. Clinical characteristics associated with myocardial infarction, arrhythmias, and sudden death in patients with vasospastic angina. Circulation 1987; 75: 1110-6.
5. Kerin NZ, Rubenfire M, Naini M, Wajszczuk WJ, Rao P. Prinzmetal's variant angina: electrocardiographic and angiographic correlations. J Electrocardiol 1982; 15: 365-80.
6. Kugiyama K, Yasue H, Okumura K, Ogawa H, Fujimoto K, Nakao K, et al. Nitric oxide activity is deficient in spasm arteries of patients with coronary spastic angina. Circulation 1996; 94: 266-71.
7. Nakayama M, Yasue H, Yoshimura M, Shimasaki Y, Kugiyama K, Ogawa H, et al. T-786-->C mutation in the 5'-flanking region of the endothelial nitric oxide synthase gene is associated with coronary spasm. Circulation 1999; 99: 2864-70.
8. Shepherd JT, Katusić ZS. Endothelium-derived vasoactive factors: I. Endothelium-dependent relaxation. Hypertension 1991; 18 (5 Suppl): III76-85.
9. Nobuyoshi M, Abe M, Nosaka H, Kimura T, Yokoi H, Hamasaki N, et al. Statistical analysis of clinical risk factors for coronary artery spasm: Identification of the most important determinant. Am Heart J 1992; 124: 32-8.

Address for Correspondence: Dr. Çağlar Kaya,
Trakya Üniversitesi Tıp Fakültesi Hastanesi,
Kardiyoloji Anabilim Dalı,
Balkan Yerleşkesi 22000
Edirne-*Türkiye*
Phone: +90 555 604 06 04
E-mail: caglarkaya2626@gmail.com
©Copyright 2019 by Turkish Society of Cardiology - Available online at www.anatoljcardiol.com
DOI:10.14744/AnatolJCardiol.2019.74171