dextrocardia, and only few cases, who have typical AVNRT or accessory pathway, have previously been described in patients with dextrocardia, IVC interruption, and azygos continuation (3, 4). To the best of our knowledge, the present case may be the first case of RF ablation of scar-related AFL due to surgical repair of ASDs in a patient with dextrocardia and complex venous anomaly.

Dextrocardia or complex cardiac anatomy may be very challenging to electrophysiologists during catheter abla¬tion procedures. An interrupted IVC with azygous continuation to SVC may complicate the femoral venous approach typically used for diagnostic or interventional cardiac catheterization because of the abrupt 180° turn at the level of the superior azygous arch, and ablation of left atrial arrhythmias in such cases is more difficult. Therefore, we used three long sheaths to stabilize the catheters and control them. Femoral venous approach is not feasible in left atrial arrhythmias, which requires atrial septal puncture in an interrupted IVC, which will eventually require a superior approach.

Atrial tachycardias are common after repair of many types of complex congenital heart disease (5). The most common late-onset atrial arrhythmias in these patients are cavotricuspid isthmus-dependent AFL, incisional atrial reentrant tachycardia, and atrial fibrillation and less commonly focal atrial tachycardia (6). Arrhythmia mechanisms are related to surgical incisions, atrial enlargement, and structural remodeling with slow conduction creating the substrate for macroreentry (7). The efficacy of antiarrhythmic drugs in this type of arrhythmias has been unsatisfactory, and these tachycardias are difficult to medically manage and frequently recur after electrical cardioversion. In patients with surgically corrected ASD, electroanatomic mapping-guided RF ablation of late-onset macroreentrant atrial arrhythmias demonstrated a high success rate in a very long-term follow-up (8).

Conclusion

This case demonstrated a complex venous anomaly with dextrocardia and successful management of scar-related AFL due to surgical repair of ASD. The use of RF ablation with electroanatomic mapping system is effective and safe in such patients.

References

1. Bohun CM, Potts JE, Casey BM, Sandor GGS. A population-based study of cardiac malformations and outcomes associated with dextrocardia. Am J Cardiol 2007; 100: 305-9.
2. Anderson RC, Adams P, Burke B. Anomalous inferior vena cava with azygos continuation (infrahepatic interruption of the inferior vena cava). Report of 15 new cases. J Pediatr 1961; 59: 370-83.
3. Pecoraro R, Proclemer A, Pivetta A, Gianfagna P. Radiofrequency ablation of atrioventricular nodal tachycardia in a patient with dextrocardia, inferior vena cava interruption, and azygos continuation. J Cardiovasc Electrophysiol 2008; 19: 444.
4. Taniguchi H, Miyauchi Y, Kobayashi Y, Hirasawa Y, Hosaka H, Iwasaki YK, et al. Radiofrequency catheter ablation of a coronary sinus-ventricular accessory connection in dextrocardia with complete situs inversus and an anomalous inferior vena cava. Pacing Clin Electrophysiol 2005; 28: 164-7.
5. Walsh EP, Cecchin F. Arrhythmias in adult patients with congenital heart disease. Circulation 2007; 115: 534–45.
6. Berger F, Vogel M, Kramer A, Alexi-Meskishvili V, Weng Y, Lange PE, et al. Incidence of atrial flutter/fibrillation in adults with atrial septal defect before and after surgery. Ann Thorac Surg 1999; 68: 75–8.
7. Magnin-Poull I, De Chillou C, Miljoen H, Andronache M, Aliot E. Mechanisms of right atrial tachycardia occurring late after surgical closure of atrial septal defects. J Cardiovasc Electrophysiol 2005; 16: 681-7.
8. Scaglione M, Caponi D, Ebrille E, Di Donna P, Di Clemente F, Battaglia A, et al. Very long-term results of electroanatomic-guided radiofrequency ablation of atrial arrhythmias in patients with surgically corrected atrial septal defect. Europace 2014; 16: 1800-7.

Address for Correspondence: Dr. Veysel Kutay Vurgun,
Ankara Üniversitesi Tıp Fakültesi, Kardiyoloji Anabilim Dalı,
Cebeci Kalp Merkezi, 06100,
Ankara-*Türkiye*
Phone: +90 312 595 62 86
E-mail: kutayvurgun@gmail.com
©Copyright 2018 by Turkish Society of Cardiology - Available online at www.anatoljcardiol.com
DOI:10.14744/AnatolJCardiol.2017.7950

Catheter ablation of manifest posteroseptal accessory pathway associated with coronary sinus diverticula in a child with congenitally corrected transposition of the great arteries

Yakup Ergül, Osman Esen*, Senem Özgür, Alper Güzeltaş
Department of Pediatric Cardiology, *Anesthesia and Reanimation, Sağlık Bilimleri University, İstanbul Mehmet Akif Ersoy Thoracic and Cardiovascular Surgery Training and Research Hospital; İstanbul-*Turkey*

Introduction

Patients with congenitally corrected transposition of the great arteries (ccTGA) usually have some specific electrophysiological features, such as twin AV node and accessory pathway (AP)-related supraventricular tachycardia (SVT) (1-3). There is limited number of AP-related case presentations of patients with both ccTGA and Wolff–Parkinson–White (WPW) syndrome (3, 4).

Some of the posteroseptal pathways are related to coronary sinus (CS) diverticula, and these pathways are close to the epicardium. Therefore, multiple ablation entries can cause ablation failure (4, 5). Till date, there has been no report of ccTGA accompanied with WPW syndrome treated by an ablation from inside the CS diverticula in pediatric patients. Here we present a successful

Figure 1. On the left side, WPW pattern was observed in the 12-channel ECG records of patient with ccTGA. On the right side, one of the documented orthodromic SVT attacks was observed

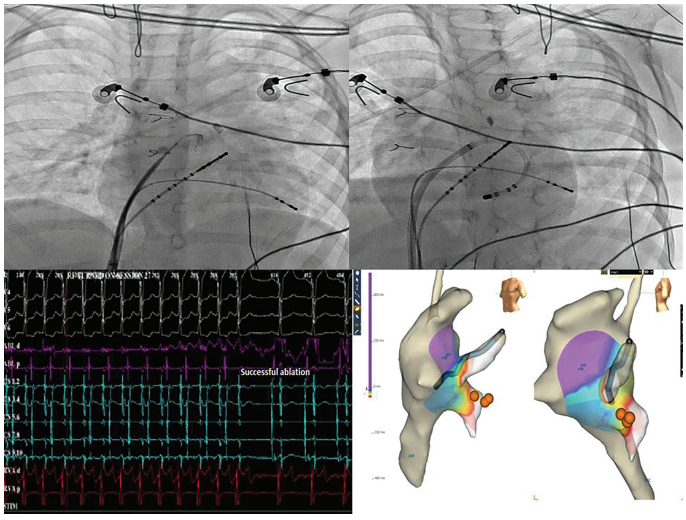

Figure 2. On the top left side, a transition to the left atrium was observed by making a transseptal puncture. On the top right side, a successful RF ablation region is shown at the left posteroseptal area. On the bottom left, some successful ablation records were observed. On the bottom right, some successful RF ablation regions are labeled with orange dots at oblique and lateral positions

radiofrequency (RF) ablation of the CS diverticula-related manifest posteroseptal AP in a pediatric patient with ccTGA.

Case Report

A 5-year-old male patient, weighing 18 kg, was referred to our clinic with multiple antiarrhythmic-resistant SVTs. He had a medical history of pulmonary banding for ccTGA, large VSD, right ventricular hypoplasia, and pulmonary hypertension. Left manifest posteroseptal AP ablation was performed two times because of medical therapy-resistant SVT, but tachycardia recurred.

He underwent catheter ablation because of SVT attacks that worsened the hemodynamics of the patient and that required cardioversion (Fig. 1). A three-dimensional (3D) mapping system (EnSite System, St. Jude Medical, Minneapolis, Minnesota, USA) and fluoroscopy were utilized during the procedure. The baseline sinus cycle length was 650 ms with an AH interval of 79 ms and a short HV interval of 10 ms. During both, V-pace was done from an RV catheter and SVT the earliest ventriculoatrial (VA) activation was between coronary (CS) catheter 7-8 and 5-6. Because the patient had previously undergone ablation in

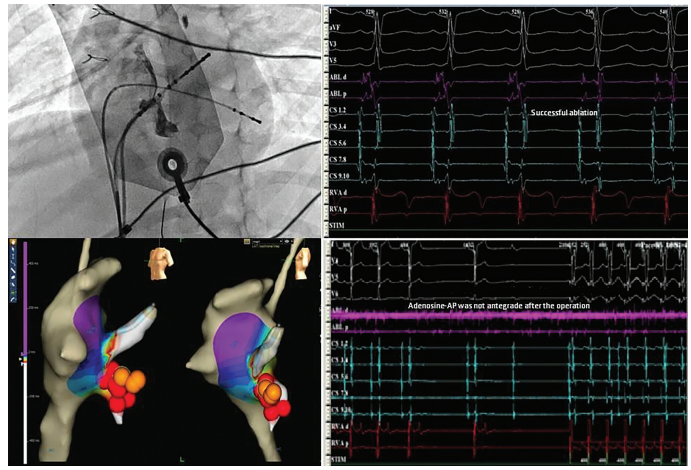

Figure 3. On the top left side, CS diverticula were observed on the CS angiogram. On the top right side, the preexisting transition disappeared by means of RF ablation, which was performed from the CS diverticula. On the bottom left side, the proximity between the RF lesions (red dots) that were given inside the left CS diverticula and the RF lesions (orange dots) that were given to the left posteroseptal region (by EnSite) is remarkable. On the bottom right side, it was observed that the adenosine AP was not antegrade after the operation and VA transmission was disassociated with a concurrent V-pace at 400 ms

the left posteroseptal region, mapping was first done from the left side using the transseptal technique. The earliest area during SVT was again the left posteroseptal region. Ablation was initiated with a 5-Fr RF ablation catheter, and the tachycardia stopped with a VA block in the third second of the ablation (Fig. 2). After three RF lesions, the WPW syndrome pattern recurred. When we performed remapping, the earliest area was found to be the CS ostium this time, and CS diverticula were detected by CS angiogram. The region 40 ms ahead of the surface delta was labeled with mapping. Coronary angiography was performed to detect coronary arterial proximity to the target. We started RF ablation at 20 W, 50°C and AP was ablated 4 th second of the lesion. We completed the ablation with four short RF lesions Anteretro AP disappearance, confirmed by adenosine (Fig. 3). The patient has remained asymptomatic, and no pre-excitation has been observed on ECG.

Discussion

RF ablation can be performed using 3D electroanatomic mapping systems for most of the complex congenital cardiac diseases. Almost 2%–5% of patients with ccTGA have one or more AP-related tachycardia substrates (2). In children, ccTGA and WPW co-occurrence is common, and the ablation experiences are limited with case presentations and low-numbered case series (3, 6, 7). In these cases, AP is usually seen in the left posteroseptal region, especially in the ones with Ebsteinoid valve (2, 6, 7). Although ablations have been performed from the retrograde aortic pathway to the tricuspid valve on the left side, the presence of the septal leaflet may increase the risk of valve disruption in the retroaortic approach (4). Therefore,

it is recommended to perform ablation by passing a catheter to the left atrium using the transseptal approach in the case of left-sided APs in patients with ccTGA (2). In our clinic, ablation is performed using transseptal puncture for all left-sided APs in pediatric patients. Although transseptal puncture in patients with congenital heart diseases is difficult, it can be successfully performed by tagging of the septum (2, 8).

In the present study patient, posteroseptal APs could have been related to CS diverticula, and this could have caused multi-ablation attempts and failures. The CS musculature in the diverticulum acts as the connection between the atrial and ventricular musculature and forms AP (3, 7). Although these are limited in pediatric patients, it was reported that an AP ablation from CS diverticula can be successfully performed even in very small children with a normal heart (9). To the best of our knowledge, this is the first case of a pediatric patient with ccTGA accompanied with WPW syndrome treated by ablation from inside the CS diverticula.

Conclusion

AP ablation can be difficult in complex congenital heart diseases. In addition, CS diverticula should be taken into account in recurrent posteroseptal APs.

References

1. Warnes CA. Transposition of the great arteries. Circulation 2006; 114: 2699-709.
2. Kanter RJ. Pearls for ablation in congenital heart disease. J Cardiovasc Electrophysiol 2010; 21: 223-30.
3. Hebe J, Hansen P, Ouyang F, Volkmer M, Kuck KH. Radiofrequency catheter ablation of tachycardia in patients with congenital heart disease. Pediatr Cardiol 2000; 21: 557-75.
4. Payami B, Shafiee A, Shahrzad M, Kazemisaeed A, Davoodi G, Yaminisharif A. Posteroseptal accessory pathway in association with coronary sinus diverticulum: electrocardiographic description and result of catheter ablation. J Interv Card Electrophysiol 2013; 38: 43-9.
5. Selvaraj RJ, Sarin K, Singh VR, Satheesh S, Pillai AA, Kumar M, et al. Radiofrequency ablation of posteroseptal accessory pathways associated with coronary sinus diverticula. J Interv Card Electrophysiol 2016; 47: 253-9.
6. Brugada J, Valls V, Freixa R, Gonzalez E, Herreros B, Matas M, et al. Radiofrequency ablation of a posteroseptal atrioventricular accessory pathway in a left-sided Tricuspid ring with Ebsteinlike anomaly in a patient with Congenitally Corrected Transposition of the great arteries. Pacing Clin Electrophysiol 2000; 23: 133-6.
7. Okreglicki AM, Millar RS. Radiofrequency ablation of a posteroseptal atrioventricular accessory pathway in a left-sided tricuspid ring with Ebstein like anomaly in a patient with congenitally corrected transposition of the great arteries. Pacing Clin Electrophysiol 2000; 23: 1707-8.
8. Chavan C, Rao HB, Badani RS, Raju PR, Narasimhan C. Ablation of incessant orthodromic reciprocating tachycardia in a child with congenitally corrected transposition of great arteries and ebsteinoid malformation of left atrioventricular valve. J Interv Card Electrophysiol 2008; 23: 149-52.
9. Veloor HP, Lokhandwala Y. A 2-year-old child with coronary sinus diverticulum and Wolff-Parkinson-White syndrome. Cardiol Young 2013; 23: 274-6.

Address for Correspondence: Dr. Yakup Ergül,
Mehmet Akif Ersoy Göğüs Kalp Damar Cerrahisi
Eğitim Araştırma Hastanesi, Halkalı, Küçükçekmece,
İstanbul-*Türkiye*
Phone: +90 212 692 20 00
E-mail: yakupergul77@hotmail.com
©Copyright 2018 by Turkish Society of Cardiology - Available online at www.anatoljcardiol.com
DOI:10.14744/AnatolJCardiol.2017.8108