Diagn Interv Radiol 2015; 21: 494–497
© Turkish Society of Radiology 2015

INTERVENTIONAL RADIOLOGY
PICTORIAL ESSAY

Imaging findings and endovascular management of iatrogenic hepatic arterial injuries

Serkan Güneyli
Mustafa Gök
Celal Çınar
Halil Bozkaya
Mehmet Korkmaz
Mustafa Parıldar
İsmail Oran

ABSTRACT
Iatrogenic hepatic arterial injuries (IHAIs) include pseudoaneurysm, extravasation, arteriovenous fistula, arteriobiliary fistula, and dissection. IHAIs are usually demonstrated following percutaneous transhepatic biliary drainage, percutaneous liver biopsy, liver surgery, chemoembolization, radioembolization, and endoscopic retrograde cholangiopancreatography. The latency period between the intervention and diagnosis varies. The most common symptom is hemorrhage, and the most common lesion is pseudoaneurysm. Computed tomography angiography (CTA) is mostly performed prior to angiography, and IHAIs are demonstrated on CTA in most of the patients. Patients with IHAI are mostly treated by coils, but some patients may be treated by liquid embolic materials or stent-grafts. CTA can also be used in the follow-up period. Endovascular treatment is a safe and minimally invasive treatment option with high success rates.

Iatrogenic hepatic arterial injuries (IHAIs) arising from percutaneous interventions, laparoscopic or open surgery include pseudoaneurysm (PA), extravasation, arteriovenous fistula (AVF), arteriobiliary fistula (ABF), and dissection (1–3). AVF can occur between hepatic artery and hepatic vein or between hepatic artery and portal vein, called arterioportal fistula (APF). Percutaneous interventions seem to have a higher incidence of IHAIs than surgery (4). The incidence of IHAIs is more than the incidence of traumatic hepatic arterial injuries (5). Hemorrhage following an invasive upper abdominal procedure such as hepatic, pancreatic, and biliary intervention may indicate an IHAI that requires early diagnosis and treatment. Angiography is not only the gold standard imaging modality but also the first suggested treatment option with the advantage of endovascular treatment (6).

The etiologies of IHAIs are percutaneous transhepatic biliary drainage, percutaneous liver biopsy, liver surgery (pancreaticoduodenectomy, laparoscopic cholecystectomy, and mass excision), transcatheter chemoembolization, transcatheter radioembolization, and endoscopic retrograde cholangiopancreatography (1–3). Mean latency period between the intervention and the diagnosis of IHAI varies. The symptoms are hemorrhage, hemobilia, and pain. Computed tomography angiography (CTA) is mostly performed prior to angiography, and IHAIs are demonstrated on CTA in most patients. Due to technical limitations of the CTA, IHAI cannot be clearly demonstrated in some patients; however, CTA can show perihepatic hematoma in these patients. CTA findings and hemodynamic status of the patients are considered to determine the indication for angiography.

Endovascular management

Transfemoral arteriography is performed under intravenous sedation, and IHAIs are clearly identified on angiograms. The location of the lesions may be lobar or segmental hepatic artery, common hepatic artery, gastroduodenal artery, proper hepatic artery, or cystic artery. Coils (mostly pushable coils) are used either alone or with a liquid embolic material. Liquid embolic material alone or stent-grafts may also be used in some patients. Follow-up is performed by CTA.

Pseudoaneurysm

After a disruption in the arterial wall continuity, blood dissects into tissues under the high arterial pressure and a sac that has a communication with the arterial lumen forms. This sac,

From the Department of Radiology (S.G. ✉ *serkanguneyli@yahoo.com*), Bülent Ecevit University School of Medicine, Zonguldak, Turkey; the Department of Radiology (M.G.), Kafkas University School of Medicine, Kars, Turkey; the Department of Radiology (C.Ç., H.B., M.P., İ.O.), Ege University School of Medicine, İzmir, Turkey; the Department of Radiology (M.K.), Dumlupınar University School of Medicine, Kütahya, Turkey.

Received 9 January 2015; revision requested 9 February 2015; final revision received 25 March 2015; accepted 26 April 2015.

Published online 31 August 2015.
DOI 10.5152/dir.2015.15014

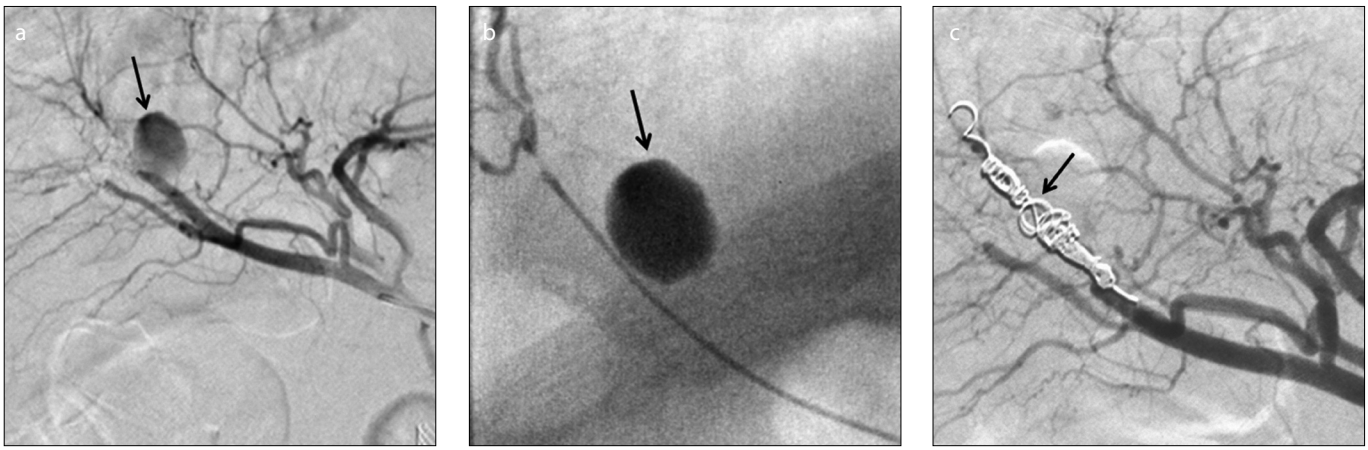

Figure 1. a–c. Selective hepatic angiography image **(a)** of a 74-year-old male patient, who had undergone percutaneous transhepatic biliary drainage because of obstructive icterus due to metastatic colon cancer, shows a pseudoaneurysm (*arrow*) of the right hepatic artery. Superselective angiography image **(b)** shows the pseudoaneurysm (*arrow*) that occurred one month after the intervention. Coils were preferred over glue in this patient, because their use was technically easier as glue may adhere to the catheters. Control angiography **(c)** reveals complete embolization with pushable coils (*arrow*).

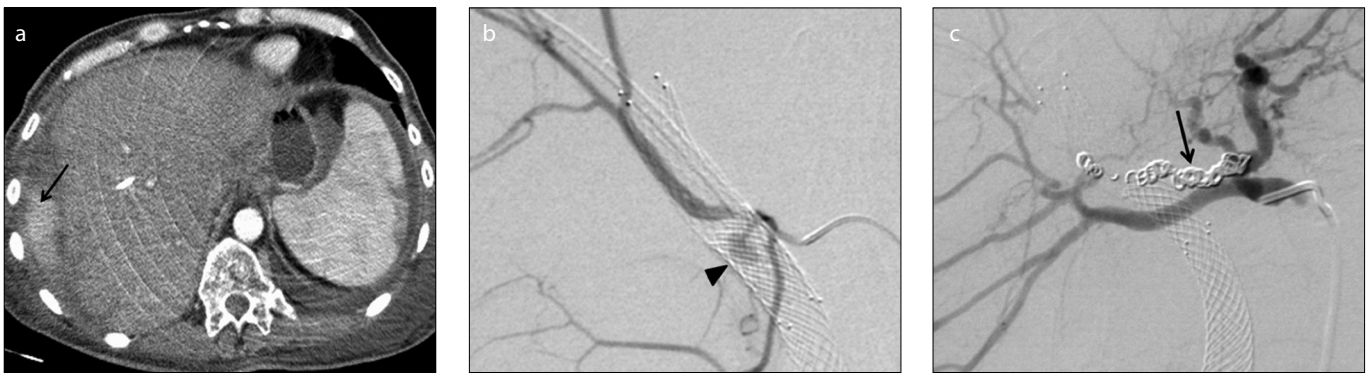

Figure 2. a–c. Axial computed tomography angiography image **(a)** of a 48-year-old male patient, who had undergone percutaneous transhepatic biliary drainage because of icterus due to primary liver lymphoma, shows perihepatic hematoma and extravasation (*arrow*). Superselective angiography image **(b)** shows a pseudoaneurysm (*arrowhead*) of the middle hepatic artery that occurred five days after biliary drainage and stenting. The parent artery was embolized in this patient, because embolization of only the pseudoaneurysm sac may have led to the recurrence of hemorrhage. Control angiography **(c)** reveals total embolization with pushable coils (*arrow*).

Main points

- Iatrogenic hepatic arterial injuries (IHAIs) should be considered in patients with hemorrhage following an invasive upper abdominal procedure.
- IHAIs include pseudoaneurysm, extravasation, arteriovenous fistula, arteriobiliary fistula, and dissection.
- Percutaneous transhepatic biliary drainage and percutaneous liver biopsy are the most common etiologies of IHAIs.
- Pseudoaneurysm, which is the most common IHAI, can be usually demonstrated on computed tomography angiography prior to catheter angiography.
- Endovascular treatment is a minimally invasive treatment option that can be performed safely and effectively in patients with IHAIs.

called PA, is surrounded by the media, adventitia, or soft tissue (7). Blood extravasation into the sac leads to the formation of a fibrous capsule. This capsule displays progressive enlargement that causes PA to have a higher rupture risk than a true aneurysm (8). Previous studies (2, 8) reported that PA seems to be the most common IHAI, and rupture in iatrogenic PAs of the hepatic artery is also common with a rate of 21%–80%. Asymptomatic patients with PA should also be treated because of the high rupture risk (8).

PA is seen either isolated (Fig. 1) or with another IHAI. PAs are usually detected following percutaneous transhepatic biliary drainage (Fig. 2), pancreaticoduodenectomy, percutaneous liver biopsy, laparoscopic cholecystectomy, endoscopic retrograde cholangiopancreatography, and mass excision. Coils are the first preferred embolic material in most patients, while liquid embolic materials such as glue, thrombin, or polyvinyl alcohol can be used in some patients (1). Covered stent-graft can be used in patients who have a PA with a narrow neck (Fig. 3).

Extravasation

Extravasation that can be detected by CTA or angiography is defined as migration of blood out of the vessel into the gastrointestinal lumen or the peritoneal cavity (Fig. 4). Extravasation is seen either isolated or with a PA. The etiology and treatment of extravasation are similar to those of PA (1).

Arteriovenous fistula

Hepatic AVFs are abnormal communications between the hepatic artery and the

Figure 3. a–c. Selective hepatic angiography image **(a)** of a 22-year-old female patient shows a pseudoaneurysm (*arrow*) of the right hepatic artery that occurred six days after laparoscopic cholecystectomy. Superselective angiography image **(b)** shows the pseudoaneurysm (*arrow*) with a narrow neck. Stent-graft was used in this patient, because she is young and suitable for anticoagulant therapy after embolization. Control angiography **(c)** shows a patent covered stent-graft (*arrow*).

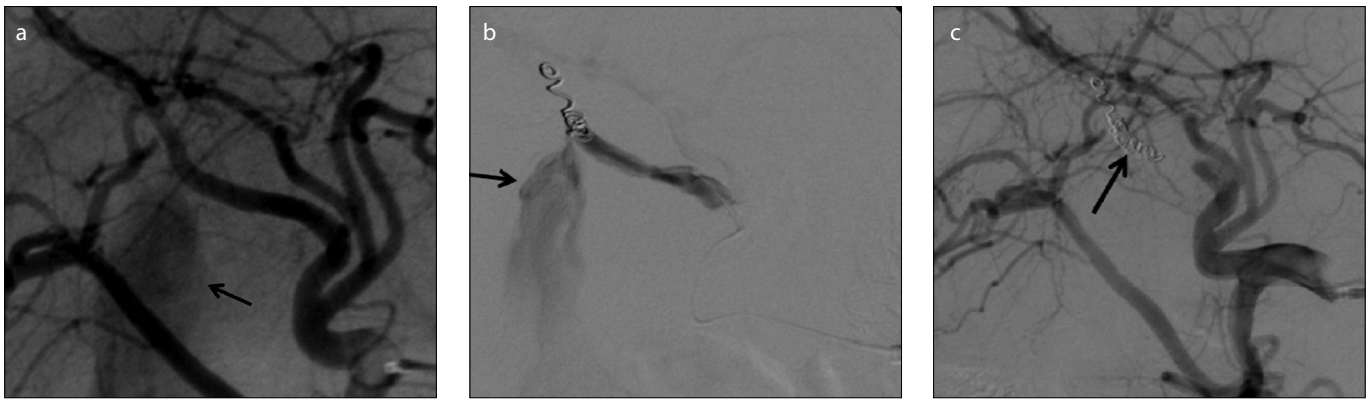

Figure 4. a–c. Selective hepatic angiography image **(a)** of an 80-year-old male patient shows a pseudoaneurysm (*arrow*) of the right hepatic artery that occurred three days after percutaneous transhepatic biliary drainage. Superselective angiography image **(b)** shows the extravasation (*arrow*). Coils were used in this patient, because he was 80-year-old and not suitable for anticoagulant therapy after embolization. Control angiography **(c)** reveals complete embolization with pushable coils (*arrow*).

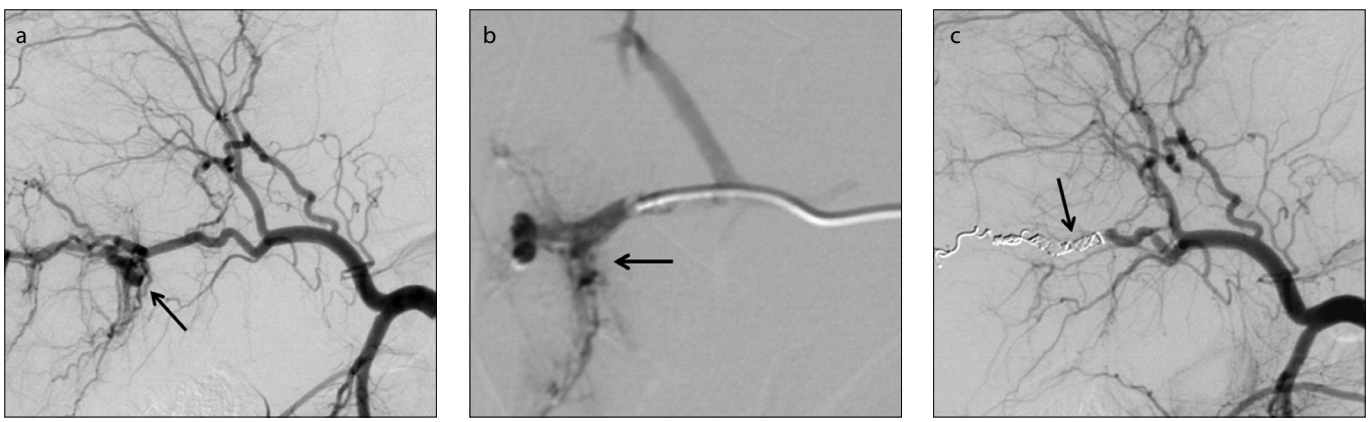

Figure 5. a–c. Selective hepatic angiography image **(a)** of a 23-year-old male patient shows an arterioportal fistula (*arrow*) between the left hepatic artery and the portal vein that occurred two months after percutaneous liver biopsy. Superselective angiography image **(b)** shows the fistula (*arrow*). Control angiography **(c)** reveals total embolization with pushable coils (*arrow*).

portal or hepatic vein without an intervening capillary bed (9). The hepatic arteriole and portal venule show close proximity and they are located in the portal triad along with the biliary tract. This may cause the incidence of APF or ABF following biopsy to be more than the incidence of a fistula between the hepatic artery and the hepatic vein (9, 10). APF is mostly seen following percutaneous liver biopsy (Fig. 5) and to a lesser extent following other percutaneous interventions (9).

Figure 6. a–d. Selective hepatic angiography image **(a)** of a 55-year-old male patient shows dissection (*arrow*) of the right hepatic artery that occurred during transcatheter radioembolization of metastatic liver lesions and previously embolized cystic and gastroduodenal arteries. Angiography image **(b)** shows a balloon-expandable stent-graft (*arrow*). Control angiography **(c)** shows the stent-graft (*arrow*). Axial computed tomography angiography image **(d)** at 18-month follow-up shows a patent stent-graft (*arrow*).

Arteriobiliary fistula

An ABF is an abnormal communication between the hepatic artery and the biliary system. ABF presents rarely, following percutaneous transhepatic biliary drainage or other percutaneous interventions (10). It may be associated with an extrahepatic biliary injury.

Dissection

An arterial dissection is separation of the layers of the arterial wall, and it may be associated with aneurysm formation later. Dissection occurs during the intervention (Fig. 6) and is treated by balloon-expandable stent-graft.

Conclusion

IHAIs are diagnosed by CTA or catheter angiography (2). Kumar et al. (11) reported the usefulness of CTA prior to angiography in management of patients with massive hemobilia. Previous studies (1, 12) reported a rate of 80%–100% for successful embolization of IHAIs. Superselective embolization performed as distal as possible minimizes complication rates and loss of hepatic artery flow. The choice of embolic material should be based on cost, technical ease of use and effectiveness of permanent occlusion with minimal loss of hepatic arterial flow. Although some uncommon complications such as migration of the embolic material (8), bile leakage (12), coil erosion into the common bile duct (13), hepatic abscess and gallbladder fibrosis (14) were reported after hepatic arterial embolization, the mortality and morbidity rates of endovascular embolization are lower than those of surgery (5).

In conclusion, IHAIs should be considered in patients with hemorrhage following an invasive upper abdominal procedure. In cases of IHAI, endovascular treatment can be performed safely and effectively with high success rates.

Conflict of interest disclosure

The authors declared no conflicts of interest.

References

1. Choi SH, Gwon DI, Ko GY, et al. Hepatic arterial injuries in 3110 patients following percutaneous transhepatic biliary drainage. Radiology 2011; 261:969–975. [CrossRef]
2. Tessier DJ, Fowl RJ, Stone WM, et al. Iatrogenic hepatic artery pseudoaneurysms: an uncommon complication after hepatic, biliary, and pancreatic procedures. Ann Vasc Surg 2003; 17:663–669. [CrossRef]
3. Saad WE, Dasgupta N, Lippert AJ, et al. Extrahepatic pseudoaneurysms and ruptures of the hepatic artery in liver transplant recipients: endovascular management and a new iatrogenic etiology. Cardiovasc Intervent Radiol 2013; 36:118–127. [CrossRef]
4. Basile A, Lupattelli T, Giulietti G, et al. Interventional treatment of iatrogenic lesions and hepatic arteries. Radiol Med 2005; 110:88–96.
5. Christensen T, Matsuoka L, Heestand G, et al. Iatrogenic pseudoaneurysms of the extrahepatic arterial vasculature: management and outcome. HPB (Oxford) 2006; 8:458–464. [CrossRef]
6. Schick C, Ritter RG, Balzer JO, Thalhammer A, Vogl TJ. Hepatic artery aneurysm: treatment options. Eur Rad 2004; 14:157–159. [CrossRef]
7. Saad NE, Saad WE, Davies MG, Waldman DL, Fultz PJ, Rubens DJ. Pseudoaneurysms and the role of minimally invasive techniques in their management. Radiographics 2005; 25:173–189. [CrossRef]
8. Reber PU, Baer HU, Patel AG, Wildi S, Triller J, Büchler MW. Superselective microcoil embolization: treatment of choice in high-risk patients with extrahepatic pseudoaneurysms of the hepatic arteries. J Am Coll Surg 1998; 186:325–330. [CrossRef]
9. Kumar A, Ahuja CK, Vyas S, et al. Hepatic arteriovenous fistulae: role of interventional radiology. Dig Dis Sci 2012; 57:2703–2712.[CrossRef]
10. Gurakuqi GC, Stadlbauer V, Portugaller HR, Högenauer C, Trauner M, Stauber RE. Fatal hemobilia resulting from an iatrogenic arteriobiliary fistula as a rare complication of transjugular liver biopsy. Eur J Gastroenterol Hepatol 2008; 20:83–86. [CrossRef]
11. Kumar M, Gupta S, Soin A, Nundy S. Management of massive haemobilia in an Indian hospital. Indian J Surg 2008; 70:288–295. [CrossRef]
12. Carrafiello G, Laganà D, Dizonno M, Cotta E, Ianniello A, Fugazzola C. Emergency percutaneous treatment in iatrogenic hepatic arterial injuries. Emerg Radiol 2008; 15:249–254. [CrossRef]
13. Ozkan OS, Walser EM, Akinci D, Nealon W, Goodacre B. Guglielmi detachable coil erosion into the common bile duct after embolization of iatrogenic hepatic artery pseudoaneurysm. J Vasc Interv Radiol 2002; 13:935–938. [CrossRef]
14. Messina LM, Shanley CJ. Visceral artery aneurysms. Surg Clin North Am 1997; 77:425–442. [CrossRef]