Diagn Interv Radiol 2021; 27:401–407
© Turkish Society of Radiology 2021

INTERVENTIONAL RADIOLOGY
ORIGINAL ARTICLE

Percutaneous management of complicated parapneumonic effusion and empyema after surgical tube thoracostomy failure in children: a retrospective study

Turkmen Turan Ciftci
Devrim Akinci
Emre Unal
Gonul Tanır
Hakan Artas
Okan Akhan

PURPOSE
We aimed to evaluate the results of percutaneous management of complicated parapneumonic effusions (PPE) and empyema after surgical tube thoracostomy failure in children.

METHODS
A total of 84 children treated percutaneously after surgical tube thoracostomy failure between 2004 and 2019 were included to this retrospective study. Technical success was defined as appropriate placement of the drainage catheter. Clinical success was defined as complete resolution of infection both clinically and radiologically. Management protocol included imaging-guided pigtail catheter insertion, fibrinolytic therapy, serial ultrasonographic evaluation, catheter manipulations as necessary (revision, exchange, or upsizing), and appropriate antibiotherapy. All patients were followed up at least 6 months.

RESULTS
Technical success rate was 100%. Unilateral single, unilateral double, and bilateral catheter insertions were performed in 73, 9, and 2 patients, respectively. Inserted catheter sizes ranged from 8 F to 16 F. Streptokinase, urokinase, and tissue plasminogen activator were used as fibrinolytic agent in 29 (34%), 14 (17%), and 41 (49%) patients, respectively. In order to maintain effective drainage, 42 additional procedures (catheter exchange, revision, reposition, or additional catheter placement) were performed in 20 patients (24%). Clinical success was achieved in 83 of 84 patients (99%). Median catheter duration was 8 days (4–32 days). Median hospital stay during percutaneous management was 11.5 days (7–45 days). Factors affecting the median catheter duration were the presence of necrotizing pneumonia ($p < 0.001$) and bronchopleural fistulae ($p < 0.001$).

CONCLUSION
Percutaneous imaging-guided catheterization with fibrinolytic therapy should be the method of choice in pediatric complicated PPE and empyema patients with surgical tube thoracostomy failure. Percutaneous treatment is useful in avoiding more aggressive surgical options.

Parapneumonic effusions (PPE) may progress from anechoic fluid loculations (stage I) to hyperechoic collection containing septa (stage II) or to loculations with or without accompanying pleural thickening (stage III) (1). There is currently no standardized treatment protocol. Management may vary among centers (1–8). Surgical tube thoracostomy remains a common drainage method for PPE despite its high failure rates (9–11). Nevertheless, imaging-guided catheter placement has been reported to be a safe and effective method of choice in complicated PPE and empyema (6, 12). To our knowledge, there is no study in the literature evaluating the role of percutaneous catheter placement with fibrinolytic therapy as a salvage treatment in case of surgical tube thoracostomy failure in childhood PPE and empyema.

In this study, we evaluated the results of percutaneous management of complicated parapneumonic effusions and empyema after surgical tube thoracostomy failure in pediatric age group.

Methods

Study design

Between 2004 and 2019, 84 children with PPE refractory to surgical tube thoracostomy were included to this retrospective study. Clinical and radiological data were recorded for

From the Department of Radiology (T.T.C., D.A., E.U. ✉ *emreunal.rad@gmail.com*, O.A.), Hacettepe University School of Medicine, Ankara, Turkey; Department of Pediatric Infectious Disease (G.T.), Dr. Sami Ulus Maternity and Children's Health and Diseases Training and Research Hospital, Ankara, Turkey; Department of Radiology (H.A.), Firat University School of Medicine, Elazig, Turkey.

Received 12 May 2020; revision requested 16 June 2020; last revision received 23 July 2020; accepted 26 August 2020.

Published online 20 April 2021.

DOI 10.5152/dir.2021.20331

You may cite this article as: Ciftci TT, Akinci D, Unal E, Tanır G, Artas H, Akhan O. Percutaneous management of complicated parapneumonic effusion and empyema after surgical tube thoracostomy failure in children: a retrospective study. Diagn Interv Radiol 2021; 27:401–407

each patient. To assess long-term success, 6-month post-treatment chest radiographs were compared with pre-treatment chest radiographs with sonographic evaluation of pleural thickness. Institutional review board approval was obtained for the study (B.30.2.HAC.0.70.00.01/431.10-414).

Inclusion and exclusion criteria

Pediatric patients (≤16 years old) who underwent surgical tube thoracostomy due to parapneumonic effusion and failed to demonstrate clinical and radiological improvement on follow-up were included in the study.

Exclusion criteria were >16 years of age, imaging-guided catheter placement as first-line treatment, pleural effusion due to noninfectious causes, and <6 months of follow-up.

Patient preparation and procedure

Patient position and the number / size of the drainage catheters were planned based on ultrasonography (US) and previously obtained imaging findings. Computed tomography (CT) was not routinely performed except for suspected necrotizing pneumonia (NP), parenchymal abscesses, bronchopleural fistulae (BF), or malignancy.

Patients fasted at least 4–6 hours before the procedure. Preprocedural laboratory evaluations were determined. Any coagulopathy (platelet <50 000/mm^3, INR >1.5) was corrected before the procedure. Antibiotic prophylaxis was not applied since patients were already having broad-spectrum antibiotics. Surgically placed, nonfunctioning chest tubes were removed by pediatric surgeons before or after the procedures. All patients were treated as inpatient. Informed consent was obtained from patients' parents/guardians.

Main points

- Surgical tube thoracostomy has high failure rates due to the blind nonguided nature of the technique and structure of the placed tube itself.
- Imaging-guided catheter placement is a safe and effective method in complicated parapneumonic effusion.
- Percutaneous imaging-guided catheterization with fibrinolytic therapy should be the method of choice in complicated childhood parapneumonic effusions nonresponsive to surgical chest tube placement.

Procedures were performed by one of 3 interventional radiologists (D.A., T.C., E.U., having 20, 14, and 5 years of experience, respectively) in an interventional radiology unit equipped with fluoroscopy and US. Procedures were performed with intravenous sedation. For sedation, propofol (1 mg/kg) and fentanyl (1 µg/kg) were administered by an anesthesiologist. The puncture side was chosen to enable the catheter to traverse as much septa as possible. An 18 G Chiba needle was inserted from the lowest part of the effusion, thereafter it was carefully advanced to superior or posterior part depending on the location of fluid with US guidance (Supplemental video). Following coiling of 0.035-inch stiff guidewire (Amplatz Super Stiff, Boston Scientific) into the cavity, the tract was dilated and drainage catheter (Skater, Angiotech or Flexima APDL Boston Scientific) was placed and connected to an underwater seal drainage system. If required, final catheter position was confirmed by short-time fluoroscopy.

Postprocedural care

Catheter outputs, clinical and laboratory signs were recorded for each patient. Patients were routinely evaluated with US in the interventional radiology unit. For loculations that could not be drained with single catheter, additional catheters were placed under US guidance. Fluoroscopy was predominantly used for exchanging or upsizing of occluded catheters. Chest radiographs were obtained in case of clinical worsening or prior to catheter removal to evaluate lung expansion. Following clinical and radiological improvement, if daily drainage was below 10 mL/24 h, drainage catheters were removed.

Fibrinolytic therapy

Urokinase (UK) and streptokinase (STK) were used in 2005–2013 and tissue plasminogen activator (t-PA) was used in 2013–2019 depending on the availability of fibrinolytic agents. STK was administered at 12 000 U/kg, UK at 40 000 units to children aged >1 year and at 10 000 units to infants <1 year, t-PA at 0.1 mg/kg (maximum 6 mg) daily according to international guidelines and previous studies (2–8, 13). The volume of mixture of the fibrinolytic agent and isotonic saline (5–20 cc) is based on the estimated amount of the pleural loculation. In small loculations, installation of large amount of fibrinolytic agent was avoided to prevent overdistension. First session of fibrinolytic agent injections at the time of catheter placement were performed under US guidance to ensure effective distribution of agent into fluid loculation. Following injection, the catheter was clamped for 2 hours. Afterwards drainage resumed. No special position was required during fibrinolytic agent administration. Fibrinolytic treatments were continued once a day depending on US findings. Presence of residual pleural fluid despite appropriate catheter position was the main indication for fibrinolytic treatment.

Definitions and outcome measures

Technical success was defined as appropriate drainage catheter placement within the pleural collection. Clinical success was defined as complete recovery of clinicoradiological findings within 6 months of follow-up. Failure was defined as (*i*) need for surgery or (*ii*) development of recurrence within 6 months of follow-up. Complications were classified according to the CIRSE classification system (14). Secondary interventions (revision, exchange, catheter upsize or inserting a new catheter) and side effects directly attributable to fibrinolytic agents were evaluated separately. The duration of catheter stay and length of hospital stay were also recorded.

Statistical analysis

Statistical analysis was conducted by SPSS 24 for Windows (IBM SPSS Statistics). The variables were investigated using visual (histograms, probability plots) and analytical methods (Kolmogorov–Smirnov) to determine whether they are normally distributed. Mann–Whitney U and Kruskal–Wallis tests were conducted to compare non-normally distributed continuous values. The chi–square test or Fisher's exact test was used to compare nominal variables. Descriptive analyses were presented using tables of frequencies for nominal variables, median and minimum-maximum values for non-normally distributed numeric variables, mean and standard deviation for the normally distributed numeric variables. An overall 5% type-1 error level was used to infer statistical significance.

Results

A total of 84 children (52 boys, 62%) with a median age of 6 years (range, 1–16 years), underwent percutaneous imaging-guided management of PPE refractory to surgical

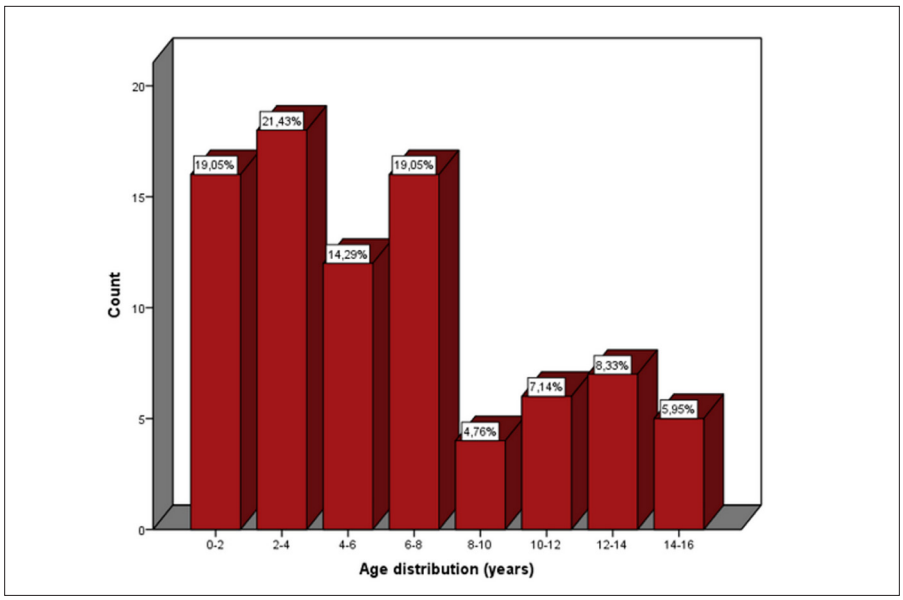

Figure 1. Bar chart represents the age distribution of patients.

Table 1. Associated comorbidities, biochemistry, microbiological and pleural fluid characteristics of patients

Associated comorbidities	n (%)
None	67 (80)
Measles, mumps, or rubella	3 (4)
Chiari malformation, renal failure, Down syndrome, cerebral palsy	2 each (10)
Epilepsy, hyper IgE syndrome, neuroblastoma, retinitis pigmentosa, ALL, neuroblastoma	1 each (6)
Causative agent	
Streptococcus pneumonia	12 (14)
Staphylococcus aureus	3 (4)
Streptococcus pyogenes	2 (2)
Biochemistry	
WBC ($\times 10^3$µL), mean±SD	12.6±5.4
CRP (mg/L), median (min–max)	100 (34–460)
Pleural fluid analyses	
Pleural fluid LDH (IU/L), median (min–max)	1804 (394–9000)
Pleural-serum LDH ratio, median (min–max)	4 (1–11)
Pleural-serum protein ratio, median (min–max)	3 (1–30)
Pleural pH, median (min–max)	7 (6.75–7.4)
Pleural fluid glucose (mg/dL), median (min–max)	10 (0–45)

WBC, white blood cell; CRP, C-reactive protein; LDH, lactate dehydrogenase; ALL, acute lymphoblastic leukemia; SD, standard deviation.

tube thoracostomy. Age distribution of patients is presented in Fig. 1. Presence of associated comorbidities and results of laboratory analyses are summarized in Table 1. Stage II and III empyema were evident in 59 (70%) and 25 (30%) of the patients, respectively.

Previously inserted failed surgical chest tube sizes varied between 14 F and 28 F. The median duration of surgical chest tubes was 9 days (range, 3–19 days). The majority of these chest tubes (65%) had been placed under general anesthesia. Unilateral single, unilateral double, and bilateral tubes had been placed surgically in 70, 9, and 5 patients, respectively. Fifty-six patients (67%) had already received one or more sessions of fibrinolytic agents during the previous treatment period. The causes of previous treatment failure were malpositioned or kinked tube, tube blockage due to fibrin formation, presence of additional fluid loculation in pleural cavity, superinfection or a combination of these factors.

Overall, 73 patients (87%) had clinically and radiologically confirmed active pneumonia. At least one symptom, such as chest pain (70%, n=59), fever (82%, n=69), cough (71%, n=60), tachypnea (49%, n=41), hypotension together with tachycardia (38%, n=32), or respiratory distress (27%, n=23) was present.

Sixteen patients had undergone CT examination before percutaneous treatment. In 8 patients, CT was performed due to unstable clinical status detected during the percutaneous treatment. Necrotizing pneumonia, lung abscess and BF were detected in 14 (17%), 3 (4%) and 6 (7%) of the patients, respectively. Lymphoma was diagnosed in one patient.

For percutaneous drainage, US, US + fluoroscopy, and CT guidance were used in 74, 9, and 1 patients, respectively. CT guidance was required due to presence of BF which prevented US evaluation. Unilateral single, unilateral double, and bilateral catheterization was performed in 73, 9, and 2 patients, respectively. Unilateral double catheters were placed in case of multiple loculations that could not be drained with one catheter. Inserted catheter sizes ranged as 8–16 F with the majority being at 10 F (n=37).

Technical success rate was 100%. Six patients (7%) had 8 cases of grade 3 complications such as catheter dislodgement, kinking, and obstruction, all managed by catheter exchange. In order to maintain effective drainage, 42 additional procedures were performed (Table 2).

STK, UK, and t-PA were used as fibrinolytic agent in 29, 14, and 41 patients, respectively. Thirty-two patients (38%) received 3 sessions, 15 patients (18%) received 4 sessions, 8 patients (10%) received 5 sessions and 29 patients (34%) received more than 5 sessions of fibrinolytic therapy (Table 3).

There was no evidence of systemic effects of fibrinolytic treatment. Minor side effects were recorded in 37 patients (44%) in the form of mild chest pain and discomfort (n=3), transient fever (n=27), minor bleed-

ing in drained fluid (n=14), coughing and mild respiratory distress (n=2). Some patients had more than one side effects. Rates of side effects and clinical success did not differ among fibrinolytic agents ($p > 0.05$).

Clinical success was achieved in 83 of 84 patients (99%) (Fig. 2). Mortality or grade 4/5 complication were not seen during treatment or follow-up period. Median catheter duration was 8 days (4–32 days). Median hospital stay during percutaneous management was 11.5 days (7–45 days). The median hospital stay from the onset of pulmonary infectious symptoms to discharge was 24 days (16–41 days). Presence of necrotizing pneumonia and BF statistically significantly prolonged the duration of catheterization and hospitalization ($p < 0.001$, $p = 0.007$) (Table 4). Presence of lung abscess statistically significantly prolonged duration of catheter stay ($p = 0.036$). The factors affecting catheter duration and hospital stay are summarized in Table 4.

Using both culture-based and molecular methods, potential causative organisms (*Streptococcus pneumoniae*, n=12; group A streptococcus, n=3; *Staphylococcus aureus*, n=2) could be identified in 17 of 84 patients (20%). The median duration of antibiotic treatment during percutaneous management was 21 days (15–33 days). The antibiotics were administered intravenously until stable clinical status was achieved and were continued orally thereafter (4–6 weeks).

The only patient recorded as failure was a 10-year-old child with pneumococcal pneumonia complicated with stage 3 PPE. Initial surgical chest tube was kept for 14 days. A 12 F pigtail catheter was inserted and drained fluid was apparently purulent. He received 12 sessions of STK therapy. The patient became afebrile 5 days after initiation of fibrinolysis. One week after catheter removal he developed recurrent effusion and was successfully treated percutaneously. After second intervention there was no recurrence.

Discussion

The results of this study demonstrate that complicated childhood PPEs nonresponsive to surgical chest tube placement, can be treated with percutaneous management with a high clinical success rate (99%). Thanks to effective use of US (for serial evaluation of the pleural space, as a guidance method during the procedure and for monitoring the fibrinolytic agent distribution in the pleural space) and unique characteristics of the pigtail catheters, extremely high success rates can be achieved in almost all patients even at the advanced stage of the disease. Although surgical tube thoracostomy combined with fibrinolytic therapy has been shown to have satisfying success rates, the failure rate remains quite high for the initial management of childhood PPEs due to the blind nonguided placement technique and the structure of the tube itself (9–11, 15–19). In a review of 44 studies on the management of PPEs in pediatric population, the failure rate of chest tube insertion was 25% (17). Chen et al. (10) reported a failure rate of tube thoracostomy as high as 56% in the treatment of pediatric PPEs. This study showed that 70% of children with late presenting empyema required surgery which included 54% of those who had primary tube thoracostomy. Similarly, Jamal et al. (9) reported 43% failure rate for surgical tube thoracostomy as the first intervention for treatment of complicated PPE and empyema in children. Huang et al. (11) mentioned a success rate of 53% for the drainage of complicated PPE and empyema with surgical tube thoracostomy. The most common reason for tube thoracostomy failure was pleural adhesions and fibrin membranes (20). Even in skilled hands, it is challenging to place a thoracostomy tube in accurate position within the pleural space. Drainage may also be hampered by fibrinous debris and septations. Tube exchange or revision could be more challenging with thoracostomy tubes.

Imaging-guided placement of pigtail catheters via Seldinger technique enables safe passage through pleural space and appropriate drainage of small collections where conventional trocar insertion could be challenging and hazardous. Although

Table 2. Summary of secondary interventions after first placement of percutaneous pleural catheter

Cause of secondary intervention	Procedure count (n)
Catheter revision in 20 patients	21
Catheter exchange/upsize in 10 patients	11
New catheter placement due to dislodgement in 2 patients	2
Additional catheter placement due to new loculations in 5 patients	5
New catheter placement due to recurrence in 1 patient	1
Additional catheter placement due to broncho-pleural fistula in 2 patients	2
Guidance	n (%)
Ultrasound	27 (64)
Ultrasound + fluoroscopy	14 (34)
CT	1 (2)
Anesthesia	
Local anesthesia	21 (50)
Sedation	21 (50)

Table 3. Summary of fibrinolytic therapy

	Fibrinolytic therapy sessions				Catheter duration (days)	Complications, n (%)		
Agent, n (%)	3	4	5	≥ 6		Transient fever	Mild bleeding in pleural fluid	Hemoptysis
Streptokinase, 29 (34)	19	6	4	11	7 (4–14)	11 (38)	7 (24)	1 (3)
t-PA, 41 (49)	8	6	2	10	8 (5–12)	10 (24)	5 (12)	1 (2)
Urokinase, 14 (17)	5	3	2	8	7 (5–9)	6 (43)	2 (14)	0

t-PA, tissue plasminogen activator.

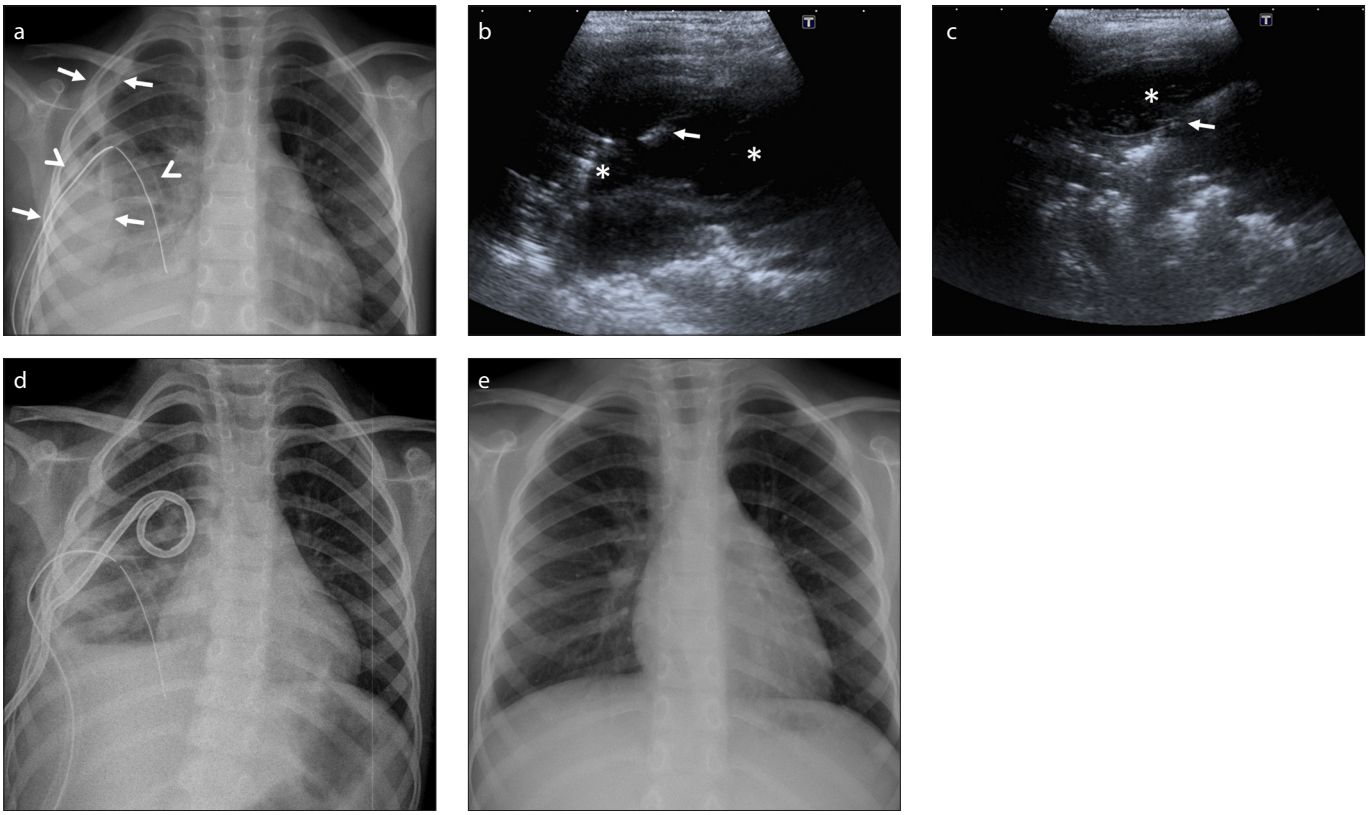

Figure 2. a–e. A 5-year old boy with complicated parapneumonic effusion following surgical tube thoracostomy failure. The patient was referred for percutaneous catheter placement due to ongoing fever, fatigue, and dyspnea. He required oxygen at 6 L/min. Daily drainage with surgical tube was 0–5 cc for 48 hours. Chest radiograph **(a)** demonstrates residual pleural collection *(arrows)* due to malpositioned chest tube *(arrowheads)*. Gray-scale sonograms (**b** and **c**) demonstrate needle (*arrow*, **b**) and guidewire (*arrow*, **c**) insertions through the pleural collection *(asterisks)*. A 10 F pigtail drainage catheter was placed under ultrasound guidance. The patient was afebrile on the next day after the procedure and oxygen therapy was reduced to 2 L/min by nasal cannula. He received daily fibrinolytic therapy via drainage catheter. Chest radiograph **(d)** obtained on the 2nd day after the procedure demonstrates significant lung expansion compared to baseline radiograph. There was no drainage from the surgical chest tube. The chest tube was withdrawn and pleural drainage was established with the drainage catheter. Chest radiograph **(e)** obtained on follow-up (day 130) shows recovery of the lung expansion.

there are no randomized, controlled trials comparing surgical and radiological management, some observational pediatric case series show that imaging-guided drainage catheter placement is highly effective in the treatment of PPE (5–8, 12, 18, 21). Small pigtail drains have several advantages: (*i*) easy and less painful procedure, (*ii*) better tolerated once placed, (*iii*) low placement-related complication rates (21, 22). Flexible pigtail catheters can change configuration proportional to the size of collection, therefore damage to expanding lung or migration into fissure in case of established collection drainage is less likely compared with conventional chest tubes. Pigtail catheters have holes on the inside curve of the catheter therefore drainage will continue in case of close contact with pleura. Kinking and deformation are prevented by the high strength of the catheters and their possession of "memory", the ability to resume their original configuration after distortion (22).

Fibrinolytic therapy improves drainage without hampering pleural-limiting membranes. Following drainage of the collection, pleural surfaces adhere and chest tube could be away from any residual fluid loculation. Administration of fibrinolytics via conventional chest tubes placed without imaging guidance is less likely to be successful due to tube malposition. For these reasons, we believe that imaging-guided catheter management with fibrinolytic therapy is the most important factor in success. Fibrinolytic therapy should not be utilized via a malpositioned tube. Isolated pleural loculations distant from the drainage site should be treated with additional drainage catheters.

The first-generation fibrinolytics, STK and UK, were initially used in this study. Both agents have been associated with adverse effects, specifically, immunologic and hypersensitivity reactions. Fever after intrapleural injection has been reported (1, 2, 23–25). Antibody-mediated response that may decrease effectivity is associated with STK use because of its bacteria-based morphology. Minor side effects reported in two largest pediatric studies include discomfort during administration and transient blood staining of fluid (6, 8). No life-threatening adverse events were noted. However, t-PA is not associated with hypersensitivity reactions and retains its effectiveness over multiple doses (23–25). Intrapleural t-PA injection was well tolerated with only minor adverse effects in our study. Vital signs and hematocrit levels remained stable in all patients. We performed fibrinolytic injections under US guidance in the majority of the patients to ensure adequate distribution of fibrinolytic agent within the collection. However, in case of BF, fibrinolytics should be used more cautiously to avoid bronchial spread which may lead to decreased efficacy, pneumonitis, and greater systemic absorption. A significant increase in the

Table 4. Catheterization and hospitalization durations among given factors

		Catheterization duration (days)	*p*	Hospitalization duration (days)	*p*
Age (years)	0–2	8 (5–12)	0.332	11 (8–18)	0.427
	2–4	6.5 (4–32)		11.5 (7–45)	
	4–6	8 (6–28)		15 (10–30)	
	6–8	7.5 (5–12)		11.5 (8–21)	
	8–10	8 (6–14)		10.5 (10–17)	
	10–12	9 (6–16)		11.5 (8–19)	
	12–14	8 (9–16)		11 (10–24)	
	14–16	7 (4–18)		11 (8–30)	
Sex	Female	7.5 (4–32)	0.621	11.5 (7–45)	0.897
	Male	8 (4–28)		11.5 (7–30)	
Comorbid disease	Present	8 (5–16)	0.577	12 (7–21)	0.955
	Absent	8 (4–32)		11 (7–45)	
Sonographic stage	Stage 2	8 (4–32)	0.283	11 (7–45)	0.969
	Stage 3	8 (4–28)		12 (7–30)	
Active pneumonia	Present	8 (4–32)	0.274	14 (7–45)	0.121
	Absent	8 (6–18)		11 (7–27)	
Necrotizing pneumonia	Present	16 (5–32)	<0.001	19 (9–45)	0.007
	Absent	7 (4–14)		11 (7–21)	
Lung abscess	Present	16 (4–32)	0.036	19 (11–19)	0.196
	Absent	8 (9–16)		11 (7–45)	
Bronchopleural fistula	Present	23 (16–32)	<0.001	30 (25–45)	<0.001
	Absent	7 (4–16)		11 (7–21)	
Causative microorganism	Present	9 (5–32)	0.108	12 (8–45)	0.660
	Absent	8 (4–23)		11 (7–30)	
Purulent effusion	Present	9 (5–24)	0.861	12 (8–30)	0.946
	Absent	7 (4–32)		11 (7–45)	
Previous fibrinolytic therapy	Present	8 (4–32)	0.852	12 (7–45)	0.585
	Absent	8 (5–28)		11 (8–30)	
Fibrinolytic agents	t-PA	8 (5–32)	0.593	12 (8–45)	0.440
	STK	7 (4–18)		11 (7–27)	
	UK	7 (5–16)		11 (7–30)	
Catether bore (French)	8	8 (6–28)	0.211	11 (8–30)	0.952
	10	8 (4–32)		12 (8–45)	
	12	8 (5–18)		11 (7–30)	
	14	7 (4–10)		11.5 (7–16)	
	16	7 (4–32)		12 (11–14)	

Data are presented as median (min–max).
t-PA, tissue plasminogen activator; STK, streptokinase; UK, urokinase.

incidence of BF in association with empyema has been reported from 1% of cases in 2002–2007 to 33% of cases in 2008–2009, with an associated increase in median hospital stay (26). Our data are consistent with these reports, and more recently we observed a significant increase in BF frequency with resultant increased length of hospital stay. It is postulated that changes in the epidemiology of causative pathogens with the introduction of pneumococcal conjugate vaccines have resulted in increased necrotizing or cavitating pneumonias with abscess formation and BF (26–28).

The main limitation of our study was its retrospective nature.

In conclusion, percutaneous imaging-guided catheterization with fibrinolytic

therapy should be the method of choice in pediatric complicated PPE and empyema patients with surgical tube thoracostomy failure. Percutaneous treatment is useful in avoiding more aggressive surgical options.

Conflict of interest disclosure

The authors declared no conflicts of interest.

References

1. Course CW, Hanks R, Doull I. Question 1 What is the best treatment option for empyema requiring drainage in children? Arch Dis Child 2017; 102:588–590. [Crossref]
2. Balfour-Lynn IM, Abrahamson E, Cohen G, et al. BTS guidelines for the management of pleural infection in children. Thorax 2005; 60 Suppl 1:i1–21. [Crossref]
3. Bradley JS, Byington CL, Shah SS, et al. The management of community-acquired pneumonia in infants and children older than 3 months of age: clinical practice guidelines by the Pediatric Infectious Diseases Society and the Infectious Diseases Society of America. Clin Infect Dis 2011; 53:e25–76. [Crossref]
4. Cantin L, Chartrand-Lefebvre C, Lepanto L, et al. Chest tube drainage under radiological guidance for pleural effusion and pneumothorax in a tertiary care university teaching hospital: Review of 51 cases. Can Respir J 2005; 12:29–33. [Crossref]
5. Feola GP, Shaw LC, Coburn L. Management of complicated parapneumonic effusions in children. Tech Vasc Interv Radiol 2003; 6:197–204. [Crossref]
6. Lewis MR, Micic TA, Doull IJM, Evans A. Real-time ultrasound-guided pigtail catheter chest drain for complicated parapneumonic effusion and empyema in children - 16-year, single-centre experience of radiologically placed drains. Pediatr Radiol 2018; 48:1410–1416. [Crossref]
7. Thomson AH, Hull J, Kumar MR, Wallis C, Balfour Lynn IM. Randomised trial of intrapleural urokinase in the treatment of childhood empyema. Thorax 2002; 57:343–347. [Crossref]
8. Wells RG, Havens PL. Intrapleural fibrinolysis for parapneumonic effusion and empyema in children. Radiology 2003; 228:370–378. [Crossref]
9. Jamal M, Reebye SC, Zamakhshary M, Skarsgard ED, Blair GK. Can we predict the failure of thoracostomy tube drainage in the treatment of pediatric parapneumonic collections? J Pediatr Surg 2005; 40:838–841. [Crossref]
10. Chen LE, Langer JC, Dillon PA, et al. Management of late-stage parapneumonic empyema. J Pediatr Surg 2002; 37:371–374. [Crossref]
11. Huang HC, Chang HY, Chen CW, Lee CH, Hsiue TR. Predicting factors for outcome of tube thoracostomy in complicated parapneumonic effusion for empyema. Chest 1999; 115:751–756. [Crossref]
12. Akhan O, Ozkan O, Akinci D, Hassan A, Ozmen M. Image-guided catheter drainage of infected pleural effusions. Diagn Interv Radiol 2007; 13:204–209.
13. Rosen H, Nadkarni V, Theroux M, Padman R, Klein J. Intrapleural streptokinase as adjunctive treatment for persistent empyema in pediatric patients. Chest 1993; 103:1190–1193. [Crossref]
14. Filippiadis DK, Binkert C, Pellerin O, Hoffmann RT, Krajina A, Pereira PL. CIRSE quality assurance document and standards for classification of complications: The CIRSE classification system. Cardiovasc Intervent Radiol 2017; 40:1141–1146. [Crossref]
15. Doski JJ, Lou D, Hicks BA, et al. Management of parapneumonic collections in infants and children. J Pediatr Surg 2000; 35:265–270. [Crossref]
16. Ekingen G, Guvenc BH, Sozubir S, Tuzlaci A, Senel U. Fibrinolytic treatment of complicated pediatric thoracic empyemas with intrapleural streptokinase. Eur J Cardiothorac Surg 2004; 26:503–507. [Crossref]
17. Gates RL, Caniano DA, Hayes JR, Arca MJ. Does VATS provide optimal treatment of empyema in children? A systematic review. J Pediatr Surg 2004; 39:381–386. [Crossref]
18. Merriam MA, Cronan JJ, Dorfman GS, Lambiase RE, Haas RA. Radiographically guided percutaneous catheter drainage of pleural fluid collections. AJR Am J Roentgenol 1988; 151:1113–1116. [Crossref]
19. Ulku R, Onat S, Kilic N. Intrapleural fibrinolytic treatment of multiloculated pediatric empyemas. Minerva Pediatr 2004; 56:419–423.
20. Moulton JS, Benkert RE, Weisiger KH, Chambers JA. Treatment of complicated pleural fluid collections with image-guided drainage and intracavitary urokinase. Chest 1995; 108:1252–1259. [Crossref]
21. Ozkan OS, Ozmen MN, Akhan O. Percutaneous management of parapneumonic effusions. Eur J Radiol 2005; 55:311–320. [Crossref]
22. Tattersall DJ, Traill ZC, Gleeson FV. Chest drains: does size matter? Clin Radiol 2000; 55:415–421. [Crossref]
23. Israel EN, Blackmer AB. Tissue plasminogen activator for the treatment of parapneumonic effusions in pediatric patients. Pharmacotherapy 2014; 34:521–532. [Crossref]
24. Laisaar T, Pullerits T. Effect of intrapleural streptokinase administration on antistreptokinase antibody level in patients with loculated pleural effusions. Chest 2003; 123:432–435. [Crossref]
25. Paraskakis E, Vergadi E, Chatzimichael A, Bouros D. Current evidence for the management of paediatric parapneumonic effusions. Curr Med Res Opin 2012; 28:1179–1192. [Crossref]
26. McKee AJ, Ives A, Balfour-Lynn IM. Increased incidence of bronchopulmonary fistulas complicating pediatric pneumonia. Pediatr Pulmonol 2011; 46:717–721. [Crossref]
27. Krenke K, Sanocki M, Urbankowska E, et al. Necrotizing pneumonia and its complications in children. Adv Exp Med Biol 2015; 857:9–17. [Crossref]
28. Sawicki GS, Lu FL, Valim C, Cleveland RH, Colin AA. Necrotising pneumonia is an increasingly detected complication of pneumonia in children. Eur Respir J 2008; 31:1285–1291. [Crossref]