Dicle Tıp Dergisi / Dicle Medical Journal 2011; 38 (2): 228-230

CASE REPORT / OLGU SUNUMU

A rare complication during percutaneous transcatheter closure of atrial septal defect: Atrial rim erosion

Atriyal septal defektin perkutan transkateter kapatılmasında nadir bir komplikasyon: Atriyal kenar erozyonu

Mehmet Erdem Memetoğlu[1], Osman Güvenç[2]

[1]*Gümüşhane Devlet Hastanesi Kalp Damar Cerrahisi Bölümü, Gümüşhane, Türkiye*

[2]*Akdeniz Üniversitesi Pediatri Anabilim Dalı, Antalya, Türkiye*

Geliş Tarihi / Received: 08.08.2010, Kabul Tarihi / Accepted: 29.10.2010

ABSTRACT

In this report we persent a rare complication of Amplatzer septal occluder; associated with 'atrial rim' erosion during atrial septal defect closure. In our case report, we also present a brief review of literature of complications associated with transcatheter closure of atrial septal defects.

Key words: Atrial, equipment failure, septal defects, complication

ÖZET

Bu raporda Amplatzel septal oklüder'in, atriyal septal defekt onarımı esnasında, "atriyal kenar" erozyonuyla bağlantılı nadir bir komplikasyonu bildirmekteyiz. Olgu sunumuzda, atriyal septal defektlerin transkateter onarımında görülen komplikasyonlarının literatür özetini de sunduk.

Anahtar kelimeler: Atriyal, teçhizat yetersizliği, septum kusurları, komplikasyon

INTRODUCTION

Percutaneous device closure of atrial septal defect (ASD), has emerged as an alternative to traditional surgical closure. Although reduced hospital stay, decreased morbidity and absence of a surgical incision are beneficial, device-related complications are coming into light.

CASE

A 9-year-old male was found to have splitting of S2 and a 2/6 systolic murmur at the second left intercostal space in his physical examination. His body mass index (BMI) was found 28.5 kg/m^2. The electrocardiogram was unremarkable. A chest X-ray showed normal heart shadow with increased pulmonary vascular markings. Routine laboratory investigations revealed no abnormalities. Transthoracic echocardiography followed by intraoperative transesophageal echocardiography (TEE) evaluated the presence of a large secundum ASD (22 mm at its widest dimension) with a deficient aortic rim (Figure 1). Normal left ventricular systolic function, right atrium and pulmonary arteries were noticed. Pulmonary artery pressure was 40 mmHg and the Qp/Qs ratio was.[1,9]

The atrial septal defect occlusion procedure was performed in angiography laboratory.

An intravenous bolus of 80 mg of gentamycin and 300 U/kg heparin were administered 30 minutes prior to the procedure. The procedure was performed under general anesthesia and fluoroscopic and echocardiographic guidance. We used TEE for size assessment and monitoring of the whole procedure. Following standard right heart catheterization and haemodynamic measurements, an exchange guide wire was placed in a left pulmonary vein. A sizing balloon was passed into the left atrium and the stretched diameter of the ASD was determined. The sizing balloon was then exchanged for an appropriately sized device delivery sheath, and 28 mm sized atrial septal defect occluder (ASO) device (AGA Medical Corporation, Minnesota, ABD) was deployed and released across the defect (Figure 2). After all these steps; the device was tried to release from the loading wire but we couldn't manage to separate the loading wire from the device. The patient underwent emergency surgery. Surgery

Yazışma Adresi /Correspondence: *Dr. Mehmet Erdem Memetoğlu, Gümüşhane Devlet Hastanesi 29000 Gümüşhane / Türkiye* Email: dr.m.erdem07@hotmail.com

Copyright © Dicle Tıp Dergisi 2011, Her hakkı saklıdır / All rights reserved

Electronic PDF security powered by www.IndexCopernicus.com

was performed through a median sternotomy. After establishing standard bicaval cannulation and total cardiopulmonary bypass; we opened the right atrium. Intraoperative findings showed a perforation of the left atrial roof by penetration of the occluder device as well as penetration into the right atrial wall (Figure 3). After examining the secundum ASD, the occluded was resected, the ASD was closed with an autologous pericardial patch in a standard manner. Postoperative period was uneventful.

The patient was discharged on the 5th day without any complication.

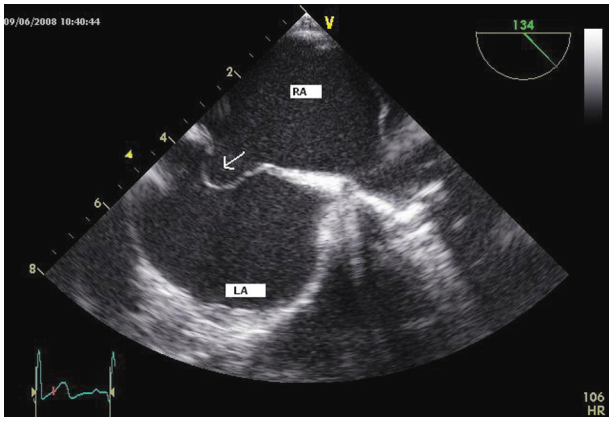

Figure 1. Transesophageal echocardiographic view of a secundum atrial septal defect. Arrow shows the secundum atrial septal defect

LA: left atrium, **RA:** right atrium

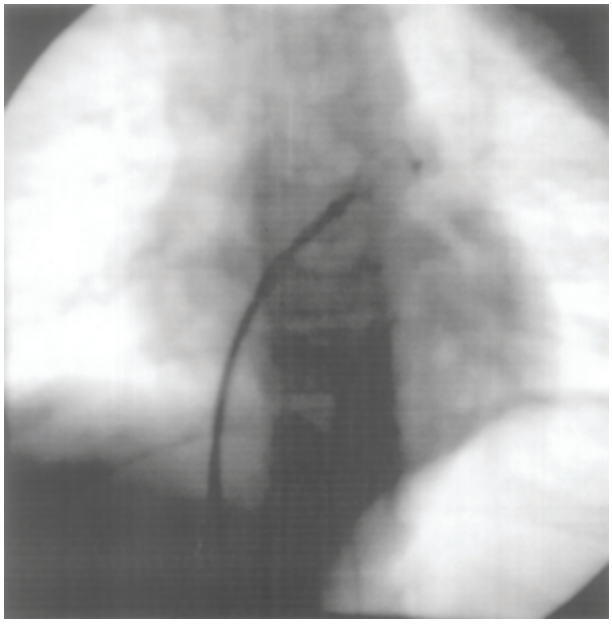

Figure 2. Image showing the amplatzer septal device at the right atrium during closure

Figure 3. The 28 mm Amplatzer septal occlusion device after extraction.

DISCUSSION

Device closure of ASDs has emerged as an attractive alternative to surgical closure for less morbidity, lack of a scar and shorter hospital stay.[1] Interventional closure remains impossible in patients with ostium premium defects, sinus venosus defects, and secundum septal defects >35 mm. There are contraindications in patients with multiple ASDs including lack of a rim around defect, which increases the risk of device embolisation; short septal length, small left atrium, and unusual location of the defect.[2]

The rate of thrombus formation on Amplatzer devices is very low.[3] There are rare case reports in the literature of cardiac rupture, which is of course a very ominous complication. There is also report of fistula formation between the left and the right atria.[4]

This is thought to be due to the use of an oversized device, which can cause rupture of the cardiac wall. Another study showed a very small probability of myocardial erosion due to the device (0.1%).[5]

This is more likely to occur in patients with an ASD located near the aortic wall, as well as in patients with an oversized device. Cardiac perforation is usually observed during the immediate postprocedural period, but may occur up to three years

Electronic PDF security powered by www.IndexCopernicus.com

later. However the probability of these complications is very low.[6]

The immediate complications following percutaneous ASD closure with an Amplatzer device are rare and involve mainly the very initial stage following the procedure. There are case reports in the literature of device embolization, either early or late, due to suboptimal implantation technique.[7] This is mainly due to the use of a device that is too small for the size of the defect, or the lack of sufficient rim at the inferior-posterior defect border.

We now report a case a perforation of the left atrial roof by penetration of the occluder device as well as penetration into the right atrial wall during percutaneous device closure of atrial septal defect. This complication is rare with only a few cases documented to date.[8]

In our opinion, the grossly oversized occluder could have also led to erosion of our case's atrial rim, and even if the risk is small, it would be arguably better to have a smaller device than a larger foreign body than is necessary to do the same work.

This study revealed that atrial rim deficiency and the size of ASD may be the most important relating factors in transcatheter closure of ASD.

We believe that while assessing the suitability of the margins of an ASD for device closure by echocardiography, atrial rims must be routinely assessed. Appropriate patient selection, as well as accurate device sizing to fit the dimensions of the defect, are important factors for the success and the safety of the method.

In conclusion, strict selection criteria governing an adequate atrial rim and the size of the device may help reduce the incidence of complications during percutaneous closure of atrial septal defects.

REFERENCES

1. Celiker A, Ozkutlu S, Karagöz T, Ayabakan C, Bilgiç A. Transcatheter closure of interatrial communications with Amplatzer device: results, unfulfilled attempts and special considerations in children and adolescents. Anadolu Kardiyol Derg 2005; 5(2):159-64.
2. Boutin C, Musewe NM, Smallhorn JF, et al. Echocardiographic following-up of atrial septal defect after catheter closure by double-umbrella device. Circulation 1993; 88(5):621-7.
3. Krumsdorf U, Ostermayer S, Billinger K, et al. Incidence and clinical course of thrombus formation on atrial septal defect and patient foramen ovale closure devices in 1,000 consecutive patients. J Am Coll Cardiol 2004; 43(3):302-9.
4. Preventza O, Sampath-Kumar S, Wasnick J, Gold JP. Late cardiac perforation following transcatheter atrial septal defect closure. Ann Thorac Surg 2004; 77(9):1435-7.
5. Amin Z, Hijazi ZM, Bass JL, Cheatham JP, Hellenbrand WE, Kleinman CS. Erosion of Amplatzer septal occluder device after closure of secundum atrial septal defects: review of registry of complications and recommendations to minimize future risk. Catheter Cardiovasc Interv 2004; 63(5):496-502.
6. Divekar A, Gaamangwe T, Shaikh N, Raabe M, Ducas J. Cardiac perforation after device closure of atrial septal defects with the Amplatzer septal occluder. J Am Coll Cardiol 2005; 45(8):1213-8.
7. Koçyildirim E, Kanani M, Bonhoeffer P, Elliott MJ. Amplatzer device embolization: hazards of multiple attempts at catheter retrieval. Anadolu Kardiyol Derg 2007; 7(3):329-30.
8. Berdat PA, Chatterjee T, Pfammatter JP, Windecker S, Meier B, Carrel T. Surgical management of complications after transcatheter closure of an atrial septal defect or patent foramen ovale. J Thorac Cardiovasc Surg 2000; 120(7):1034-9.

Electronic PDF security powered by www.IndexCopernicus.com