ZKTB

KLiNiK ARAŞTIRMA

Five-millimeter Port Site Spigelian Hernia After Laparoscopy

Laparoskopi Sonrası 5-mm'lik Trokar Yeri Hernisi: Spigel Hernisi

Aysen Telce Boza *, Evrim Bostancı *, Mesut Polat **, Hasan Yavuz **
Semra Kayatas *, Murat Api *

* Zeynep Kamil Women and Children Diseases Training and Research Hospital, Department of Obstetrics and Gynecology

** Zeynep Kamil Women and Children Diseases Training and Research Hospital, Department of General Surgery

ABSTRACT

Trocar site hernia is a rare complication of laparoscopic surgery. It mainly occurs at 10-mm and larger port sites. Only a few cases of herniation through 5-mm port sites were reported in the literature, but none of them occured through Spigelian fascia. We reported an unusual presentation of an incarcerated Spigelian hernia through 5-mm lateral port site, that presented with the symptoms of ileus.

Key words: total laparoscopic hysterectomy; 5-mm port site; Spigelian hernia

ÖZET

Trokar yeri hernisi laparoskopik cerrahinin nadir görülen komplikasyonlarından biridir. Genellikle 10-mm ve üzeri trokar yerlerinden gelişir. Literatürde 5-mm'lik trokar yerinden gelişen birkaç herni olgusu mevcuttur ancak hiçbiri Spigel fasyasından arasından gelişmemiştir. Biz bu yazıda, 5-mm'lik trokar yerinden gelişen, Spigel fasyası arasından inkansere olan ve ileus semptomları veren sıradışı olguyu sunmaktayız.

Anahtar kelimeler: total laparoskopik histerek-tomi; 5-mm trokar yeri; Spigel hernisi

İletişim Bilgileri:

Sorumlu Yazar: Aysen Telce Boza
Yazışma Adresi: Zeynep Kamil Women and Children Diseases Training and Research Hospital, Dept. of Obstetrics and Gynecology, Istanbul, Turkey, 34668
Tel: (+90) 530 923 00 46
Email: arcke83@gmail.com
Makalenin Geliş Tarihi: 03.10.2013
Makalenin Kabul Tarihi: 01.02.2014

INTRODUCTION

With the advancement and advantages of minimal invasive surgery in gynecologic practice, most of the hysterectomies are being done via laparoscopy. Almost all trocar site hernias have been found in sites greater than or equal to 10 mm, with only a few cases reported of 5-mm site herniation [1]. Spigelian hernia is a rare but important type of hernia because of high incarceration rate. It is extremely uncommon in the literature that Spigelian hernia occuring at 5-mm port site [2]. Here we reported a case of Spigelian hernia from 5-mm trocar site after total laparoscopic hysterectomy (TLH).

PRESENTATION OF CASE

Fourty seven year old primiparous women underwent TLH due to dysfunctional uterine bleeding unresponsive to the medical therapy. She had two phannestiel and one right subcostal incision for 3 previous abdominal surgery as cholecystectomy, ooferectomy and cesarean section. Four trocars entry technique was used ; one 10-mm trocar from umbilicus for telescope, one 10-mm trocar from 4 cm inferior to the umbilicus, other two lateral 5-mm trocars from 2-3cm medial to anterior superior iliac spine. Extensive adhesions of omentum to the anterior abdominal wall was noted. For adequate exposure the adhesiolysis were performed. Pnomoperitoneum was maintained between 14 and 16 mmHg throughout. The total time of pnomoperitoneum was 90 minute. The deep fascial layer of two 10-mm trocar sites were approximated by polyglactin 910 sutures but other two 5-mm lateral port sites were not closed. The patient's initial postoperative course was unremarkable. She began a liquid diet 6 hours after the surgery, at the end of first postoperative day, she had passage of

both flatus and faeces. She was discharged at the second postoperative day. With pain complaints at home, she readmitted at the same day of discharge. She detailed that moderate abdominal pain with paroxysms occuring every 4 minutes and nausea started. On her physical examination, the abdomen distended without the sign of peritonitis as rebound, guarding and localized tenderness; tympany also presented. The laboratory studies (serum electrolytes, BUN, creatinin, uric asid) were all within normal limits. On plain abdominal radiography which was done in upright position revealed a few air-fluid levels with distended loops of bowel on the left upper quadrant [Fig 1].

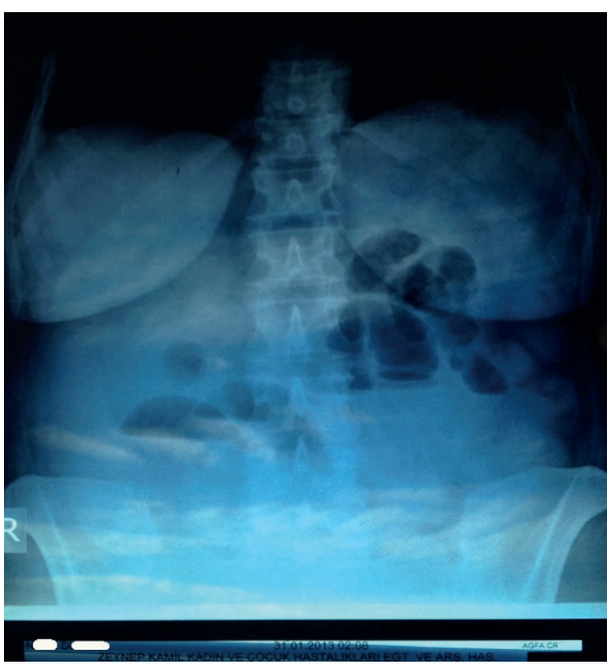

Figure 1: The plain abdominal X-ray at the readmission, bowel loops were seen on the left upper quadrant

With these findings the patients was consulted to the general surgery. She was followed up to 10 days with the diagnosis of partial bowel obstruction with nasogastric suction, intravenous fluid and total parenteral nutrition by stopping oral nutrition. On tenth days, because the nasogastric output declined, abdominal distention decreased due to passage of flatus a few times, the nasogastric tube was removed and the patient was began to soft diets. At the 12th day of readmission she started to vomit after every meal and complained of distention and inability to pass flatus again, a contrasted computerized tomography (CT) was obtained. It is reported that a segment of small bowel was found to be herniated through a right-sided fascial defect lateral to the midline, 6 cm superior to the inguinal region. Superficial tissue ultrasonography (USG) of this region also revealed small bowel loops above the rectus fascia [Fig 2].

Figure 2: Superfical tissue USG; small bowel loops seen as the hyperechogenic area above the abdominal fascia

Operative exploration through the midline incision revealed a fascial defect and herniated small bowel segment which was 60cm proximal to the ileocecal valve through aponeurosis of transversus abdominus muscle [Fig 3].

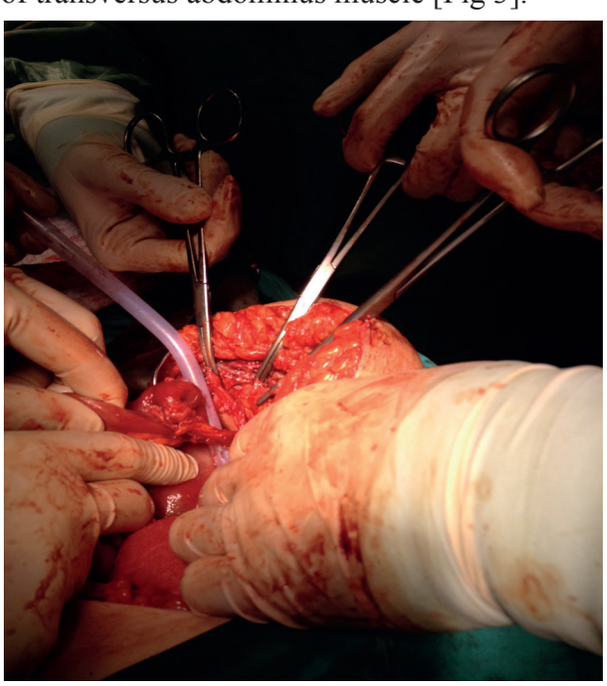

Figure 3: Incarcerated small bowel loop was observed at the hernia site

Herniation was detected the 5-mm lateral port site. The abdominal wall tissue in this area was noted to be quite thin and weak. The incarcerated 10 cm small bowel segment was removed from the fascial defect , 1-2cm serosal bowel injury was repaired as well as herniorrhaphy. All wrtitten informed consent was obtained from the patient for publication of this case report and accompanying images. A copy of the written consent is available for review by the Editor-in-Chief of this journal.

DISCUSSION

A Spigelian hernia occurs along the semilunar line, which is the caudal most extent of posterior rectus sheath [3]. This anatomic location is weak because of the absence of a posterior sheath behind the rectus muscle. Altough almost 1000 cases have been reported in the literature, only a few cases have been seen after laparoscopic procedures [4]. Our case was a rare complication namely Spigelian hernia after laparoscopic total hysterectetomy.

Spigelian hernias are uncommon and are often a diagnostic challange. Since its rarely after laparoscopy, diagnostic workup did not cover all possible causes. They occur through the Spigelian fascia, which is the part of the transversus abdominus aponeurosis lying between the semilunar line and the lateral edge of the rectus muscle. Spigelian hernias may contain preperitoneal fat, greater omentum, small intestine or colon or rarely other organs. Approximately 20% of reported Spigelian hernias were incarcerated at the time of operation [4]. In our case, the hernia contained 10cm small bowel segment incarcerated through transversus abdominus aponeurosis. Patients with Spigelian hernias may complain of pain, local swelling, or both. However, the symptoms, location and severity are quite variable and may be intermittent. In addition, bowel obstruction is not commonly reported. Our patient had no findings on physical examination, only had symptoms of ileus. These non-spesific findings made our diagnosis difficult and delayed.

CT scanning of the abdomen will confirm the presence of Spigelian hernia [5], but USG examination has been shown to be the most reliable and easiest method to asist in diagnostic workup [6]. Our diagnosis was obtained 12 day after the first symptom occured on account of CT scan and the diagnosis was confirmed by superficial tissue USG which identified the nonreduced hernia passing through the defect in the Spigelian fascia. The diagnosis was further confirmed by intraoperative findings. Once the Spigelian hernia is confirmed, operative repair is mandatory. A transverse incision should be made directly over the fascial defect. We operated our patient with midline incision which made the operation difficult to reach the hernia and required further dissection. Spigelian hernia occurs through a preexisting fascial weakness, but that the herniation itself was the result of both the pnemoperitoneum and fascial weakness due to previous 3 abdominal surgery.

CONCLUSION

Due to high incarceration rate and difficulty in diagnosis, the Spigelian hernia would be beared in mind as the differential diagnosis of ileus after laparoscopy.

DISCLOSURE

No author has any potential conflict of interest.

REFERENCES

1. Plaus WJ. Laparoscopic trocar site hernias. J Laparoendosc Surg 1993;3:567-570.

2. Bassi A ; Tulandi T. Small bowel herniation through a spigelian defect within 48 hours after laparoscopy. J Minim Invasive Gynecol, 2013 May-Jun; Vol. 20 (3), pp. 392-3.

3. Skandalakis PN, Zoras O, Skandalakis JE, Mirilas P. Spigelian hernia: surgical anatomy, embryology, and technique of repair. Am Surg 2006; 72:42.

4. Spagen L. Spigelian hernia. Surg Clin North Am.1984;64(2):351-366.

5. Shenouda NF, Hyams BB, Rosenbloom MB. Evaluation of Spigelian hernia by CT. J Comput Assist Tomogr 1990; 14:777.

6. Mufid MM, Abu-Yousef MM, Kakish ME, et al. Spigelian hernia: diagnosis by high-resolution real-time sonography. J Ultrasound Med 1997; 16:183.