EXPERIMENTAL STUDY

Separate and synergistic effects of taurolidine and icodextrin in intra-abdominal adhesion prevention

Necmi Kurt, M.D., Hasan Ediz Sıkar, M.D., Levent Kaptanoğlu, M.D., Hasan Fehmi Küçük, M.D.

Department of General Surgery, Kartal Dr. Lütfi Kırdar Training and Research Hospital, Istanbul-*Turkey*

ABSTRACT

BACKGROUND: In our present study, we aimed to evaluate the effects of taurolidine, a blocking agent of fibrin deposition, and icodextrin, a colloid osmotic material that also inhibits fibrin accumulation, and the effect of their application separately and concomittantly in intra-abdominal adhesion prevention.

METHODS: Forty BALB/c male mice, weighing 30–35 g and 11–12 weeks old were divided into four groups as follows: group 1: control group, group 2: taurolidine group, group 3: icodextrin group, and group 4: taurolidine and icodextrin group. Animals were sacrificed by cervical dislocation after 14 days. The adhesions were classified and scored by two blinded researchers according to Nair's macroscopic adhesion staging system and microscopically evaluated using Zuhlke classification system.

RESULTS: In group 2 there was no mice with score 4. In group 3, scores 3 and 4 were absent. Scores 2, 3, and 4 were not detected in group 4. The mean value of adhesion scores decreased from groups 1 to 4. There was a significant statistical difference between all the groups and group 1. There was no change between the study groups on macroscopic examination, whereas histopathological examination revealed statistically significance between group 4 and other groups.

CONCLUSION: Taurolidine and icodextrin, when used alone or together, decrease postoperative intra-abdominal adhesion formation. Macroscopic appearence was not supportive of statistical difference between group 4 and other groups. Microscopic evaluation paves the road for future studies for determining significance when taurolidine and icodextrin are applied concomittantly. Additional experimental studies are required for dose adjustment.

Keywords: Icodextrin; surgical adhesions; taurolidine.

INTRODUCTION

Adhesions form as a natural part of the body's healing process after surgery in a similar manner as scars. The term adhesion is commonly used when the scar extends from within one tissue across another tissue, usually across the peritoneal cavity in surgical cases. Postsurgical adhesions commonly occur when two separate surfaces are close to one another. This type of formation may cause inflammation and accumulation of fibrin deposits on damaged tissues. Fibrin then connects two separate tissues and acts like a glue to seal the injured site. The rate of intra-abdominal adhesion formation following abdominal surgeries is 67%–93%.[1] Postoperative intra-abdominal adhesions still remain as major obstacle in successful treatment of patients with acute mechanical intestinal obstruction.[2,3] Nearly 75% of these cases suffer from signs and symptoms of ileus. Our records describe a rate of 45.5%.[4] Other consequences of intra-abdominal adhesions are as infertility, chronic pelvic pain, and major additive complications of secondary surgeries.[5] Postoperative intra-abdominal adhesions may cause a significant increase in hospital costs because of high morbidity and mortality rates.[3] Depending on the severity of the obstruction, a partial obstruction may relieve itself with a conservative approach. However, many adhesions require surgery for treatment. Therefore, various efforts have been made to overcome adverse effects of adhesions. Meticulous dissection of tissues to avoid surgical trauma, manipulation of time-consuming effect of ischemia time, absence of overheated liquids while washing the intestines, providing ideal surgical manipulation by appropriate use of devices such as ecarteurs or cautery have all limited impacts in adhesion prevention. Various agents, including pharmacological drugs and physical barriers, were administered to avoid

Address for correspondence: Hasan Ediz Sıkar, M.D.
Kartal Dr. Lütfi Kırdar Eğitim ve Araştırma Hastanesi,
Genel Cerrahi Kliniği, İstanbul, Turkey
Tel: +90 216 - 458 30 00 E-mail: hasan.sikar@me.com

Submitted: 01.10.2016
Accepted: 23.12.2016

Ulus Travma Acil Cerrahi Derg
2017;23(5):377–382
doi: 10.5505/tjtes.2016.01957

Copyright 2017
TJTES

adhesions. Taurolidine is an antimicrobial agent used to prevent intra-abdominal adhesion formation and sepsis in experimental and clinical trials. In previous studies, the blocking effects of taurolidine on fibrin deposition have been described.[6] Icodextrin is an colloid osmotic material used in forming an aqueous solution for peritoneal dialysis and after gynecological procedures for reducing postoperative adhesions. The osmotic activity of icodextrin helps in separating tissues and reducing adhesive effects of fibrin. Tissues are kept from gluing together. In our present study, we aimed to evaluate effects of taurolidine and icodextrin in preventing intra-abdominal adhesions separately and to determine whether they have a synergistic effect when used concomitantly.

MATERIALS AND METHODS

This present study was conducted at Pendik Veterinary Control and Research Institute Experimental Animals Unit. Our study was approved by the Pendik Veterinary Control and Research Institute Animal Experiments Local Ethics Committee (25/17). Forty BALB/c male mice, weighing 30–35 g and 11–12 weeks old, were bred in Pendik Veterinary Control and Research Institute. The animals were randomized into four groups, consisting of 10 rats as follows: group 1: control group, group 2: taurolidine group, group 3: icodextrin group, and group 4: taurolidine and icodextrin group. Animals were kept in eight cages (five mice in each) with satisfactory environment conditions and room temperatur e in 12 h day/night cycles with free access to water and specific pathogen-free conditions. All animals were fed a normal diet.

Surgical Technique

All surgical procedures and approaches have been performed in semi-sterile environment. All animals were anesthetized with 4 mg/kg xylazine (Rompun, Bayer Turk Kimya San. Ltd. Sti., Istanbul, Turkey) and 100 mg/kg ketamine hydrocloride (Ketasol, Richter Pharma Ag, Wels, Austria) via the intramuscular route. Spontaneous breathing of mice has been provided perioperatively and with the help of a table lamp, the body temperature was maintained at 37°C. Prior to the incision, the abdominal space of all animals were cleaned and wiped with povidone iodide. Laparotomy was performed with a 15-mm midline incision. Two animals died because of adverse effects of anesthesia, but they were replaced with animals of the same species and gender. Initially, to achieve intraperitoneal adhesion, a cecal abrasion model was formed in all groups. Thus, following a 15-mm midline incision, the cecum was found and a 1 cm^2 defect in the serous layer and an additional 1 cm^2 peritoneal damage was created on the abdominal wall using a lancet. The intestines of all animals were re-placed into the abdominal cavity. In group 1 (n=10), the abdomen was closed without any pharmacologic agent administration (the control group). In group 2 (n=10), 1 ml (0.02 g) taurolidine (Taurolin®, Geistlich Sohns Ltd,Wolhusen, Switzerland) instillation was performed before closure (the taurolidine group). In group 3 (n=10), 1 ml (0.04 g) icodextrin 4% (Adept®, Baxter Healthcare Corporation, Deerfield, USA) instillation was performed (the icodextrin group). Finally, in group 4 (n=10), the abdomen was closed following 0.5 ml (0.01 g) taurolidine and 0.5 ml (0.02 g) icodextrin 4% instillation (the taurolidine and icodextrin group).

All animals were kept for 14 days and sacrificed by cervical dislocation. The abdominal cavity was reopened with a reverse U-shaped incision. Adhesions were scored by two blind observers according to Nair's macroscopic adhesion staging system, which has been used and tested before.[7] Cecum and adherent organs were extracted for histopathological analysis. All specimens were fixed in 10% formalin solution for histopathological evaluation. According to routine tissue processing, serial sections (5 µm) were stained with hematoxylin and eosin. Histopathological evaluation of the adhesions was performed by a blind investigator, following the rules followed by Zühlke et al.[8]

Statistical analysis was performed using the Statistical Package for Social Sciences software (SPSS Inc, vers. 13.0, Chicago, IL, USA). Numeric values were represented as n (number

Table 1. The adhesion scoring system defined by Nair et al.

Score	Explanation
0	Complete absence of adhesions
1	Single band of adhesions; between the viscera or from one viscus to the abdominal wall
2	Two bands between viscera or from the viscera to the abdominal wall
3	More than two bands; between viscera, from viscera to the abdominal wall, or complete intestines forming a mass without adhering to the abdominal wall
4	Viscera directly adherent to the abdominal wall irrespective of the number and extent of adhesive bands

Table 2. Histological classification according to Zuhlke et al.

Score	Explanation
1	Loose connective tissue, cell-rich, old and new fibrin, fine reticulin fibers
2	Connective tissue with cells and capillaries and few collagen fibers
3	More firm connective tissue, fewer cells, more vessels, and few elastic and smooth muscle fibers
4	Old firm granulation tissue, cell-poor, serosal layers that are hardly distinguishable

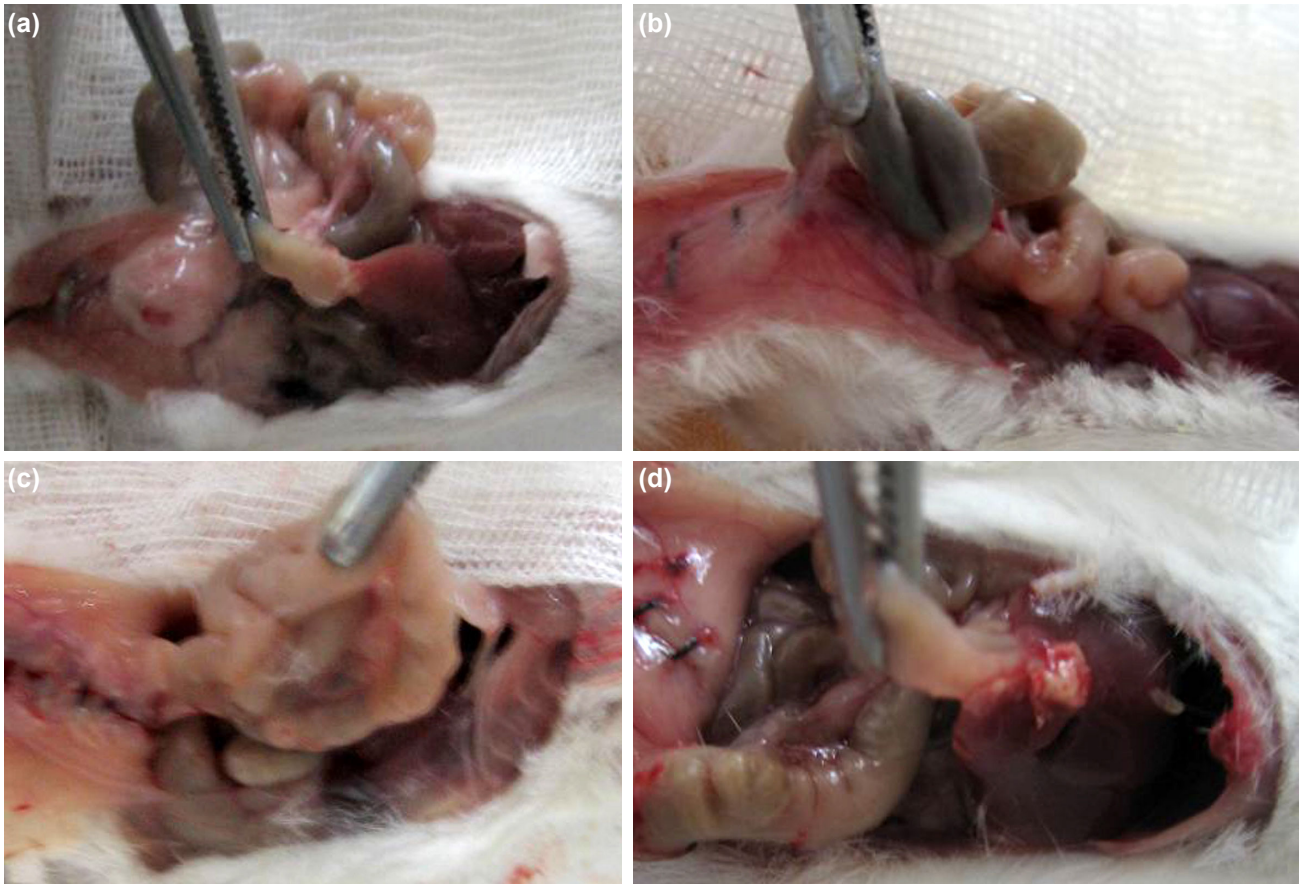

Figure 1. (a-d) Macroscopic findings. Single band of adhesions, score 1 **(a)**. Two bands between viscera, score 2 **(b)**. Complete intestines forming a mass, score 3 **(c)**. Viscera directly adherent to the abdominal wall, score 4 **(d)**.

of mice), mean ± standard deviation. Overall comparison of the groups was performed using Kruskal–Wallis Test. Paired comparisons of the groups were performed by Mann–Whitney U Test. Based on the results of analyses, p value <0.05 was considered to be statistically significant.

RESULTS

The adhesion scoring system defined by Nair et al was used in our study. Zero represents complete absence of adhesion, whereas 4 stands for viscera directly adherent to the abdominal wall. Table 1 describes the macroscopic scoring system. We tried to document our macroscopic findings in Figure 1. Adhesive band formation scores for specific groups are shown in Table 3; there was a statistically significant difference between all groups on overall comparison (p=0.007). No mice was detected with score 4 in group 2; scores 3 and 4 in group 3; scores 2, 3, and 4 in group 4. There was a significant statistical difference between all the groups and the control group, whereas there was no statistical difference among the study groups (i.e., groups 2–4) (Table 4).

According to Zühlke et al's histological classification system, 1 stands for loose connective tissue, whereas 4 represents old, firm granulation tissue. Table 2 describes histolopathological classification. There was no mice with score 4 in all groups. There was a significant statistical difference between

Table 3. Adhesion scores of groups (macroscopic/microscopic)

Adhesion Score	Group 1 (n=10)	Group 2 (n=10)	Group 3 (n=10)	Group 4 (n=10)
0	1	4	5	5
1	2/1	4/3	4/4	5/9
2	2/3	1/6	1/5	0/1
3	3/6	1/1	0/1	0/0
4	2/0	0/0	0/0	0/0

Table 4. Statistical comparison of adhesion degrees between groups

	Macroscopic Evaluation	Histological Evaluation
Group 1 – Group 2	p=0.022	p=0.031
Group 1 – Group 3	p=0.006	p=0.022
Group 1 – Group 4	p=0.003	p<0.001
Group 2 – Group 3	p=0.53	p=0.7
Group 2 – Group 4	p=0.4	p=0.007
Group 3 – Group 4	p=0.83	p=0.021

all groups on overall comparison (p=0.001). Group 4 showed statistically significant difference compared with other groups (Table 4). Histological evaluation results are depicted in Figure 2. There were no deaths during the postoperative period.

DISCUSSION

Postoperative intra-abdominal adhesion formation is a significant cause of morbidity and mortality and can also result in major technical difficulties during subsequent surgeries. During surgical procedures within the abdominal cavity, injury and ischemia of the peritoneum may result in adhesion formation. In response to trauma and ischemia, the damage on the peritoneum is usually covered with neutrophils in 4 h. Complete recovery takes place in nearly 1 week.[9–11] Though structurally different, the peritoneal recovery process is a biochemically inflammatory process and it is theoretically possible to manipulate this process using pharmacological agents, via their anti-inflammatory efficacy of resulting in increased fibrinolytic activity. In previous studies, non-steroidal anti-inflammatory drugs have been used, both perioperatively and postoperatively, for their anti-inflammatory effects on adhesion prevention. However, their impacts were insufficient and side effects remain as major obstacles in successful application.[12,13] Also, corticosteroids have been administered for preventing adhesions considering their suppressive effects against inflammatory response but have been found to be insufficient with low doses and serious side effects have been found with high doses.[14,15] Several pharmacological agents, such as high doses of vitamin E and simvastatin, were discovered to have a high efficacy in adhesion prevention.[16–18] Taurolidine is an antimicrobial agent used for intra-abdominal adhesion formation and sepsis prevention in experimental and clinical trials. In previous studies, the blocking effects of taurolidine on fibrin deposition have been described.[6] Taurolidine prevents long-term postoperative inflammation.[19–21] Tarhan et al. reported that intraperitoneal administration of taurolidine increases t-PA levels and t-PA plasminogen activator inhibitor type-1 ratio. This mechanism explains the effect of taurolidine on the peritoneal fibrinolytic system.[22] Taurolidine also have antiendotoxic, antibacterial, and tumoricidal effects besides its adhesion preventive effect. Its antimicrobial capacity against gram-positive, gram-negative, and anaerobic bacteria and some fungi makes taurolidine an effective drug. It can be used in infections with resistance against a wide range of antibiotics, such as staphylococcus resistant to metisiline and enterococcus resistant to vancomycine.[19,23] In our study, taurolidine has been explored and evaluated for its adhesion preventive effects. A statistically significant adhesion preventive effect has been found compared with the control group. We believe that taurolidine can be utilized for abdominal adhesion prevention.

Apart from pharmacological agents, physical barriers are also successful as they keep damaged surfaces apart during inflammatory response. As concomitant repair of the peritoneum takes place through all damaged surfaces, the ideal physical barrier should keep all peritoneal surfaces apart at the same time and for the same time period. Hyaluronic acid-saline buffered with phosphate combination or hyaluronic acid-

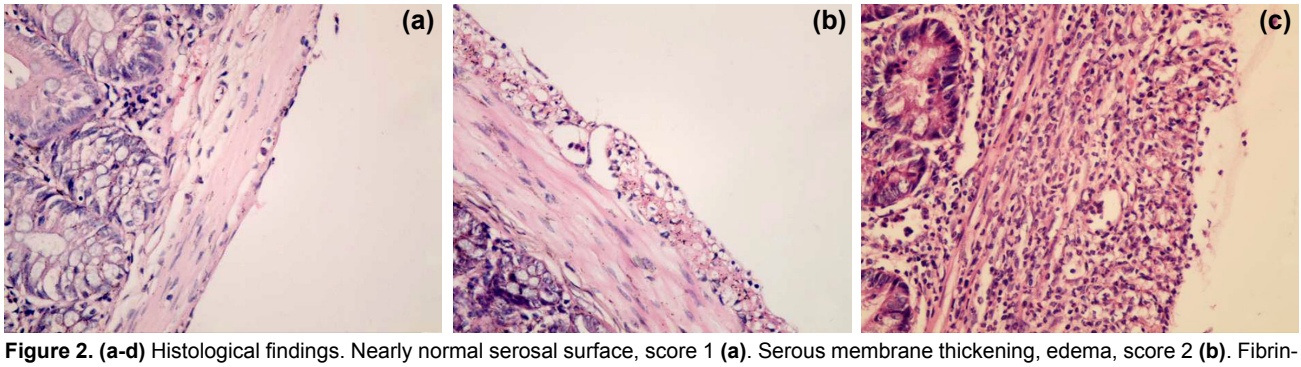

Figure 2. (a-d) Histological findings. Nearly normal serosal surface, score 1 **(a)**. Serous membrane thickening, edema, score 2 **(b)**. Fibrinous structure with serous membrane thickening, score 3 **(c)**.

carboxymethyl cellulose membrane has prevented peritoneal adhesions in a multicenter clinical trial.[24,25]

Icodextrin is a colloid osmotic material used for forming an aqueous solution for peritoneal dialysis and after gynecological procedures for reducing postoperative adhesions. The osmotic activity of icodextrin helps in separating tissues and reducing adhesive effects of fibrin. Tissues are kept from gluing together. Icodextrin is a solution whose adhesion preventive effects have been proven in preclinical and clinical studies.[26–28] Its ability to keep both damaged and non-damaged peritoneal surfaces apart makes it an ideal physical barrier. Icodextrin (4%) solution is not absorbed from the peritoneal space for 48 h; only half of it is absorbed in 96 h; thus, it continues showing its efficacy through the peritoneal surface for 3–5 days, which is a critical period for adhesion formation.[29] Besides, icodextrin has no effect on wound healing.[27]

In our study, we have used icodextrin 4% in group 3 animals. No adhesions of scores 3 and 4 have been detected. Compared with the control group, its adhesion preventive effect in group 3 has been found to be significant. We believe that anti-inflammatory effects and separation of damaged surfaces are required in combination for abdominal adhesion prevention. This synergistic impact can be achieved through the combined administration of taurolidine and icodextrin. Considering the features of these two different materials, we can predict that an ideal adhesion preventative material can be formed. Increased fibrinolytic activity and distance between peritoneal surfaces for a required period are the main goals of our study. Taurolidine and icodextrin, though having different mechanisms of activity, share similar usage patterns. In particular, their efficacy does not alter with respect to the implementer as they have easy application features. Although these two agents have not been recently discovered, concomitant application has not been observed in literature. In our study, we detected high abdominal adhesion preventive effects of taurolidine and icodextrin. The difference has been found to be statistically significant.

In our study, compared with groups 2 and 3, no experimental animal in group 4 had a score of 2, 3, and 4 for adhesion severity In addition, some animals in group 4 showed nearly normal serosal surfaces on evaluation of histopathological specimens. We believe that the combined application of taurolidine and icodextrin could be responsible for this synergistic effect. Our evaluation using Zuhlke's classification of histopathological tissues supported this idea.

Optimal dose of taurolidine and icodextrin in BALB/c species mice is not known; therefore, dose-dependent studies should be planned for future evaluations. Pharmacological agents, such as corticosteroids and vitamin E, has adhesion preventive effects at high doses.[14–17] Future studies may show similar impacts of taurolidine and icodextrin. In literature, there is a study in which in 2 ml (0.04 g) of taurolidine 2% solution has been used as an adhesion preventative.[30] Results of that study were similar to our findings. They were not able to discover any dose-dependent effects.

Our current study is the first experimental design for determining the efficacy of icodextrin 4% solution in adhesion prevention. Our results revealed successful adhesion prevention using with 1 ml (0.04 g) icodextrin. Concomitant application of taurolidine and icodextrin 4% solution was also tested for the first time (0.5 ml). In light of this pioneer study, further evaluations for dose adjustment are required to overcome adverse effects of abdominal adhesions.

In conclusion, taurolidine and icodextrin, when used alone or together, decrease postoperative intra-abdominal adhesion formation. Macroscopic appearance was not supportive of statistical difference between taurolidine and icodextrin group and other groups. Microscopic evaluation paves the way for future studies as significant abdominal adhesion preventive effects were observed when taurolidine and icodextrin were applied concomitantly. Additional experimental studies are required for dose adjustment.

Conflict of interest: None declared.

REFERENCES

1. Risberg B. Adhesions: Preventive Strategies. Eur J Surg Suppl 1997;577:32–9.
2. Parlak M. Barsak Tıkanmaları (İleus). In: Kalaycı G editor. Genel Cerrahi. İstanbul: Nobel Tıp Kitabevi; 2002. s. 1310–8.
3. Tavakkolizadeh A, Whang EE, Ashley SW, Zinner MJ. Small Bowel Obstruction. In: Brunicardi FC, Andersen DK, Billiar TR, Dunn DL, Hunter JG, Matthews JB, et al. editors. Schwartz's Principles of Surgery. 9th ed. New York: Mc Graw Hill Co; 2009. pp. 988–93.
4. Kucuk HF, Sıkar HE, Uzun H, Tutal F, Kaptanoglu L, Kurt N. Acute Mechanical Intestinal Obstructions. Ulus Travma Acil Cerrahi Derg 2010;16:349–52.
5. Liakakos T, Thomakos N, Fine PM, Dervenis C, Young RL. Peritoneal adhesions: etiology, pathophysiology, and clinical significance. Recent advances in prevention and management. Dig Surg 2001;18:260–73.
6. Kaptanoglu L, Kucuk HF, Colak E, Kurt N, Bingul SM, Akyol H, et al. The effect of taurolidine on experimental thrombus formation. Eur J Pharmacol 2008;578:238–41.
7. Nair SK, Bhat K, Aurora AL. Role of proteolyticenzyme in the prevention of postoperative intraperitoneal adhesions. Arch Surg 1974;108:849–53.
8. Zühlke HV, Lorenz EM, Straub EM, Savvas V. Pathophysiology and classification of adhesions. Langenbecks Arch Chir Suppl Verh Dtsch Ges Chir 1990;1009–16.
9. diZerega GS. Biochemical events in peritoneal tissue repair. Eur J Surg Suppl 1997;577:10–6.
10. Holmdahl L, Eriksson E, al-Jabreen M, Risberg B. Fibrinolysis in human peritoneum during operation. Surgery 1996;119:701–5.
11. Raftery AT. Regeneration of parietal and visceral peritoneum: an electron microscopical study. J Anat 1973;115:375–92.
12. Bateman BG, Nunley WC, Kitchin JD. Prevention of postoperative peritoneal adhesions with ibuprofen. Fertil Steril 1982;38:107–8.
13. Yücel O, Yankol Y, Köksoy FN, Önalan H, Akbaba P, İğdem AA. Postoperatif adezyonlar önlenebilir mi ? İntraabdominal adezyon modelinde

COX-2 selektif inhibitörü Rofecoxib'in etkisi. Çağdaş Cerrahi Dergisi 2005;19:145–9.
14. Grosfeld JL, Berman IR, Schiller M, Morse TS. Excessive morbidity resulting from the prevention of intestinal adhesions with steroids and antihistamines. J Pediatr Surg 1973;8:221–6.
15. Replogle RL, Johnson R, Gross RE. Prevention of postoperative intestinal adhesions with combined promethazine and dexamethasone therapy: experimental and clinical studies. Ann Surg 1966;163:580–8.
16. Erdener A, Çetinkurşun S, İlhan H, Ulman İ. Postoperatif intraperitoneal yapışıklıkların önlenmesinde E vitamininin yeri. Ulusal Cerrahi Dergisi 1989;5:29–31.
17. Kagoma P, Burger SN, Seifter E, Levenson SM, Demetriou AA. The effect of vitamin E on experimentally induced peritoneal adhesions in mice. Arch Surg 1985;120:949–51.
18. Kucuk HF, Kaptanoglu L, Kurt N, Uzun H, Eser M, Bingul S, et al. The role of simvastatin on postoperative peritoneal adhesion formation in an animal model. Eur Surg Res 2007;39:98–102.
19. Caruso F, Darnowski JW, Opazo C, Goldberg A, Kishore N, Agoston ES, et al. Taurolidine antiadhesive properties on interaction with E.coli;its transformation in biological environment and interaction with bacteria cell wall. PLoS One 2010;5:8927.
20. Watson RW, Redmond HP, Mc Carthy J, Bouchier-Hayes D. Taurolidine, an antilipopolysaccharide agent, has immunoregulatory properties that are mediated by the amino acid taurine. J Leukoc Biol 1995;58:299–306.
21. Bedrosian I, Sofia RD, Wolff SM, Dinarello CA. Taurolidine, an analogue of the amino acid taurine, suppresses interleukin 1 and tumor necrosis factor synthesis in human peripheral blood mononuclear cells. Cytokine 1991;3:568–75.
22. Tarhan OR, Barut I, Sezik M. An Evaluation of normal saline and taurolidine on intra-abdominal adhesion formation and peritoneal fibrinolysis. J Surg Res 2008;144:151–7.
23. Bisseling TM, Willems MC, Versleijen MW, Hendriks JC, Vissers RK, Wanten GJ. Taurolidine lock is highly effective in preventing catheter-related bloodstream infections in patients on home parenteral nutrition: a heparin-controlled prospective trial. Clin Nutr 2010;29:464–8.
24. Diamond MP. Reduction of de novo postsurgical adhesions by intraoperative precoating with Sepracoat (HAL-C) solution: a prospective, randomized, blinded, placebo-controlled multicenter study. The Sepracoat Adhesion Study Group. Fertil Steril 1998;69:1067–74.
25. González-Quintero VH, Cruz-Pachano FE. Preventing adhesions in obstetric and gynecologic surgical procedures. Rev Obstet Gynecol 2009;2:38–45.
26. Verco SJ, Peers EM, Brown CB, Rodgers KE, Roda N, diZerega G. Development of a novel glucose polymer solution (icodextrin) for adhesion prevention: pre-clinical studies. Hum Reprod 2000;15:1764–72.
27. Baca B, Boler DE, Onur E, Akca O, Hamzaoglu I, Karahasanoglu T, et al. Icodextrin and Seprafilm do not interfere with colonic anastomosis in rats. Eur Surg Res 2007;39:318–23.
28. diZerega GS, Verco SJ, Young P, Kettel M, Kobak W, Martin D, et al. A randomized, controlled pilot study of the safety and efficacy of 4% icodextrin solution in the reduction of adhesions following laparoscopic gynaecological surgery. Hum Reprod 2002;17:1031–8.
29. Hosie K, Gilbert JA, Kerr D, Brown CB, Peers EM. Fluid dynamics in man of an intraperitoneal drug delivery solution: 4% icodextrin. Drug Deliv 2001;8:9–12.
30. Bahadir I, Oncel M, Kement M, Sahip Y. Intra-abdominal use of taurolidine or heparin as alternative products to an antiadhesive barrier (Seprafilm) in adhesion prevention: an experimental study on mice. Dis Colon Rectum 2007;50:2209–14.

DENEYSEL ÇALIŞMA - *ÖZET*

Taurolidin ve icodextrin'in karıniçi yapışıklıkların önlenmesinde ayrı ve sinerjik etkileri

Dr. Necmi Kurt, Dr. Hasan Ediz Sıkar, Dr. Levent Kaptanoğlu, Dr. Hasan Fehmi Küçük

Kartal Dr. Lütfi Kırdar Eğitim ve Araştırma Hastanesi, Genel Cerrahi Kliniği, İstanbul

AMAÇ: Çalışmamızda fibrin oluşumunu engelleyen ajan olan taurolidin ve fibrin kümelenmesini engelleyen icodextrin'in ayrı ayrı ve birlikte uygulanmasının karıniçi yapışıklığın önlenmesine olan etkisini değerlendirmeyi amaçladık.
GEREÇ VE YÖNTEM: Kırk adet 30–35 gram ağırlığında, 11–12 haftalık erkek BALB/c fare, 4 gruba ayırıldı. Grup 1: Kontrol grubu, Grup 2: Taurolidin grubu, Grup 3: İsodekstrin grubu ve Grup 4: Taurolidin ve isodekstrin grubu olarak adlandırıldı. Deney hayvanları 14. gün servikal dislokasyonla sakrifiye edildiler. Yapışıklıklar iki kör araştırmacı tarafından Nair'in makroskobik yapışıklık skorlama sistemiyle sınıflandırıldı. Mikroskobik değerlendirme için Zühlke'nin sınıflandırması kullanıldı.
BULGULAR: Grup 2'de skor 4 olan fare olmadı. Grup 3'te skor 3 ve 4 olan fare yoktu. Skor 2, 3 ve 4 Grup 4'teki farelerde saptanmadı. Grup 1'den 4'e doğru yapışıklık skor ortalamalarının azaldığı görüldü. Kontrol grubuyla tüm çalışma grupları arasında istatistiksel açıdan anlamlı farklılık saptandı. Makroskobik değerlendirmede çalışma grupları arasında farklılık saptanmazken histopatolojik incelemede Grup 4 ve diğer çalışma grupları arasında istatistiksel açıdan anlamlı farklılık saptandı.
TARTIŞMA: Taurolidin ve isodekstrin ayrı ayrı veya beraber kullanıldığında karıniçi yapışıklık oluşumunu azaltmaktadır. Makroskobik görünüm taurolidin ve isodekstrin grubuyla diğerlerinin istatistiksel açıdan farklılığını desteklememektedir ancak mikroskobik değerlendirme beraber kullanıldıklarında farklılık yaratması nedeniyle gelecek çalışmalara yol göstermektedir. Doz ayarlaması için ilave deneysel çalışmalar gereklidir.
Anahtar sözcükler: Icodextrin; peritoneal yapışıklık; taurolidin.

Ulus Travma Acil Cerrahi Derg 2017;23(5):377–382 doi: 10.5505/tjtes.2016.01957