ORIGINAL ARTICLE

Ingested intraabdominal foreign bodies that require surgical intervention

Remzi Kızıltan, M.D.,[1] Özkan Yılmaz, M.D.,[1] Abbas Aras, M.D.,[1] Osman Toktaş, M.D.,[1] Abdulsamet Batur, M.D.,[2] Fatma Ağar, M.D.,[1] Şehmus Ölmez, M.D.,[3] Çetin Kotan, M.D.[1]

[1]Department of General Surgery, Yüzüncü Yıl University Faculty of Medicine, Van-*Turkey*
[2]Department of Radiology, Yüzüncü Yıl University Faculty of Medicine, Van-*Turkey*
[3]Department of Gastroenterology, Yüzüncü Yıl University Faculty of Medicine, Van-*Turkey*

ABSTRACT

BACKGROUND: The aim of the present study was to review cases that required surgical intervention to remove ingested foreign bodies.

METHODS: Medical records of 7 patients who underwent surgical intervention at the Yüzüncü Yıl University Department of General Surgery between 2009 and 2014 after ingesting foreign bodies were reviewed.

RESULTS: Female:male ratio was 5:2; mean age was 25 (16–35). Four patients had swallowed pins, 1 patient had swallowed a sewing pin, 1 patient had swallowed a safety pin, and 1 patient had swallowed a wristwatch. The patient who had swallowed the wristwatch had psychiatric disorders. All other patients stated that they had swallowed the objects by accident.

CONCLUSION: Most ingested foreign bodies pass smoothly through the gastrointestinal (GI) tract within a week, but those that migrate out of the lumen require surgical intervention due to complications including perforation, abscess, fistula, and peritonitis. Early diagnosis and intervention is crucial to reduce morbidity and mortality. It is believed that sharp and pointed objects that migrate outside of the lumen ought to be removed, lest they cause complications.

Keywords: Foreign body; ingested; laparoscopy; laparotomy; surgical intervention.

INTRODUCTION

Incidences of foreign body ingestion are globally observed. While foreign bodies often exit the body by gastrointestinal (GI) transit, surgical intervention is required in some cases. Though foreign body ingestion is observed among all age groups, it is most commonly encountered in children and early adolescents. Healthy adults may accidentally swallow objects such as needles, toothpicks, dentures, fish bones, and chicken bones. In addition, various foreign bodies are ingested by individuals with psychiatric disorders. Most ingested foreign bodies pass through the GI tract without inducing complication.[1,2] Otherwise, bleeding caused by mucosal erosion and abrasion may occur, and can be very serious, or even life-threatening. Massive gastrointestinal system (GIS) bleeding associated with aortoduodenal fistula, which occurred following needle ingestion, was described in a report by Kotan C. from the present clinic.[3] In addition, migration out of the lumen, GIS perforation, abscess, and peritonitis may be observed. The rate of such complications arising from the ingestion of foreign bodies is estimated to be less than 1%.[4]

Presently described are clinical presentations of various ingested objects and the treatments applied.

Address for correspondence: Remzi Kızıltan, M.D.
Yüzüncü Yıl Üniversitesi Tıp Fakültesi, Genel Cerrahi Anabilim Dalı, 65100 Van, Turkey
Tel: +90 432 - 215 04 72 / 6835 E-mail: bergamalidr@mynet.com

Qucik Response Code

Ulus Travma Acil Cerrahi Derg
2016;22(3):269–272
doi: 10.5505/tjtes.2015.87400

Copyright 2016
TJTES

MATERIALS AND METHODS

The Ethics Committee of the Yüzüncü Yıl University Medical Faculty approved the present study in decision no. 1 made on June 18, 2015. Medical records of 7 patients who underwent surgical retrieval of ingested foreign bodies at Yüzüncü Yıl University Department of General Surgery between 2009 and 2014 were retrospectively reviewed. The foreign bodies were pins in 4 patients, a sewing pin in 1 patient, a safety pin in 1 patient, and a wristwatch in 1 patient (Figs. 1, 2).

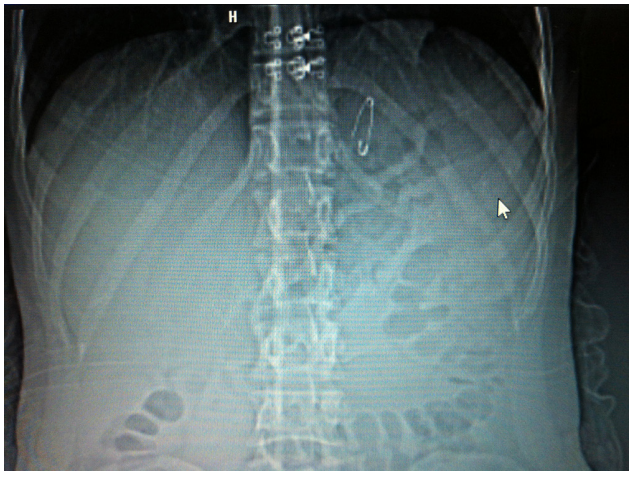

Figure 1. Safety pin in the abdomen.

Figure 2. The wristwatch was removed from the stomach.

Physical examinations were performed, plain abdominal radiographs were taken, and high-fiber diet was recommended during weekly follow-ups. Comparison of the localization of the foreign body with that shown on previous radiography served as evaluation of radiography during follow-up. Abdominal tomography was planned when localization of the foreign body was constant. On abdominal computed tomography (CT) scans, it was observed that foreign bodies were extraluminal in 6 cases, 2 of which were in the liver, 2 of which were in the omentum majus, and 1 of which was in the omentum minus. In the case in which the patient ingested a safety pin, localization of the foreign body appeared constant on plain abdominal radiography follow-up. CT scan of the abdomen showed that it was adjacent to the stomach wall, outside the stomach. The object was not visible on gastroscopy. Gastroscopy was performed on another patient, who had ingested a wristwatch, but surgical procedure was deemed necessary due to failure of the extraction process.

RESULTS

Five female and 2 male patients were included, with an average age of 25 (16–35). The patient who swallowed the wristwatch had psychiatric disorders; the others stated that they had swallowed the foreign bodies by accident.

Common symptoms were non-specific abdominal pain in the right upper quadrant or the epigastric region. Surgical intervention was scheduled because the patients were symptomatic, and because foreign bodies were extraluminal on abdominal CT scans. In 2 patients, pins were laparoscopically removed from the omentum majus and omentum minus. Two foreign bodies were extracted from the liver segment, and 5 were extracted from the omentum minus via direct laparotomy in 2 patients. In the other 3 patients, decision to perform laparotomy was made because it was not possible to detect the foreign bodies via laparoscopic exploration. Location of the foreign bodies was determined with the aid of fluoroscopy. In 1 patient, a pin was removed from the liver parenchyma. In another, laparoscopic exploration was performed to extract a safety pin localized adjacent to the stomach, though it proved impossible to detect the foreign body via laparotomy. A safety pin was located in the lumen of the cecum on CT scan of the abdomen obtained on the first postoperative day. This was interpreted as a probable translocation of the safety pin due to surgical manipulation of the intestinal lumen that superposed with the stomach. During follow-up, the safety pin was safely discarded by defecation. Subsequent to laparoscopic exploration, the patient who ingested the wristwatch underwent gastrotomy. The wristwatch was located in the gastric fundus and was removed from the abdomen by slightly expanding the port site and gastrostomy line (Table 1).

DISCUSSION

Incidence of foreign body ingestion is not known. The most common cause is ingestion by accident. Perforation most commonly occurs in the duodenal, ileocecal, and rectosigmoid regions.[4] Most foreign bodies transmigrate uneventfully from the stomach to the duodenum and transverse from the colon to the liver.[5] Of those included in the present study, 2 foreign bodies were extracted from the right lobe of the liver, 1 was extracted from the omentum minus, and 2 were extracted from the omentum majus. For this reason, the starting point of transmigration is thought to be the duodenum.

Average follow-up period was 2.5 months. The psychiatric patient who ingested the wristwatch attended the shortest follow-up period (1 month), while the longest (6 months) was

Table 1. Summary of cases

No	Name-Surname	Age	Gender	Duration of the pre-operative Follow-up (month)	Type and localization of the foreign body	Performed surgical procedure
1	F.G	22	Female	2	A pin in the liver segment seven	The foreign body was removed via open surgery which started with laparoscopy
2	Y.T	26	Female	2	A pin in the omentum majus	The foreign body was removed via laparotomy
3	A.A	16	Female	2	A sewing needle in the liver segment five	The foreign body was removed via laparotomy
4	M.C.Ö	34	Male	2	A pin in the omentum majus	The foreign body was removed via laparoscopy
5	A.A	35	Female	2	A pin in the omentum minus	The foreign body was removed via laparoscopy
6	A.A	25	Female	6	A safety pin in the abdomen	Started with laparoscopy and continued with laparotomy but the foreign body could not be found
7	E.Ö	22	Male	1	A wristwatch in the stomach	Started with laparoscopy, then foreign body removed via laparotomy

attended by the patient who ingested the safety pin. Most ingested foreign bodies pass harmlessly through the GI tract within 1 week.[6–8] If this does not occur, clinicians must seriously consider the possibility of complications.

Plain radiography is sufficient for the determination of the localization of most radio-opaque foreign bodies;[9] CT and magnetic resonance imaging are rarely necessary. In the present study, follow-up involved plain radiography of the abdomen. Biochemical hemogram and CT scan of the abdomen were obtained in symptomatic patients with unchanging foreign body localization observed on plain radiography of the abdomen.

As foreign bodies migrate out of the lumen, they may cause very small perforation and minimal leakage. Therefore, peritonitis occurrence is thought to be very rare. Foreign bodies that migrate to the extraluminal region may remain unnoticed for long periods of time, and are thus more likely to cause infection and abscess. Occurrence of abscess was not observed in the present cases.

Çekirdekçi reported cardiac tamponade in 2 cases in which sewing pins migrated from the esophagus.[10] Localization in the vertebrae resulting from migration was reported by Özsunar.[11] In a study by Chen, thyroid abscess that occurred following ingestion of a fish bone by a 50-year-old female Chinese patient was reported.[12]

Gurjit Singh reported an increase in the frequency of children aged between 6 months and 6 years swallowing button batteries from toys, which can cause corrosive injuries. Therefore, if detected in the esophagus, batteries should be removed immediately via endoscopic intervention.[13]

Urgent intervention is indicated if any of the following warning signs are present:[14]

- Localization of battery in the esophagus
- Patient showing signs of airway compromise
- Evidence of near-complete esophageal obstruction
- When the ingested object is sharp, long (>5 cm), and localized in the esophagus or stomach
- When the ingested object is a high-powered magnet or magnets
- When signs or symptoms suggesting inflammation or intestinal obstruction are present (fever, abdominal pain, or vomiting).[15]

Surgical removal should be considered for blunt objects beyond the stomach that remain in the same location for longer than 1 week.[16]

Conclusion

Ingested foreign bodies should be strictly followed until they are naturally expelled from the body. Furthermore, early diagnosis and intervention is crucial in the reduction of morbidity and mortality. Sharp and pointed objects that migrate

outside the lumen should be removed before they cause complications.

Conflict of interest: None declared.

REFERENCES

1. Crankson SJ. Hepatic foreign body in a child. Pediatr Surg Int 1997;12:426–7.
2. Lee KF, Chu W, Wong SW, Lai PB. Hepatic abscess secondary to foreign body perforation of the stomach. Asian J Surg 2005;28:297–300.
3. Başer M, Arslantürk H, Kisli E, Arslan M, Oztürk T, Uygan I, et al. Primary aortoduodenal fistula due to a swallowed sewing needle: a rare cause of gastrointestinal bleeding. Ulus Travma Acil Cerrahi Derg 2007;13:154–7.
4. Santos SA, Alberto SC, Cruz E, Pires E, Figueira T, Coimbra E, et al. Hepatic abscess induced by foreign body: case report and literature review. World J Gastroenterol 2007;13:1466,70.
5. Nishimoto Y, Suita S, Taguchi T, Noguchi S, Ieiri S. Hepatic foreign body - a sewing needle - in a child. Asian J Surg 2003;26:231–3.
6. Abel RM, Fischer JE, Hendren WH. Penetration of the alimentary tract by a foreign body with migration to the liver. Arch Surg 1971;102:227–8.
7. Crankson SJ. Hepatic foreign body in a child. Pediatr Surg Int 1997;12:426–7.
8. Lotfi M. Foreign body in the liver. Int Surg 1976;61:228.
9. Suita S, Ohgami H, Nagasaki A, Yakabe S. Management of pediatric patients who have swallowed foreign objects. Am Surg 1989;55:585–90.
10. Cekirdekci A, Ayan E, Ilkay E, Yildirim H. Cardiac tamponade caused by an ingested sewing needle. A case report. J Cardiovasc Surg (Torino) 2003;44:745–6.
11. Ozsunar Y, Tali ET, Kilic K. Unusual migration of a foreign body from the gut to a vertebral body. Neuroradiology 1998;40:673–4.
12. Chen CY, Peng JP. Esophageal fish bone migration induced thyroid abscess: case report and review of the literature. Am J Otolaryngol 2011;32:253–5.
13. Singh G, Sharma S, Khurade S, Gooptu S. Ingested foreign bodies in children: a report of two cases. J Family Med Prim Care 2014;3:452–5.
14. Gilger MA, Jain AK, McOmber ME. Foreign bodies of the esophagus and gastrointestinal tract in children. Literature review current through. 2013. Aug, [Last cited on 2013 Aug 23]. Available at: http://www.uptodate.com/contents/foreignbodies of the esophagus and gastrointestinal tract in children.
15. Uyemura MC. Foreign body ingestion in children. Am Fam Physician 2005;72:287–91.
16. Ikenberry SO, Jue TL, Anderson MA, Appalaneni V, Banerjee S, Ben-Menachem T, et al. Management of ingested foreign bodies and food impactions. Gastrointest Endosc 2011;73:1085–91.

ORİJİNAL ÇALIŞMA - *ÖZET*

Yutulan ve cerrahi müdahale gerektiren intraabdominal yabancı cisim olgularımız

Dr. Remzi Kızıltan,[1] Dr. Özkan Yılmaz,[1] Dr. Abbas Aras,[1] Dr. Osman Toktaş,[1] Dr. Abdulsamet Batur,[2] Dr. Fatma Ağar,[1] Dr. Şehmus Ölmez,[3] Dr. Çetin Kotan[1]

[1]Yüzüncü Yıl Üniversitesi Tıp Fakültesi, Genel Cerrahi Anabilim Dalı, Van
[2]Yüzüncü Yıl Üniversitesi Tıp Fakültesi, Radyoloji Anabilim Dalı, Van
[3]Yüzüncü Yıl Üniversitesi Tıp Fakültesi, Gastroenteroloji Anabilim Dalı, Van

AMAÇ: Bu çalışmada yutulan yabancı cismin vücut dışına çıkarılması için cerrahi müdahale yapılan olgular analiz edildi.
GEREÇ VE YÖNTEM: Van Yüzüncü Yıl Üniversitesi Tıp Fakültesi Genel Cerrahi Anabilim Dalı'nda 2009 ile 2014 yılları arasında yabancı cisim yutulması sonrasında cerrahi müdahale yapılmış yedi olgunun tıbbi kayıtları geriye dönük olarak incelendi.
BULGULAR: Erkek/kadın oranı 2/5, ortalama yaş 25 (16–35), dört olgu toplu iğne, bir olgu dikiş iğnesi, bir olgu çengelli iğne ve bir olgu da kol saati yutmuştu. Kol saati yutan olgunun psikyatrik hastalığı bulunmaktaydı. Diğer bütün olgular yabancı cisimleri kazara yuttuklarını ifade ediyorlardı.
TARTIŞMA: Yutulan yabancı cisimlerin çoğu bir hafta içinde gastrointestinal tarktusu sorunsuzca geçmekte ancak lümen dışına migrasyon yapan bir kısmı perforasyon, apse, fistül ve peritonit gibi komplikasyonlar nedeni ile cerrahi tedavi gerektirmektedir. Morbidite ve mortalitenin azaltılması için erken tanı ve müdahale önemlidir. Lümen dışına çıkan keskin ve sivri cisimlerin, herhangi bir komplikasyon meydana getirmeden cerrahi müdahale ile çıkarılması gerektiğini düşünmekteyiz.

Anahtar sözcükler: Cerrahi müdahale; laparoskopi; laparotomi; yabancı cisim; yutma.

Ulus Travma Acil Cerrahi Derg 2016;22(3):269–272 doi: 10.5505/tjtes.2015.87400