CASE REPORT

Embolism of a pellet after shotgun injury: From liver to right ventricle

Selim Bakan, M.D.,[1] Bora Korkmazer, M.D.,[1] Ahmet Baş, M.D.,[1] Osman Şimşek, M.D.,[2] Hasan Ali Barman, M.D.,[3] Deniz Çebi Olgun, M.D.[1]

[1]Department of Radiology, İstanbul University Cerrahpaşa Faculty of Medicine, İstanbul-*Turkey*

[2]Department of General Surgery, İstanbul University Cerrahpaşa Faculty of Medicine, İstanbul-*Turkey*

[3]Department of Cardiology, İstanbul University Cerrahpaşa Faculty of Medicine, İstanbul-*Turkey*

ABSTRACT

Bullet embolism to the heart is a rare but serious complication of penetrating trauma. Distant migration of foreign bodies via the vascular system must be taken into consideration following penetrating gunshot trauma. Delays in diagnosis may result in poor management and subsequent complications that may lead to grave prognosis. Presently described was a conservatively managed case of asymptomatic intracardiac pellet embolization. Highlighted was the importance of serial scanning for intravascular migration of pellet following penetrating gunshot injury, in addition to conservative management in asymptomatic patients.

Keywords: Heart; pellet embolization; gunshot injury.

INTRODUCTION

Bulllet embolism is a relatively rare but potentially life-threatening complication of penetrating missile injury. Bullets from penetrating wounds can access the vasculature and migrate to nearly every large vascular bed. Patients may be asymptomatic or present with devastating complications such as sepsis, ischemia, endocarditis, cardiac valvular incompetence, stroke, and pulmonary embolism.[1]

Presently reported was a case of asymptomatic venous embolization, in which a pellet possibly migrated from the right hepatic vein to the interventricular septum. The case was managed conservatively after failure of endovascular methods due to arrhythmia.

CASE REPORT

A previously healthy 29-year-old male was brought to the emergency department with gunshot injuries. Physical examination revealed multiple millimetric hemorrhagic entrance holes in the anterior abdominal wall, anterior chest wall, bilateral thigh region, right suprapubic region, left supraorbital region and metacarpophalangeal joint of the third finger of the left hand. Glasgow Coma Scale score was 15. Upon arrival, the pulse was 98 bpm, with systolic blood pressure of 100 mmHg.

Thoracoabdominal computed tomography (CT) was performed in order to evaluate the thoracoabdominal region, as well as pellet trajectory. Thorax CT revealed a metallic foreign body in the inferior lobe superior segment of the left lung, as well as in the sternum. Densities consistent with contusion were present in the superior lobe posterior segment, inferior lobe superior segment, and inferior lingular segment of the left lung. On abdominal CT, pellets were observed in the right lobe of the liver (segment 6), the posterior wall of the gastric corpus, the anterior perigastric fatty tissue, the jejunum, the bilateral perinephric tissues, the left psoas muscle, and the subcutaneous tissue of the abdominal wall. Lacerations were detected in the anterosuperior—posteroinferior aspects of the spleen, as well as in the posterolateral left kidney. Abdominal CT also revealed widespread high-density fluid within the abdomen.

The patient was in hypovolemic shock one hour after arrival, and was emergently transferred to surgery for abdominal exploration, which revealed hemorrhagia from the spleen and

Address for correspondence: Selim Bakan, M.D.
İstanbul Üniversitesi, Cerrahpaşa Tıp Fakültesi,
Radyoloji Anabilim Dalı, Fatih, İstanbul Turkey
Tel: +90 505 - 934 51 56 E-mail: dr.selim79@gmail.com

Qucik Response Code

Ulus Travma Acil Cerrahi Derg
2016;22(4):395–398
doi: 10.5505/tjtes.2015.32470

Copyright 2016
TJTES

retroperitoneal vessels in the peripancreatic region. After splenectomy provided better exposure, hematoma due to laceration of the pancreatic tail was detected. Regions of active bleeding were repaired with primary suturation. Due to the presence of focal hemorrhagic spots secondary to massive transfusion coagulopathy, Mikulicz tamponade was placed over the splenectomy lodge and distal pancreatic region. Intestinal edema was observed, and Bogota bag technique was performed to prevent abdominal compartment syndrome. Reoperation was planned for 24 hours later. Detected during the second operation were multiple entrance holes in the jejunum, as well as a few in the gastric corpus, the posterior wall of the gastric antrum, and the anterolateral wall of the caecum. Margins of the existing entrance holes were debrided and repaired with modified Gambee sutures. Surgery was concluded following control of bleeding and debridement of the necrotic entrance holes in the anterior abdominal wall. The patient survived, with a good clinical course. No complication was observed, though the majority of the pellets remained in the abdomen.

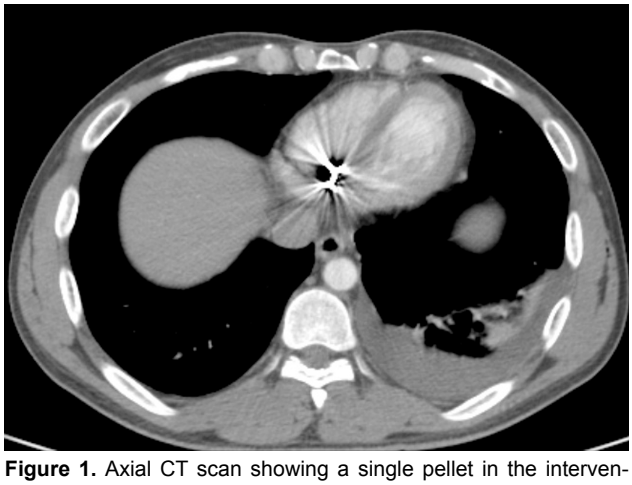

Figure 1. Axial CT scan showing a single pellet in the interventricular septum, with no suggestion of cardiac or mediastinal injury.

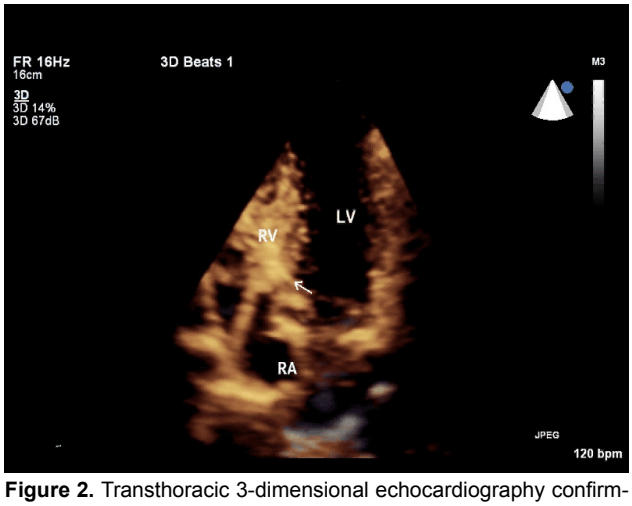

Figure 2. Transthoracic 3-dimensional echocardiography confirming location of the pellet (white arrow) in the side of the interventricular septum facing the right ventricle, 12 mm above the tricuspid annulus.

On the tenth postoperative day, abdominal CT (Fig. 1) showed a single pellet in the interventricular septum, with no indication of cardiac or mediastinal injury. Transthoracic 3-dimensional echocardiography (Fig. 2) confirmed the location of the pellet in the side of the interventricular septum facing the right ventricle, with no pericardial effusion or evidence of free-wall perforation. In order to investigate the source of the pellet embolization, prior (preoperative) and recent (postoperative day 10) thoracoabdominal CT examinations were compared (Fig. 3). The pellet was located in segment 6 of the liver on prior CT examination, but could not be detected on current CT scan. No other significant differences in location of the pellets remaining in the abdomen or thorax were observed upon comparison.

The most plausible explanation for the intracardiac location of the pellet was determined as intravascular migration from the right hepatic vein to the heart via the inferior vena cava. The patient was taken to the interventional radiology unit for endovascular retrieval of the intracardiac pellet. Under local anesthesia following right axillary vein puncture with Seldinger technique, 5-F introducer placement was performed. Access to the right atrium and right ventricle was obtained through the right axillary vein and superior vena cava. Mul-

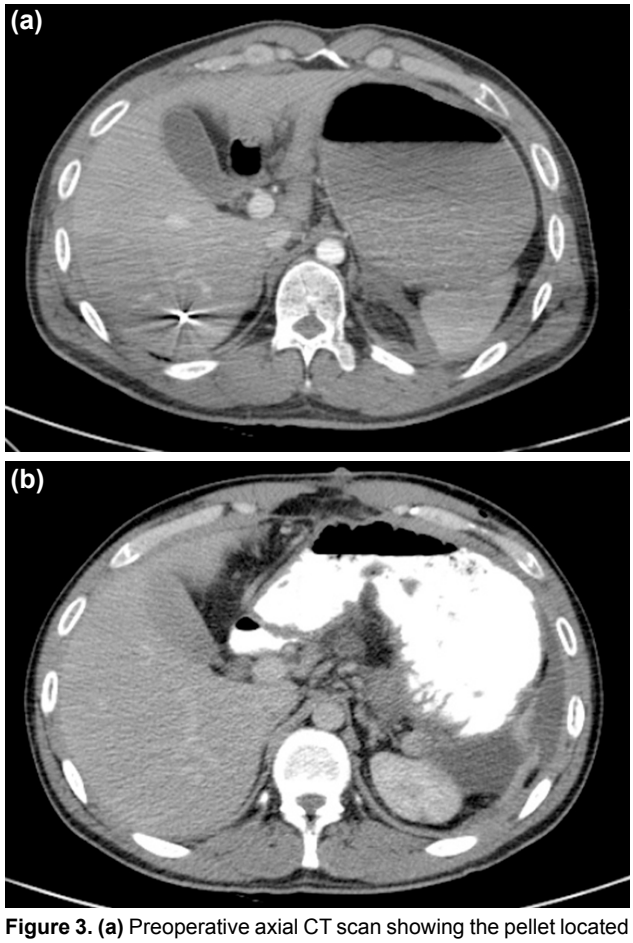

Figure 3. (a) Preoperative axial CT scan showing the pellet located in segment 6 of the liver. **(b)** The pellet in the liver could not be detected on postoperative day 10 axial CT scan.

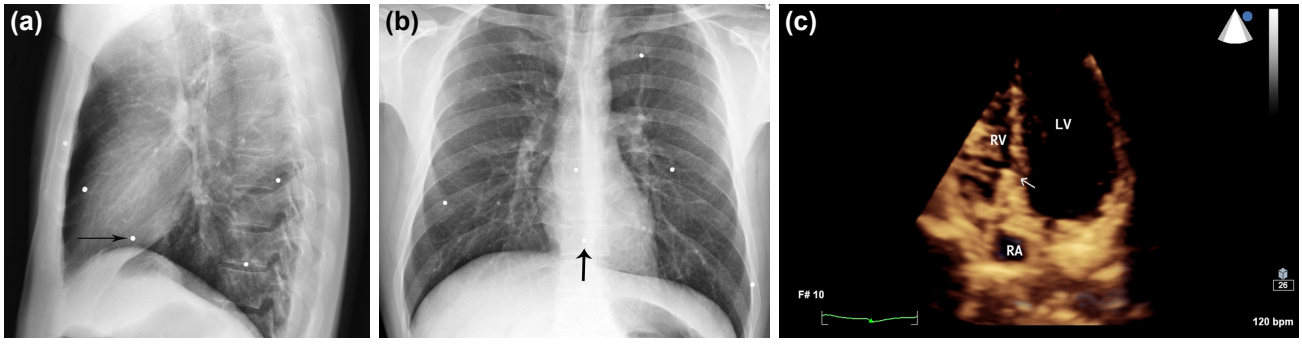

Figure 4. (a, b) Posteroanterior and lateral chest x-rays revealing the pellet (black arrows) in the silhouette of the heart, 6 weeks after discharge. **(c)** Echocardiograms at 6 months after discharge showing the pellet (white arrow) within the interventricular septum.

tiple attempts to remove the pellet with snare catheter failed because the foreign body was presumably embedded in the papillary muscles. Due to recurrent episodes of arrhythmia, the procedure was terminated. No further attempts were made, and conservative management was selected. Outpatient review with x-rays and echocardiograms at 6 weeks and 6 months following discharge demonstrated that the pellet remained within the interventricular septum (Fig. 4), presumably having become epithelialized.

DISCUSSION

Exact incidence of bullet embolism in non-military circumstances is unclear, but may be increased due to use of low-kinetic-energy weapons in civilian settings.[1] Upon impact, the penetrating foreign body either pierces or is retained by tissues following loss of kinetic energy. It can enter the vessel directly at the time of injury or gradually erode into the lumen via the pulsating movement of the vessel against the foreign body.[2] Bullet embolization can be arterial or venous, with most documented cases being arterial.[3] Arterial embolization typically originates from the large arteries, left ventricle, aorta, or pulmonary veins, and often embolizes to lower-extremity arteries.[4,5] Venous embolization frequently originates from the large peripheral veins or the vena cava, embolizing to the right side of the heart, particularly to the right ventricle or pulmonary arteries.[4,6] In the present case, the right hepatic vein was believed to be the source of the embolus, though hepatic veins are rarely reported as a source for venous emboli origin, with a frequency of 0.9% in the literature.[4] Migrating venous foreign bodies lodge in the right ventricle more often than in the pulmonary arterial tree, as they tend to be trapped beneath the tricuspid valve or chordae tendinae, eventually encapsulated with fibrous tissue.[4,7] Following encapsulation, the foreign body may remain silent, as in the present case, or result in valvular dysfunction or myocardial instability. Only one-third of venous embolizations become symptomatic, with symptoms most commonly including dyspnea, chest pain, and hemoptysis.[8]

Two rare venous embolization scenarios have been reported. The first is venous retrograde embolization, in which projectile movement contradicts normal venous blood flow, occurring in up to 15% of cases.[8,9] The second is paradoxical embolization, defined as the passage of a foreign body from the venous to the arterial vascular system through a right-to-left shunt. This shunt can occur in up to 10% of cases via patent foramen ovale ventricular septal defect, atrioventricular septal perforation, or arteriovenous fistula.[9,10] Although a paradoxical embolism originates from the venous system, it behaves as an arterial embolus. Bullet embolism should be suspected in any patient presenting with a gunshot entrance wound without exit wound, when signs and symptoms do not correlate with expected trajectory, and when radiographic location of a retained bullet changes during serial imaging.[7,11]

X-ray, CT, and echocardiography can be utilized in the investigation of suspected foreign body embolism. X-rays can demonstrate the extent of bullet spread throughout the injury site. Chest x-ray is particularly important in the evaluation of patients with cardiopulmonary symptoms, as well as in asymptomatic patients, such as the present. If this basic investigation raises doubts regarding bullet embolism, CT and echocardiography should be performed. Serial CT scanning can assist in the detection of the embolic source. Echocardiography is vital in locating the bullet and defining the extent of cardiac trauma, thus aiding in the selection of the appropriate therapeutic option.[2,12]

Advances in endovascular techniques and technology have increased use and success of bullet retrieval with a snare device since the method was first reported by Hartzler et al. in 1980.[7,13] However, conservative management may be suitable in cases of asymptomatic venous embolism and when endovascular retrieval has failed.[14] Conservative management requires regular follow-up, with special attention to possible indications of embolus complications.[15]

Surgical removal of a foreign body is recommended in complicated cases, such as those with recurrent embolism and intractable infection, as well as in symptomatic cases in which endovascular approach fails or is unavailable.[16,17] However, pulmonary bullet emboli can be conservatively followed in the absence of pulmonary infarction, pulmonary abscess, or erosion in the bronchial tree.[14] Removal of intracardiac foreign body embolism has been recommended in some cases

to avoid major venous obstruction, endocarditis, arrhythmia, valvular dysfunction, myocardial irritability, and delayed migration.[6,10] However, in recent years, conservative management of asymptomatic right-cardiac foreign body embolism has been favored by many authors.[2,15] Lundy et al. suggested that asymptomatic, firmly lodged, right-sided, smooth, <5 mm, or entirely intramyocardial emboli have a low risk, and that conservative management is suitable in these cases.[15]

Conclusion

Following penetrating gunshot injury, the possibility of pellet migration to distant sites via the vascular system must be kept in mind. Clinical suspicion and radiological imaging techniques can assist in accurate diagnosis, reducing incidence of morbidity and mortality. Following definitive diagnosis, endovascular treatment should be considered, if applicable. In asymptomatic patients, conservative management and close follow-up (with echocardiography and chest x-ray) may be suitable.

Conflict of interest: None declared.

REFERENCES

1. Nolan T, Phan H, Hardy AH, Khanna P, Dong P. Bullet embolization: multidisciplinary approach by interventional radiology and surgery. Semin Intervent Radiol 2012;29:192–6.
2. Hussein N, Rigby J, Abid Q. Bullet embolus to the right ventricle following shotgun wound to the leg. BMJ Case Rep 2012;2012.
3. Colquhoun IW, Jamieson MP, Pollock JC. Venous bullet embolism: a complication of airgun pellet injuries. Scott Med J 1991;36:16–7.
4. Springer J, Newman W, McGoey R. Intravascular bullet embolism to the right atrium. J Forensic Sci 2011;56 Suppl 1:S259–62.
5. Kurt N, Küçük HF, Celik G, Demirhan R, Celik G, Gül O, et al. Bullet embolism of the right external iliac artery following cardiac gunshot wound (a case report). Ulus Travma Derg 2001;7:131–3.
6. Patel KR, Cortes LE, Semel L, Sharma PV, Clauss RH. Bullet embolism. J Cardiovasc Surg (Torino) 1989;30:584–90.
7. Miller KR, Benns MV, Sciarretta JD, Harbrecht BG, Ross CB, Franklin GA, et al. The evolving management of venous bullet emboli: a case series and literature review. Injury 2011;42:441–6.
8. Schmelzer V, Mendez-Picon G, Gervin AS. Case report: transthoracic retrograde venous bullet embolization. J Trauma 1989;29:525–7.
9. Bining HJ, Artho GP, Vuong PD, Evans DC, Powell T. Venous bullet embolism to the right ventricle. Br J Radiol 2007;80:296–8.
10. Shannon FL, McCroskey BL, Moore EE, Moore FA. Venous bullet embolism: rationale for mandatory extraction. J Trauma 1987;27:1118–22.
11. Duncan IC, Fourie PA. Embolization of a bullet in the internal carotid artery. AJR Am J Roentgenol 2002;178:1572–3.
12. Soong W, Beckmann AK, Lin L, Ahmad US, McGee EC. Transesophageal echocardiography in the management of right ventricular bullet embolization from the left brachiocephalic vein. J Cardiothorac Vasc Anesth 2012;26:459–61.
13. Hartzler GO. Percutaneous transvenous removal of a bullet embolus to the right ventricle. J Thorac Cardiovasc Surg 1980;80:153–5.
14. Unkle D, Shaikh KA. Iliac vein to pulmonary artery missile embolus: case report and review of the literature. Heart Lung 1988;17:363–5.
15. Lundy JB, Johnson EK, Seery JM, Pham T, Frizzi JD, Chasen AB. Conservative management of retained cardiac missiles: case report and literature review. J Surg Educ 2009;66:228–35.
16. Grewal KS, Sintek CF, Jorgensen MB. Bullet embolism to the heart. Am Heart J 1997;133:468–70.
17. Kalimi R, Angus LD, Gerold T, DiGiacomo JC, Weltman D. Bullet embolization from the left internal iliac vein to the right ventricle. J Trauma 2002;52:772–4.

OLGU SUNUMU - *ÖZET*

Ateşli silah yaralanması sonrası saçma embolisi: Karaciğerden sağ ventriküle

Dr. Selim Bakan,[1] Dr. Bora Korkmazer,[1] Dr. Ahmet Baş,[1] Dr. Osman Şimşek,[2] Dr. Hasan Ali Barman,[3] Dr. Deniz Çebi Olgun[1]

[1]İstanbul Üniversitesi Cerrahpaşa Tıp Fakültesi, Radyoloji Anabilim Dalı, İstanbul
[2]İstanbul Üniversitesi Cerrahpaşa Tıp Fakültesi, Genel Cerrahi Anabilim Dalı, İstanbul
[3]İstanbul Üniversitesi Cerrahpaşa Tıp Fakültesi, Kardiyoloji Anabilim Dalı, İstanbul

Kardiyak saçma embolisi penetran travmalardan sonra görülen nadir ancak ciddi bir komplikasyondur. Ateşli silah yaralanması sonrası yabancı cisimlerin vasküler sistem aracılığı ile uzak migrasyonu dikkate alınmalıdır. Gecikmiş tanının sebep olabileceği yetersiz tedavi ve takip eden komplikasyonlar, kötü prognoz nedeni olabilir. Bu yazıda, konservatif olarak yaklaşılan semptomsuz kardiyak saçma embolisi olgusunu sunduk. Bu olgu sunumu penetran ateşli silah yaralanması sonrası saçma taneciğinin uzak migrasyon olasılığını ve semptomsuz hastalarda konservatif yaklaşımın önemini vurgulamaktadır.

Anahtar sözcükler: Ateşli silah; kalp; saçma embolisi.

Ulus Travma Acil Cerrahi Derg 2016;22(4):395–398 doi: 10.5505/tjtes.2015.32470