ORIGINAL ARTICLE

# What is the clinical yield of capsule endoscopy in the management of obscure bleeding in emergency service?

**Muhammed Zübeyr Üçüncü, M.D.,[1]* Süleyman Bademler, M.D.,[2] Mehmet İlhan, M.D.,[2] Ali Fuat Kaan Gök, M.D.,[2] Filiz Akyüz, M.D.,[3] Recep Güloğlu, M.D.[2]**

[1]Department of General Surgery, Arnavutköy State Hospital, İstanbul-*Turkey*
[2]Department of General Surgery, İstanbul Universty İstanbul Faculty of Medicine, İstanbul-*Turkey*
[3]Department of Gastroenterology, İstanbul Universty İstanbul Faculty of Medicine, İstanbul-*Turkey*

## ABSTRACT

**BACKGROUND:** The aim of this study was to investigate the efficacy of capsule endoscopy (CE) performed on patients who presented to emergency room with clinically evident gastrointestinal (GI) bleeding from unknown source and were hospitalized for follow-up.

**METHODS:** Total of 38 patients who underwent CE and were followed-up for evaluation of clinically perceptible GI bleeding with no obvious etiology in Istanbul Medical Faculty emergency surgery department were included in the study. Patient data, which were collected between January 1, 2007 and June 1, 2015, were reviewed retrospectively.

**RESULTS:** Of the 38 patients included in this study, 12 (32%) patients were women and 26 (68%) were men. Average age was 55.57 years (range: 20–88 years). Nine patients were using anticoagulants. Ten patients were followed-up in intensive care, and 7 patients underwent angiography. Angioembolization was performed for 1 patient who was diagnosed as having active bleed with CE. Average erythrocyte suspension replacement was 20.7 units. Total of 13 patients underwent surgery for bleeding found with CE. Eleven (34%) patients underwent double-balloon endoscopy, during which 5 patients were treated with cauterization and sclerotherapy was performed on 2. Four (18%) patients died during the study period: 2 died as result of bleeding from unknown source, 1 died of cholangiocarcinoma recurrence, and 1 died of anastomotic leakage. One patient was readmitted to hospital due to recurrence of bleeding. Nineteen (50%) patients were treated successfully based on CE findings. Diagnostic yield of CE was determined to be 78.9%. Average length of hospital stay was 32.68 days (range: 3–153 days).

**CONCLUSION:** CE is an effective tool to detect source of GI bleeding. CE should be first choice of evaluation method for patients admitted to emergency room with obscure overt GI bleeding once radiological imaging determines absence of obstruction.

**Keywords:** Capsule endoscopy; emergency service; obscure bleeding.

## INTRODUCTION

Gastrointestinal (GI) tract bleeding that persists or recurs with no obvious etiology represents approximately 5% of all cases of GI system bleeding.[1] These patients can be defined as those who have undergone at least 1 colonoscopy and gastroscopy, but source of continuous bleeding could not be detected.[2] Angiodysplasia has been detected as most frequent source of these GI bleeds.[3] GI bleeding without obvious etiology may be either occult or overt. Overt bleeding is defined as visible GI bleeding that generally presents as melena, or hematochezia. In contrast, occult bleeding is not visible to the patient or the physician. These bleeds may be associated with iron deficiency anemia and may manifest as positive fecal blood test.[4]

Debate continues on treatment of GI bleeding with no obvious etiology as result of difficulties in determining source. Capsule endoscopy (CE) is favored technique to evaluate these bleeds.[5–7] Several studies have shown high specificity and sensitivity of CE in setting of overt GI bleeding (OGIB) and reported that it has better diagnostic yield than other

**Current affiliation:* *İstanbul Gelişim University, Health Sciences Institute.*
**Address for correspondence:** Muhammed Zübeyr Üçüncü, M.D. Arnavutköy Devlet Hastanesi, Genel Cerrahi Kliniği, Arnavutköy, İstanbul, Turkey
Tel: +90 212 - 453 12 12 E-mail: muhammeducuncu@gmail.com

Qucik Response Code

Ulus Travma Acil Cerrahi Derg
2017;23(1):46–50
doi: 10.5505/tjtes.2016.79360

Copyright 2017
TJTES

endoscopic or radiological techniques. The aim of this study was to present our experience in evaluation of patients with OGIB using CE in emergency service.

## MATERIALS AND METHODS

Patients who were admitted to the Istanbul University Istanbul Faculty of Medicine emergency unit with symptoms of melena or hematochezia were included in the study if there was no evidence of obvious decline in hemoglobin or hematocrit in gastroscopic and colonoscopic examination, and if CE was performed. Patients were hemodynamically stable and had at least 2 units of erythrocyte replacement. Study cohort included patients who presented between January 1, 2007 and June 1, 2015. Informed written and oral consent were obtained from all patients included in the study. CE was performed after abdominal tomography with contrast agent in order to prevent capsule retention.

### CE Procedure

CE procedure was performed in outpatient clinic without hospitalization using Pillcam SB2 (Medtronic, Inc., Minneapolis, MN, USA). Bowel preparation was performed with 4 L polyethylene glycol solution 1 day before procedure. Patients swallowed Pillcam capsule in outpatient clinic and were not permitted to drink for 2 hours or eat for 4 hours. Patients were asked to verify ejection of capsule in stool and to alert endoscopy unit if it was not ejected.

Capsule retention was defined as presence of capsule in the GI tract 2 weeks after ingestion. One gastroenterologist (FA) with extensive experience in small bowel endoscopy evaluated recorded CE images.

### Statistical Analysis

Descriptive statistics were used to summarize patient demographic and clinical characteristics, endoscopic findings, and therapeutic procedures. Categorical variables were presented as percentages and numeric variables as means and ranges.

## RESULTS

Thirty-eight patients who were under follow-up to identify source of GI bleeding of unknown origin in the Istanbul University Istanbul Faculty of Medicine emergency surgery department and who were screened using CE were included in this study. Twelve patients (32%) were women and 26 (68%) were men. Average age was 55.57 years (range: 20–88 years). Nine patients were using anticoagulants. Ten were followed-up in intensive care, and 7 underwent angiography. Angioembolization was performed on 1 patient who was diagnosed with CE as having active bleed. Average erythrocyte suspension replacement was 20.7 units. Thirteen patients underwent surgery for bleeding found with CE. Tumor was detected in 8 of these patients. Double-balloon endoscopy was performed in 11 patients. Of these, sclerotherapy was performed on 2 patients and cauterization was used in 5 cases. According to CE findings, 19 patients were therapeutically treated (Figure 1). Four patients died: 2 patients died in hospital during conservative follow-up. One patient who was undergoing therapeutic treatment died of anastomotic leakage after bowel resection and anastomosis. One patient died as result of cholangiocarcinoma recurrence (Table 1).

Source of bleeding was detected in 35 patients based on CE

**Table 1.** Comparison of the therapeutically treated patients with the conservatively followed ones

| | Conservative treatment | Therapeutic treatment |
|---|---|---|
| Sex (Male/Female) | 19 (15/4) | 19 (11/8) |
| Average age | 56.94 | 54.2 |
| RBC replacement | 11.7 | 29.6 |
| Additional illness | 10 | 11 |
| Avarage hospitalisation | 17.1 | 48.2 |
| Mortality | 2 | 2 |
| Anticoagulant users | 5 | 3 |
| Patients stayed in ICU | 1 | 9 |

RBC: Red blood cell; ICU: Intensive care unit.

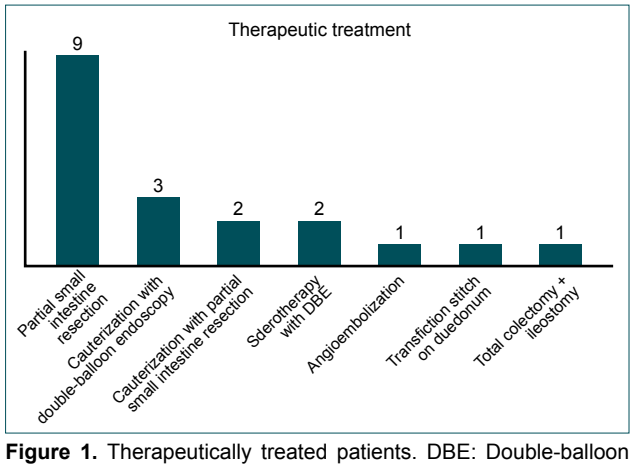


**Figure 1.** Therapeutically treated patients. DBE: Double-balloon endoscopy.

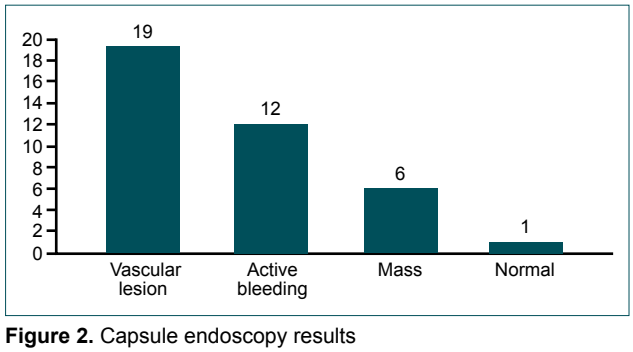


**Figure 2.** Capsule endoscopy results

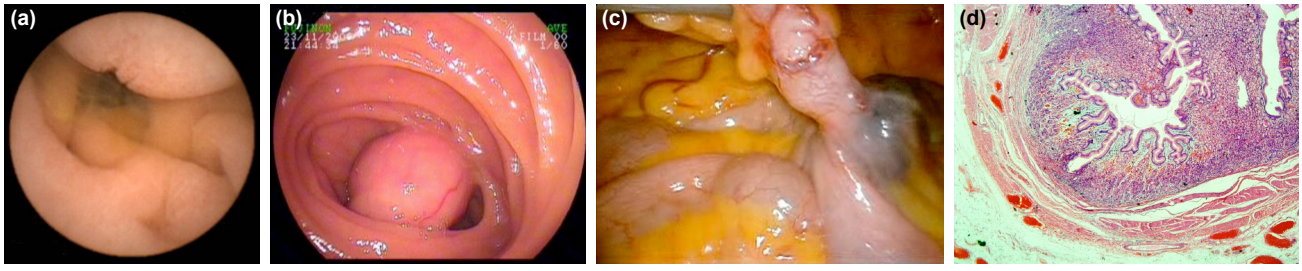


**Figure 3. (a)** Capsul endoscopy image. **(b)** Double baloon image. **(c)** 36 age man patient photos. **(d)** Pathologically image.

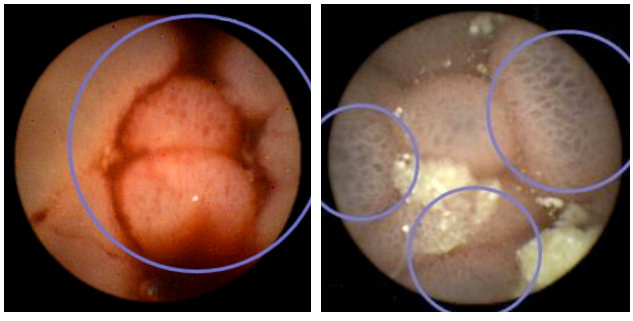

**Figure 4. (a)** Active bleeding. **(b)** Vascular lesion.

results. Source of GI bleeding was not determined based on CE evaluation in 2 patients, and CE evaluation was normal in remaining patient. Diagnostic yield was 78.9% in the present study. Capsule retention occurred in 3 patients due to small bowel adenocarcinoma and in 1 patient due to lipoma. One patient was readmitted to hospital due to multiple angiodysplasia of the small intestine. Average length of hospital stay was 32.68 days (range: 3–153 days) CE results were grouped in 4 categories: 1) active bleeding, 2) vascular lesions (angiodysplasia, erosion, ulcers, vascular ectasia), 3) mass (bulk), and 4) normal findings (Figure 2–4).

Seventeen patients from conservatively managed group were not readmitted to hospital for any GI bleeding symptoms.

## DISCUSSION

According to the American Gastroenterology journal guidelines issued in 2015, bleeding from small intestine was categorized into 2 main groups. If no specific source of bleeding could be identified after thorough examination, bleeding was referred to as obscure. However, overt and occult GI bleeding refers to known source, even if etiology is not initially obvious. Performance of CE has had great impact on correct categorization of suspected cases of GI bleeding. In study conducted by Pennazio et al., diagnostic value of CE in patients with occult bleeding was 92.3%, and it was 44% for overt bleeding.[8] According to some published literature, this rate may decrease to 45.7%. This may be due to length of time between bleeding occurrence and CE. Bresci et al. revealed inverse relationship between timing of CE and bleeding. The authors found higher diagnostic value in patients who underwent earlier CE.[9] It has been proposed in international consensus meetings that earliest CE performance should be within the first 2 weeks of symptom observation.

Age is a factor that improves diagnostic efficiency in determining etiological source of GI bleeding. Scaglione et al. reported that diagnostic value under the age of 65 years was 45% while ratio goes up to 75% for patients aged over 65 years.[10]

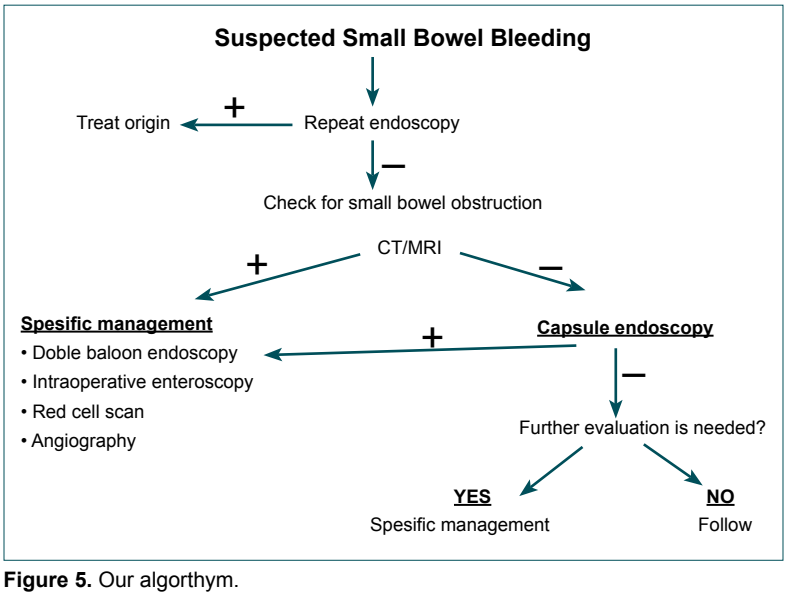


**Figure 5.** Our algorthym.

Different methods have been used to identify source of bleeding, such as double-balloon endoscopy, angiography, and radionuclide imaging. In addition to drawbacks of these methods, including invasiveness, sedation requirement, and radiation involvement, diagnostic value has been found to be lower when compared with CE. Angiography can detect source of bleeding with intra-arterial contrast agent, but only when intensity of bleeding is at least 0.5 mL/min.[11]

Advantage of angiography is that intervention can be performed in the same session if bleeding is detected. However, it does not give us any information about nature of the lesion. Although radionuclide scanning is superior to angiography in terms of being non-invasive method and providing information about active bleeding (0.1–0.4 mL/min), no bleeding intervention can be performed with this method. Double-balloon endoscopy requires significant experience, sedation of the patient, and has lower diagnostic yield compared with CE. Kameda et al. examined diagnostic yield of double-balloon endoscopy (65%) and CE (71%). Although Lin et al. supported Kamada, diagnostic yield of double-balloon endoscopy was found to be higher than that of CE in a study conducted by Arakawa et al.[12,13] In conclusion, CE is superior method because it is non-invasive, does not require sedation or radiation, and provides better diagnostic value. Although CE offers advantages over other methods, it also has drawbacks, such as inability to perform biopsy or therapeutic intervention, and there is risk for capsule retention. Although tomography performed prior to CE would seem to be solution in terms of preventing capsule retention, it should be noted that it is also possible that battery life may expire before capsule reaches the cecum in patients with no evidence of obstruction. Furthermore, experienced physician is needed to recognize lesions seen with CE. In our study, retention was detected in 4 patients due to presence of mass.

Intraoperative enteroscopy has been proposed as alternative method and should be preferred for evaluation in unstable situation.[14] Guidelines have begun to emerge with widespread use of CE in patients with GI bleeds and no obvious etiology. Guidelines developed by Gerson et al. are presented here as an example.[8–18] Our algorithm is shown in Figure 5.

In the present study, after gastroscopy and colonoscopy, tomography was performed on patients with GI bleeding to determine presence of any obstruction before CE. Appropriate treatment for each patient was based on CE results. Diagnostic yield was found to be 78.9%, which is consistent with the literature.[19]

Main limitations of this study include its retrospective nature and the inability to perform CE in large population due to cost to patients. Thus, patient standardization and comparison could not be made.

## Conclusion

CE should be selected as first-line diagnostic evaluation method for patients without evidence of obstruction in tomography results who have clinically perceptible GI bleeding that recurs or persists after negative upper and lower GI tract endoscopic examination.

Conflict of interest: None declared.

## REFERENCES


1. Katz LB. The role of surgery in occult gastrointestinal bleeding. Semin Gastrointest Dis 1999;10:78–81.
2. American Gastroenterological Association medical position statement: evaluation and management of occult and obscure gastrointestinal bleeding. Gastroenterology 2000;118:197–201.
3. Foutch PG. Angiodysplasia of the gastrointestinal tract. Am J Gastroenterol 1993;88:807–18.
4. American society for gastrointestinal endoscopy. Gastrointestınal endoscopy 2003;58:5.
5. Scapa E, Jacob H, Lewkowicz S, Migdal M, Gat D, Gluckhovski A, et al. Initial experience of wireless-capsule endoscopy for evaluating occult gastrointestinal bleeding and suspected small bowel pathology. Am J Gastroenterol 2002;97:2776–9.
6. Iddan G, Meron G, Glukhovsky A, Swain P. Wireless capsule endoscopy. Nature 2000;25:405–417.
7. Swain P, Fritscher-Ravens A. Role of video endoscopy in managing small bowel disease. Gut 2004;53:1866–75.
8. Pennazio M, Santucci R, Rondonotti E, Abbiati C, Beccari G, Rossini FP, et al. Outcome of patients with obscure gastrointestinal bleeding after capsule endoscopy: report of 100 consecutive cases. Gastroenterology 2004;126:643–53.
9. Bresci G, Parisi G, Bertoni M, Tumino E, Capria A. The role of video capsule endoscopy for evaluating obscure gastrointestinal bleeding: usefulness of early use. J Gastroenterol 2005;40:256–9.
10. Scaglione G, Russo F, Franco MR, Sarracco P, Pietrini L, Sorrentini I. Age and video capsule endoscopy in obscure gastrointestinal bleeding: a prospective study on hospitalized patients. Dig Dis Sci 2011;56:1188–93.
11. Singh V, Alexander JA. The evaluation and management of obscure and occult gastrointestinal bleeding. Abdom Imaging 2009;34:311–9.
12. Lin TN, Su MY, Hsu CM, Lin WP, Chiu CT, Chen PC. Combined use of capsule endoscopy and double-balloon enteroscopy in patients with obscure gastrointestinal bleeding. Chang Gung Med J 2008;31:450–6.
13. Arakawa D, Ohmiya N, Nakamura M, Honda W, Shirai O, Itoh A, et al. Outcome after enteroscopy for patients with obscure GI bleeding: diagnostic comparison between double-balloon endoscopy and videocapsule endoscopy. Gastrointest Endosc 2009;69:866–74.
14. Gerson LB, Fidler JL, Cave DR, Leigthon JA. ACG Clinical guidelines: Diagnosis and management of small bowell bleeding. The American journal of Gastroenterology 2015.
15. Gupta R, Reddy DN. Capsule endoscopy: current status in obscure gastrointestinal bleeding. World J Gastroenterol 2007;13:4551–3.
16. Kameda N, Higuchi K, Shiba M, Machida H, Okazaki H, Yamagami H, et al. A prospective, single-blind trial comparing wireless capsule endoscopy and double-balloon enteroscopy in patients with obscure gastrointestinal bleeding. J Gastroenterol 2008;43:434–40.
17. Lecleire S, Iwanicki-Caron I, Di-Fiore A, Elie C, Alhameedi R, Ramirez

S, et al. Yield and impact of emergency capsule enteroscopy in severe obscure-overt gastrointestinal bleeding. Endoscopy 2012;44:337–42.

18. Heo HM, Park CH, Lim JS, Lee JH, Kim BK, Cheon JH, et al. The role of capsule endoscopy after negative CT enterography in patients with obscure gastrointestinal bleeding. Eur Radiol 2012;22:1159–66.
19. Calabrese C, Liguori G, Gionchetti P, Rizzello F, Laureti S, Di Simone MP, et al. Obscure gastrointestinal bleeding: single centre experience of capsule endoscopy. Intern Emerg Med 2013;8:681–7.

ORİJİNAL ÇALIŞMA - *ÖZET*

## Nedeni bilinmeyen gastrointestinal sistem kanamalarda kapsül endoskopisinin acil servisteki yeri?

**Dr. Muhammed Zübeyr Üçüncü,[1] Dr. Süleyman Bademler,[2] Dr. Mehmet İlhan,[2] Dr. Ali Fuat Kaan Gök,[2] Dr. Filiz Akyüz,[3] Dr. Recep Güloğlu[2]**

[1]Arnavutköy Devlet Hastanesi, Genel Cerrahi Kliniği, İstanbul
[2]İstanbul Üniversitesi İstanbul Tıp Fakültesi, Genel Cerrahi Anabilim Dalı, İstanbul
[3]İstanbul Üniversitesi İstanbul Tıp Fakültesi, Gastroenteroloji Bilim Dalı, İstanbul

AMAÇ: Bu çalışmanın amacı acilde nedeni bilinmeyen gastrointestinal (GİS) kanama tanısı ile yatırılarak takip edilen hastalarda kapsül endoskopisinin yerini irdelemek.
GEREÇ VE YÖNTEM: İstanbul Üniversitesi İstanbul Tıp Fakültesi Acil Cerrahi biriminde 1 Ocak 2007 ile 1 Haziran 2015 tarihleri arasında nedeni bilinmeyen aşikar GİS kanama tanısı ile takip edilen ve kapsül endoskopisi yaptığımız 38 hastanın verileri geriye dönük olarak incelendi.
BULGULAR: İstanbul Üniversitesi İstanbul Tıp Fakültesi Acil Cerrahi'de nedeni bilinmeyen GİS kanama tanısıyla takip edilen ve kapsül endoskopisi yapılabilen 38 hasta çalışmaya dahil edildi. On iki hasta kadın (%32) 26 hasta erkekti (%68). Ortalama yaş: 55.57 (20–88) idi. Dokuz hasta kan sulandırıcı ilaç kullanıyordu. 10 hasta yoğun bakımda takip edildi. Yedi hastaya anjiyo yapıldı aktif kanama saptanmadı. Kapsül endoskopisinde aktif kanama saptanan bir hastaya anjiyoembolizasyon yapıldı. Ortalama eritrosit süspansiyon replasmanı 20.7 ünite idi. On üç hasta kapsül endoskopisinde bulunan kanama odakları nedeniyle ameliyat edildi (%34). On bir hastaya çift balon endoskopisi yapıldı. Bunlardan beşine koterizasyon ikisine skleroterapi yapılarak müdahale edildi (%18). Dört hasta hayatını kaybetti. İki olgu kanama odağı saptanamadığı için bir olgu kolanjiyokarsinom nüksü nedeniyle bir olguda anastomoz kaçağı nedeniyle hayatını kaybetti. Bir olgu tekrar kanama nedeniyle hastaneye başvurdu. On dokuz hastaya kapsül endoskopisi bulgularına dayanılarak başarılı şekilde müdahale edildi (%50). Tanısal değer %78.9 olarak saptandı. Hastanede ortalama kalış süresi 32.68 (dağılım, 3–153 gün) idi.
TARTIŞMA: Kapsül endoskopisi kanama etiyolojisini saptamada etkindir. Acile başvuran hastalarda nedeni bilinmeyen kanamalarda radyolojik olarak obstrüksiyon bulunmayan olgularda ilk tercih edilecek yöntem kapsül endoskopi olmalıdır.

Anahtar sözcükler: Acil servis; gizli kanama; kapsül endoskopi.

Ulus Travma Acil Cerrahi Derg 2017;23(1):46–50 doi: 10.5505/tjtes.2016.79360