CASE REPORT

Acute arterial occlusion due to vascular closure device: A report of two cases

Süleyman Utku Çelik, M.D., Ömer Arda Çetinkaya, M.D., Can Konca, M.D., Mehmet Ali Koç, M.D., Elvan Onur Kırımker, M.D., Akın Fırat Kocaay, M.D., İskender Alaçayır, M.D.

Department of General Surgery, Ankara University Faculty of Medicine, Ankara-*Turkey*

ABSTRACT

Vascular closure devices are frequently used after percutaneous arterial interventions to achieve hemostasis at the puncture site and facilitate early ambulation. Occasionally, complications have been reported with closure devices, such as hematoma, infection, arteriovenous fistula, pseudoaneurysm, and ischemia. This is a report of 2 cases of severe, acute-onset arterial occlusion and critical limb ischemia, one of which occurred in the upper limb following the use of a vascular closure device, and the required surgical treatment.

Keywords: Arterial catheterization; arterial occlusive disease; complication; vascular closure devices.

INTRODUCTION

Vascular closure devices (VCDs) were specifically designed to provide faster hemostasis following arteriotomy. One of these devices, the Angio-Seal vascular closure device (St. Jude Medical, Inc., St. Paul, MN, USA), consists of a polymer anchor, a small bovine collagen sponge, and a traction suture; all components of the device are absorbed within 60 to 90 days.[1,2] The device seals and compresses the arterial wall between the anchor and the collagen sponge.[3]

VCDs have many advantages, such as immediate hemostasis, and early ambulation and hospital discharge.[1,4] However, in terms of minor or major vascular complications, it is still controversial as to whether VCDs are more efficient than manual compression (MC).[4,5] VCD-related complications have been reported, including access site infection and acute arterial occlusion that may require extra-surgical intervention.[2,3] Herein, 2 cases of limb-threatening ischemic complications following the use of Angio-Seal vascular closure device are reported.

CASE REPORT

Case 1 – A 55-year-old woman experienced severe pain, pulselessness, and pallor in the right leg immediately after digital subtraction angiography to assess a coiled middle cerebral artery bifurcation aneurysm via femoral access that was closed with an Angio-Seal vascular closure device (St. Jude Medical, Inc., St. Paul, MN, USA). An hour after the procedure, there were no audible Doppler signals at the right ankle and aorto-ilio-femoral angiography demonstrated a thrombus in the distal right popliteal artery (Fig. 1a,b). After informed consent was obtained, the entire closure device, collagen sponge, and suture tail were located at the puncture site anterior to the common femoral artery and extracted from the lumen. A thrombectomy was performed (Fig. 1c), the patient was monitored in the intensive care unit, and later discharged from the hospital without any complication. At 1-month follow-up, the patient had no claudication or complaints.

Case 2 – A 60-year-old man with a history of aorto-bifemoral bypass graft and endovascular stenting for superior mesenteric

Cite this article as: Çelik SU, Çetinkaya ÖA, Konca C, Koç MA, Kırımker EO, Kocaay AF, et al. Acute arterial occlusion due to vascular closure device: A report of two cases. Ulus Travma Acil Cerrahi Derg 2018;24:181–183

Address for correspondence: Süleyman Utku Çelik, M.D.
Ankara Üniversitesi Tıp Fakültesi, İbn-i Sina Hastanesi, Sıhhiye, 06100 Ankara, Turkey
Tel: +90 312 - 508 33 33 E-mail: s.utkucelik@hotmail.com

Ulus Travma Acil Cerrahi Derg 2018;24(2):181–183 DOI: 10.5505/tjtes.2017.10705 Submitted: 18.11.2017 Accepted: 21.12.2017 Online: 23.02.2018
Copyright 2018 Turkish Association of Trauma and Emergency Surgery

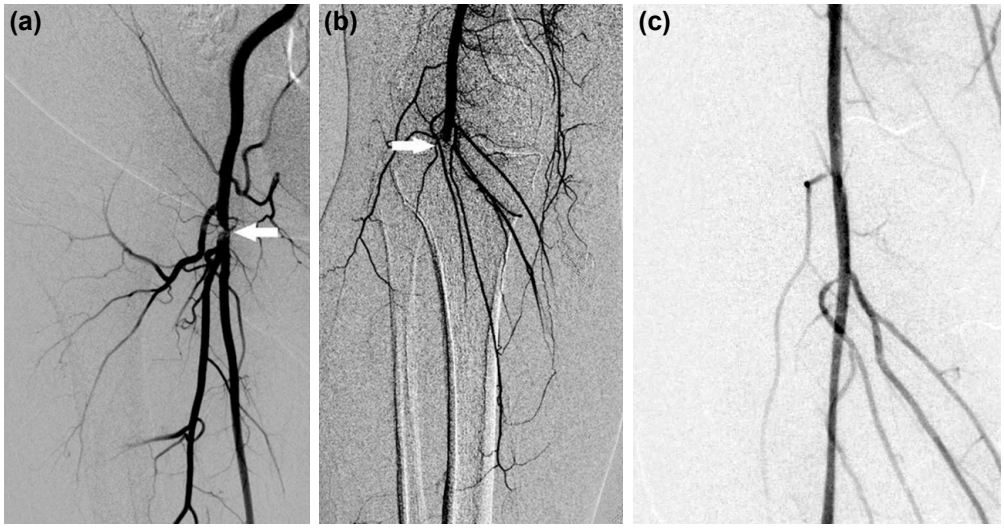

Figure 1. (a) Femoral angiography revealing stenosis in the right common femoral artery caused by the vascular closure device (arrow). **(b)** Angiogram illustrating an occluded right popliteal artery (arrow). **(c)** Final angiography demonstrating patency of the popliteal artery after balloon embolectomy.

artery (SMA) occlusion was admitted with severe abdominal pain after eating. The patient underwent digital subtraction angiography to assess the SMA via a left axillary artery approach. An Angio-Seal vascular closure device was used for arterial closure. After the procedure, the patient developed sudden severe pain, pulselessness, pallor, and coolness in the left arm. Immediate arterial duplex scanning revealed an occlusion of the left axillary artery. After obtaining informed consent, an embolectomy was performed and the closure device was removed from the distal brachial artery with the collagen sponge and suture tail (Fig. 2). The patient was discharged on postoperative day 2 without symptoms of claudication.

DISCUSSION

VCDs were developed in the early 1990s as a faster means to close arterial puncture areas than MC.[1,2,5,6] Though recent meta-analyses have failed to demonstrate the clear superiority of VCDs to MC, their use in clinical practice is widely accepted, despite an increase in device-related complications.[4,5,7]

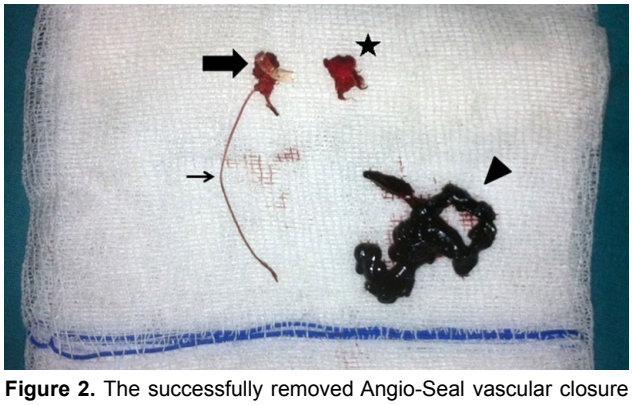

Figure 2. The successfully removed Angio-Seal vascular closure device, which consists of a polymer anchor (thick arrow), a traction suture (thin arrow), and a small collagen sponge (star), and the thrombus material (arrowhead).

MC requires an educated medical staff, manpower, prolonged bed rest, and long-time pressure on the puncture area.[1–3,7] To overcome these disadvantages of compression, an alternative was found: closure devices. VCDs offer many advantages, such as immediate hemostasis, successful use in patients who are highly anticoagulated, and early ambulation and hospital discharge.[1,4] On the other hand, these devices may lead to some complications, including hematoma, acute limb ischemia, and infection, which occur in up to 2.5% of patients.[5,8] Nikolsky et al.[5] described in a meta-analysis that the risk of major or minor vascular complications was similar to that of MC. In another study of 7376 patients in whom the Angio-Seal VCD was applied, device-related symptomatic lower limb ischemia was found in 14 cases (0.2%).[9] The cause of these iatrogenic complications was not clear, but they may have been related to malpositioning of the device, intimal dissection, or significant atherosclerosis at the puncture site.[2,3]

The risk factors for limb-threatening ischemic complications following the use of a vascular closure device are diabetes, obesity, peripheral vascular disease with arterial wall calcification, and severe ischemic heart disease.[8,11] Complication rates can be higher in women than in men due to the smaller arteries found in women.[11]

There is no consensus on the treatment strategy for patients with ischemic complications. Device-related complications can be treated with interventional therapy, including balloon angioplasty, stent grafting, extraction with a snare catheter, and arterectomy. Repetitive surgical approaches may be unavoidable if an acute ischemic complication is present.[10] In Case 1, the device-related complication seems to have been related to distal embolization originating around the polymer anchor in a stenotic length of artery with or without an arterial wall lesion (Fig. 1a). In Case 2, which occurred in the upper limb, intra-arterial deployment of the anchor led

to displacement of the collagen plug in the small arterial lumen. When treating device-related complications, the special structure of the VCD should be kept in mind and therapeutic options must be reviewed.

Conclusion

The use of closure devices to provide immediate hemostasis in patients undergoing interventional procedures may enhance patient comfort and facilitate early ambulation; nevertheless, they can also result in significant life and limb-threatening ischemic complications. Thus, cardiologists, interventional radiologists, and vascular surgeons should be aware of rare, but serious, complications. The use of routine duplex scanning after the interventional procedure may be beneficial, especially in patients with comorbidities, such as diabetes, obesity, peripheral vascular disease, and severe ischemic heart disease. Moreover, careful assessment of the arterial wall structure before the use of VCDs may also play a pivotal role in avoiding complications.

Finally, and most importantly, close observation of patients following the use of a VCD is important and highly recommended in order not to overlook any acute complications, especially limb ischemia.

Conflict of interest: None declared.

REFERENCES

1. Modi S, Gadvi R, Babu S. Initial experience with Angioseal™: Safety and efficacy of the endovascular closure device. Indian J Radiol Imaging 2013;23:134–8.
2. Mattens E. Acute claudication caused by Angio-Seal closure devices: a report of four cases. Acta Chir Belg 2008;108:247–50.
3. van der Steeg HJ, Berger P, Krasznai AG, Pietura R, Schultze Kool LJ, van der Vliet JA. Acute arterial occlusion after deployment of the Angio-Seal closure device: is it as uncommon as we think? Eur J Vasc Endovasc Surg 2009;38:715–7.
4. Robertson L, Andras A, Colgan F, Jackson R. Vascular closure devices for femoral arterial puncture site haemostasis. Cochrane Database Syst Rev 2016;3:CD009541.
5. Nikolsky E, Mehran R, Halkin A, Aymong ED, Mintz GS, Lasic Z, et al. Vascular complications associated with arteriotomy closure devices in patients undergoing percutaneous coronary procedures: a meta-analysis. J Am Coll Cardiol 2004;44:1200–9.
6. Cianci C, Kowal RC, Feghali G, Hohmann S, Stoler RC, Choi JW. Critical lower limb ischemia from an embolized Angio-Seal closure device. Proc (Bayl Univ Med Cent) 2013;26:398–400.
7. Koreny M, Riedmüller E, Nikfardjam M, Siostrzonek P, Müllner M. Arterial puncture closing devices compared with standard manual compression after cardiac catheterization: systematic review and meta-analysis. JAMA 2004;291:350–7.
8. Siani A, Accrocca F, Gabrielli R, Antonelli R, Giordano AG, Ambrogi C, et al. Management of acute lower limb ischemia associated with the Angio-Seal arterial puncture closing device. Interact Cardiovasc Thorac Surg 2011;12:400–3.
9. Thalhammer C, Aschwanden M, Jeanneret C, Labs KH, Jäger KA. Symptomatic vascular complications after vascular closure device use following diagnostic and interventional catheterisation. Vasa 2004;33:78–81.
10. Bito Y, Sakaki M, Inoue K, Yoshioka Y, Mizoguchi H. Surgical treatment of complications associated with the angio-seal vascular closure device: report of three cases. Ann Vasc Dis 2010;3:144–7.
11. Dregelid E, Jensen G, Daryapeyma A. Complications associated with the Angio-Seal arterial puncture closing device: intra-arterial deployment and occlusion by dissected plaque. J Vasc Surg 2006;44:1357–9.

OLGU SUNUMU - *ÖZET*

Vasküler kapatma cihazına bağlı gelişen akut arter tıkanıklığı: İki olgu sunumu

Dr. Süleyman Utku Çelik, Dr. Ömer Arda Çetinkaya, Dr. Can Konca, Dr. Mehmet Ali Koç, Dr. Elvan Onur Kırımker, Dr. Akın Fırat Kocaay, Dr. İskender Alaçayır

Ankara Üniversitesi Tıp Fakültesi, Genel Cerrahi Anabilim Dalı, Ankara

Vasküler kapatma cihazı, endovasküler girişimsel işlemler sonrasında hemostazı sağlamak amacıyla sıklıkla kullanılmaktadır. Bu cihazlar, ponksiyon yerinde hızlı bir hemostaz sağlamasının yanı sıra, hastanın erken mobilizasyonuna ve kliniğin iş yükünün azalmasına da olanak sağlamaktadır. Ancak nadir de olsa işleme bağlı komplikasyonlar bildirilmiştir. Bu yazıda, vasküler kapatma cihazı kullanımı sonrasında ani başlayan ve cerrahi girişim gerektiren iki akut arter tıkanıklığı olgusu paylaşıldı.

Anahtar sözcükler: Arteryel kateterizasyon; arteriyel oklüzif hastalıklar; komplikasyon; vasküler kapatma cihazları.

Ulus Travma Acil Cerrahi Derg 2018;24(2):181-183 doi: 10.5505/tjtes.2017.10705