SCIE DOI: 10.14744/scie.2019.15238
South. Clin. Ist. Euras. 2019;30(3):255-260

Original Article

Contribution of Color Doppler Sonography to the Diagnosis of Prostatic Pathologies

Özgür Sarıca, Sabahat Nacar Doğan

Department of Radiology, Taksim Training and Research Hospital, İstanbul, Turkey

Submitted: 08.11.2018
Accepted: 04.02.2019

Correspondence: Özgür Sarıca, Taksim Eğitim ve Araştırma Hastanesi Radyoloji Kliniği, İstanbul, Turkey
E-mail: sozgur@yahoo.com

Keywords: Color Doppler ultrasonography; prostate cancer; prostate pathologies; PSA; transrectal ultrasonography.

This work is licensed under a Creative Commons Attribution-NonCommercial 4.0 International License.

ABSTRACT

Objective: The aim of this study was to investigate the ability of color Doppler ultrasonography to determine prostate cancer, to evaluate the contribution of color Doppler ultrasonography to a conventional greyscale transrectal ultrasonography (TRUS) examination, and to assess the efficacy of prostate-specific antigen (PSA) values in the detection of prostate cancer in combination with sonographic imaging methods.

Methods: A total of 78 patients who presented at the Radiology Department of Taksim Training and Research Hospital and were diagnosed with benign prostate hyperplasia or prostate cancer were included in the study. The age range of the patients was 49 to 90 years. A Diasonic VST Master color Doppler ultrasonography system with a 7-Mhz transrectal probe (Diasonic Technology Co. Ltd., Gyeonggi-do, South Korea) was used to assess the patients. The presence and number of nodules; the size, shape, and echo structure of the lesion; the loss of peripheral zone and inner gland border; capsular invasion; seminal vesicle thickening; and obliteration or patency of the prostate seminal vesicle angle as observed in the TRUS examination were noted. A vascularization map of different regions of the prostate gland was evaluated by section. The color flow was graded using a 3-point scale and the findings were compared with the pathology results.

Results: Based on the results of a histopathological examination, 28 cases (36%) were malignant and the remaining 50 cases (64%) were benign. The mean PSA density (PSAD) value was 0.41 in the malignant cases and 0.23 in the benign cases. The best results for the diagnosis of prostate cancer were obtained with the combined use of TRUS, color Doppler ultrasound, and PSAD. The sensitivity, specificity, positive, and negative predictive value was 64%, 80%, 64%, and 80%, respectively.

Conclusion: The addition of color Doppler ultrasound to TRUS increased the specificity and decreased the sensitivity (from 78% to 51%) of the findings. Though RDUS does not provide a significant advantage in the diagnosis of cancer, the color flow grading better determines the areas to be biopsied. Due to the poor sensitivity of a color Doppler examination, it should be evaluated with grayscale and PSA findings. The best specificity (80%) was observed with the combined use of these 3 methods.

INTRODUCTION

Prostate cancer is the most common carcinoma in males.[1] The incidence of prostate cancer which is graded according to age was calculated to be 35/100000 in Turkey.[2] As the age increases, the incidence of prostate cancer increases. Therefore, diagnosing prostate cancer and distinguishing it from benign pathologies of the prostate constitute a very important clinical problem.

One of the important steps in the early diagnosis and treatment of prostate cancer is the measurement of prostate specific antigen (PSA) in serum.[3,4] With the development of defining the disease which is only localized in the prostate gland, curative treatments such as radical prostatectomy and radiotherapy have become possible. Early diagnosis of prostate cancer is also the main purpose of prostatic imaging.

Although the European Urological Association has accepted multiparametric prostate magnetic resonance imaging (MRI) with endorectal coil as the reference method for local staging of prostate cancer, gray scale transrectal ultrasonographic (TRUS) examination with its well-known proven diagnostic value is still considered as a valuable tool.[5] New developments in sonographic technique and many new studies in the literature point to the continuous and dynamic development of this method. With the use of high frequency transducers, new advances have been made in the TRUS examination of

prostate cancer. Tissue harmonic imaging, color doppler, power Doppler examinations are well known examples of these developments.

The classical appearance of prostate cancer in TRUS examination is a hypoechoic lesion located in the peripheral zone of the prostate gland. Unfortunately, this finding has low sensitivity and specificity in cancer detection. While only 50% of the hypoechoic areas observed in the peripheral zone of the prostate gland are diagnosed as prostate cancer,[6] 30% of the cancers have been reported to be isoechoic in TRUS.[7] Low positive predictive value of TRUS in the diagnosis of malignant lesions weakens the power of this technique. This makes the biopsy necessary in all peripheral zone lesions.[8,9] Therefore, the methods to increase the positive predictive value of TRUS are being investigated in order to reduce the cost and morbidity and prevent unnecessary biopsy.

The aim of our study was to investigate the ability of Color Doppler Ultrasound (CDU) in detecting cancer, the contribution of CDU to the TRUS imaging and to evaluate the efficacy of using PSA values together with sonographic imaging methods in detecting prostate cancer.

MATERIALS AND METHODS

The study was performed retrospectively on 78 patients aged between 49–90 years (mean 65.3 years) with a prediagnosis of benign prostate hyperplasia or prostate cancer.

Patients with suspected hypoechogenic lesions on TRUS examination, nodular palpation finding on rectal examination or high PSA (>4 ng/mL) were included in the study. Patients with a diagnosis of prostate cancer who had previously received radiotherapy, surgery, chemotherapy or hormonal therapy, and those with clinically significant cardiovascular disease were excluded from the study.

Diasonic VST master color doppler USG instrument and 7 Mhz transrectal probe were used in the study. B mode ultrasonography (USG) was carefully performed on axial and sagittal planes. In TRUS imaging, the presence and number of the nodules, size, shape, echo structure of the lesion, affected zone, non-mass echo difference in the peripheral zone, loss of peripheral zone and inner gland boundary, capsular invasion, seminal vesicle thickening, prostate seminal vesicle angle obliteration were noted.

The vascularization map was evaluated in sections passing through different areas of the gland. The color flow was graded with a 3-point scale. The findings were compared with the pathology results. CDU examination was performed on the foci which had pathologies in TRUS. In cases without pathology, CDU examination was performed carefully to evaluate diffuse abnormal gland vascularization. The CDU severity of both focal and generalized pathologies were evaluated according to the 0–3 scale as described in the previous publications.[10]

Color Doppler flow rating:

Grade 0 Normal flow (capsular/periurethral) flow

Grade 1 Color doppler signal that can hardly be monitored in the prostate parenchyma

Grade 2 Color doppler signal that can be easily monitored in a limited area of the prostate parenchyma

Grade 3 Diffuse and strong color doppler signal in prostate parenchyma

Grade 0 and 1 were accepted as CDU negative and grade 2 and 3 CDU were accepted as positive (Figs. 1 and 2).

After B mode and color doppler examination of the prostate gland, the preparation for biopsy was started. After informed consent was obtained, all patients underwent TRUS-guided and systematic biopsies using an 18 gauge (G) tru-cut biopsy set without anesthesia or sedation. Right before the procedure, a single dose of intramuscular (IM) gentamicin was administered for 80 mg and oral ciprofloxacin (2x500 mg) was given for the following 3 days for prophylaxis. One day before the procedure, the fibrous foods were restricted and the rectal cleansing was performed in the morning of the procedure with laxative applied rectally. During the biopsy, it was bewared that a small amount of urine remained in the bladder to limit the cranio-caudal movement of the prostate. Following the le-

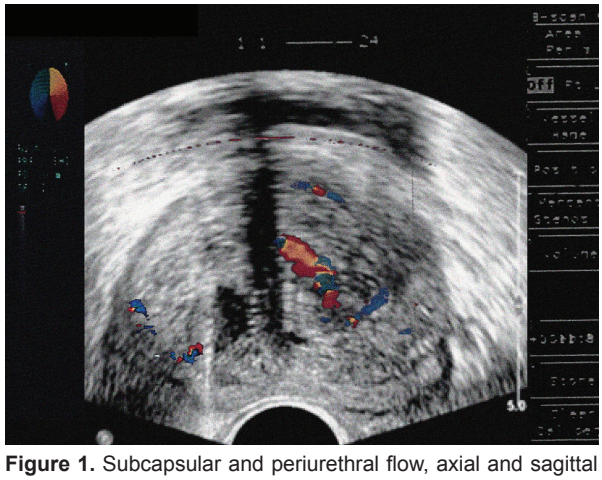

Figure 1. Subcapsular and periurethral flow, axial and sagittal sections of color doppler signal, with difficulty in monitoring the prostate parenchyma (grade 1 flow sample).

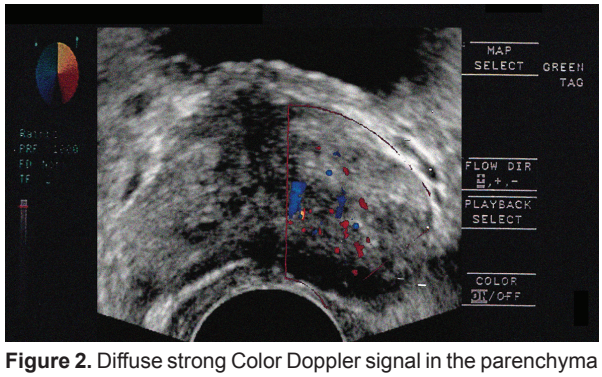

Figure 2. Diffuse strong Color Doppler signal in the parenchyma (grade 3 flow sample).

sion biopsy, systematic biopsies including other quadrants were done to detect malignancies that could be missed in TRUS.

Statistical analysis was performed using NCSS (Number Cruncher Statistical System) 2007 & PASS (Statistical Analysis and Sample Size) 2008 Statistical Software (Utah, USA). While evaluating the study findings, diagnostic tests (specificity, sensitivity, positive predictive value (PPV), negative predictive value (NPV)) as well as descriptive statistical methods (mean, Standard deviation, median, frequency, rate) were used. The results were evaluated in 95% confidence interval.

RESULTS

The mean age of our patients was calculated as 65.3 years (49–90 years). The prostate volumes of all cases ranged from 28 to 105 cc with an average of 53.44 cc. According to the biopsy pathology results, a malignancy was detected in 28 cases (36%). All malignant cases were adenocarcinomas with different Gleason scores. The remaining 50 patients (64%) had no malignancy.

Table 1. Distribution of laboratory values and CDU examination findings of the cases by groups

	Malignant (n=28)	Benign (n=50)
Mean age	66	64
Mean volume (mL)	54.03	53.11
Mean PSA (ng/mL), n (%)	21.34	12.21
<4 ng/mL	3 (10.7)	12 (24)
4–10 ng/mL	6 (21.42)	21 (42)
>10 ng/mL	19 (67.85)	17 (34)
Mean PSAD, n (%)	0.41	0.23
<0.15	5 (17.85)	28 (56)
>=0.15	23 (82.14)	22 (44)
CDU, n (%)		
Abnormal	24 (85.71)	28 (56)
Normal	4 (14.28)	22 (44)

CDU: Color Doppler ultrasound; PSA: Prostate specific antigen; PSAD: Prostate specific antigen density.

In TRUS examination, 36 cases were evaluated as malignant and 42 cases as benign. In our series, the pathology was detected in 51 patients and 27 patients were evaluated as normal in CDU. In laboratory analysis; PSA was suggestive of malignancy (PSA >4.0 ng/mL) in 63 cases and PSA was within normal limits in the remaining 15 cases. 27 patients with PSA values between 4–10 ng/mL were detected. The mean PSAD value of our cases was measured as 0.29. In 45 of the cases, PSAD suggested malignancy (>0.15) and in the remaining 33 cases, PSA were within normal limits.

The distribution of laboratory values and CDU examination findings of the cases by groups are summarized in Table 1.

28 cases were observed to have color scaled anomaly in CDU examination and to be histopathologically benign. 12 of these patients were diagnosed with benign prostatic hyperplasia (BPH) and 16 were diagnosed with prostatitis. 22 of all malignant cases were evaluated as malignant and 6 were evaluated as benign in TRUS examination.

Complications such as rectal hemorrhage and hematuria after biopsy were negligible.

When the positive predictive value (PPV), negative predictive value (NPV), sensitivity and specificity were calculated for each variable by comparing the results of imaging and laboratory findings with the pathology results in our study, the values in Table 2 were obtained.

If CDU was added to the TRUS for the decision to perform biopsy and the biopsy was not done when CDU was negative, 4 cancer cases (14%) would not be caught. Under this condition, the sensitivity (51%) of TRUS would decrease, and specificity (83%) and NPV (77%) would increase, while the PPV would not change (60%).

DISCUSSION

Accurate, reliable early diagnosis and staging are essential requirements for optimal management of patients with prostate cancer. The most commonly used diagnostic method for the detection of prostate cancer is digital rectal examination (DRE). However, early diagnosis of prostate cancer can be difficult with DRE and various laboratory tests and modern radiological imaging methods are used in addition to DRE in order to prevent delay in di-

Table 2. The results of imaging and laboratory findings with the pathology results

Method	Sensitivity	Specificity	PPV	NPV
Prostate specific antigen density	82.14%	56% (0.41–0.70) CI	51.11%	84.84%
Prostate specific antigen	89.28%	24% (0.13–0.38) CI	39.68%	80%
transrectal ultrasonographic	78.57%	72% (0.57–0.83) CI	61.11%	85.71%
(Color Doppler Ultrasound) color grading	85.71%	46% (0.31–0.60) CI	47.05%	85.18%
Transrectal ultrasonographic+CDU+PSAD	64.28%	80%	64.28%	80%

*In case of deviation from normal with the criteria defined in all three methods, this case was considered as positive, if one of the three methods was evaluated within normal limits, then it was considered as negative. CI 95% confidence interval. PPV: Positive predictive value; NPV: Negative predictive value; CDU: Color-Doppler ultrasonography; PSAD: Prostate specific antigen density; CI: Confidence interval.

agnosis. The sensitivity of PSA levels in detecting prostate cancer was found to be better than DRE. However, PSA levels are not specific.[11–13] This elevation can occur in benign prostatic hypertrophy, acute and chronic prostatitis, prostatic intra-epithelial neoplasia, infarcts, etc. The presence of prostate cancer in people with normal PSA levels makes the situation more complicated and increases the need for imaging methods.[13]

Because of the known low sensitivity and specificity of TRUS, which is the most commonly used imaging method in the diagnosis of prostate cancer, additional imaging methods that increase diagnostic power have been investigating for a long time. Advances in sonographic vascular (CDU) imaging help to diagnose prostate cancer. It is known that cancerous tissue initiates a vascular reaction leading to new vascularization. Neovascularization has been reported in many cancers as in prostate cancer.[14–16]

In our study, cancer was detected in 36% by histopathological evaluation. In many studies performed with different imaging methods, the rate of cancer detection was reported to be 29–53%.[17–23] In our study, sensitivity was higher with color grading (85%) than TRUS (78%), but specificity was lower (TRUS; 72%, CDU 46%). Low specificity is primarily due to the apparent overlap between cancer and prostatitis. As a matter of fact, none of the patients with prostatitis had normal color grading.

The diagnostic strength of TRUS and CDU combination varies between studies. In general, the sensitivity and specificity of combined evaluation have been reported to be between 33–88% and 57–85%.[24–26]

In our study, sensitivity was calculated as 51%, specificity 83%, PPV 60% and NPV 77% when TRUS and CDU were combined. If CDU was added to the TRUS for the decision to perform a biopsy and the biopsy was not performed when CDU was negative, 4 cancer cases (14%) would not be caught. Our results are similar to the studies evaluating the information in the literature on a case-by-case basis, whereas more satisfactory results were obtained in studies that evaluated CDU separately for each biopsy area. In a study of this type, they reported 93% specificity.[27]

Kelly et al.[28] found higher positive predictive values compared to CDU by doing TRUS alone. In our study, the positive predictive value of TRUS (61%) was higher than the color grading (47%).

Kelly et al. reported 1 case of CDU that could not be visualized by conventional gray scale USG to represent 1.3% of all patients in the study. Rifkin et al.,[29] in a study where they did with a bigger group, identified abnormal color flow normal gray scale in 9 of 132 cancer cases (7%) and in 5% of benign lesions. Abnormal color flow monitoring is a rare condition although TRUS evaluation is normal. This may indicate both benign and malignant conditions. In our series, there was only one case with abnormal color flow and a normal gray scale. Unfortunately, despite the inclusion of CDU findings, it remains difficult to diagnose the isoechoic prostate cancers.

Should the decrease in vascularity be evaluated for benignity? We cannot respond positively to this question since we have seen cases detected with cancer despite of being "CDU negative". Numerous cases of CDU-negative cancer have been reported in the literature, as well. With the available data, we cannot reveal a possible link between Gleason stage and CDU. In a study by Newman et al.[27] that correlated CDU with histological results in all biopsy sites, no correlation could be established between the Gleason score and CDU.

It is well known that ultrasonography, a subjective examination method, depends on the experience of the examiner. Although it cannot be clearly demonstrated in this study, it can be argued that CDU examination may eliminate the experience dependent situation.

Screening for prostate cancer is based on a triad of DRE, PSA and TRUS. Many studies have demonstrated that the combined use of these three studies facilitates cancer detection.[30,31] In our study, when TRUS + CDU + PSAD were used together, the sensitivity was 64.28% and the specificity was 80%.

Due to the low specificity of TRUS-guided prostate biopsy in hypoechoic nodules originating from the peripheral region, not only biopsy of nodules but systematic biopsy is required. Combining random and targeted biopsies with or without palpable abnormalities increases the rate of cancer detection. Our results suggest that combined sensitivity calculated from CDU and TRUS may not be sufficient to prevent random biopsies.

The sensitivity and specificity of prostate MRI imaging, which is a popular imaging modality recently, in the detection of prostate cancer were reviewed with three meta-analysis. In the one with 21 studies using Prostate imaging reporting and data system (PIRADS version 2) V2, 89% of common sensitivity and 73% of specificity were calculated.[32] Compared to multiparametric prostate MRI meta-analysis[33] that did not use prostate imaging reporting and data system (PIRADS) and PIRADS V1,[34] PIRADS V2 studies showed increased sensitivity while specificity decreased slightly (sensitivity and specificity values for both studies were 74% and 88%,[33] 78% and 79%[34] respectively). In a meta-analysis consisting of 16 studies and 2624 patients, the sensitivity and specificity of ultrasound using contrast material for detecting prostate cancer were determined as 70% and 74%, respectively.[35] When the sensitivity and specificity of the triple combination (64.28% and 80%), which we obtained the best results in our study, were compared with the results of prostate MRI and prostate ultrasound with contrast; the specificity values of our study were comparable with the new techniques, but the sensitivity values were lower.

The main limitation of our study is that the grading of vascularization depends on the subjective evaluation of the person who applies the CDU. Other limitations include the relatively small number of cases, the absence

of rectal examination findings in the study, the fact that CDU was not recorded separately for each biopsy site, no correlation of Gleason score, and the absence of new sonographic applications such as USG with contrast or elastography.

After all; in our study, the addition of CDU to TRUS increased the specificity but decreased the sensitivity (from 78% to 51%). CDU examination findings can be considered as one of the secondary findings (e.g. loss of normal accepted limits, bulging at the contour) used to make a biopsy decision for cancer diagnosis. According to our results, although we cannot claim that CDU provides a significant advantage in the diagnosis of cancer, color flow grading better identifies the prospective biopsy sites. Because of the low specificity of Color Doppler examination, it should be evaluated with Gray Scale and PSA findings. As a matter of fact, we obtained the best specificity (80%) by using three methods together. Although the specificity obtained by using three methods together was similar to new techniques such as multiparametric prostate MRI and prostate USG examination with contrast, the sensitivity values were lower.

Ethics Committee Approval

Approved by the local ethics committee.

Peer-review

Internally peer-reviewed.

Authorship Contributions

Concept: Ö.S.; Design: Ö.S.; Supervision: Ö.S.; Materials: S.N.D.; Data: S.N.D.; Analysis: S.N.D.; Literature search: Ö.S.; Writing: Ö.S.; Critical revision: S.N.D.

Conflict of Interest

None declared.

REFERENCES

1. Mohler JL, Antonarakis ES, Armstrong AJ, D'Amico AV, Davis BJ, Dorff T, et al. Prostate Cancer, Version 2.2019, NCCN Clinical Practice Guidelines in Oncology. J Natl Compr Canc Netw 2019;17:479–505.
2. Zorlu F, Zorlu R, Divrik RT, Eser S, Yorukoglu K. Prostate cancer incidence in Turkey: an epidemiological study. Asian Pac J Cancer Prev 2014;15:9125–30.
3. Morote J, Raventós CX, Lorente JA, Lopez-Pacios MA, Encabo G, de Torres I, et al. Comparison of percent free prostate specific antigen and prostate specific antigen density as methods to enhance prostate specific antigen specificity in early prostate cancer detection in men with normal rectal examination and prostate specific antigen between 4.1 and 10 ng./ml. J Urol 1997;158:502–4.
4. Yokomizo Y, Miyoshi Y, Nakaigawa N, Makiyama K, Ogawa T, Yao M, et al. Free PSA/total PSA ratio increases the detection rate of prostate cancer in twelve-core biopsy. Urol Int 2009;82:280–5.
5. Heidenreich A, Bastian PJ, Bellmunt J, Bolla M, Joniau S, van der Kwast T, et al. EAU guidelines on prostate cancer. part 1: screening, diagnosis, and local treatment with curative intent-update 2013. Eur Urol 2014;65:124–37.
6. Dyke CH, Toi A, Sweet JM. Value of random ultrasound-guided transrectal prostate biopsy. Radiology 1990;176:345–9.
7. Ghai S, Toi A. Role of transrectal ultrasonography in prostate cancer. Radiol Clin North Am 2012;50:1061–73.
8. Brawer MK, Chetner MP, Beatie J, Buchner DM, Vessella RL, Lange PH. Screening for prostatic carcinoma with prostate specific antigen. J Urol 1992;147:841–5.
9. Chang P, Friedland GW. The role of imaging in screening for prostate cancer. A decision analysis perspective. Invest Radiol 1990;25:591–5.
10. Patel U, Rickards D. The diagnostic value of colour Doppler flow in the peripheral zone of the prostate, with histological correlation. Br J Urol 1994;74:590–5.
11. Colberg JW, Smith DS, Catalona WJ. Prevalence and pathological extent of prostate cancer in men with prostate specific antigen levels of 2.9 to 4.0 ng./ml. J Urol 1993;149:507–9.
12. Bretton PR, Evans WP, Borden JD, Castellanos RD. The use of prostate specific antigen density to improve the sensitivity of prostate specific antigen in detecting prostate carcinoma. Cancer 1994;74:2991–5.
13. Spencer JA, Alexander AA, Gomella L, Matteucci T, Goldberg BB. Clinical and US findings in prostate cancer: patients with normal prostate-specific antigen levels. Radiology 1993;189:389–93.
14. Brawer MK, Deering RE, Brown M, Preston SD, Bigler SA. Predictors of pathologic stage in prostatic carcinoma. The role of neovascularity. Cancer 1994;73:678–87.
15. Gasparini G, Harris AL. Prognostic significance of tumor vascularity. Springer Link. Beverly A. Teicher (ed): Humana Press, New York; 1999. 317-339.
16. Evans SM, Laughlin KM, Pugh CR, Sehgal CM, Saunders HM. Use of power Doppler ultrasound-guided biopsies to locate regions of tumour hypoxia. Br J Cancer 1997;76:1308–14.
17. Shigeno K, Igawa M, Shiina H, Wada H, Yoneda T. The role of colour Doppler ultrasonography in detecting prostate cancer. BJU Int 2000;86:229–33.
18. Halpern EJ, Frauscher F, Forsberg F, Strup SE, Nazarian LN, O'Kane P, et al. High-frequency Doppler US of the prostate: effect of patient position. Radiology 2002;222:634–9.
19. Remzi M, Dobrovits M, Reissigl A, Ravery V, Waldert M, Wiunig C, et al. Can Power Doppler enhanced transrectal ultrasound guided biopsy improve prostate cancer detection on first and repeat prostate biopsy? Eur Urol 2004;46:451–6.
20. Inahara M, Suzuki H, Nakamachi H, Kamiya N, Shimbo M, Komiya A, et al. Clinical evaluation of transrectal power doppler imaging in the detection of prostate cancer. Int Urol Nephrol 2004;36:175–80.
21. Ismail M, Gomella LG. Ultrasound for prostate imaging and biopsy. Curr Opin Urol 2001;11:471–7.
22. Novis MI, Baroni RH, Cerri LM, Mattedi RL, Buchpiguel CA. Clinically low-risk prostate cancer: evaluation with transrectal doppler ultrasound and functional magnetic resonance imaging. Clinics (Sao Paulo) 2011;66:27–34.
23. Del Rosso A, Di Pierro ED, Masciovecchio S, Galatioto GP, Vicentini C. Does transrectal color Doppler ultrasound improve the diagnosis of prostate cancer? Arch Ital Urol Androl 2012;84:22–5.
24. Beyersdorff D, Taupitz M, Winkelmann B, Fischer T, Lenk S, Loening SA, et al. Patients with a history of elevated prostate-specific antigen levels and negative transrectal US-guided quadrant or sextant biopsy results: value of MR imaging. Radiology 2002;224:701–6.
25. Sen J, Choudhary L, Marwah S, Godara R, Marwah N, Sen R. Role of colour Doppler imaging in detecting prostate cancer. Asian J Surg 2008;31:16–9. doi: 10.1016/S1015-9584(08)60049-4.
26. Drudi FM, Giovagnorio F, Carbone A, Ricci P, Petta S, Cantisani V, et al. Transrectal colour Doppler contrast sonography in the diagnosis of local recurrence after radical prostatectomy--comparison with

MRI. Ultraschall Med 2006;27:146–51.
27. Newman JS, Bree RL, Rubin JM. Prostate cancer: diagnosis with color Doppler sonography with histologic correlation of each biopsy site. Radiology 1995;195:86–90.
28. Kelly IM, Lees WR, Rickards D. Prostate cancer and the role of color Doppler US. Radiology 1993;189:153–6.
29. Rifkin MD, Sudakoff GS, Alexander AA. Prostate: techniques, results, and potential applications of color Doppler US scanning. Radiology 1993;186:509–13.
30. Catalona WJ, Smith DS, Ratliff TL, Dodds KM, Coplen DE, Yuan JJ, et al. Measurement of prostate-specific antigen in serum as a screening test for prostate cancer. N Engl J Med 1991;324:1156–61.
31. Cooner WH, Mosley BR, Rutherford CL Jr, Beard JH, Pond HS, Terry WJ, et al. Prostate cancer detection in a clinical urological practice by ultrasonography, digital rectal examination and prostate specific antigen. J Urol 1990;143:1146–52.
32. Woo S, Suh CH, Kim SY, Cho JY, Kim SH. Diagnostic Performance of Prostate Imaging Reporting and Data System Version 2 for Detection of Prostate Cancer: A Systematic Review and Diagnostic Meta-analysis. Eur Urol 2017;72:177–188.
33. de Rooij M, Hamoen EH, Fütterer JJ, Barentsz JO, Rovers MM. Accuracy of multiparametric MRI for prostate cancer detection: a meta-analysis. AJR Am J Roentgenol 2014;202:343–51.
34. Hamoen EHJ, de Rooij M, Witjes JA, Barentsz JO, Rovers MM. Use of the Prostate Imaging Reporting and Data System (PI-RADS) for prostate cancer detection with multiparametric magnetic resonance imaging: a diagnostic meta-analysis. Eur Urol 2015;67:1112–21.
35. Li Y, Tang J, Fei X, Gao Y. Diagnostic performance of contrast enhanced ultrasound in patients with prostate cancer: a meta-analysis. Acad Radiol 2013;20:156–64.

Prostat Patolojilerinde Renkli Doppler İncelemenin Yeri

Amaç: Çalışmamızın amacı renkli Doppler ultrasonografinin kanser belirleme yeteneğinin araştırılması transrektal gri skala ultrason incelemeye katkısı ve PSA değerlerinin sonografik görüntüleme yöntemleri ile birlikte kulanımının prostat kanseri saptamadaki etkinliğinin değerlendirilmesidir.

Gereç ve Yöntem: Çalışmaya Taksim Eğitim ve Araştırma Hastanesi Radyoloji Bölümü'ne benign prostat hiperplazisi ya da prostat kanseri ön tanısı ile başvuran ve yaşları 49–90 arasında değişen 78 hasta alındı. Araştırmada Diasonic VST master renkli Doppler USG aracı ve 7 Mhz'lik transrektal prob kullanıldı. TRUS incelemede nodüllerin varlığı ve sayısı, lezyonun boyutu, şekli, eko yapısı, tutulan zon, peripheral zondaki nonkitlesel eko farklılığı, periferik zon ve inner gland sınırının kaybı, kapsüler invazyon, seminal vezikül kalınlaşması, prostat seminal vezikül açısının obliterasyonu ya da açıklığı not edildi. Damarlanma haritası ise bezin değişik alanlarından geçen kesitlerde değerlendirildi. Renkli akım 3 puan skalası ile gradelendi ve bulgular patoloji sonuçları ile karşılaştırıldı.

Bulgular: Histopatolojik inceleme sonucunda 28 olgu (%36) malign, geri kalan 50 olgu ise (%64) benign olarak değerlendirildi. Malign olguların ortalama prostat spesifik antijen dansitesi (PSAD) değeri 0.41 olarak kaydedildi, benign olgularda 0.23 olarak saptandı. Prostat kanseri belirleme açısından en iyi sonuçları transrektal gri skala ultrason, renkli Doppler ultrason ve PSAD'nin birlikte kullanımı ile elde edildi. Bu koşulda sensitivite, spesifite, pozitif ve negatif prediktif değerler sırası ile %64, %80, %64 ve %80 olarak kaydedildi.

Sonuç: Çalışmamızda RDUS'ninn TRUS'ye eklenmesi spesifiteyi artırsa da sensitiviteyi (%78 den %51'e) düşürmektedir. Sonuçlarımıza göre RDUS'nin kanser tanısında belirgin bir avantaj sağladığını iddia edemesek de renkli akım gradelemesi biyopsiye aday yerleri daha iyi belirlemektedir. Renkli Doppler incelemesinin spesifitesinin kötü olması nedeni ile gri skala ve PSA bulguları ile birlikte değerlendirilmelidir. Nitekim çalışmamızda da en iyi spesifite (%80) üç yöntemin birlikte kullanılması ile elde edildi.

Anahtar Sözcükler: Prostat karsinomu; prostat patolojileri; PSA; renkli Doppler ultrason; transrektal ultrason.