Radical vulvectomy with right gluteal and left medial thigh V-Y advancement flap reconstruction

İlker Selçuk[1], Ozan Doğan[2], Cağatay Barut[3], Eray Çalışkan[4], Kamil Zalewski[5], Evrim Erdemoğlu[6], Ate van der Zee[7]

[1]Clinic of Gynecologic Oncology, University of Health Sciences Turkey, Ankara City Hospital, Ankara, Turkey
[2]Private Clinic, İstanbul, Turkey
[3]Department of Anatomy, Bahçeşehir University Faculty of Medicine, İstanbul, Turkey
[4]Department of Obstetrics and Gynecology, Okan University Faculty of Medicine, İstanbul, Turkey
[5]Department of Gynecologic Oncology, Holycross Cancer Center, Kielce, Poland
[6]Department Gynecologic Oncology, Süleyman Demirel University Faculty of Medicine, Isparta, Turkey
[7]Department of Gynecologic Oncology, University of Groningen, Groningen, Netherlands

Abstract

Vulvar cancer is rare. The vulva constitutes the external female genitalia and it is associated with the perineum with the intersection of urinary, sexual and anal systems. The deep anatomy of the perineum in the urogenital and anogenital triangle should be well-known to gynecological oncologists. Radical vulvectomy is the surgical treatment of choice in gross tumors expanding over the vulvar skin. After this type of excision, reconstruction is critically important because it is not always feasible to suture the vulvar defect in a primary manner. Thus, the reconstruction options should also be known to gynecological oncologists. Here, we present a video of radical vulvar cancer surgery, which was performed on a cadaver with gluteal and medial thigh V-Y advancement flap reconstruction.

Keywords: Vulvar cancer, flap, vulvectomy, perineum, cadaveric

Received: 13 April, 2020 **Accepted:** 27 April, 2020

Introduction

Vulvar cancer is the least common gynecological malignancy and makes up around 2-5% of gynecological cancers. It usually presents with pruritus and sometimes with a vulvar lesion, which is commonly detected on the labia majora. Squamous cell carcinoma is the most common histological type, constituting approximately 90%, and management does not significantly change among the subtypes. Vulvar cancer is generally diagnosed in the early stages and surgical removal of the vulva with a conservative or radical approach forms the cornerstone of treatment, especially for early-stage disease (1,2). Inguinal lymph nodes are the site of lymphatic dissemination and lymph node involvement is one of the most important prognostic factors associated with stage, adjuvant treatment and survival. Thus inguino-femoral lymphadenectomy is a part of surgical treatment (3).

Due to the small number of cases, the learning curve for gynecological oncology fellows concerning vulvar cancer surgery is steep. Additionally, after removal of the vulva the reconstruction phase is not always feasible with primary suturation. Hence, plastic surgeons will apply vulvar flap replacement and this is not always performed by all gynecological oncologists. Currently, wide local vulvar excision on the side affected by the tumor, with similar margins to radical vulvectomy, is the main type of surgery in early-stage vulvar cancer. In contrast, in gross tumors expanding across the vulvar skin, radical vulvectomy is the choice of surgical treatment. In this video article we demonstrate radical vulvar cancer surgery

Address for Correspondence: *İlker Selçuk*
e.mail: ilkerselcukmd@hotmail.com ORCID: orcid.org/0000-0003-0499-5722
©Copyright 2021 by the Turkish-German Gynecological Education and Research Foundation - Available online at www.jtgga.org
Journal of the Turkish-German Gynecological Association published by Galenos Publishing House.
DOI: 10.4274/jtgga.galenos.2020.2020.0055

that was performed using a cadaver during the Vulvar Cancer Surgery Cadaveric Workshop; an International and European Society of Gynaecological Oncology endorsed meeting held on the 31th August 2018 at Bahçeşehir University Faculty of Medicine, Department of Anatomy, İstanbul, Turkey.

Vulvar anatomy

Vulva is the term used to describe the entire external female genitalia. The vulva is comprised of the mons pubis, labia majora, labia minora, clitoris, vaginal vestibule and vestibular glands. The anastomotic vessel arc of the external and internal pudendal arteries supplies the vulvar region. The innervation of the vulva is provided by the ilioinguinal nerve, genitofemoral nerve and pudendal nerve (dorsal clitoral nerve and perineal nerves). Superficial inguinal lymph nodes are the primary site of lymphatic drainage of vulva and after the superficial lymph nodes, the drainage flows over the cribriform fascia to the deep femoral lymph nodes (4).

The perineum is the region between the anus and the upper portion of the clitoris, at the mons pubis. The boundaries of the perineum are; anteriorly pubic symphysis and arcuate ligament of the pubis, posteriorly coccyx, anterolaterally ichiopubic rami and ichial tuberosities, posterolaterally sacrotuberous ligament, superiorly pelvic floor and inferiorly the skin. Superficially the skin covers the perineum while the pelvic diaphragm and the levator ani muscle forms the deepest part (5). A line between the ischial tuberosities divides this diamond-shaped region into the anteriorly located urogenital and posteriorly located anal triangle (Table 1).

Radical vulvectomy with right gluteal and left medial thigh V-Y advancement flap reconstruction: surgical technique (Video attachment shows the surgical technique)

1. The circumferential outer incision on the vulvar skin aims to excise the tumor with clear margins. A pathological margin of 0.8 cm is critical after the tissue shrinkage with formalin. Thus, an incision 2 cm laterally, from the tumor will be optimal for clear margins. The resection margin will decrease to 1 cm around the urethra and anus to protect the functions of these structures. Nevertheless, the distal urethra (1 cm) could be sacrificed without any harm to function. In some cases, partial external anal sphincter excision may also be applied (6).

2. The incision deepens down to the subcutaneous fatty tissue and afterwards down to the inferior fascia of urogenital diaphragm which is termed as perineal membrane, by the way the contents of the superficial perineal space (ischiocavernosus, bulbospongiosus and superficial transverse perineal muscle) are excised with the vulvar specimen. The arterial supply from the internal pudendal artery come from the 5 and 7 o'clock directions and they should be ligated or sutured.

3. The upper part of the vulvar incision deepens down to the pubic periosteum, which is medial to the adductor fascia. Here, the suspensory ligament of the clitoris should be ligated or sutured.

Table 1. Layers of the perineum from inferior to superior (from skin to pelvic floor)

A. Urogenital triangle
Skin
Superficial perineal fascia
Superficial fatty layer (Camper's fascia)
Membranous layer (Scarpa's fascia)
Deep perineal fascia
- This fascia covers the superficial perineal muscles located at the superficial perineal pouch - **Superficial perineal pouch** - the lateral border is formed by the ischiopubic rami
Bulbospongiosus muscle
Ischiocavernosus muscle
Superficial transverse perineal muscle
Perineal branch of pudendal nerve
Crura of clitoris
Bulbs of vestibule
Perineal membrane (Inferior fascia of urogenital diaphragm)
- The perineal body is continuous with the perineal membrane - **Deep perineal pouch** - the lateral boundary is formed by the inferior portion of the obturator internus muscle
Deep transverse perineal muscle
External urethral sphincter
Proximal urethra
Internal pudendal vessels
Dorsal nerve of clitoris
Superior fascia of urogenital diaphragm
Pelvic floor
Levator ani muscle
Coccygeus muscle
B. Anal triangle
Anal canal, sphincters, the ischio-anal fossa, nerves and vessels are the contents of the anal triangle
Skin
Superficial fascia
Superficial fascia of anal triangle contains the subcutaneous fatty tissue
Deep fascia
Deep fascia of the anal triangle is inferior to the levator ani muscle and covers the ischioanal fossa and its lateral part
Pelvic floor
Levator ani muscle
Coccygeus muscle

4. At the inferior part of the incision, dissection is performed over the rectovaginal septum.
5. A circumferential inner incision encircling the urethra and vaginal introitus is performed.
6. The outer incision on the labia majora and skin is combined with the inner incision, which is around the vaginal introitus, and the vulvar specimen is excised totally (Figure 1).
7. The wound is closed primarily in most cases. Deep structures are sutured with 2-0 delayed absorbable materials to prevent any dead space. Skin should be closed in a tension-free fashion.
8. If a tension-free closure is not possible, the vulvar defect should be closed by a flap in advance with an adequate blood supply, which may prevent later cosmetic and functional problems. For flap replacement the gluteal or the medial thigh is incised in a manner of "V-Y" down to the level of the muscle fascia (Figure 2). During this step, the perforators arising from the internal pudendal artery are secured, and electrocautery could be used in most of the circumstances. When the flap is mobilized in all directions, it is advanced medially to the vaginal inner wall in a tension-free manner. The "dog ear" formation, which is shaped at the edges, is removed and the flap is sutured to the surrounding tissue with the aim of closing all the layers (7) (Figure 3). Always consider a multidisciplinary approach for reconstruction of the vulvar defect (8).

Complications of radical vulvectomy

Since the surgery is extremely radical and impinges on the urinary, sexual and anal organs, there may be many dysfunctions related to these systems (9).

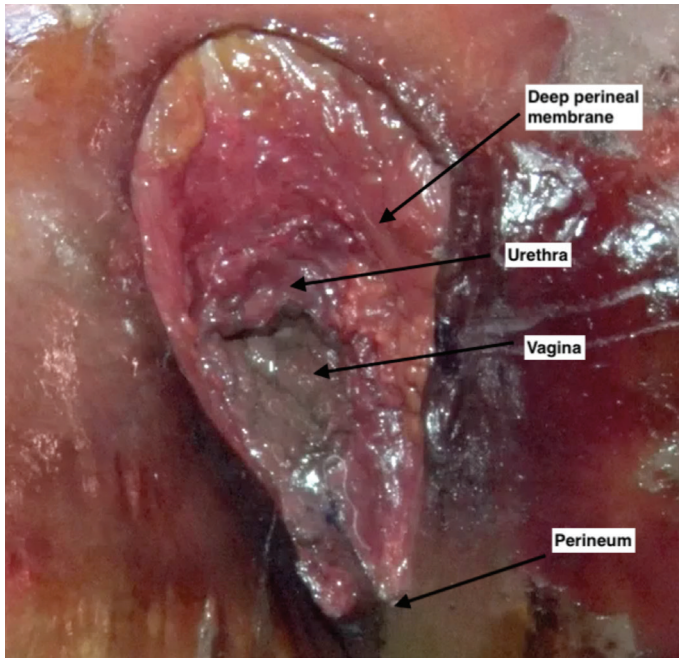

Figure 1. The vulvar region after excision of the radical vulvectomy specimen

- Wound complications

Wound breakdown and wound infection are particularly prevalent in obese patients at the end of the first week. Suction drains are suggested in selected patient groups.

- Flap complications

They mostly arise due to inappropriate vascular supply or increased tension.

- Urinary complications

Infection and involuntary urine loss are the probable complications with regard to the radicality of the surgery.

- Psychosocial and sexual dysfunction

It is an important issue that may be revealed and mitigated with professional support.

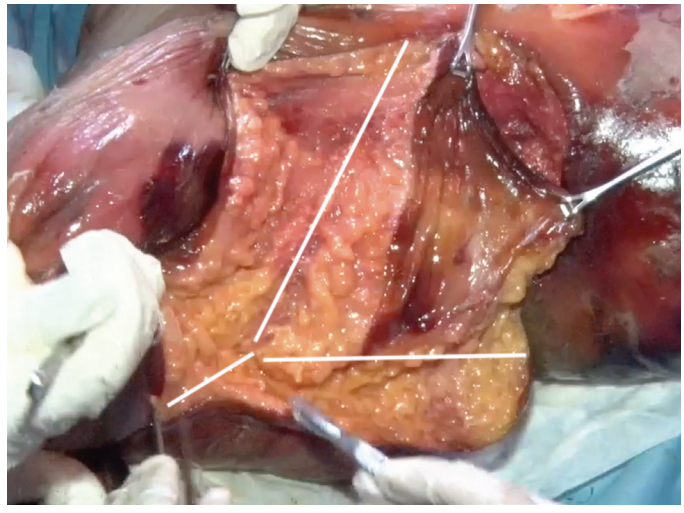

Figure 2. The incision for left gluteal V-Y flap advancement to the level of muscle fascia

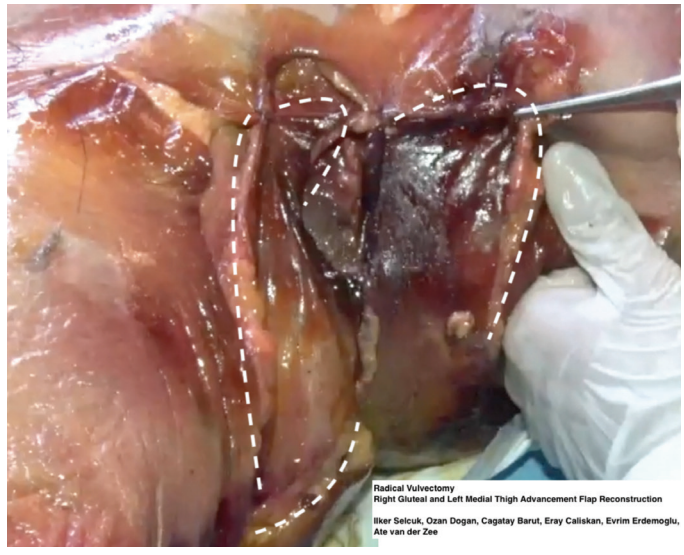

Figure 3. Vulvar reconstruction with V-Y advancement flap and closure of deep and superficial layers

Conclusion

Vulvar cancer is rare and curative surgery is a radical procedure. The anatomy and the reconstruction techniques should be known by all gynecological oncologists in order to achieve optimal surgical outcomes more widely.

Video 1.

https://www.doi.org/10.4274/jtgga.galenos.2020.2020.0055.video1

Conflict of Interest: *No conflict of interest was declared by the authors.*

Financial Disclosure: *The authors declared that this study received no financial support.*

References

1. Dellinger TH, Hakim AA, Lee SJ, Wakabayashi MT, Morgan RJ, Han ES. Surgical management of vulvar cancer. J Natl Compr Canc Netw 2017; 15: 121-8.
2. Rogers LJ, Cuello MA. Cancer of the vulva. Int J Gynaecol Obstet 2018; 143(Suppl2): 4-13.
3. Weinberg D, Gomez-Martinez RA. Vulvar cancer. Obstet Gynecol Clin North Am 2019; 46: 125-35.
4. Selcuk İ, Aktaş Akdemir H, Ersak B, Tatar İ, Sargon MF, Güngör T. Inguinofemoral lymphadenectomy and femoral dissection: cadaveric educational video. J Turk Ger Gynecol Assoc 2021; 22: 155-7.
5. Standring S. Gray's anatomy: the Anatomical Basis of Clinical Practice. In: Standring S, editor. True pelvis, pelvic floor and perineum. 41st ed: Elsevier; 2016.
6. Bristow RE. Radical vulvectomy. In: Cundiff GW, Azziz R, Bristow RE, editors. Te Linde's Atlas of Gynecologic Surgery. 1st ed: Lippincott Williams & Wilkins (LWW); 2013.
7. Lee PK, Choi MS, Ahn ST, Oh DY, Rhie JW, Han KT. Gluteal fold V-Y advancement flap for vulvar and vaginal reconstruction: a new flap. Plast Reconstr Surg 2006; 118: 401-6.
8. Oonk MHM, Planchamp F, Baldwin P, Bidzinski M, Brännström M, Landoni F, et al. European Society of Gynaecological Oncology Guidelines for the management of patients with vulvar cancer. Int J Gynecol Cancer 2017; 27: 832-7.
9. Morrow PC. Surgery for Vulvar Neoplasia. In: Morrow PC, editor. Morrow's Gynecologic Cancer Surgery. 2nd ed: South Coast Medical Publishing; 2012.