Marmara Medical Journal 2017; 30: 54-57
DOI: 10.5472/marumj.299425

CASE REPORT / OLGU SUNUMU

Fallopian tube metastasis in a patient with a history of breast cancer

Meme kanseri hikayesi olan bir hastada fallop tüpü metastazı: nadir bir olgu

Melek KARAKURT ERYILMAZ, Fatma YALÇIN MÜSRİ, Derya KIVRAK SALİM, Betül ÜNAL, Gülgün ERDOĞAN, Metin KABA, Hasan Şenol COŞKUN

ABSTRACT

Breast carcinoma metastasis to the fallopian tube is extremely rare. Distinction between a primary fallopian tumor and metastasis of breast cancer is crucial since treatment and prognosis are different. However, it is difficult to confirm pathologically without surgery. Herein, we report a 46-year-old woman with a history of left modified radical mastectomy for breast cancer 13 years ago, presenting with a left adnexial mass. She underwent total abdominal hysterectomy with bilateral salpingo-oophorectomy. Pathology findings revealed cytokeratin (CK) 7, ER, and PR positive tumor cells. Mammoglobuline, P53, CK20, GCDFP-15 and, thrombomoduline were negative. HER2 was also 2+. Fluorescence in situ hybridization (FISH) for HER2 was negative. Based on the morphology and immunophenotype of the tumor, we established the diagnosis as metastasis of breast cancer to the fallopian tube.

Keywords: Fallopian tube cancer, Breast cancer, Fallopian tube metastasis

ÖZ

Meme kanserinin fallop tüpüne metastazı oldukça nadir görülür. Tedavi ve prognozları farklı olduğundan primer fallop tüpü tümörü ile fallop tüpüne meme kanseri metastazının birbirinden ayırt edilmesi ve durumun cerrahiden önce patolojik olarak doğrulanması zordur. Biz burada 13 yıl önce meme kanseri nedeniyle sol modifiye radikal mastektomi hikayesi olan 46 yaşında bir kadın hastayı sunduk. Hasta sol adneksiyel kitle ile başvurdu. Total abdominal histerektomi ile birlikte bilateral salpingo-ooferektomi yapıldı. Immünhistokimyasal olarak tümör hücreleri sitokeratin 7 (CK7), östrojen reseptörü (ER) ve progesteron reseptörü (PR) ile pozitif boyandı. Mammoglobulin (x2), P53, CK20, GCDFP-15, trombomodulin ve HER2 boyası negatifti. HER2 için floresan in situ hibridizasyon (FISH) negatifti. Hastaya tümörün hem morfolojik hem de immünfenotipik özellikleri nedeniyle meme kanserinin fallop tüpüne metastazı tanısı konulmuştur.

Anahtar kelimeler: Fallop tüp kanseri, Meme kanseri, Fallop tüpüne metastaz

Introduction

Breast cancer is the most common malignancy in women. Breast cancer usually presents as a localized disease, however, one to five percent of women diagnosed with breast cancer have metastatic disease on presentation. Another 30 percent of women with early-stage breast cancer at diagnosis would develop distant metastatic disease after treatment [1]. Metastatic breast cancer is unlikely to be cured; median survival is approximately 18 to 24 months, though this varies based on subtype of tumor, sites of metastatic involvement, and burden of metastatic disease [2]. The most common metastasic sites are the lung, liver, brain, and bone [3].

We report the development of metastasis to the fallopian tube in a 46 year-old woman who had prior history of breast carcinoma.

Melek Karakurt Eryılmaz (✉), Fatma Yalçın Müsri, Derya Kıvrak Salim, Hasan Şenol Coşkun
Department of Medical Oncology, School of Medicine, Akdeniz University, Antalya, Turkey
e-mail: drangelkarakurt@hotmail.com

Betül Ünal, Gülgün Erdoğan
Department of Pathology, School of Medicine, Akdeniz University, Antalya, Turkey

Metin Kaba
Department of Obstetrics and Gynecology, School of Medicine, Akdeniz University, Antalya, Turkey

Submitted / Gönderilme: 08.11.2016 **Accepted/Kabul:** 17.12.2016

Case Report

A 46-year-old woman presented with chest pain in April 2015. In 2002, she was treated for invasive ductal carcinoma (estrogen receptor (ER) +, progesterone receptor (PR) +, and the human epidermal growth factor receptor 2(HER2), pT2N2M0) with left modified radical mastectomy, adjuvant chemotherapy and radiotherapy, followed by anti-hormonal therapy with tamoxifen for 5 years. There was no history of any other systemic disease. On admission, she was not using any medication. Thoracic computed tomography (CT) scan revealed left pleural effusion. Abdominopelvic CT demonstrated intraabdominal multiple lenfadenopathies and a 7×6.5 centimeter parauterine cystic mass. On (18) F-fluorodeoxyglucose ((18) F-FDG) positron emission tomography/computed tomography (PET/CT), left pleural effusion, multiple hypermetabolic metastatic nodules in the left lung, bilateral hilar and abdominal hypermetabolic metastatic lenfadenopathies, and a 7×7 centimeter left adnexal hypermetabolic mass (maximum standardized uptake values (SUV max): 12) were demonstrated. Serum CA 12-5 level was normal [26 U/ml (normal < 35 U/ml)]. Serum CA 15-3 level was markedly elevated [231 U/ml (normal < 38.6 U/ml)]. In May 2015, total abdominal hysterectomy with bilateral salpingo-oophorectomy was performed. Frozen-section test revealed a 7.5×6.5×6 cm cystic mass on the wall of the left fallopian tube. There were no pathologic findings for the ovaries, endometrium, and the right fallopian tube. Serous fluid within the cyst was drained. Cyst wall thickness was 2 mm. Histopathological examination revealed a 2 mm malignant epithelial tumor on the wall of the fallopian tube (Figure 1). Tumor was diffusely stained with cytokeratin (CK) 7, ER, and PR (Figure 2). Staining for mammoglobuline, P53, CK20,

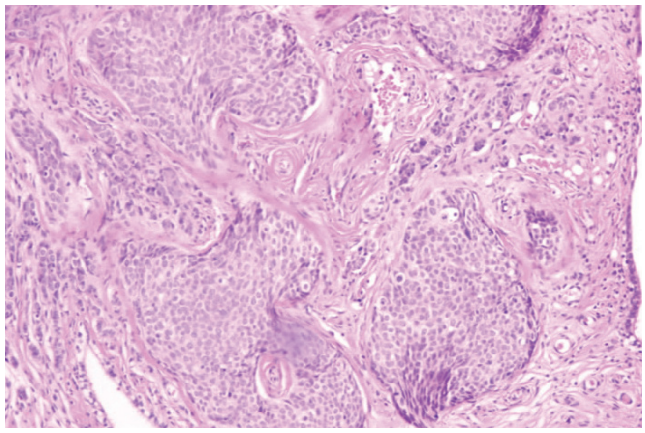

Figure 1. The tumor is located in tubal stromal tissue under cuboidal ciliated tubal epithelium. It is composed of diffuse sheets, well defined nests, cords or as individual cells

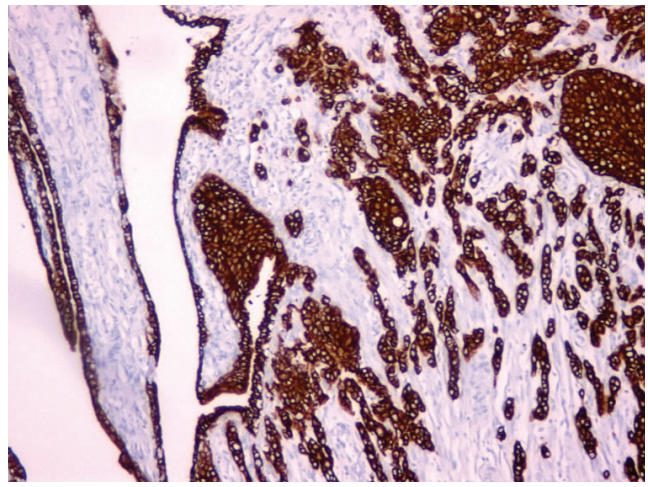

Figure 2a. Tumoral cells show positive immunostaining for CK 7 x100

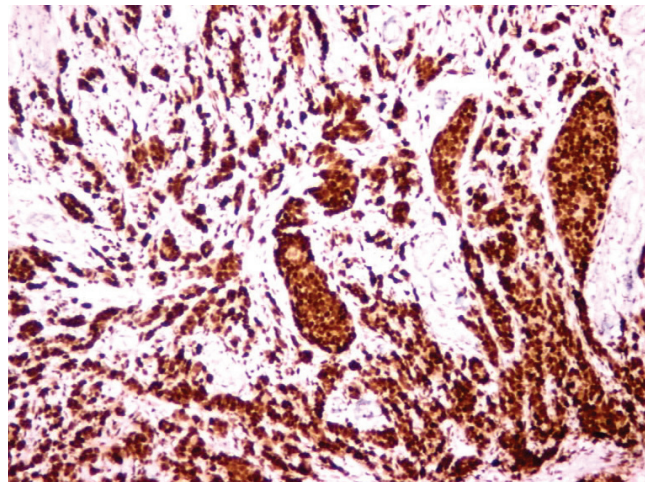

Figure 2b. Tumoral cells show positive immunostaining for ER x100

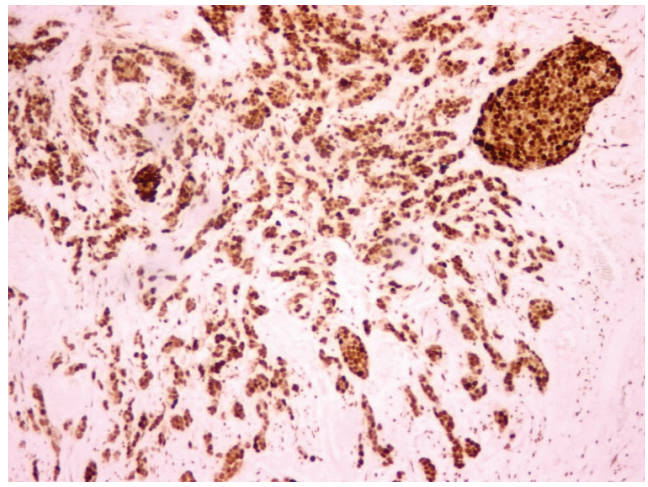

Figure 2c. Tumoral cells show positive immunostaining for PR x100

GCDFP-15 and thrombomoduline were negative. HER2 was also 2+. Fluorescence in situ hybridization (FISH) for HER2 was negative. Histopathological examination revealed similarities between the specimens of the breast and the fallopian tube. The definitive histopathological diagnosis was consistent with metastatic breast carcinoma to the fallopian tube. Six cycles of docetaxel (75 mg/m^2 every 3 weeks) were planned with the diagnosis of metastatic breast carcinoma.

Discussion

Metastases to the fallopian tubes from non-gynecologic cancers are uncommon. Most common metastases to the fallopian tubes are from gynecologic carcinomas. The reason for the metastases to the fallopian tubes can be the spread of the breast and colorectal cancers. In a retrospective study including, 325 cases with metastasis to the female genital tract, one hundred forty-nine (45%) cases were metastatic from non-gynecologic cancers. Average age of the patients with metastases from non-gynecologic cancers was 53.1 years. In 128 of the 149 cases (86%) the primary tumor was diagnosed previous to or concurrent with the discovery of the metastasis. In 21 cases, metastasis was the first finding, resulting in a search for the primary neoplasm. The study showed that the most common primary neoplasms were colorectal (37.6%) and breast cancers (34.9%). The most frequent metastatic sites for non-gynecologic cancers were the ovaries and the vagina. None of the patients with breast carcinomas had fallopian metastasis in this study [4]. In another case series of 100 non-gynecologic cancers metastasized to the fallopian tubes, most tumors were adenocarcinoma (87%), and remainder were lymphomas, neuroendocrine tumors, and mesotheliomas. Most common primary neoplasms were colon (35%), and breast cancers (15%). The anatomic distribution of metastases included the tubal mucosa (29%), submucosa (43%), muscularis propria (54%), serosa (76%), lymphovascular spaces (38%), intraluminal space (16%), and mesonephric remnants (39%). Thirty-five percent of the cases had an apparent tubal nodule or mass. Tumor involved the fimbriae in 49% of the cases, including 10% of cases in which the tumor was restricted to the fimbriae without involving the nonfimbriated portion of the tube [5].

In a similar case report, a 36-year-old woman had two successive primary cancers of the breast (left, right) removed surgically. At the time of the second mastectomy a bilateral salpingo-oophorectomy was also performed. Unexpectedly, breast cancer metastasis was found on the right fallopian tube; infiltrating cancer was also present in the left ovary [6].

The development of an adnexial mass in patients with a history of breast cancer cause therapeutic and diagnostic dilemmas. An accurate histological examination including appropriate immunohistochemical panel is needed to discriminate primary tubal tumors from metastatic lesions from the breast. ER, PR, and HER2 receptor status have prognostic and predictive value for patients with metastatic breast cancer. Expression of these receptors may be discordant between recurrent and primary breast cancers, therefore a repeat biopsy may be needed in women with metastatic breast cancer. In a pooled analysis of two prospective studies, the rates of discordance in ER, PR, and HER2 between the primary and recurrent breast cancers were 13%, 31%, and 5.5%, respectively [7]. In another prospective observational study, rates of discordance for ER, PR, and HER2 were 13%, 28%, and 3%, respectively [8]. In our case, ER, PR, and HER2 receptor were positive in the primary breast tumor but HER2 was negative while ER and PR were positive in metastatic breast tumor lesion.

Breast carcinoma metastasis to the fallopian tube is rare. Clinicians should evaluate whether the tubal lesion in a patient with a history of breast cancer is metastatic or primary, because treatments and prognosis are different. Patients with metastasis to the fallopian tubes should be treated with systemic chemotherapy.

Conflict of interest

None.

References

1. Early Breast Cancer Trialists' Collaborative Group (EBCTCG). Effects of chemotherapy and hormonal therapy for early breast cancer on recurrence and 15-year survival: an overview of the randomised trials. Lancet 2005;365:1687-717. doi: 10.1016/S0140-6736(05)66544-0.
2. Gennari A, Conte P, Rosso R, Orlandini C, Bruzzi P. Survival of metastatic breast carcinoma patients over a 20-year period: a retrospective analysis based on individual patient data from six consecutive studies. Cancer 2005;104:1742-50. doi: 10.1002/cncr.21359.

3. Dafni U, Grimani I, Xyrafas A, Eleftheraki AG, Fountzilas G. Fifteen-year trends in metastatic breast cancer survival in Greece. Breast Cancer Res Treat 2010; 119:621-31. doi: 10.1007/s10549-009-0630-8.
4. Mazur MT, Hsueh S, Gersell DJ. Metastases to the female genital tract. Analysis of 325 cases. Cancer 1984;53:1978-84. doi:10.1002/1097-0142(19840501)53:9<1978::AID-CNCR2820530929>3.0.CO;2-1.
5. Rabban JT, Vohra P, Zaloudek CJ. Nongynecologic metastases to fallopian tube mucosa: a potential mimic of tubal high-grade serous carcinoma and benign tubal mucinous metaplasia or nonmucinous hyperplasia. Am J Surg Pathol 2015; 39:35-51. doi: 10.1097/PAS.0000000000000293.
6. Case TC. Cancer of the breast with metastasis to the fallopian tube. J Am Geriatr Soc 1968;16:832-4. doi: 10.1111/j.1532-5415.1968.tb02771.x.
7. Amir E, Clemons M, Purdie CA, et al. Tissue confirmation of disease recurrence in breast cancer patients: pooled analysis of multi-centre, multi-disciplinary prospective studies. Cancer Treat Rev 2012; 38:708-14. doi: 10.1016/j.ctrv.2011.11.006.
8. de Dueñas EM, Hernández AL, Zotano AG, et al. Prospective evaluation of the conversion rate in the receptor status between primary breast cancer and metastasis: results from the GEICAM 2009-03 ConvertHER study. Breast Cancer Res Treat 2014; 143:507-15. doi: 10.1007/s10549-013-28252.