Kafkas Univ Vet Fak Derg
17 (6): 941-948, 2011

RESEARCH ARTICLE

Using Total Hip Prosthesis with Porous-Coated and Interlocking System In Twenty-one Dogs [1]

Serhat ÖZSOY * Zihni MUTLU * Dilek Olgun ERDİKMEN * Kemal ALTUNATMAZ *

[1] *This study is supported by BAP (Istanbul University Scientific Research Center) The project number is 417/2007*
* Department of Surgery, Faculty of Veterinary Medicine, University of İstanbul, TR- 34320 Istanbul - TURKEY

Makale Kodu (Article Code): KVFD-2011-4760

Summary

In this study, porous-coated, fixed with screwed-system femoral prosthesis and total hip prosthesis composed of screwed-system acetabular cup were applied on 21 dogs of different breeds, sexes and ages. Total hip arthroplasty (THA) was applied as one sided in all cases. In 7 cases luxation occured and in 5 of them the prostheses were taken out. One of the cases had a second operation for dislocation, but because of reluxation the prosthesis was taken out again. Ventral luxation occured in one of the cases but with a second operation success was obtained. Aseptic loosening of the femoral implant occured in 1 case, and in 1 case aseptic loosening of acetabular cup occured, both prostheses were taken out. One case died due to another disease. It has been indicated that the 12 cases are going on their livings with the applied prostheses.

Keywords: *Dog, Total hip arthroplasty, Porous coated, Interlocking prosthesis system*

Yirmibir Köpekte Poroz Kaplı İnterlocking Vida Sistemli Kalça Protezi Uygulaması

Özet

Bu çalışmada farklı ırk,yaş ve cinsiyetteki 21 köpekte poroz kaplı ve kilitli vida tespit sistemli femur protezi ve vida tespitli asetabular kaptan oluşan total kalça protezi (TKP) uygulaması yapıldı. TKP tüm olgularda tek taraflı uygulandı. Operasyon yapılan 7 olguda luksasyon oluştu ve bunların 5'inde protez çıkarıldı. Çıkık bulunan bir olguda ikinci operasyondan sonra reluksasyona bağlı olarak protez çıkarıldı. Bir olguda ventral luksasyon oluştu ve ikinci operasyonla başarı elde edildi. Bir olguda femur protezinde aseptik protez gevşemesi, 1 olguda da aseptik asetabular kap gevşemesi oldu ve her iki protez de çıkarıldı.Protez yapılan bir olgu başka bir hastalığa bağlı olarak öldü. TKP uygulanan 12 olgunun ise uygulanan protezle yaşamlarını sürdürdükleri belirlendi.

Anahtar sözcükler: *Köpek, Total kalça protezi, Poroz kaplama, Kilitli protez sistemi*

INTRODUCTION

A cemented canine hip prosthesis has been available since 1976 and an uncemented prosthesis since the mid-1980's [1], micrototal hip replacement has been available for small dogs and cats since June 2005 [2,3]. Indications for canine THA include osteoarthritis secondary to hip dysplasia, traumatic luxation of a previously normal coxofemoral joint, irrepairable fracture, failed femoral head and neck excision and osteoarthritis secondary to trauma [4,5]. The most indications for THA were hip dysplasia and secondary arthritis [6].

All commercially available veterinary implants use a metal on plastic interface. The femoral head and stem are composed of either stainless steel, cobalt chrome, or titanium and the acetabular cup is composed of ultra-high molecular weighted polyethylene and a metal shell [4,7].

To increase prosthesis longevity, uncemented porous-coated compenents that allow biological fixation through tissue ingrowth have been designed. Fixation of the implants is provided acutely by press-fitting, and chronically by fibrous and bony, ingrowth into porous coating [8-11]. The prerequisites for the ingrowth of bone are close contact of the porous surface with the bone and mechanical

İletişim (Correspondence)
+90 212 4737070/17301
drzihnimutlu@yahoo.com

stabilization of the prosthesis at the time of insertion [12].

No difference was found in the hydroxyapatite-coated femoral stem and the porous-coated stem after radiographic and clinical evaluation [8,10]. Dorr et al. [8], suggested that although the hydroxyapatite stem showed better radiographic results than the porous-coated stem, the clinical results were similar.

Complications of THA including luxations, infection, aseptic loosening of components, patella luxation, pulmoner embolism, periprosthetic femoral fractures, femoral medullary infarction and neuropraxia [13-16]. Intraoperative complications were similar to those reported elsewhere with the penetration of pelvic canal and fissure formation in the proximal femur the most common complications [3,6].

The luxation appearing after THA also depends on other factors as much as the acetabular component positioning. Closing the joint capsula plays an important role. Most of the luxations happens at the acute postoperative period. Because the fibrous tissue preventing luxation on the capsula and periarticular tissue has not occured yet [17]. The rate of postoperative luxation was between 1.1% to 12%. The majority of luxation occured within 6 weeks of surgery [6,18].

Periprosthatic bone resorption or osteolysis is the dominant cause of implant failure in total hip arthroplasty [19]. Aseptic loosening is the major cause of implant failure in THA on both cemented and cementless prosthesis in human patients [20]. Bone preparation, cementing techniques, prosthesis placement and prosthesis design have been implicated as the cause of aseptic loosening following THA in people [21]. Aseptic loosening has been attributed to a biological reaction to wear debris, spesifically polyethylene particles, that stimulate inflamatory mediators (*cytokines*) which mediate bone resorption [1].

In this study, we aim to evaluate the clinical and radiological results of appling porous-coated interlocking femoral and acetabular prosthesis produced in Turkey on patients.

MATERIAL and METHODS

Prosthesis Material

The system used in this study was produced by an orthopedy firm (Serbay Ortopedi - İstanbul/TURKEY). The femoral components used in the total hip prosthesis system was produced according to the dogs' weights in 6 different sizes, femur heads in 5 different sizes, metal acetabular cups in 4 different sizes (28, 30, 32, 34 mm) and in 4 different sizes of polyethylene acetabular cups compatible to them. The prosthesis sizes for the patients were decided by mesuring the proximal femural shafts modular diameter according to the dogs VD hip X rays. For a 9 mm diameter number 1 femural prosthesis, for a 10 mm diameter number 2 femural prosthesis, for a 11 mm diameter number 3 femural prosthesis, for 12 mm diameter number 4 femural prosthesis, for a 13 mm diameter number 5 femural prosthesis and for a 14mm diameter number 6 femural prosthesis was used. The body of the femur prosthesis were made of porous-coated 316L stainless steel. Three holes were opened in the mediolateral direction on the femur shaft for the application of the interlocking screw. Screw-joints were opened on the femur-neck, for the fixation of the interlocking taps. Acetabulum prostheses have been produced as a hemispheric structure. The ultra-high molecular weight of Poliethylene-acetabular cups were produced in 4 different sizes. They and the femur-heads have also been produced according to the press-fit system. All parts of the prosthesis systems were sterilized with ethyleneoxide, and stored.

Our study group was made up of 21 domestic dogs brought to the Istanbul University Veterinary Faculty-The Surgery Department-The Clinic of Small Animals, with hip complaints.

Methods

The owners of the patients have been kept informed about the prostheses which will be applied just after the patients' clinical and radiografic examinations. A day before the operation the application of parental antibiotics (Ceftrioxane sodium 20 mg/kg IM, sid, Rocephin flk, Roche, Turkey) were started. The postoperative antibiotic application was carried on for 7 days. The radiographic and clinical examinations were done first immediately after the operation, then after the 1st and 2nd month, and finally after a year on from the operation. The radiographic and clinical examinations were repeated if there were complaints from the patients' owners. The patients were positioned in lateral recumbency after anesthesia. A cranial-lateral approach was obtained on the hip joint. After the skin and the underskin tissues were opened, the superficial gluteal muscle was excluded and then by tenotomy of the deep gluteal muscle we reached the joint. A *"T"* incision was made to the joint capsula then the femur head and neck was taken out. The femoral neck excision was done with an angle of 130°, and it was widened to an apropriate size to the prosthesis with the help of a medular diameter reamer. Using different dimension openers, it was deepened as far as the acetabulum spongious bone. The suitable acetabular prosthesis chosen for the acetabulum was fixed at the retroversion angle of 15-20° with 3 cortical screws. Acetabular poliethylene prosthesis was also fixed to the metal prosthesis. The femur prosthesis was replaced in an apropriate position by knocking with a private knock-set. Later, a suitable femur head was chosen and replaced with the press-fit application. The femur neck was replaced into the poliethylene acetabular cup with pressure. The 3

cortical screws with help of the guidelines were replaced into the 3 holes which had been opened before on the prosthesis shaft in the craniocaudal direction. Having seen that the joint movement was normal, the operation ended by closing the tissues. After the operation we advised the patients owners to put their dogs in cage rest for 4 weeks, avoid excessive excersise for 8 weeks and only walk them with a leash for 16 weeks. The postoperative clinical evaluation was evaluated by the McCartney and Fox scale [22,23]: ''excellent" (no lameness, clinically normal), "good" (slight lameness after extensive exercise), "fair" (slight to moderate intermittent lameness but consistent weight-bearing), and "poor" (non-weight-bearing lameness).

RESULTS

In this study, one-sided hip prosthesis was applied on 21 dogs. The dogs belonged to 7 different breeds. The age variance of the patients were between 1 and 10 (2.7 age on average). Most of the cases were male dogs (90%). The dogs' weights were between 22-42 kg (34 kg on average) *(Table 1)*.

From the total number of patients we decided to apply hip prosthesis , there was osteolysis *(cryptococus granulomatoz osteomyelitis)* on femur head and neck depending on osteomyelitis on 1 patient, femur head and neck fracture on 2 patients, and on 18 patients there were secondary variations (osteoarthritis, sub-laxation, luxation) depending on hip displasia *(Table 2)*. Twelve of the applied prosthesis cases have continued their lives without any complications *(Fig. 1)*. We were informed that one of them (case no: 2) had died from another illness *(Erlichiosis)* 2 years after the operation. It has been indicated that on 7 of the cases, luxation had appeared between the 15 th-30th day after the operation; craniodorsal luxation in 6 of them, cranioventral luxation in 1 of them. The prosthesis materials were taken out from 5 of these 7 patients because their owners did not want a re-prosthesis application. The remaining 2 cases which had luxation were given second operations and the angles of their metal acetabular cups were changed. But, 15 days after the second operation, craniodorsal luxation was formed in one of the patients so the prosthesis materials were taken out completely. It was observed that case no 14 which had been reoperated after he had had cranioventral luxation has no problem and can use his leg normally.

On 1 of the 2 cases which THA was applied, acetabular cup loosening and on the other one aceptic femoral prosthesis loosening was found. A patient (case no: 4) which had acetabular cup loosening walked excellently up to 8 months after the operation and it had been said that he had no problems with his prosthesis. But later it was

Table 1. *Breed, age, sex variations of the cases (M-males, F-females)*
Tablo 1. *Olguların ırk, yaş, cinsiyet ve ağırlık dağılımı (M-erkek, F-dişi)*

Case No	Breed	Age (year)	Sex	Weight (kg)
1	Labrador Retriever	1. 5	M	42
2	Golden Retriever	10	M	37.5
3	Labrador Retriever	1	M	33
4	Rottweiler	2	M	42
5	German Shepherd Dog	2	F	22
6	Turkish Anatolian Sheep Dog	1. 5	M	40
7	Gordon Setter	5	M	25
8	German Shepherd Dog	1	M	30
9	Saint Bernard	2	M	50
10	Turkish Anatolian Sheep Dog	1	M	35
11	Golden Retriever	6	M	32
12	German Shepherd Dog	5	M	35
13	German Shepherd Dog	2	M	31
14	Turkish Anatolian Sheep Dog	2	F	33
15	Turkish Anatolian Sheep Dog	1	M	35
16	German Shepherd Dog	2	M	36
17	Rottweiler	1	M	30
18	German Shepherd Dog	2	M	28
19	Turkish Anatolian Sheep Dog	2. 5	M	36
20	Turkish Anatolian Sheep Dog	2	M	30
21	German Shepherd Dog	1	M	32

Table 2. *The prosthesis indications, the application results and the postoperative observation periods of the patients*
Tablo 2. *Hastaların protez endikasyonları, uygulama sonuçları ve post operatif takip süreleri*

Case No	Indication of the Prosthesis	Radiographic Symptoms	Functional Valuation of the Extremity	Post-op Patient Tracing Period
1	Hip dysplasia	No abnormal symptoms	Good	3.5 years
2	Osteomyelitis, depending on fungal infection	No abnormal symptoms	Excellent but died from another reason 2 years later	2 years
3	Hip dysplasia	Craniodorsal luxation	Poor. The prosthesis was removed	1 month
4	Hip dysplasia	Aseptic acetabular prosthesis loosening Radiolucent gap between metal acetabular shell and bone	Poor. The prosthesis was removed	1 year
5	Hip dysplasia	No abnormal symptoms	Good	3.5 years
6	Hip dysplasia	Craniodorsal luxation One month later the 2nd operation have made and dorsal luxation was observed again	Poor. The prosthesis was removed	2 months
7	Hip dysplasia	No abnormal symptom	Excellent	3 years
8	Hip dysplasia	Craniodorsal luxation	Poor. The prosthesis was removed	1 month
9	Hip dysplasia	Craniodorsal luxation	Poor. The prosthesis was removed	20 days
10	Hip dysplasia	Radiolucent gap in the femoral stem shaft and osteolysis Aseptic loosening in the femur prosthesis	Poor. The prosthesis was removed	13.5 months
11	Hip dysplasia	No abnormal symptoms	Good	3 years
12	Hip dysplasia	No abnormal symptoms	Good	3.5 years
13	Hip dysplasia	No abnormal symptoms	Excellent	3.5 years
14	Hip dyspasia	Cranioventral luxation. The 2nd operasion done	Excellent	2 years
15	Hip dysplasia	Craniodorsal luxationon	Poor. The prosthesis was removed	1 month
16	Hip dysplasia	Osteophytic growth in the femur stem proximal	Good	3 years
17	Femur head-neck fractura	No abnormal symptoms	Good	2.5 years
18	Femur head-neck fractura	No abnormal symptoms	Good	3.5 years
19	Hip dysplasia	In the femur stem proximal, osteophytic growth as trochanter minor level	Good	3 years
20	Hip dysplasia	No abnormal symptoms	Good	2.5 years
21	Hip dysplasia	Craniodorsal luxation	Poor. The prosthesis was removed	1 month

said that there had been some lameness and pain on the hip joint area. In the clinical examination of this patient, it was observed that there was an extension and flexion of the extremity, and pain on the rotation movements of the joint. In the radiographic examination it was noticed that there was a radiolucent gap between the metal acetabular cup and the bone *(Fig. 2)*, It was adviced that a non-steroid anti-inflammatory drug be given to the patient (carprofen 2.2 mg/kg, PO, bid, Rimadyl, Pfizer-Turkey). Because of the continuation of lameness and pain, the prosthesis was removed. The hip variances according to the hip displasia had been found on the other hip of this case before and triple-pelvic osteotomy had been applied. It was brought to our attention that on one patient aseptic femur prosthesis loosening was detected (case no:10) but used its extremity excellent and had no problems until a year after the operation but after that period lameness was seen. In the clinical examination of the patient, it was observed that there was a pain especially in the femur prosthesis part, and lameness was found. In the radiographic examination, we identified that there was a radiolucent gap and osteolysis in the part of the femur prosthesis shaft. Thinking about the possibility of postoperative late-stage infection, it was suggested to be given a wide-spectrum antibiotics (cephalexin 20 mg/kg, PO, bid, Maksipor tabl. Fako - Turkey) and a nonsteroid anti-inflammatory (carprofen 2.2 mg/kg, PO, bid, Rimadyl, Pfizer - Turkey) for 15 days. No healing was seen for about 1 month, and in the re-taken radiographies, there were more obvious aseptic loosening symptoms so the prosthesis was removed. The observation period of the patients were between 1 month - 3.5 years (2 years on average). Observing the patients was carried out by either calling them to the clinic or with the information taken by phone.

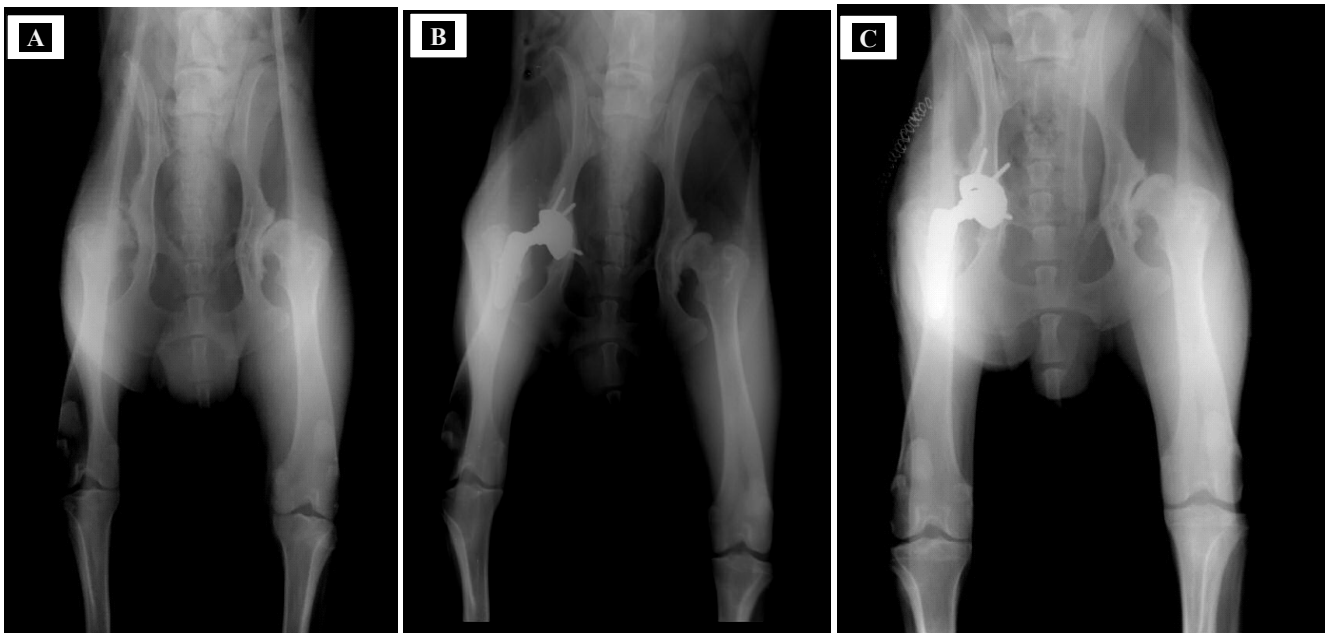

Fig 1. The case no 7: A-Preoperative, B-Just postoperative, C-The X-ray of postoperative 8 months later
Şekil 1. Olgu no 7' nin: A-Preoperatif, B-Hemen postoperatif, C-Postoperatif 8 ay sonraki görünümü

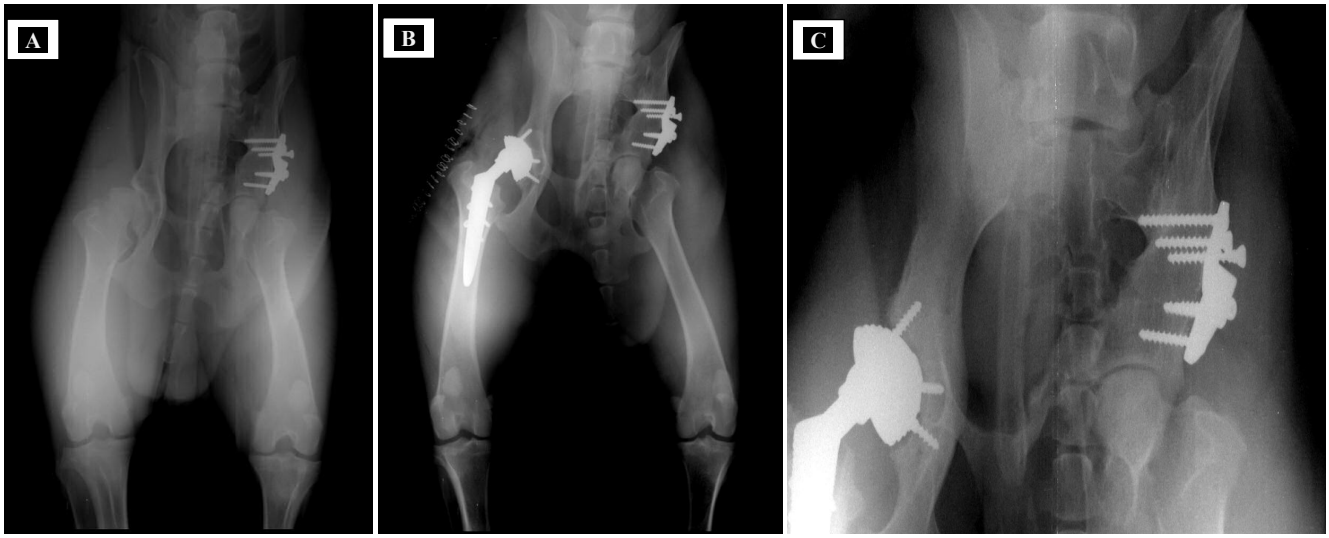

Fig 2. The case no 4: A- Preoperative, B- Just postoperative, C- 1 year later aseptic acetabular prosthesis loosening
Şekil 2. Olgu no 4'ün: A- Preoperatif, B- Hemen postoperatif, C- 1 yıl sonra aseptik asetabular protez gevşemesi

According to the patients' clinical evaluation, the clinical situation of 4 patients are excellent, 9 are good, and 8 are poor. It has been indicated that the femoral stem position of 5 cases were in varus and in the other 16 cases in neutral position. On 3 cases where varus position was found we detected dorsal luxation forming. In the postoperative ventro-dorsal position, the lateral-opening angle variance measured is between 45°-65° (on avarage 57°) *(Table 3)*.

In both cases (case no 16 and 19), it has been identified that there have been some growth in the area of femoral stem. But it has been detected that they have not shown a functional disorder.

DISCUSSION

The long term failure rate associated with early cementing techniques was high, ranging from 10% - 50% after 10-15 years. To avoid using Polymethylmethacrylate [24] uncemented THA techniques have been developed partly. With this aim, porous, hydroxy apatite, tri-calcium phosphate coated and carbon fibre prostheses have been developed and used [8,10-12,19,25,26]. To avoid the complications caused by cemented prosthesis, with the aim of making a prosthesis that will stay for a longer time and is more tissue-friendly (biologically), porous-coated (femur and

Table 3. *The femoral stem positions and the widening angles of acetabulum (in ventro-dorsal position)*
Tablo 3. *Femur'un stem pozisyonları ve asetabulumun lateral açılma açıları (ventro-dorsal pozisyonda)*

Case No	Position of the Prosthesis	Lateral Opening Angle (^{o})	Femoral Stem Position
1	Normal	~55	Varus
2	Normal	~50	Neutral
3	Luxation	~45	Neutral
4	Aseptic acetabular prosthesis loosening	~50	Neutral
5	Normal	~60	Varus
6	Luxation	~55	Varus
7	Normal	~50	Neutral
8	Luxation	~50	Varus
9	Luxation	~50	Neutral
10	Aseptik femur prosthesis loosening	~58	Neutral
11	Normal	~60	Neutral
12	Normal	~60	Neutral
13	Normal	~60	Neutral
14	Luxation	~55-60 (Revision angle)	Neutral
15	Luxation	~45-50 (Revision angle)	Neutral
16	Normal	~58	Neutral
17	Normal	~60	Varus
18	Normal	~55	Neutral
19	Normal	~65	Neutral
20	Normal	~55	Neutral
21	Luxation	~60	Neutral

acetabulum metal prostheses) and a biologic prosthesis material which will combine with the bone in time (osseo-integration) have been used in this study. Two approaches have been described most commonly for canine total hip arthroplasty. Most of these preferred choices are with the craniolateral aproach, deep gluteal muscle tenotomy or trochanteric osteotomy [4]. With the trochanteric osteotomy approach being easier to uncover the area because of the excess of the complications that can occur after, we have used deep gluteal osteotomy application, and we have not come across with any problems.

The most common indication for THA was hip dysplasia and secondary arthritis (96%). Other indications included hip luxation (1.6%), femoral head and neck fracture (1.6%), revision of femoral head ostectomy (0.8%), revision of triple pelvic osteotomy [6,27]. Paralled to the resources, there was hip dysplasia and seconder osteoarthritis (85%) in most of the cases that makes up our study.

Papers in canine THA suggest variable degrees of exercise restriction for up to 2 months after the surgical procedure and the avoidance of situations that might lead to luxation of the prosthesis [4]. According to some reports post-operative exercise regimens vary from minimal walking to specific THA weight training programs. Patients with THA are most often restricted to partial weight bearing for the first 6 weeks after surgery. Depending on the inadequacy of the soft tissues, the inhibition period of movement can be prolonged up to 4 months [4,6]. In this study, to the owners of the dogs applied THA, we adviced cage-rest particularly as long as 1 month postoperation, and definitely to avoid excessive movements like jumping, running or jumping high for 2 months and have their dogs walked with a leash. But because most of the dogs being young (aged ≤2) and the fact that they are dogs that are looked after at factories we understood the warnings would not be taken seriously enough and could not be applied. Therefore, we have concluded that it is nesessary to be more careful in the patient choice for hip prosthesis and that this is an important criteria that can affect the success of positive application.

The most significant risk factors for postoperative luxations are acetabular malalignment, inadequate soft tissue tension, impingement, prior joint replacement and surgical approach, insufficient reaming of the acetabulum resulting in a poorly placed acetabular cup (with reduced dorsal support) predisposed to luxation after canine THA [18]. In our study, the complication we have most often come across was the luxation of the prosthesis. 6 of them were craniodorsal and 1 of them was cranioventral. All of the Luxations occuring in a period of 1 month post-operation, brings many reasons into mind. One of the most important

among them is that the idea of poorly made postoperative limitations. Cross et al.[17], in his study, identifies that the rate of luxation while in normal hips is 0%, in dysplastic hips it is 5% - 10.2%. We think that the most important reason of high luxation rate in this study is that most of the cases had no normal hip, bone and soft tissue structures. Especially luxation depending on hip displasia and in the case of sub-luxation, it is seen that muscle groups of hip area are weak and loosening which does not provide sufficient hip prosthesis stability in the postoperative period.

The lateral opening angle should be assessed on post operative radiographs. For the lateral opening optimum recommended angle is 45° [6]. In our study, in 2 cases an angle of 45° was obtained but in one of them craniodorsal luxationhas occured. But it was detected that in most of the cases this angle is 60° and below.

In the sources, it has been recomended that lateral opening angle must be between 45°-60°, otherwise when over 60°, the risk of luxation will increase and also it has been said that the postoperative period should be lenghtened up to 4 months [4]. In our study during the operation, to decrease this angle we tried to replace the acetabular cup with a retroversion of 15°-20°. But on one case the cranioventral luxation occured because of the increase in the retroversion angle and the non-suitable acetabular cup position.

Correct acetabular component positioning may be critical in maintaning implant congruency because errors in acetabular positioning have been reported to be associated with luxation of implant [17]. If abnormal joint laxity is identified, the cause should be defined and addressed appropriately at that stage by, for example, caudolateral transposition of deep gluteal tendon, soft tissue imbrication, suturing joint capsule to trochanteric soft tissues or trochanteric bone tunnels, selection of a longer femoral neck, acetabular revision, or distolateral translocation of the greater trochanter [6]. In our study, to decrease the luxation risk in the end of the operation, tighten the soft tissues, stitching application of the joint capsula and the areal tissues to the trochanteric soft tissues were made in all cases.

A number of different treatments for THA luxation has been described: closed reduction and application of an Ehmer sling, open reduction and capsuloraphy, revision of acetabular position (directly or by triple pelvic osteotomy), removal of prosthesis and use of cortical outograft from the wing of ipsilateral ilium [28]. In total hip prosthesis luxations, we have tried closed-reduction revision techniques in a few cases as indicated by the researchers but we were not successful. We are thinking that not knowing when the dislocation cases happen exactly is effective on this unsuccess. Acetabular position revision has been done with another operation in both cases. But success was obtained in one of them.

Periprosthetic bone resorption or osteolysis is the dominant cause of implant failure in total hip arthroplasty. Cementless fixation of acetabular component has evolved and has become increasingly populer. Minimizing micro-motion at the bone-implant interface to a critical level is essential for bone ingrowth into porous-coated prosthesis [26]. Aseptic loosening is also an important cause of implant failure in dogs. Incidences of aseptic loosening from 7% to 22% have been reported [29]. Resorptive changes surrounding porous coated implants in the proximal portion of the femur have been described in previous studies using dogs. The remodelling and resorption of bone in the proximal portions of femur implanted with uncemented prosthetic stems may be explained by stres shielding. Aseptic loosening has been attributed to a biological reaction to wear debris, spesifically polyethylene particles, that stimulate inflamatory mediators (cytokines) which mediate bone resorption [1]. Other factors may include toxicity of wear products from artificial materials, large implant diameter relative to the host femur and surgical injury [11]. The two aseptic loosening problems in our studies that we have come across have been identified between the 8th and the 12th months. Materials removed in the operation, and a black and sticky material on the bone have been located. It has been thought that this material, as mentioned in the sources, may belong to the erosion products of the prosthesis material and the reaction between the bone layers.

In conclusion, with the THA application which has been produced in our country and used for the first time, we have obtained a success rate of 57%. When comparing with the other studies, it is seen that this ratio is low. But using more qualified prosthesis material, chosing the cases more carefully and using the gained experience better, we believe that the rate of success will increase.

REFERENCES

1. Hanson SP, Peck JN, Berry CR, Graham J, Stevens G: Radiographic evaluation of the Zurich cementless total hip acetabular component. *Vet Surg,* 35 (6): 550-558, 2006.

2. Warnock JJ, Dyce J, Pooya H, Schulz KS: Retrospective analysis of canine miniature total hip prostheses. *Vet Surg,* 32 (3): 285-291, 2003.

3. Liska DW: Micro total hip replacement for dogs and cats: Surgical technique and outcomes. *Vet Surg,* 39 (7): 797-810, 2010.

4. Schulz KS: Application of arthroplasty principles to canine cemented total hip replacement. *Vet Surg,* 29 (6): 578-593, 2000.

5. DeYoung DJ, DeYoung BA, Aberman HA, Kenna RV, Hungerford DS: Implantation of an uncemented total hip prosthesis technique and initial results of 100 arthroplasties. *Vet Surg,* 21 (3): 168-177, 1992.

6. Dyce J, Wisner ER, Wang Q, Olmstead LM: Evaluation of risk factors for luxation after total hip replacement in dogs. *Vet Surg,* 29 (6): 524-532, 2000.

7. Viceconti M, Ricci S, Pancanti A, Coppello A: Numerical model to predict the long-term mechanical stability of cementless orthopaedic implants. *Med Biol Eng Comput,* 42 (6): 747-753, 2004.

8. Dorr LD, Wan Z, Song M, Ranawat A: Bilateral total hip arthroplasty comparing hydroxyapatite coating to porous - coated fixation. *J*

Arthroplasty, 13 (7): 729-736, 1998.

9. Gross KA, Walsh W, Swarts E: Analysis of retrieved hydroxyapatite-coated hip prostheses. *J Therm Spray Technol,* 13 (2): 191-199, 2004.

10. Park YS, Lee JY, Yun SH, Jung MW, Oh I: Comparsion of hydroxy-apatite-and porous-coated stems in total hip replacement. *Acta Orthop Scand,* 74 (3): 259-263, 2003.

11. Bouvy BM, Manley PA: Vascular and morphologic changes in canine femora after uncemented hip arthroplasty. *Vet Surg,* 22 (1): 18-26, 1993.

12. Roberson JR, Spector M, Baggett MA, Kita K: Porous-Coated femoral components in a canine model for revision arthroplasty. *J Bone Joint Surg Am,* 70 (8): 1201-1208, 1988.

13. Liska WD, Poteet BA: Pulmonary embolism associated with canine total hip replacement. *Vet Surg,* 32 (2): 178-186, 2003.

14. Preston AC, Schulz SK, Vasseur PB: Total hip arthroplasty in nine canine hind limb amputees: A retrospectiv study. *Vet Surg,* 28 (5): 341-347, 1999.

15. Liska WD: Femur fractures associated with canine total hip replacement. *Vet Surg,* 33 (2): 164-172, 2004.

16. Sebestyen P, Marcellin-Little DJ, DeYoung BA: Femoral medullary infarction secondary to canine total hip arthroplasty. *Vet Surg,* 29 (3): 227-236, 2000.

17. Cross AR, Newell SM, Chambers JN, Shultz KB, Kubilis PS: Acetabular component orientation as an indicator of implant luxation in cemented total hip arthroplasty. *Vet Surg,* 29 (6): 517-523, 2000.

18. Hayes GH, Ramirez J, Hobbs SJL: Does the degree of preoperative subluxation or soft tissue tension affect the incidence of postoperative luxation in dogs after total hip replacement. *Vet Surg,* 40 (1): 6-13, 2011.

19. Yee AM, Protzner K, Fornasier VL, Binnington AG, Bogoch E, Davey JR: Cementless acetabular fixation in total hip arthroplasty using polyglycolide-lactide screws: An *in vivo* canine study. *J Arthroplasty,* 15 (4): 496-504, 2000.

20. El-Warrak AO, Olmstead ML, Von Rechenberg B, Auer JA: A review of aseptic loosening in total hip arthroplasty. *Vet Comp Orthop Traumatol,* 14, 115-124, 2001.

21. Edwards MR, Egger LE, Schwarz PD: Aseptic loosening of the femoral implant after cemented total hip arthroplasty in dogs: 11 cases in 10 dogs (1991-1995*). J Am Vet Med Assoc,* 211 (5): 580-586, 1997.

22. McCartney WT: Use of modified acrylic external fixator in 54 dogs and 28 cats. *Vet Rec,* 143, 330-334, 1998.

23. Fox SM, Bray JC, Guerin SR, Burbridge HM: Antebrachial deformities in the dog: Treatment with external fixation. *J Small Anim Pract,* 36, 315-320, 1998.

24. Marcellin-Little DJ, DeYoung BA, Doyens DH, DeYoung DJ: Canine uncemented porous-coated anatomic total hip arthroplasty: Results of a long-term prospective evaluation of 50 consecutive cases. *Vet Surg,* 28 (1): 10-20, 1999.

25. Maistrelli GL, Mohamed N, Garbuz D, Fornasier V, Harrington IJ, Binnigton A: Hydroxyapatite coating on carbon composite hip implants in dogs. *J Bone Joint Surg Br,* 74 (3): 452-456, 1992.

26. Yee A, JM, Protzner K, Fornaiser VL, Binnington AG, Bogoch E, Davey JR: Cementless acetabular fixatian in total hip arthroplasty using polyglycolide-lactide screws: An *in vivo* canine study. *J Arthroplasty,* 15 (4): 496-504, 2000.

27. Ganz SM, Jackson J, VanEnkevort B: Risk factors for femoral fracture after canine pres-fit cementless total hip arthroplasty. *Vet Surg,* 39 (6): 688-695, 2010.

28. Torres BT, Chambers JN, Budsberg SC: Successful cementless cup reimplantation using cortical bone graft augmentation after an acetabular fracture and cup displacement. *Vet Surg,* 38 (1): 87-91, 2009.

29. Margalit KA, Hayashi K, Jackson J, Kim SY, Garcia TC, TomoWiggans MSK, Aiken S, Stover SM: Biomechanical evaluation of acetabular cup implantation in cementless total hip arthroplasty. *Vet Surg,* 39 (7): 818-823, 2010.