Kafkas Univ Vet Fak Derg
19 (4): 613-618, 2013
DOI: 10.9775/kvfd.2013.8406

Journal Home-Page: http://vetdergi.kafkas.edu.tr
Online Submission: http://vetdergikafkas.org

RESEARCH ARTICLE

Effect of Hyaluronic Acid/Carboxymethylcellulose and Flunixin Meglumine Combination on the Prevention of Postoperative Intraabdominal Adhesions: An Experimental Study in Rabbits [1]

Mustafa KÖM [1]

[1] *This study was presented in "IV th Congress of Veterinary Gynecology (International Participation), November 4-7, 2010, Belek, Antalya - TURKEY"*

[1] Firat University, Faculty of Veterinary Medicine, Department of Surgery, TR-23200 Elazığ - TURKEY

Makale Kodu (Article Code): KVFD-2013-8406

Summary

Despite the development in the knowledge concerning pathophysiology of abdominal cavity and improvement in surgical techniques, intraabdominal adhesions are one of the most common complications in surgery. The aim of this study was to determine the effects of hyaluronic acid/carboxymethylcellulose (HA/CMC) and flunixin meglumine combination on the prevention of postoperative intraabdominal adhesions in rabbits. All the surgery were made under aseptic condition under general anesthesia. A 2x2 cm area of parietal peritoneum was resected on the abdominal wall after median laparotomy. Twenty-four adult, male rabbits were divided into four groups equally. Groups were evaluated as C (control), S (HA/CMC), F (flunixin meglumine), and SF (HA/CMC and flunixin meglumine combination). No medication was given to the rabbits in group C. In S and SF groups, 3x3 cm of HA/CMC applied directly to peritoneal defect. In F and SF groups, flunixin meglumine was administred 1.1 mg/kg for 5 days intraperitoneally. Relaparotomy was performed 10 days after surgery. As a result of macroscopical and histopathological evaluations, the scores of adhesion in the S, F, and SF groups were significantly lower than those of the control group ($P<0.05$). Adhesion scores in SF group were lower as compared to S and F groups ($P<0.05$). It is observed that HA/CMC and flunixin meglumine combination can be used more effective on the prevention of postoperative intraabdominal adhesions in rabbits.

Keywords: *Intraabdominal adhesion, Hyaluronic acid/carboxymethylcellulose, Flunixin meglumine, Rabbit*

Postoperatif İntraabdominal Adezyonların Önlenmesinde Hyaluronik Asit/Karboksimetilselüloz ve Fluniksin Meglumin Kombinasyonu'nun Etkisi: Tavşanlarda Deneysel Bir Çalışma

Özet

Abdominal boşluğun patofizyolojisi konusunda bilgilerin artmasına ve cerrahi tekniklerin gelişmesine rağmen intraabdominal adezyonlar, cerrahideki en önemli sorunlardan biridir. Bu çalışmada, tavşanlarda postoperatif intraabdominal adezyonların önlenmesinde hyalüronik asit/karboksimetilselüloz (HA/KMS) ve fluniksin meglumine kombinasyonunun etkisinin değerlendirilmesi amaçlandı. Tüm operasyonlar genel anestezi eşliğinde aseptik koşullar altında yapıldı. Median laparotomiden sonra abdominal duvar üzerinden 2x2 cm'lik bir parietal periton alanı rezeke edildi. Çalışmada 24 adet yetişkin erkek tavşan 4 gruba eşit olarak ayrıldı. Gruplar; C (kontrol), S (HA/KMS), F (fluniksin meglumine), ve SF (HA/KMS ve fluniksin meglumine kombinasyonu) olarak değerlendirildi. Kontrol grubundaki olgulara herhangi bir tedavi uygulanmadı. S ve SF gruplarındaki olguların defektli alanları 3x3 cm'lik HA/KMS ile örtüldü. F ve SF gruplarına, fluniksin meglumine 1.1 mg/kg dozunda intraperitoneal olarak 5 gün süre ile verildi. Postoperatif 10. günde tekrar laparotomi yapıldı. Makroskobik ve histopatolojik değerlendirmeler sonucunda; S, F, and SF gruplarındaki adezyon skorları kontrol grubundakine oranla önemli derecede düşük bulundu ($P<0.05$). SF grubundaki adezyon skorları, S ve F grupları ile karşılaştırıldığında daha düşük olduğu saptandı ($P<0.05$). Tavşanlarda postoperatif intraabdominal adezyonların önlenmesinde HA/KMS ve fluniksin meglumine kombinasyonun daha etkili olduğu gözlendi.

Anahtar sözcükler: *İntraabdominal adezyon, Hyalüronik asit/karboksimetilselüloz, Fluniksin meglumine, Tavşan*

İletişim (Correspondence)
+90 424 2370000/3882
mkom@firat.edu.tr

INTRODUCTION

Adhesions are fibrous bands that cause separate organs to adhere to one another and can be classified into congenital, inflammatory, and postoperative. Postoperative adhesions are considered to be an inevitable result of surgery. The incidence of postoperative adhesion ranges from 66 to 93% after operations [1-3]. Surgical trauma, tissue ischemia, hemorrhage, infection, and foreign materials play an important role in etiology of postoperative adhesions. Postoperative intraabdominal adhesions cause chronic abdominal/pelvic pain, female infertility, and small bowel obstruction. Also, fibrous adhesions make prolong operation time, operation difficulty, increased bleeding, intestinal rupture, and morbidity in repeated operations [1-5].

When there is an injury in mesothelial surface of the peritoneum, it triggers an inflammatory reaction characterized by increased neutrophil leucocytes, fibroblasts, macrophages, and mesothelial cells. There is increase in vascular permeability and release of fibrin-rich exudate. Peritoneal mesothelial cells have a critical duty in maintaining the intraperitoneal balance between fibrinolysis and formation. Plasminogen is an important protein in the process of fibrinolysis. Early fibrinolysis, within 5 days, encourages healing of the peritoneum without adhesion formation. Inadequate fibrinolysis processes lead to persistent fibrin structures that subsequently mature into fibrous tissue, followed by organization into rigid, persistent fibrous adhesions containing blood vessels and nerve fibers [1-6].

Many different techniques, agents, and materials have been tried to reduce adhesions [1-3,6-9]. Several pharmacological drugs including corticosteriod, non-steroid antiinflammatory drugs (NSAIDs), melatonin, progesterone, aprotinin, methylen blue, heparin, mitomycin C, vitamin E, and tPA have been used to prevent adhesions [1,2,8,10,11]. NSAIDs inhibit prostaglandin and thromboxane synthesis by changing cycloxygenase activities. Flunixin meglumine (non-selective COX inhibitors) are commonly used to treat animals suffering from various diseases and has been proved to prevent the formation of peritoneal adhesions in studies [1,2,7,9-12]. Mechanical barriers such as carboxymethylcellulose, hyaluronic acid, icodextrin, polyethylene glycol, fibrin glue, oxidized regenerated cellulose, expanded polytetrafluoro ethylene, and hyaluronic acid/carboxymethylcellulose (HA/CMC) have been applied to prevent adhesion by mechanically minimizing the development of fibrin between serosal surfaces [1,2,6,13]. HA/CMC is a biosynthetic material that have been widely used in human and animals. In developed countries, HA/CMC is accepted as an important antiadhesive barrier. Unfortunately, none of these treatments is ideal [1-3,5,8,9,14-16].

Although several substances have been tried to eliminate adhesions, these have had a limited success in the intraabdominal adhesions. A current interest to overcome adhesions have been focused on various combination of drugs [2,4,8,9,17-23]. Therefore, it was to investigate the effect of HA/CMC, flunixin meglumine and their combination on the prevention of postoperative intraabdominal adhesions in rabbits.

MATERIAL and METHODS

Animals

Twenty-four rabbits weighing approximately 2.8-3.6 kg were used in this study. The rabbits were hospitalized for 2 weeks with a deprivation of food for 12 h immediately before surgery. The animals were kept under standart conditions and had free access to water and pellets. The study protocol was approved by Animal Ethic Committee of the Veterinary Faculty, Firat University (2006/7).

Anesthesia

The animals were anesthetized with 10 mg/kg of xylazine HCl (Rompun®, Bayer, İstanbul, Turkey) and 40 mg/kg of ketamine HCl (Ketalar®, Eczacıbaşı, İstanbul, Turkey) intramuscularly.

Surgical Procedure

All the surgery were performed under aseptic conditions, including an iodine scrub, drapping and use of a steril technique. Powder-free gloves were used for the operation. Following complete aseptic preparations, a 5-6 cm of incision was performed for midline laparotomy. A 2x2 cm area of parietal peritoneum was removed on the right abdominal wall. The animals were divided into four groups, each containing 6 rabbits: group C (control), group S (HA/CMC), group F (flunixin meglumine), and group SF (HA/CMC and flunixin meglumine combination). No medication was applied to the control group. HA/CMC (Seprafilm®, Genzyme, USA) 3 cm x 3 cm were placed on the deperitonized area of abdominal wall in S and SF groups. Flunixin meglumine (Finadyn®, Eczacıbaşı, İstanbul) was given 1.1 ml/kg for 5 days in F and SF groups intraperitoneally. The abdomen was closed with continuous sutures with 2/0, and skin was closed with interrupted 2/0 polypropilene sutures (Monofilament polyglytone, Caprosyn™, USA).

All animals were sacrified on the 10th days after operation. After performing a U-type incision to the anterior abdominal wall, the evaluation was macroscopically classified according to adhesion scoring system described by the Majuzi and colleagues [24]. The degree of adhesion formation was evaluated with the following adhesion scores: 0=no adhesion, 1=light adhesions can be easily removed through blunt dissection, 2=moderate adhesions which need sharp dissections (lower than 50%) for the separation, 3=severe adhesions which need

sharp dissections (more than 50%) for the separation, 4=presence of serosal injury, 5=presence of full-thickness injury.

Histopathological Evaluations

Peritoneal tissue samples containing adhesion were excised and the samples were fixed in 10% formaldehyde solution. After dehydration, the specimens were embedded in paraffin blocks. Then, 5 µm sections in thickness were prepared using a microtome and stained with Hematoxylin and Eosin (H&E). Histopathological evaluations were performed under a light microscope by one pathologist who was blind to groups according to semiquantitative scoring system described by Hooker and colleagues [25]. The histopathological adhesions were categorized as Grades 0–III based on the presence and extent of fibrosis and inflammation. Grade 0 was defined as no fibrosis, grade I as mild fibrosis, grade II as moderate fibrosis, and grade III as severe fibrosis. The grade of inflammation was assessed according to grade I on this scale represents a mild inflammatory reaction with giant cells, occasionally scaretted lymphocytes, and plasma cells, grade II represents moderate reaction with giant cells and increased admixed lymphocytes, neutrophiles, eosinophiles and plasma cells, and grade III represents a severe inflammatory reaction with microabscesses present.

Statistical Analysis

The group data were analyzed using the Kruskal-Wallis nonparametric test. Differences among the groups were evaluated using Mann-Whitney U test. Differences with a value of $P<0.05$ were considered to be statistically significant. Data were analyzed by SPSS software program (Version 14.0; SPSS Inc, Chicago IL).

RESULTS

Most of the animals tolerated the surgery well. No death was observed throughout the study period. There was no evidence of any of complication in the animals. The results of macroscopic and histopathologic evaluation are summarized in *Table 1*.

There were no adhesions in Grade 0, 1 or 2 in the control group. The adhesions in the control group were mostly Grade 3 or 4. In one case in control group, adhesion

Table 1. *The statistical results of adhesion, fibrosis, and inflammation scores*
Tablo 1. *Adezyon, fibrozis ve yangı skorlarının istatistiksel sonuçları*

Parameters	Groups				P Value
	C	S	F	SF	
Macroscopic	3.56±0.89[a]	1.83±0.75[b]	2.00±0.89[b]	1.05±0.89[c]	0.002
Fibrosis	2.50±0.55[a]	1.50±0.55[b]	1.33±0.52[b]	1.18±0.00[b]	0.003
Inflammation	2.50±0.55[a]	1.52±0.55[bc]	1.23±0.52[b]	0.93±0.41[c]	0.002

Superscripts a-c indicate that means in the same line without a common superscript differ significantly (P<0.05)

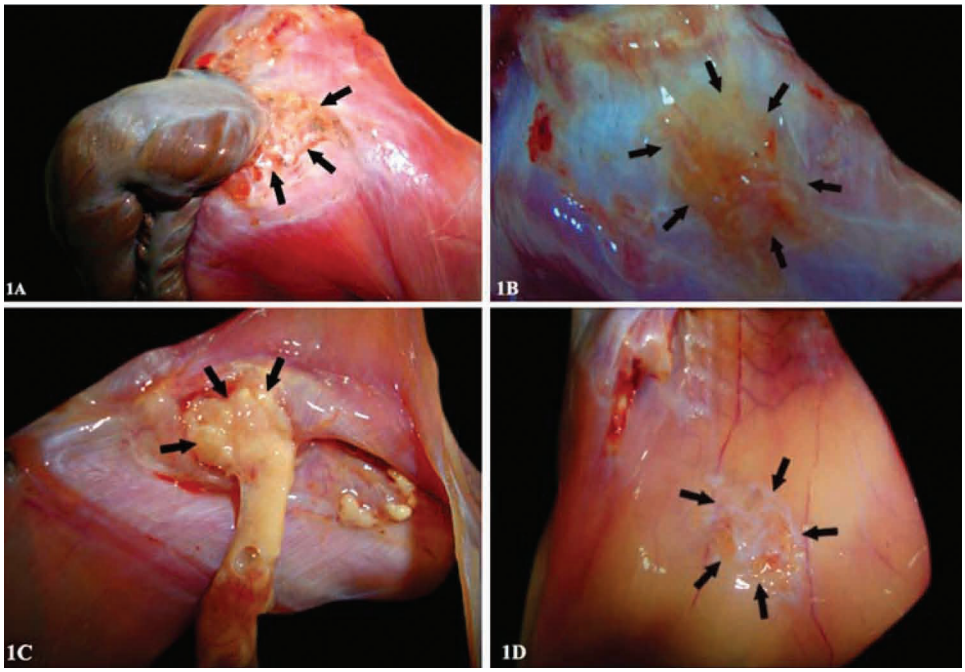

Fig 1. Macroscopical evaluations: **A)** Presence of full-thickness injury and large area of fibrosis *(arrows)* with score 5 in C group, **B)** Slight adhesion *(arrows)* with score 1 in S group, **C)** Severe adhesion which need sharp dissections (more than 50%) for the separation with score 3 in F group, **D)** No adhesion occurence with score 0 in SF group

Şekil 1. Makroskobik değerlendirmeler. **A)** C grubundaki 5. derece adezyonlu geniş fibrozis *(oklar)* ve tam kat adezyon varlığı, **B)** S grubundaki 1. dereceli hafif adezyon *(oklar)* görünümü, **C)** F grubundaki 3. derecedeki ayrılma için keskin diseksiyona (%50 den daha fazla) ihtiyaç gösteren ciddi adezyonun görünümü, **D)** SF grubundaki adezyonun yokluğu (0 derece)

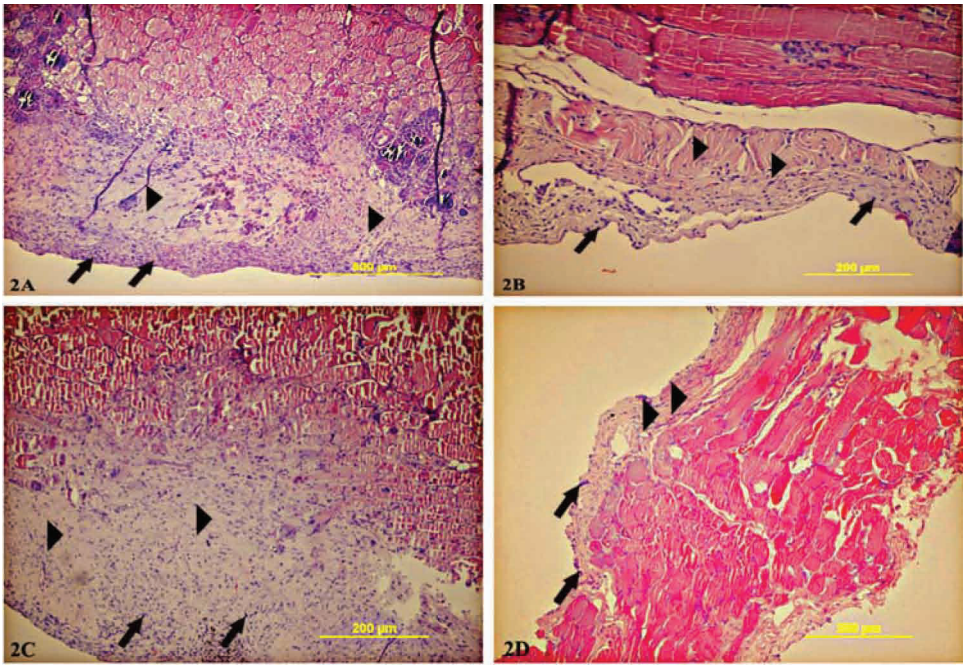

Fig 2. Histopathological evaluations. **A)** Severe fibrosis *(arrow heads)* and inflammatory changes *(arrows)* in C group, Grade III, **B)** Mild fibrosis *(arrow heads)* and mild inflammatory changes *(arrow)* in S group, Grade 1, **C)** Severe fibrosis *(arrow heads)* and inflammatory changes *(arrows)* in F group, Grade III, **D)** Mild fibrosis *(arrow heads)* and no inflammatory changes *(arrows)* in SF group

Şekil 2. Histopatolojik değerlendirmeler. **A)** C grubundaki şiddetli fibrosis *(ok başı)* ve yangısal değişiklikler *(ok)*, **B)** S grubundaki hafif fibrozis *(ok başı)* ve yangısal değişiklikler *(ok)*, **C)** F grubundaki şiddetli fibrozis *(ok başı)* ve yangısal değişiklikler *(ok)*, **D)** SF grubundaki hafif derecedeki fibrosis *(ok başı)* ve yangısal bulgu yokluğu *(ok)*

in Grade 5 was recorded *(Fig. 1-A)*. On the other hand, there were no adhesions in Grade 4 or 5 in the S, F, and SF groups. Most adhesion scores in the S and F groups were grade 1, 2, and 3 *(Fig. 1-B-C)*. Adhesion scores in the SF group were seen 2 cases in Grade 1 and 2. No adhesion was noted in 2 cases in the SF group *(Fig. 1-D)*. Statistical analysis indicated that adhesion scores were significantly lower in S, F, and SF groups when compared to the control group ($P<0.05$). A statistically significant difference was not observed between groups S and F ($P>0.05$). Group SF showed the lowest incidence of adhesions as compared to S and F groups macroscopically ($P<0.05$).

Severe fibrosis and inflammatory changes were seen in control group *(Fig. 2-A)*. Minimal fibrosis and low degree of inflammation were observed in the S, F, and SF groups *(Fig. 2 B-C)*. Statistical evaluation of fibrosis scores showed significant difference in S, F, and SF groups when compared to the control group ($P<0.05$). On the other hand, there was not significant difference between scores of fibrosis in SF group compared to that of S and F groups ($P>0.05$). However, there was a significant difference between the degrees of adhesion and inflammatory changes in SF group compared to S group ($P<0.05$), *(Fig. 2-D)*.

DISCUSSION

Despite the development in the knowledge concerning pathophysiology of abdominal cavity and improvement in surgical techniques, postoperative intraabdominal adhesions are significant health problem with major adverse effects on quality of life, use of health care resources, and financial costs after laparotomy [1-4,7-9,18,21].

There are many experimental models for the development of inflammatory and postoperative adhesions including the local peritoneal model, the damaged uterine horn, introduction of foreign objects in the abdominal and pelvic cavity, the direct mechanical intestinal damage, the ileal transection, the thermal damage, the large bowel anastomosis, the bacterial contamination, and the scraping models [16,17,19,20,22]. In this study, the parietal peritoneal model was chosen due to the similarities of the physiopathology after abdominal surgery. Since, it was observed that all cases in the control group occurred different degrees of adhesion.

Various studies have pointed out that the adhesion-forming process and mesotheliozation are completed after 7 to 14 days following surgery [10,17,23,26]. Therefore, it was chosen to wait 10 days before performing relaparotomy because other studies had shown high adhesion scores at the period of this time [4,5,27]. There have many adhesion scoring systems described by researchers in experimental models [4-6,16,17,22]. Macroscopical and histopathological evaluations were made according to semiquantitative scoring systems that had been described by Mazuji et al.[24] and Hooker et al.[25]. To date mentioned evaluations which have been used by many reseachers [4,22,23] is simple and suitable scoring systems for use in experimental studies.

The peritoneal healing process differs from skin healing process, whose differences actually came from the reepithelization, and consequences of fibrin depositon. Intraabdominal adhesions are formed as a result of tissue inflammation, fibrin deposition, fibrin organization, collagen formation and maturation [2,3,6,7]. Surgical trauma initiates a widespread inflammatory response in the peritoneum that is associated with the recruitment and activation of inflammatory cells, and the secretion of proinflammatory

mediators. Peritoneal inflammation leads to the formation of an inflammatory exudate. The increase of vessel permeability produces an outpouring of serosangineuous excudate rich in inflammatory cells. These cells promotes the formation of a fibrin-rich matrix at the sites of peritoneal injury that leads to the formation of fibrinous adhesions and eventually permanent adhesions [1,-3,7,22].

It is important to use minimal invasive surgery techniques and various agents to diminish the post-operative adhesions. These techniques and equipments have focused mainly on limiting tissue injury, like keeping the tissues moist, removing of foreign materials, avoiding of desication/ischemia, and using of laparoscopy. The roles of pharmacogical drugs are diminishing inflammatory response, enhancing fibrinolysis, preventing collagen deposition and maturation [1-4,6]. NSAIDs decrease vascular permeability, platelet aggregation, plasmine inhibitor and coagulation, and enhance macrophage function [1,2,7]. Some researchers [7,10,11,22] have demonstrated that NSAIDs have been used to prevent the adhesion formations by blocking the initial stage of inflammatory response. An optimal barrier should be non-toxic, biodegradable, easily appliable, without compromising wound healing, remain active in the presence of body fluids, and dissolved after 1 to 2 weeks. HA/CMC has been used to reduce adhesion formation after the surgery. It becomes a hydrophilic gel within approximately 24 h after placement. It is absorbed within 7 days and cleared completely from the body within 28 days [1-4,14-16]. In our study, it was used the effect of flunixin meglumine 1.1 mg/kg on the postoperative adhesions and HA/CMC covered on the peritoneal defect. These results, as expected under guidance of previous result of the studies [7,10,11,14-18], have supported that both HA/CMC and flunixin meglumine decreases adhesion formation, as evaluated by the scoring of adhesion, fibrosis, and inflammatory compared with the control group ($P<0.05$), *(Table 1)*.

The physical barriers should focus on more widespread adhesion prevention without compromising peritoneal fibrinolytic activity. HA/CMC is accepted as one of the most effective barrier to prevent intraabdominal adhesions. However, their efficacy may be limited to the site of application. HA/CMC does not address the complex nature of adhesion formation and has hydroflotation and sliconization effect on the applicated area [6-8,9,21,28]. An current approach to increase the efficacy of barriers or drugs could be improved the synergistic effect of various combinations without causing significant complications [4,9,19-23,26,28]. Lim et al.[8] found that the coadministration of HA/CMC with neurokinin 1 receptor antagonist not only increases the efficacy of the barrier at the site of application, but also significantly reduces the adhesions formation at distal unprotected sites. Attar et al.[18] have reported that combined use of HA/CMC and melatonin were found to be effective reducing the adhesion formation in a rat uterine horn model. In this study, adhesion scores of the HA/CMC and melatonin groups were similar, and significantly lower than those of the control group. Also, adhesion scores in the combination group were lower than those in the control, HA/CMC, and melatonin groups. Altun et al.[23] recently showed that low molecular weight heparin and octreotide were almost have the same effect for prevention of adhesion formation. In this work, it was observed that the scores of adhesion and inflammation in SF group were significantly lower than that in S and F groups ($P<0.05$), *(Tablo 1)*. So that based on this results, it was concluded that they were effective in combination rather than the separate using. The result of HA/CMC and flunixin meglumine combination in this study was paralel to those of other combination [8,9,18,23,26].

Numerous articles on the combination of some agents used adhesion prevention have been published but knowledge on this subject is limited and contradictory [17,18,29-31]. Şahin and Sağlam [19] researched heparin to the carboxymethylcellulose at laparotomy, whereas Başbuğ et al.[20] added hyaluronic acid plus heparin, Tayyar et al.[26] tried heparin to the amniotic membrane to cover injured rabbit uterine horns. These combinations seem to be more effective in reducing adhesion formation rather than the use of heparin, hyaluronic acid, carboxymethylcellulose and amniotic membrane alone. Conversely, some researchers [17,27,29-32] revealed that there was no difference between the groups in the combined application of various drugs (HA/CMC+atorvastatin, dimethyl sulfoxide+synovial fluid, low molecular weight heparin+hyperbaric oxygen, medroxyprogesterone acetate+heparin, HA/CMC+vitamin E, vitamin E+selenium) on the prevention of intra-abdominal adhesions.

In conclusion, HA/CMC and flunixin meglumine reduce significantly the prevalence of adhesion development separately. However, HA/CMC and flunixin meglumine combination have reduced more effectively the formation of postoperative intraabdominal adhesions. Further and more detailed investigations could be useful and necessary using additional examinations.

Acknowledgements

The author would like to thank to Dr. Yesari ERÖKSÜZ for pathological evaluations, Dr. Cemal ORHAN for his help in statistical analysis, and Dr. Süleyman AYDIN for checking the English of the manuscript.

REFERENCES

1. Arung W, Meurisse M, Detry O: Pathophysiology and prevention of postoperative peritoneal adhesions. *World J Gastroenterol*, 17 (41): 4545-4553, 2011.

2. Ergül E, Korukluoğlu B: Peritoneal adhesions: Facing the enemy. *Int J Surg*, 6, 253-260, 2008.

3. Rizo A, Spedicato M, Mutinati M, Minoia G, Angioni S, Jirillo F, Pantaleo M, Sciorci RL: Peritoneal adhesions in human and veterinary

medicine: From pathogenesis to therapy. A review. *Immunopharm Immunot*, 32 (3): 481-494, 2010.

4. İrkorucu O, Ferahköşe Z, Memiş L, Ekinci Ö, Akın M: Reduction of postsurgical adhesions in a rat model: A comparative study. *Clinics*, 64 (2): 143-148, 2009.

5. Emre A, Akın M, Işikgönül İ, Yüksel O, Anadol AZ, Çifter Ç: Comparison of intraperitoneal honey and sodium hyaluronate-carboxymethylcellulose (Seprafilm™) for the prevention of postoperative intra-abdominal adhesions. *Clinics,* 64 (4): 363-368, 2009.

6. Tarhan ÖR, Eroğlu A, Çetin R, İnce A, Bülbül M, Altuntaş İ: Effects of seprafilm on peritoneal fibrinolytic system. *ANZ J Surg*, 75 (8): 690-692, 2005.

7. Ezberçi F, Bülbüloğlu E, Çırağil P, Gül M, Kurutaş EB, Bozkurt S, Kale İT: Intraperitoneal tenoxicam to prevent abdominal adhesion formation in a rat peritonitis model. *Surg Today*, 36 (4): 361-366, 2006.

8. Lim R, Stucchi AF, Morrill JM, Reed KL, Lunch R, Becker JM: The efficacy of a hyaluronate-carboxymethylcellulose bioresorbable membrane that reduces postoperative adhesions is increased by the intra-operative co-administration of a neurokinin 1 receptor antagonist in a rat model. *Surgery,* 148 (5): 991-999, 2010.

9. Buckenmaier CC, Pusateri AE, Harris RA, Hetz SP: Comparison of antiadhesive treatments using an objective rat model. *Am Surgeon*, 65 (3): 274-282, 1999.

10. Alkan F, Koç Y, Çelik İ, Erol M, Aydın MF: An experimental study evaluating on the effects of flunixin meglumine and mepiramine maleate in the prevention of intraabdominal adhesions in rabbits. *Vet Bil Derg*, 23 (1): 41-46, 2007.

11. Köklü S: Postoperatif intraabdominal adezyonların önlenmesinde non-steroid antienflamatuar grubu bazı ilaçların etkilerinin değerlendirilmesi. *Yüksek Lisans Tezi,* Adnan Menderes Üniv. Sağlık Bil. Enst., 2008.

12. Özaydın İ, Okumuş Z, Maraşlı Ş, Cihan M, Acarer N, Çelebi F: Clinical and biochemical effects of local flunixin meglumine on the treatment of arthritis, bursitis and tenosynovitis in cattle. *Kafkas Univ Vet Fak Derg*, 1 (1-2): 68-74, 1995.

13. Belge A, Gülbahar MY, Bakır B: The effects of fibrin glue on the prevention of adhesion formation, leakage and wound healing in the dog gaster model. *Indian Vet J*, 82, 36-39, 2005.

14. Beck DE: The role of Seprafilm bioresorbable membrane in adhesion prevention. *Eur J Surg Suppl*, 577, 49-55, 1997.

15. Günerhan Y, Çağlayan K, Sümer A, Köksal N, Altınlı E, Onur E, Güneş P, Gümrükçü G: The efficacy of carboxymetylcellulose for prevention adhesion formation after thyroid region surgery. *Kafkas Univ Vet Fak Derg*, 15 (5): 785-789, 2009.

16. Durmus AS: Effect of seprafilm on prevention of intraabdominal adhesions in rats. *Indian Vet J*, 87, 816-817, 2010.

17. Lalountas MA, Ballas KD, Skouras C, Asteriou C, Kontoulis T, Pissas D, Triantafyllou A, Sakantamis AK: Preventing intraperitoneal adhesions with atorvastatin and sodium hyaluronate/carboxymethylcellulose: A comparative study in rats. *Am J Surg*, 200 (1): 118-123, 2010.

18. Attar R, Yıldırım G, Kumbak B, Ficioğlu C, Demirbağ S, Yeşildağlar N: Efficacy of melatonin and hyaluronate/carboxymethylcellulose membrane in preventing adhesion reformation following adhesiolysis in the rat uterine model. *J Obstet Gynaecol Res*, 37 (2): 125-131, 2011.

19. Şahin Y, Sağlam A: Synergistic effects of carboxymethylcellulose and low molecular weight heparin in reducing adhesion formation in the rat uterine horn model. *Acta Obstet Gyn Scan*, 73 (1): 70-73, 1994.

20. Başbuğ M, Aygen E, Tayyar M, Kaya E, Narin F, Öktem Ö: Hyaluronic acid plus heparin for improved efficacy in prevention of adhesion formation in rat uterine horn model. *Eur J Obstet Gyn R B,* 78, 109-112, 1998.

21. Ward BC, Panitch A: Abdominal adhesions: Current and novel therapies. *J Surg Res*, 165, 91-111, 2011.

22. Avşar FM, Şahin M, Aksoy F, Avşar AF, Aköz M, Hengirmen S, Bilici S: Effects of diphenhydramine HCl and methylprednisolone in the prevention of abdominal adhesions. *Am J Surg,* 181 (6): 512-515, 2001.

23. Altun Ö, Tayyar AT, Tayyar A, Özgün T, Öztürk F, Tayyar M: The effect of low molecular weight heparin and octreotide in an experimental uterine horn adhesion model. *Cumhuriyet Med J,* 34, 307-313, 2012.

24. Mazuji MK, Kalambaheti K, Pawar B: Prevention of adhesion formation with polyvinylpropriodone. Preliminary report. *Arch Surg,* 54, 1011-1015, 1964.

25. Hooker GD, Taylor BM, Driman DK: Prevention of adhesion formation with use of sodium hyaluronate-based bioresorbable membrane in a rat model of ventral hernia repair with polypropylene mesh. A randomized, controlled study. *Surgery*, 125, 211-216, 1999.

26. Tayyar M Turan R, Ayata D: The use of amniotic membrane plus heparin to prevent postoperative adhesions in the rabbit. *Tokai J Exp Clin Med*, 18 (1-2): 57-60, 1993.

27. Kılıç K, Kılıç N, Kılıç E, Yayla S, Ermutlu CŞ, Özaydın İ, Nc i cp K* Dağ S: A comparison of the efficacy of dimethyl sulfoxide (DMSO) and synovial fluid in the prevention of peritoneal adhesions (experimental rabbit model). *Kafkas Univ Vet Fak Derg*, 19 (Suppl-A): A27-A32, 2013.

28. Lim R, Morrill JM, Lynch RC, Reed KL, Gower AC, Leeman SE, Stucchi AF, Becker JM: Practical limitations of bioresorbable membranes in the prevention of intra-abdominal adhesions. *J Gastrointest Surg,* 13, 35-42, 2009.

29. Arıkan S, Adaş G, Barut G, Toklu AS, Kocakuşak A, Uzun H, Kemik Ö, Daduk Y, Aydın S, Purisa S: An evaluation of low molecular weight heparin and hyperbaric oxygen treatment in the prevention of intra-abdominal adhesions and wound healing. *Am J Surg*, 189 (2): 155-160, 2005.

30. Sağol S, Özşener S, Dinçer O, Yılmaz H, Karadadaş N: The effect of medroxyprogesterone acetate and heparin in the prevention of postsurgical adhesion formation in the rat uterine model. *J Obstet Gynaecol Res*, 25 (4): 287-293, 1999.

31. Correles F, Corrales M, Sachirmer CC: Preventing intraperitoneal adhesions with vitamin E and sodium hyaluronate/carboxymethylcellulose. A comparative study in rats. *Acta Cir Bras*, 23 (1): 36-41, 2008.

32. Durmuş AS, Yıldız H, Yaman I, Şimşek H: Efficacy of vitamin E and selenium for the prevention of intra-abdominal adhesions in rats: uterine horn models. *Clinics,* 66 (7): 1247-1251, 2011.