Kafkas Univ Vet Fak Derg
19 (5): 829-836, 2013
DOI: 10.9775/kvfd.2013.8902

Journal Home-Page: http://vetdergi.kafkas.edu.tr
Online Submission: http://vetdergikafkas.org

RESEARCH ARTICLE

The Role of Red and Infrared Low Level Laser Therapy on Unmeshed Full-Thickness Free Skin Autograft in Rabbits: As An Animal Model

Hamidreza FATTAHIAN [1] Ali NASIRIAN [1] Pejman MORTAZAVI [2]

[1] Department of Clinical Sciences, Faculty of Specialized Veterinary Sciences, Sciences and Research Branch, Islamic Azad University, Tehran - IRAN
[2] Department of Pathobiology, Faculty of Specialized Veterinary Sciences, Sciences and Research Branch, Islamic Azad University, Tehran - IRAN

Makale Kodu (Article Code): KVFD-2013-8902

Summary

The effect of laser on wound healing has been approved but the role of Low Red (LR) and Infrared Low Level Laser (ILLL) on unmeshed full-thickness free skin autograft (UFFSA) is not clear yet. The aim of the present experimental study is to determine the effectiveness of LR and ILLL in UFFSA in rabbits. The study was conducted on 15 New-Zealand white rabbits were divided into three groups, Control (C), Low Red (LR), Low Infrared (LIR). A 5×5 cm UFFSA was obtained then rotated 90 degrees and repositioned on its own bed and sutured. The rabbits in LR and LIR received LR and ILLL for 6 days post-operatively. On days 3, 5, 7, 14, and 30 skin biopsies were obtained. Graft size was measured. There were significant differences in epitheliazition, polymorphonuclears, fibroblast, and collagen among groups on days 3 and 5 and new vessels on day 3. LR and LIR had similar role in new vessels till day 5 and collagen synthesis on day 3 for group C. There was no significant difference in epithelialization in groups on days 7, 14, and 30. LIR showed significant differences of length, area, peripheral, and diameter during study and of width on day 7. We concluded LIR played the more effective role on early phase (on day 5) of healing and more acceptable appearance to LR and C groups on quantitative measures.

Keywords: *Unmeshed full-thickness free skin autograft, Low red laser, Infrared low level laser, Rabbit*

Düşük Yoğunluklu Kırmızı ve Kızılötesi Lazer Işın Tedavisinin Tavşanlarda Birbirine Geçmeyen Tam Kalınlıklı Serbest Deri Otogrefti Üzerine Etkisi: Bir Hayvan Modeli

Özet

Lazer ışınlarının yara iyileşmesi üzerine etkisi kanıtlanmış olmasına rağmen Düşük Yoğunluklu Kırmızı (LR) ve Kızılötesi Düşük Yoğunluklu Lazer (ILLL)'in birbirine geçmeyen tam kalınlıklı serbest deri otogrefti (UFFSA) üzerine etkisi açıkca bilinmememktedir. Bu deneysel çalışmanın amacı tavşanlardaki UFFSA üzerine LR ve ILLL'nin etkililiğini belirlemektir. Çalışma Kontrol (C), Düşük Kırmızı (LR), Düşük Kızılötesi (LIR) olma üzere üç gruba ayrılan 15 Yeni Zelanda beyaz tavşanı üzerinde gerçekleştirildi. Beş×beş cm'lik UFFSA elde edilip daha sonra 90 derece döndürüldü ve kendi yatağında yeniden konumlandırılıp ve dikildi. LR ve LIR içindeki tavşanlar operasyon sonrası 6 gün boyunca LR ve ILLL uygulaması aldı. Üçüncü, 5., 7., 14. ve 30. Günlerde deri biyopsileri elde edildi. Greft boyutları ölçüldü. Gruplararası önemli farklılıklar 3. ve 5. günlerde epitelizasyon, polimorfnükleer hücreler, fibroblast ve kollajen üzerine gözlemlenirken 3. gün yeni damarlar üzerinde belirlendi. Grup C için, LR ve LIR'nin 5. güne kadar yeni damarlar üzerine ve 3. gün kollajen sentezi üzerine benzer rol oynadığı belirlendi. Gün 7, 14, ve 30'da gruplar arasınad epitelizasyon açısından anlamlı bir fark bulunmadı. LIR uzunluk, alan, çevre ve çap üzerine çalışma süresince, genişlik üzerine ise 7. günde önemli farklılık gösterdi. LIR'ın erken dönem (5. gün) iyileşme aşamasında daha etkin rol oynadığı ve LR ve C gruplarınnın kantitatif ölçümler üzerine daha kabul edilebilir görünümde olduğu sonucuna varıldı.

Anahtar sözcükler: *Birbirine geçmeyen tam kalınlıklı serbest deri otogrefti, Kırmızı düşük yoğunluklu lazer, Kızılötesi düşük yoğunluklu lazer, Tavşan*

İletişim (Correspondence)
+98 218 8030091
hamidrezafattahian@yahoo.com

INTRODUCTION

Skin grafts are indicated when there is major loss of skin from trauma particularly on limbs, tumor removal, and resurfacing full thickness burns after major thermal injuries [1-3]. A skin graft (unmeshed full-thickness free skin autograft) is one choice for complicated wound therapy [2]. The main advantages of UFFSA include as pliable, movable, resistant to trauma, normal skin appearance, minimum contraction, increase the size and adequate protection and with no immune response [1,2]. Presence of seroma formation between donor and recipient sites prevents graft adherence [3]. So fluid accumulation within or under the graft and movement of the graft prevent good vascular connection from developing between the graft and the bed [2,3]. Therefore this type of graft used in spite of admitted post-surgical appearance especially in burns, contaminated bed and improper granulation bed [3]. Moreover survival time of this type of graft is not survive as well as meshed full-thickness autograft [3]. Regarding of the problem, UFFSA is not sometimes taken to the wound bed that it is not seen in meshed full-thickness autograft [1,3]. It is worthy that the latter technique does not meet cosmetic criteria, so for better appearance; UFFSA is suggested [3]. According to the struggle, unmeshed graft is not used for the reason of probable consequences. During the three last decades, many reports showed that monochromatic light sources and photomedicine were used for acceleration treatment of skin wound healing [4]. Many researchers also have indicated that the low-power laser light has therapeutic role to promote the repair processes of connective tissues as skin, ligaments, tendons, nerve, pulp of tooth, bone and cartilage in variety of animal models and as well as ulcers of a wide range of etiologies in humans [5-9]. Few studies supported the effect of low level laser and other monochromatic light sources in UFFSA and increasing its success. Therefore beneficial role of laser on "taken" and appearance of this type of graft is underquestion. As there was lack of information and few investigations deal with effect of low red and low infrared lasers and dose of them on UFFSA and on its survival time and success, so the purpose of this study was to clarify the effect of red and infrared of the low level laser therapy on UFFSA of rabbit skin.

MATERIAL and METHODS

The study was approved by the Animal Ethics Committee of the Iranian laboratory animal ethic frameworks under the reference code IAEC 1-12.

For this study, 15 mature New Zealand white rabbits of both genders were exposed to in the same light, temperature, humidity and diet for two weeks. All rabbits were then randomly allocated into three equal groups, Control (C), Low Red (LR) and Low Infrared (LIR).

First stage

On the day of the operation, left side of all rabbits was prepared for operation and clipping and aseptic surgical techniques were employed. A combination of Xylazine HCl (5 mg/kg, IM) and Ketamine HCl (40 mg/kg, IM) was given for anesthesia. All rabbits of three groups were then placed in the right lateral position and the left thoracoabdominal region was scrubbed with 1% povidone-iodine solution. After preparation of rabbits and surgical team, a 5×5 cm full-thickness skin graft was obtained and separated from the region, and then the graft was rotated 90 degrees repositioned and sutured to the surrounding skin with simple interrupted suture by 4-0 monofilamet polyamide *(Fig. 1)*. For this purpose, firstly, sutures were placed of the four corners of grafted skin and secured in bed and continued to oppose the two other borders of skin in each groups *(Fig. 2)*. Post-operatively, animals were given penicillin procaine (60.000 IU/kg, deeply SC, three days) and Gentamicin (2 mg/kg, SC, three days). Analgesic agent was not prescribed post-operatively. Every rabbit kept in solitary cage for 30 days and all of them took the same diet during study.

Second stage

The irradiation protocol established in rabbits of group LR and LIR using 1 J/cm^2 using red light (wavelength 635

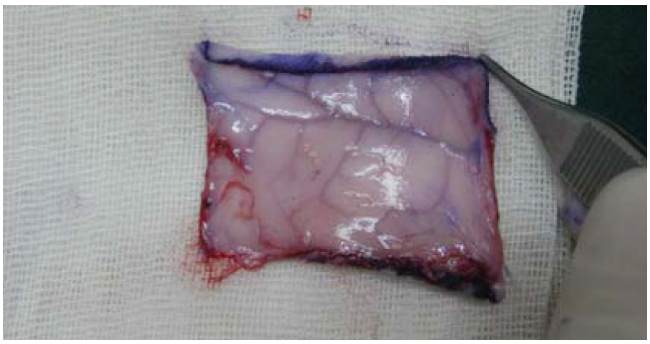

Fig 1. Skin removed, inner side, the vessels of skin are visible
Şekil 1. Serbestleştirilen derinin iç yüzü ve damarları görülmektedir

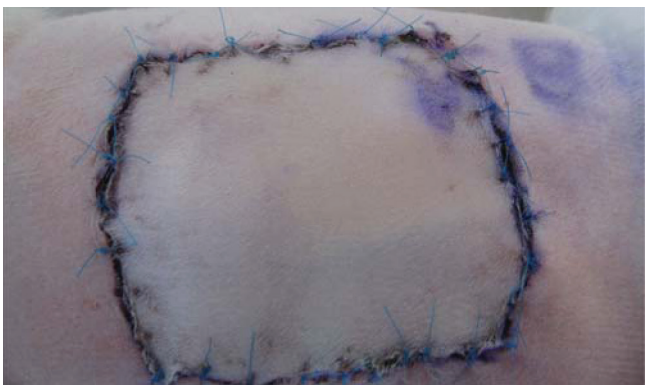

Fig 2. The skin after suturing
Şekil 2. Dikiş sonrası derinin görünümü

nm) and infrared light (wave length 850 nm) by laser (Mustang 2000, Russia) equipment. Time of irradiation was 60 sec centripetally once a daily for 6 days, with the first application immediately after surgical procedures. Rabbits in group C did not receive any laser irradiation. On days 3, 5, 7, 14, and 30 skin biopsies were obtained using scalpel blade No. 11 from the cranial end of the ventral side on day 3, from the middle of caudal side on day 5, from the middle of dorsal side on day 7, from the middle of cranial side on day 14 and from the caudal end of ventral side on day 30 of the junction of square shaped graft and skin. The sample was fixed in formalin and embedded in paraffin for sectioning. The samples were sent to laboratory and 6 micrometers section was done and stained by haematoxylin and Eosin dye for microscopic study. The evaluation of qualitative histopathologic data was scaled based of *Table 1*. Length, width, area, perimeter and diameter of graft sides were measured in each rabbit on the same days and record.

Statistical Analysis

The histologic evaluation of grafts was done qualitatively and quantitatively. Statistical data were analyzed by SPSS software version 16.0. One-way ANOVA, Tukey Post-Hoc test and repeated measures analysis with 95% confidence interval was done by General Linear Model (GLM). This procedure was used of continuous variables with normal distribution. The Kruskal-Wallis and Friedman tests were used to evaluate the ordinal variables. A *P*-value of less than 0.05 was considered statistically significant.

RESULTS

Immediately after excision of graft because of the tension lines, the area of the graft expanded and after transplanting, the shrinking process of the graft is seen simultaneously. The wound dehiscence wasn't occurred in animals of all groups during study. All rabbits tolerated surgery and survive during study. Qualitative data were as follows:

Epithelialization

Based on microscopic study, there were significant differences in epithelialization among groups (C, LR, and LIR) on days 3 and 5 and LR and LIR were similar and showed significant differences to group C. There was no difference in epithelialization in all groups days 7, 14, and 30 *(Table 2, Fig. 3-14)*.

Polymorphonuclears (PMNs)

The number of PMNs showed significant differences on days 3, 5, and 14. There were no significant differences on days 7 and 30 among groups *(Table 2, Fig. 3-14)*.

Table 1. *Explanation of used scale in the semi-quantitative evaluation of histological sections*
Tablo 1. *Histolojik kesitlerin yarı kantitatif değerlendirmesinde kullanılan ölçekler*

Scale	Epithelization	PMNL	Fibroblasts	New Vessels	Collagen
0	thickness of cut edges	absent	absent	absent	absent
1	migration of cells (<50%)	mild ST	mild-ST	mild-SCT	minimal-GT
2	migration of cells (≥50%)	mild DL/GT	mild-GT	mild-GT	mild-GT
3	Bridging the excision	moderate DL/GT	moderate_GT	moderate_GT	moderate_GT
4	keratinization	marked DL/GT	marked-GT	marked-GT	marked-GT

*(**ST** – surrounding tissue, i.e. tissue out of GT; **DL** – demarcation line; **SCT** – subcutaneous tissue; **GT** – granulation tissue)*

Table 2. *Mean ± SE of quantitative meaures (length, width, area, perimeter and diameter) in different days ±*
Tablo 2. *Farklı günlerde ortalamaSH'nın kantitatif değerleri (Uzunluk, genişlik, alan, çevre ve çap)*

Day	0			3			5			7			14			30		
Group	C	LR	LIR	C	LR	LIR	C	LR	LIR	C	LR	LIR	C	LR	LIR	C	LR	LIR
L	5± 0.00	5± 0.00	5± 0.00	4.45± 0.07	4.22± 0.0	3.54± 0.13	4.10± 0.10	3.62± 0.19	3.05± 0.09	3.50± 0.10	3.24± 0.17	2.55± 0.09	3.56± 0.12	3.05± 0.12	2.74± 0.05	3.04± 0.05	1.92± 0.10	2.25± 0.14
W	5± 0.00	5± 0.00	5± 0.00	4.5± 0.04	4.70± 0.0	4.65± 0.06	4.45± 0.04	4.45± 0.09	4.40± 0.14	4.16± 0.05	4.24± 0.10	3.82± 0.07	3.90± 0.04	3.90± 0.10	3.64± 0.05	3.14± 0.12	2.56± 0.22	3.14± 0.05
A	25± 0.00	25± 0.00	25± 0.00	21.51± 047	19.54± 0.47	16.57± 0.69	18.37± 0.52	16.27± 1.15	13.47± 0.64	15.77± 0.63	13.79± 1.06	11.01± 0.45	13.55± 0.50	11.99± 0.68	9.97± 0.29	9.56± 0.50	4.96± 0.58	7.17± 0.49
PM	20± 0.00	20± 0.00	20± 0.00	15.52± 0.021	17.54± 0.2	16.44± 0.31	17.16± 0.23	16.40± 0.68	14.55± 0.36	15.92± 0.29	15.12± 0.52	13.40± 0.26	14.92± 0.26	13.92± 0.35	12.76± 0.19	12.36± 0.33	13.92± 0.38	10.55± 0.35
D	7.07± 0.00	7.07± 0.00	7.07± 0.00	6.56± 0.07	6.32± 0.07	5.87± 0.10	6.07± 0.08	5.76± 0.18	5.3± 0.13	5.63± 0.10	5.34± 0.18	4.79± 0.89	5.25± 0.08	4.96± 0.13	4.56± 0.07	4.37± 0.12	3.21± 0.21	3.55± 0.10

*In each raw, the heterogeneous letters show the statistical differences among groups in each day (P<0.05), **L**=Length, **W**=Width, **A**=Area, **PM**=Perimeter, **D**=Diameter*

Fibroblast

Similar to epithelialization, there were significant differences among groups (C, LR, LIR) on days 3 and 5. There was no significant difference among groups on days 7, 14, and 30 *(Table 2, Fig 3-14)*.

New *vessels* (Neovascularization)

Formation of vessels was significant on day 3, 14, and 30, but there were no significantly differences on days 5 and 7 *(Table 2, Fig. 3-14)*.

Collagen synthesis

Regeneration of new collagen showed significant differences among groups (C, LR, LIR) on days 3 and 5. There was no significant difference among groups on days 7, 14, and 30. Another interesting result was the separation of epidermal from dermal layer in all groups in the third day. Histopathologic image showed that in group LIR, re-epithelialization is formed faster (on day 5) than another groups *(Table 2, Fig. 3-14)*.

So, finally all of results indicated successful "taken" of graft with acceptable appearance in group LR and particularly group LIR and efficient adhesion between bed and donor with no gap and fluid accumulation and seroma formation in all groups *(Fig. 15-17)*.

Quantitative data

The analysis of quantitative data of diameter, perimeter, length and area showed the differences among groups on day 3, 5, 7 and 14 ($P<0.05$, *Table 2*). In group LR, differences were seen in diameter, width and area on day 30 ($P<0.05$, *Table 2*). The appearance of graft of LIR and LR were more acceptable to control group and healing rate was more rapidly in former groups, so was significant in LIR particularly on day 3 and 5 *(Fig. 6-8)*.

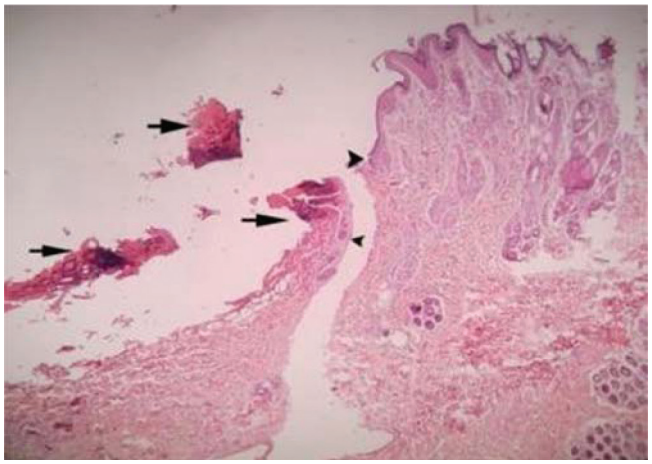

Fig 3. Re-epithelialization *(arrow head)* and necrotic epidermis *(arrow)* in C, H&E × 64

Şekil 3. C'de re-epitelizasyon *(ok başı)* ve nekrotik epidermis *(ok)*, H&E × 64

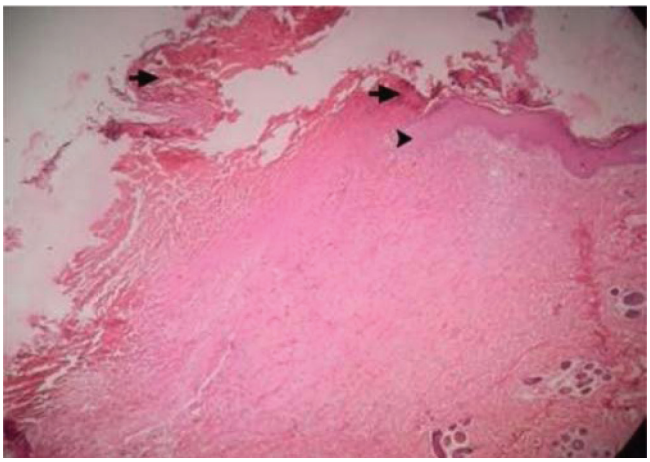

Fig 5. Re-epithelialization *(arrow head)* and necrotic epidermis *(arrow)* in LR, H&E × 64

Şekil 5. LR'de re-epitelizasyon *(ok başı)* ve nekrotik epidermis *(ok)*, H&E × 64

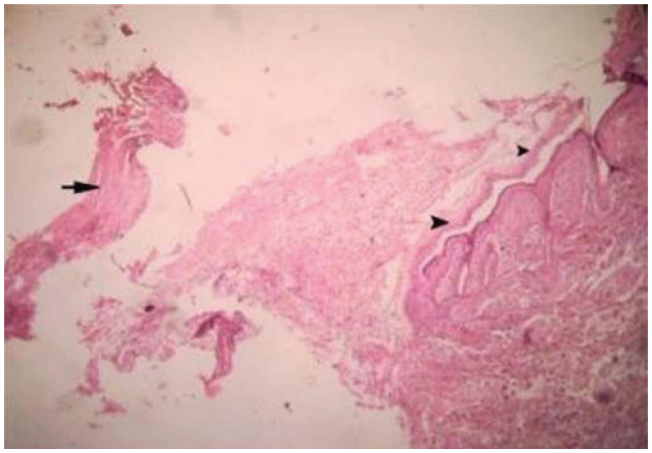

Fig 4. Re-epithelialization (arrow head) and necrotic epidermis *(arrow)* in LIR, H&E × 64

Şekil 4. LIR'de re-epitelizasyon *(ok başı)* ve nekrotik epidermis *(ok)*, H&E × 64

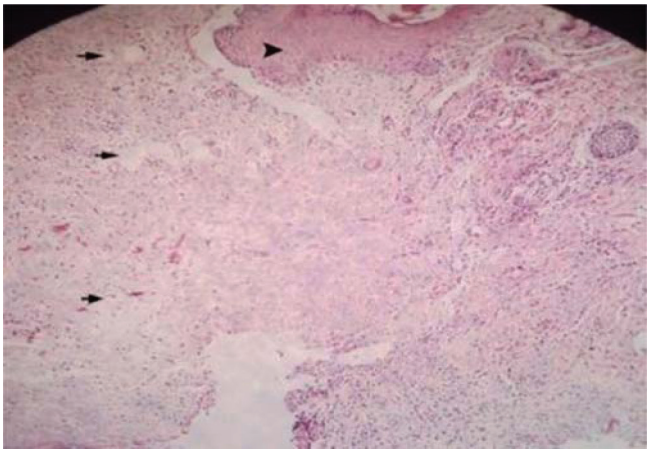

Fig 6. Re-epithelialization *(arrow head)*, collagen fiber *(arrow)* and necrotic epidermis (N) in C, H&E × 64

Şekil 6. C'de re-epitelizasyon *(ok başı)*, kollajen lif *(ok)* ve nekrotik epidermis (N) H&E × 64

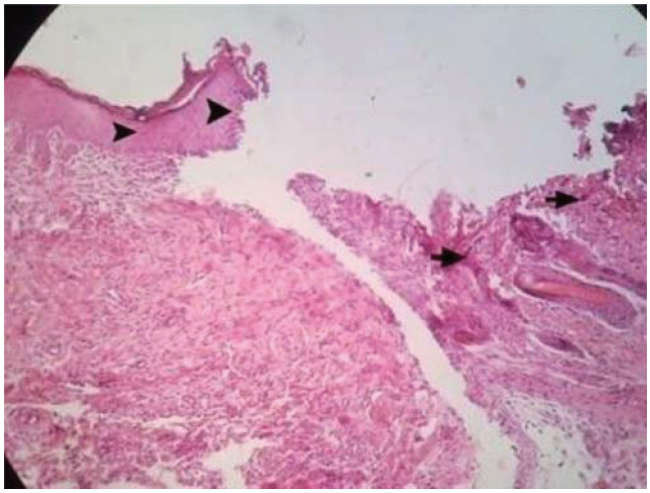

Fig 7. Re-epithelialization *(arrow head)* and necrotic epidermis (N) in LIR, H&E × 64

Şekil 7. LIR'de re-epitelizasyon *(ok başı)* ve nekrotik epidermis (N) H&E × 64

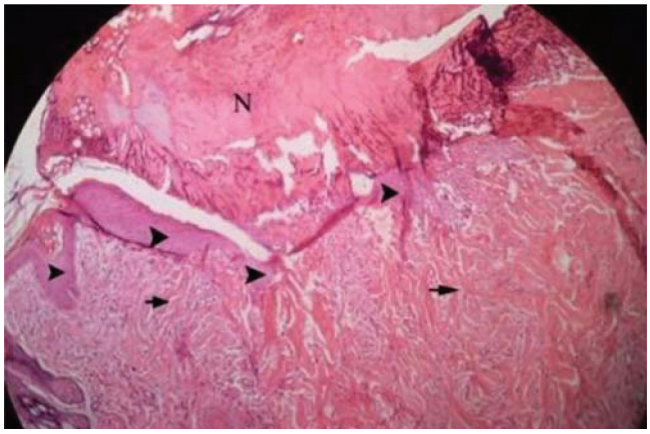

Fig 8. Re-epithelialization *(arrow head),* collagen fiber (arrow) and necrotic epidermis (N) in LR, H&E × 64

Şekil 8. LR'de re-epitelizasyon *(ok başı),* kollajen lif *(ok)* ve nekrotik epidermis (N) H&E × 64

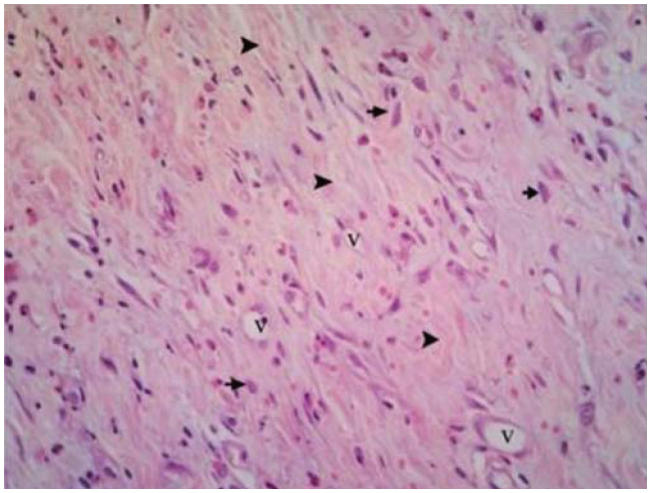

Fig 9. New vessels (V), collagen fiber *(arrow head)* and fibroblast *(arrow)* in C, H&E × 64

Şekil 9. C'de yeni damarlar (V), kollajen lif *(ok başı)* ve fibroblast *(ok)* H&E × 64

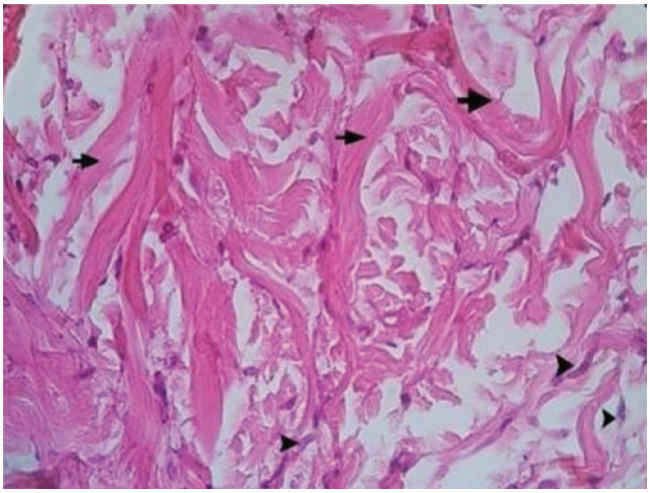

Fig 10. Collagen fibers *(arrow)* and fibroblasts *(arrow head)* in LIR, H&E × 640

Şekil 10. LIR'de kollajen lif *(ok)* ve fibroblast *(ok başı)* H&E × 64

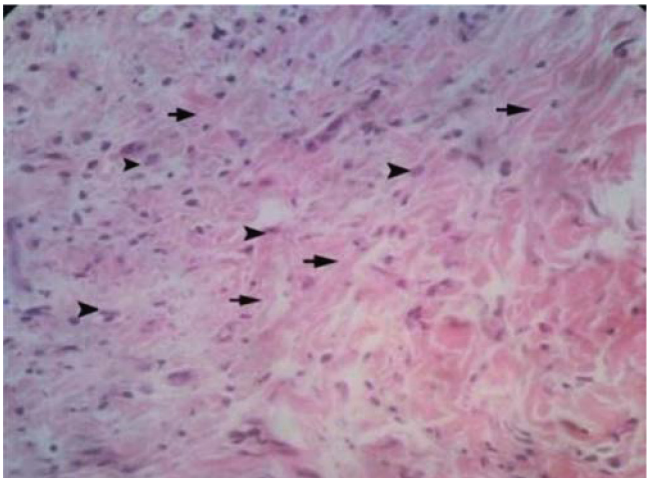

Fig 11. Collagen fibers *(arrow)* and fibroblasts *(arrow head)* in LR, H&E × 640

Şekil 11. LR'de kollajen lif *(ok)* ve fibroblast *(ok başı)* H&E × 64

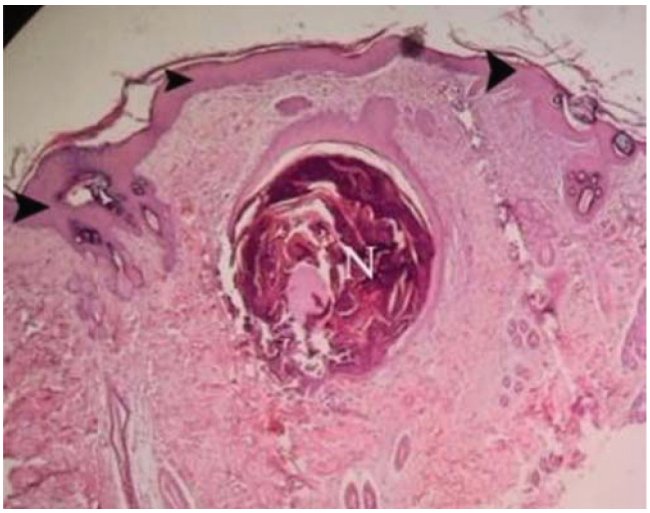

Fig 12. New epidermis *(arrow head)* and necrotic tissue (N) in C, H&E × 64

Şekil 12. C'de yeni epidermis *(ok başı)* ve nekrotik doku (N) H&E × 64

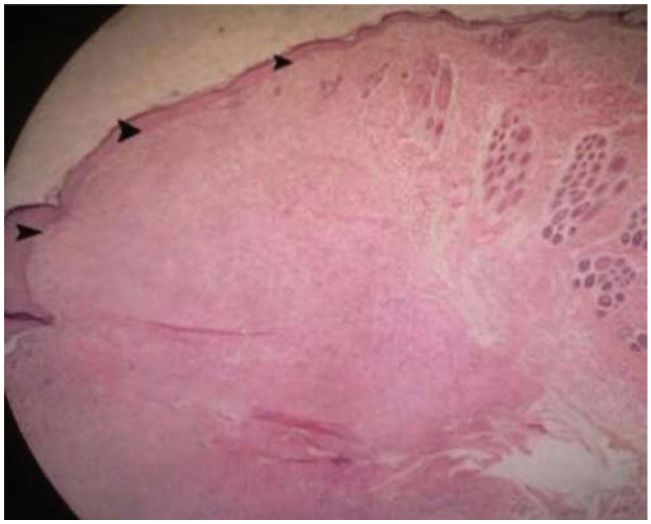

Fig 13. New epidermis *(arrow head)* and cornified in LIR, H&E × 64
Şekil 13. LIR'de yeni epidermis *(ok başı)* ve boynuzsu hali, H&E × 64

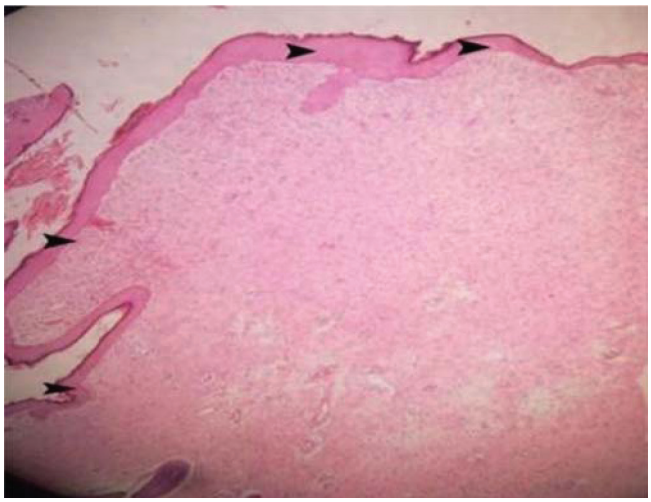

Fig 14. New epidermis *(arrow head)* and cornified in LR, H&E × 64
Şekil 14. LR'de yeni epidermis *(ok başı)* ve boynuzsu hali, H & E×64

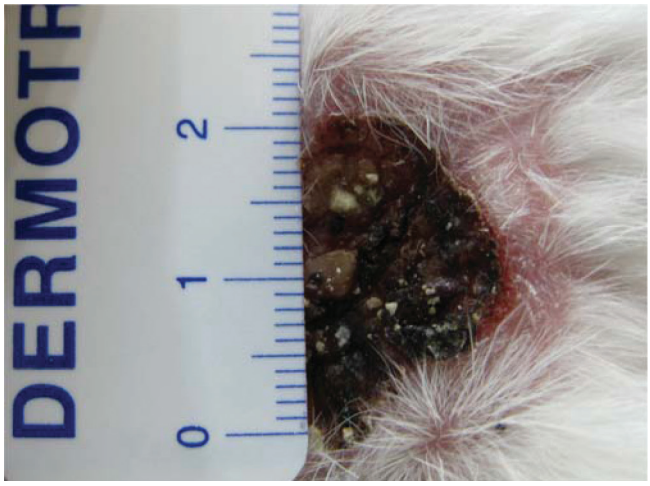

Fig 15. Appearance of a rabbit skin in control group at day 30
Şekil 15. Otuzuncu günde kontrol grubunda bir tavşan derisinin görünümü

Fig 16. Appearance of a rabbit skin in LIR group at day 30
Şekil 16. Otuzuncu günde LIR grubunda bir tavşan derisinin görünümü

Fig 17. Appearance of a rabbit skin in LR group at day 30
Şekil 17. Otuzuncu günde LR grubunda bir tavşan derisinin görünümü

DISCUSSION

The closure and repair of large defect of skin is one of the main concerns of patients, clinicians and investigators for years [10-12]. The unmeshed full-thickness free skin autograft is one of the choices for this purpose with maximum acceptable appearance, but the success rate of graft taken depends on establishment of arterial and venous connections with less fluid accumulation and seroma formation between them [1-3,13]. Hence some plastic surgeons bypass the latter consequence with meshed pattern for diminishing seroma formation and resolving postoperative complication related to UFFSA, but it meets less cosmetic appearance [1-3]. Many investigations were done on the laser role on wound healing process but there was lack of information deal with effect of low level red and low level infrared and dose of them on unmeshed full-thickness skin autograft and "taking" graft. So the role of low level laser on unmeshed full-thickness free skin auto-

graft is unknown. Although, using low level laser therapy (LLLT) in health care has been documented in the literature for more than three decades [7]. Many researchers have demonstrated that LLLT reduces pain and has effective role in wound healing (initial, second, and final phases; pro-inflammatory, proliferation, and remodeling, respectively), and can evoke vaso-dailation, early epithelialization increased fibroblastic reaction (gingival fibroblast *in vitro*), lukocytic infiltration, encouraging the formation of type I and type III procollagen specific pools of mRNA, enhancement of ATP synthesis within the mitochondria, activating lymphocytes, and increasing their ability to bind pathogens, reduction of nicotine side effects on graft, and neovascularization [14-19]. Moreover, it was revealed that using LLLT for months or years accelerates formation of bone [20]. Regarding to above effects the time required for complete graft closure will reduced [21]. The work of Karu also showed bio-stimulation effects of the rate DNA synthesis of blue (404 and 454), red (620 nm), and near infrared (760 and 830 nm) wavelengths in vitro [15]. Moore and his colleagues demonstrated that maximum cell proliferation occurred with 665 and 675 nm light, whereas 810 nm light was inhibitory to fibroblast [17]. Rodrigo's study showed that local and systemic effects using combination red and infrared laser on the repair of back wound of rats in control and other experimental groups earlier on the 7th postoperative day [22]. Current study was showed that significant effect of low red and low infrared laser on epithelialization, polymorphonuclears (PMNs), fibroblast, new vessels (angiogenesis), and collagen synthesis in UFFSA of LIR group. Significant changes on day 3 and 5 on are related to shortening the inflammatory phase of repair and enhancing release of factors stimulating the proliferative stage of repair and increasing vaso-dailation and lukocytic infiltration in inflammatory phase by Low Infrared Laser [5,8]. So these findings indicate LIR (850 nm) had significant effect to the other groups in early phase of graft taking particularly on day 3 and less effective on day 5 and the remaining days of study. As it was mentioned, former finding does not agree with Moors's study that demonstrated inhibitory effect of the wavelength and agrees with some investigators [17,23]. Walsh and et al showed that infrared (830 nm) enhances vaso-active effects by its actions on mast cells and facilitates entry of leukocyte [5,16]. Therefore, vaso-dilation, with increased local blood flow and shortening of pro- and inflammatory phase caused by laser in LIR and even LR groups [5,16]. Fluid accumulation mechanically separates the grafts from their bed, impairing nutrition and revascularization [3]. We also did not find any fluid accumulation and seroma formation between recipient and donor. The absence of seroma accumulation in the experimental and even control groups can be because of the healthy, free of debris, irregularities and non-infectious wound bed.

The wave-length, power, power density, energy density, treatment duration, treatment intervention time post-injury, and method of application are the causative factors of response of tissue to laser [18,21]. Woodruff's study revealed that energy density was the only treatment parameter with predictable dose dependent treatment effects in outcome [24]. They revealed that energy densities ranging from 19 to 24 J/cm^2 had the largest average effect size [24]. Walsh and et al and the other related researches have demonstrated a range of bio-stimulation effects at dose from 2 to 10 J/cm^2 in red and infrared wavelengths [5]. Although deciding about the right dosage to obtain best result for the healing has not been the main concern of this study, we managed to achieve positive results by applying dose 1 J/cm^2 with 850 nm wavelength. These results (positive bio-stimulation effects) were in accordance with of results of Walsh's study with different dosage from 2 to 10 J/cm^2. Therefore it can be drawn that in our study using dosage 1 J/cm^2 brings about positive results and agree with Walsh's study.

The other finding was contraction of graft on its bed that started on day 3 and continued till day 30. As was mentioned, the shrinkage of graft size in group LIR was more significant. The previous studies had revealed contraction in thin and split-thickness grafts by the time. Few reports indicated contraction of unmeshed full-thickness free skin grafts. The main reason of shrinkage in LIR could be the presence of numerous myofibroblasts especially in LIR group on day 3 to the two groups and maturity of collagen between graft and its bed. So our results agreed with results of other investigations.

Finally, the significant results of our study could represent the beginning of a paradigm of laser therapy (red and especially infrared) and its role on graft (UFFSA) and diminished well known post-operative complications.

REFERENCES

1. Dyson M: Cellular and subcellular aspects of low level laser therapy. **In,** Ohshiro T, Calderhead RG (Eds): Progress in Low Level Laser Therapy. 221, John Wiley and Sons, England, 1999.

2. Pavletic MM: Integument. **In,** Slatter (Ed): Textbook of Small Animal Surgery. 3rd ed., 250-259, WB Saunders Co, Philadelphia, 2003.

3. Waldron DR, Zimmerman-Pope N: Superficial skin wounds. **In,** Slatter (Ed): Textbook of Small Animal Surgery. 3rd ed., 295-273, WB Saunders Co, Philadelphia, 2003.

4. Walsh LJ: The current status of laser applications in dentistry. *Aust Dent J*, 48, 146-155, 2003.

5. Walsh LJ: The current status of low level laser therapy in dentistry. I. Soft tissue applications. *Aust Dent J*, 42, 247-254, 1997.

6. Sandford MA, Walsh LJ: Thermal effects during desensitition of teeth with gallium-aluminiumarsenide lasers, *peridonal*, 15, 25-30, 1994.

7. Ohshiro T, Calderhead RG: Low Level Laser Therapy: A Practical Introduction. 11-18, Chichester, John Wiley and Sons, 1988.

8. Karu TI: Photobiology of low-power laser effects. *Heallth Physics,* 56, 691-704, 1989.

9. Laakso EL, Richardson CR, Cramond T: Factors affecting low level laser therapy. *Aust J Physio,* 39, 95-99, 1993.

10. Ghamsari SM, Taguchi K, Abe N, Acorda JA, Yamada H: Histo-

pathological effect of low-level laser therapy on sutured wounds of the teat in dairy cattle. *Vet Q*, 18, 17-21, 1996.

11. Ghamsari SM, Taguchi K, Abe N, Acorda JA, Sato M, Yamada H: Evaluation of low level laser therapy on primary healing of experimentally induced full thickness teat wounds in dairy cattle. *Vet Surg*, 26, 114-120, 1997.

12. Yu W, Naim JO, Lanzafame RJ: Effects of photostimulation on wound healing in diabetic mice. *Lasers Surg Med,* 20, 56-63, 1997.

13. Calin MA, Coman T, Calin MR: The effect of low level laser therapy on surgival wound healing. *Romanian Reports in Physics,* 62 (3): 617-627, 2010.

14. Karu TI: Photobiological fundamentals of low-power laser therapy. *IEEE J Quant Electron QE-2*, 3, 1703-1717, 1987.

15. Karu TI: Molecular mechanism of the therapeutic effect of low-intensity laser radiation. *Lasers Life Sci,* 2, 53-74, 1988.

16. Walsh LJ, Trinchieri G, Waldorf HA, Whitaker D, Murphy GF: Human dermal mast cells contain and release tumor necrosis factor-which induces endothelial leukocyte adhesion molecule-1. *Proc Natl Acad Sci USA,* 88, 4220-4224, 1991.

17. Moore P, Ridgway TD, Higbee RG, Howard EW, Lucroy MD: Effect of wavelength on low-intensity laser irradiation-stimulated cell proliferation in vitro. Lasers in Surgery and Medicine, *Lasers Surg Med*, 36 (1): 8-12, 2005.

18. Garcia VG, Macarini VC, de Almeida JM, Bosco AF, Nagata MJ, Okamoto T, Longo M, Theodoro LH: Influence of low-level laser therapy on wound healing in nicotine-treated animals. *Lasers Med Sci,* 27 (2): 437-443, 2012.

19. Basso FG, Pansani TN, Turrioni APS, Bagnato VS, Hebling J, De Souza Costa CA: In vitro wound healing improvement by low-level laser therapy application in cultured gingival fibroblasts, *Int J Dentistry*, Article ID 719452, 6 pages 2012. 20).

20. Yu W, Naim JO, Lanzafame RJ: The effect of laser irradiation on the release of bFGF from 3T3 fibroblasts. *Photochem Photobiol*, 59, 167-170, 1994.

21. El Sayed SO, Dyson M: A comparison of the effect of multiwavelength light produced by a cluster of semi-conductor diodes and of each individual diode on mast cell number and degranulation in intact and injured skin. *Lasers Surg Med,* 10, 1-10, 1990.

22. Rodrigo SM, Cunha A, Pozza DH, Blaya DS, Moraes JF, Weber JBB, De Oliveira MG: Analysis of the systemic effect of red and ınfrared laser therapy on wound repair. *Photomedicine and Laser Surgery*, 27 (6): 929-935, 2009.

23. Mester E, Mester AF, Mester A: The biomedical effects of laser application. *Lasers Surg Med*, 5, 31-39, 1985.

24. Woodruff LD, Bounkeo JM, Brannon WM, Dawes KS, Barham CD, Waddell DL, Enwemeka CS: The efficacy of laser therapy in wound repair: A meta-analysis of the literature. *Photomedicine and Laser Surgery*, 22 (3): 241-247, 2004.