Kafkas Univ Vet Fak Derg
19 (4): 589-594, 2013
DOI: 10.9775/kvfd.2012.8456

Journal Home-Page: http://vetdergi.kafkas.edu.tr
Online Submission: http://vetdergikafkas.org

RESEARCH ARTICLE

Parasitic Aortitis due to *Onchocerca armillata* in Slaughtered Cattle in the Southeastern Region of Turkey

Zafer OZYILDIZ [1] Rahsan YILMAZ [1] Sule Yurdagul OZSOY [2] I. Ayhan OZKUL [3]

[1] Harran University, Faculty of Veterinary Medicine, Department of Pathology, TR-63200 Eyyubiye Campus, Sanliurfa - TURKEY
[2] Mustafa Kemal University, Faculty of Veterinary Medicine, Department of Pathology, TR-31040 Antakya, Hatay - TURKEY
[3] Ankara University, Faculty of Veterinary Medicine, Department of Pathology, TR-06800 Ankara - TURKEY

Makale Kodu (Article Code): KVFD-2012-8456

Summary

In this study, total of 400 aorta suspected with parasitic aortitis was investigated between the years 2011-2012 in slaughtered cattle in the Southeastern of Turkey. Particularly arcus aorta and its surroundings were investigated. Macroscopically 32 of 400 (8%), both macroscopically and microscopically 43 (10.75%) cattle were diagnosed as aortic onchocercosis. The aim of this study is to investigate prevalance and pathology of parasitic aortitis in detail caused by *Onchocerca armillata* in the Southeastern region of Turkey.

Keywords: *Cattle, Onchocerca armillata, Parasitic aortitis*

Türkiye'nin Güneydoğusu'nda Mezbahalarda Kesilen Sığırlarda *Onchocerca armillata*'nın Neden Olduğu Parazitik Aortitis

Özet

Bu çalışmada, Türkiyenin Güneydoğusu'nda 2011-2012 yılları arasında mezbahalarda kesilen 400 sığır aortasında gözlenen parazitik aortitis olguları incelendi. Aortaların alınış yeri arcus aorta ve çevresi idi. İncelemeler sonunda 400 hayvandan 32 tanesinde (%8) makroskobik, 43 tanesinde ise (%10.75) hem makroskobik, hem de mikroskobik olarak aortik onkoserkozis tespit edildi. Bu çalışmanın amacı Türkiye'nin Güneydoğusu'nda *Onchocerca armillata* adlı parazitin neden olduğu parazitik aortitis olgularının prevalansı ve patolojisinin ayrıntılı bir biçimde incelenmesidir.

Anahtar sözcükler: *Sığır, Onchocerca armillata, Parazitik aortitis*

INTRODUCTION

Onchocerca armillata a parasite found in the wall of the aorta of cattle [1,2] buffalo [3], sheep [3-5], goat [6] and camels [7]. *Onchocerca armillata* is mostly observed in the south of the Asian regions and African continent closer to the equator [8-10]. In recent years, onchocercosis was also reported in the Tanzania [11], Cameroon [12], Venezuela [13] and in the Greece [14]. *Onchocerca* spp. have been reported at skin, tendons, aponeurosis, testicular and breast tissues as well [8]. The life cycle and vectors of the *Onchocerca armillata* are unknown. However, black flies and mosquitoes are thought to be vectors [12-14]. Onchocercosis often do not show any significant clinical symptoms. Sometimes the bulls show neural symptoms and sometimes microfilaria localized at ocular regions causes recurrent ophthalmitis [8,14]. *Onchocerca armillata* mostly settles in the arcus aorta region. However, can also be found in brachiocephalic truncus, cervical and brachial arteries and the abdominal aorta up to the iliac bifurcation regions [1,8]. Affected aortic intima layers have undulant appearance. Numerous tunnels and nodules are found in the media. These nodules show protrusions towards the intima and media layers. Survived and matured microfilaria can pass the circulation [2]. Parasitic tunnels are filled with a thin connective tissue without inflammatory cells. Granulomatous nodules present around the dead, degenerate or calcified parasite larvae, contain dominantly eosinophil leukocytes [8,11,15,16]. Granulomatous foci in the

İletişim (Correspondence)
+90 414 3183909
zaferozyildiz@hotmail.com

vessel wall can be resorbed over time. Aneurysms can be observed in very old animals due to calcified nodules [1,15,17]. In recent years, antiparasitic disenfestation decreased the frequency of the onchocercosis [13].

The aim of this study is to examine the prevalence and pathology of parasitic aortitis that caused by *Onchocerca armillata* in the Southeastern region of Turkey.

MATERIAL and METHODS

This study was conducted in Sanliurfa, Diyarbakır, Hatay and Gaziantep provinces of Turkey between the years 2011-2012. A hundred sample from each province, from a total of 400 cattle aorta, was collected from slaughterhouses. The aortic samples were taken 2 cm above and below including arcus aorta and were fixed in 10% neutral buffered formalin. Fixed aorta lumens were opened and investigated. At suspected places of intima, adventitia or random regions of arcus aorta was trimmed parallel to the long axisbn of the vessel and passed through all the layers. Then, tissue samples embedded in paraffin by routine methods. Sections were cut 5-6 µm in thickness and were stained with hemato-xylin and eosin (HE), Masson's trichrom and Von kossa.

RESULTS

Macroscopical Findings

Macroscopically 32 of 400 (8%) cattle were diagnosed as aortic onchocercosis. The affected vessel walls, in general, thickened, crusty in consistency and lost flexibility. In a few cases the vessel walls were in appearance of rubber tube and their lumens were severely narrowed.

The intima, media and adventitial layers of the aorta were evaluated in more detail. Accordingly;

Tunica intima: Affected areas revealed tough and an irregular surface. Some of nodules were yellowish gray in color *(Fig 1. A)*. The nodules of varying sizes (0.5-4.0 cm), especially in areas close to the bifurcation, projecting to the vessel lumen, hard in consistency, bright and white surface, cross-sectional areas of calcification felt creaking *(Fig. 1-B)*. Cut surfaces were dry and in caseous structure, which was cleaved easily and surrounded by a tough connective tissue to the size varies from lentils to nuts *(Fig. 1-A,F)*. In some areas, upturned edges formed crater-like foci which causes shrinkage of the surface with the star-like connective tissue induration *(Fig. 1-A)*. In cross-sections, caseous foci, easily cleaved and yellowish gray in color were also observed *(Fig. 1-F)*.

Tunica media: The cross section of the affected areas had tough and an irregular surface. Thickening of the medial layer was noticed in areas where parasitic granulomas were observed. In some areas, dark red-brown old hemorrhage areas hard in consistency were observed along with the long axis. Their cross-sections showed caseous and/or calcified parasite nodules and tunnels *(Fig. 1-E,F)*.

Tunica adventitia: Parasitic nodule formations were observed rarely at the adventitial layer. These nodules bud-like, located sometimes single, sometimes combined with each other in groups of two to three. In this layer the diameter of the granulomas were quite large (the largest of the 4 cm) compared to the intimal layer. Granulomas that over-flowing out of the vessel were hard in consistency, and often surrounded by a broad connective tissue *(Fig. 1-C)*. In cross-sections the presence of large caseation and small amount of calcified areas were noticed *(Fig. 1-D)*.

Histopathological Findings

Fourty three of 400 (10.75%) cattle were diagnosed as aortic onchocercosis both macroscopically and micro-scopically. Histopathologically, 11 of 43 (2.75%) parasitic aortitis were diagnosed with no macroscopic findings. In general, varying degrees of tissue reactions were investigated in the aorta. The majority of parasitic tunnels were located in the intima and media *(Fig. 2-B)*. These tunnels contained dense haemorrhagia without inflammatory cell infiltration *(Fig. 2-A)*. However, calcium deposits were noticed in some regions of these tunnels *(Fig. 2-A,B,C)*. There are round or ellipsoidal cavities containing one or more intact parasitic sections, some with microfilariae. Worms and its structure surrounding thin cuticula appeared to reside within a round or ellipsoidal cavity, with a space between the worm section and the host-derived lining. Some parts of the parasitic cysts were limited by a thin connective tissue without any inflammatory cell infiltration *(Fig. 2-B,C,D)*. A thin halo was found between larvae and the connective tissue capsule *(Fig. 2-B,D)*. Muscle fibers around the parasitic cysts and tunnels were hyalinised. Masson's trichrome stain revealed presence of connective tissue at the cyst capsule. Some areas appeared basophilic with the H&E further stained by von Kossa revealed calcium deposits around and in the parasitic cysts and tunnels.

Details of inflammatory cell infiltration, calcification, sclerosis and parasitic granulomas are given in *Table 1*.

Inflammatory reactions were examined in 3 stages; acute, subacute, and chronic granulomatous aortitis.

Acute aortitis: Mostly started at adventitial vessels, sporadic eosinophils, neutrophils and macrophage infiltrations were spread in a linear style from intimal vessels to muscle bundles. In some areas, dilated blood vessels, rounded endothelial cells, inflammatory oedema and hyalinization of muscle bundles were detected around the parasitic cysts.

Subacute aortitis: A great number of eosinophils, a few number of macrophages, lymphocytes and plasma cell infiltrations were observed in the surroundings of medial and adventitial layers and that were moving towards to the

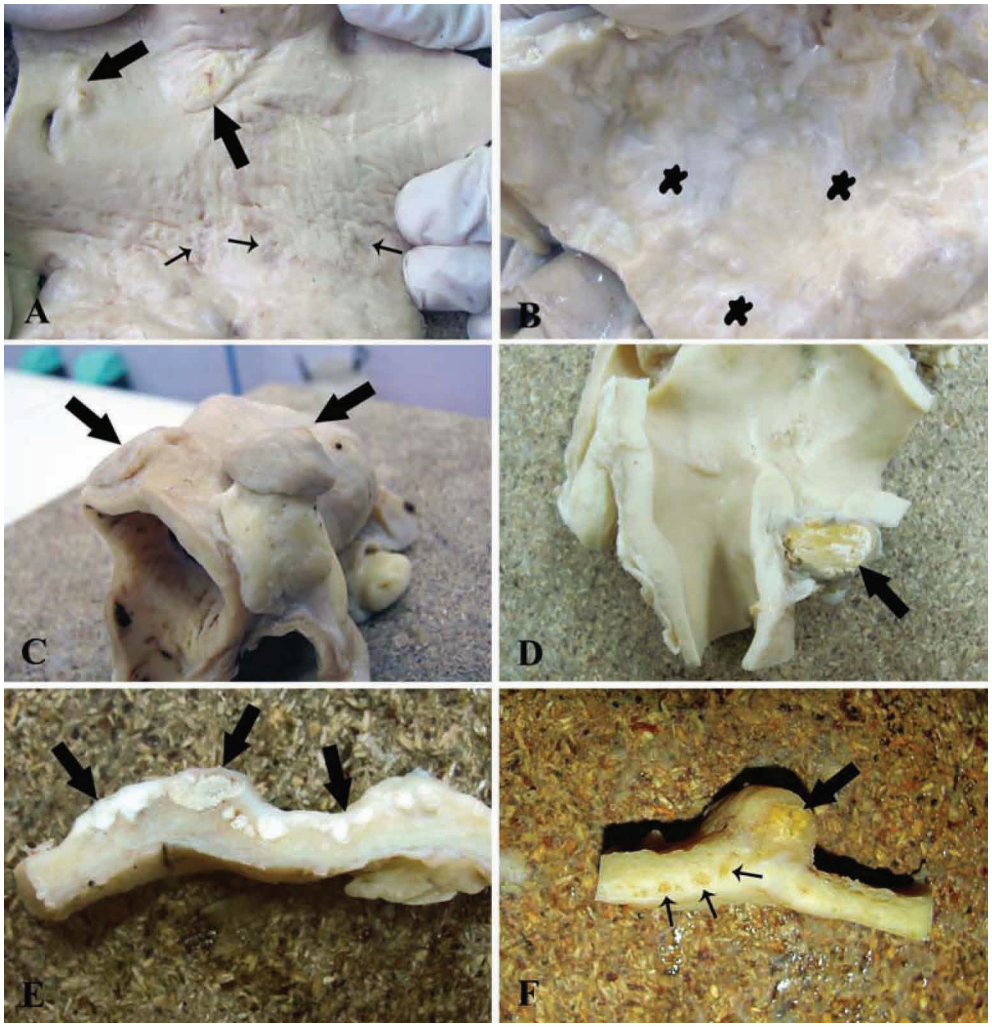

Fig 1. Macroscopic appearance of parasitic aortitis. **A-** Parasitic nodules in the lumen of the aorta *(thick arrows)*, and areas of scar in appearance of star *(thin arrows)*, **B-** Irregular and opaque appearance of calcified areas in the lumen of the aorta *(stars)*, **C-** Parasitic granulomas, surrounded by tough connective tissue, extending outward the aorta serosa *(arrows)*, **D-** Cross sections of parasitic granuloma in serosal surface *(arrow)*, **E-** Calcium deposits along with long axis of intimal surface *(arrows)*, **F-** Parasitic tunnels advancing up to intima, adventitia and serosa *(thin arrows)*, demarcated caseified parasitic granuloma in the serosal surface *(thick arrow)*

Şekil 1. Parazitik aortitisin makroskobik görünümü. **A-** Aorta lümenine doğru çıkıntı yapan parazit nodülleri *(kalın oklar)* ve yıldız görünümündeki sikatriks alanları *(ince oklar)*, **B-** Aorta lümeninde düzensiz ve opak görünümdeki kalsifikasyon alanları *(yıldızlar)*, **C-** Aorta serozasından dışa doğru taşan etrafı sert bağ doku ile sarılı paraziter granulomlar *(oklar)*, **D-** Serozal yüzeydeki paraziter granulomun kesit yüzü *(ok)*, **E-** İntima yüzeyinde uzun eksen boyunca ilerleyen kalsiyum birikimleri *(oklar)*, **F-** İntimadan adventisya ve serozaya kadar ilerleyen kazeifiye parazit tünelleri *(ince oklar)*, serozada demarke durumdaki kazeifiye parazit granulomu *(kalın ok)*

dead and caseous parasitic cysts. This cellular infiltration was generally localised around the old or calcified tunnels *(Fig. 2-F)*. Some areas showed new formation of blood vessels with presence of few fibroblasts.

Chronic granulomatous aortitis: The chronic granulomatous aortitis was the most common type of inflammation. Hyperchromatic and multinucleated giant cells were observed around the dead, degenerated or calcified parasitic cyst walls. A large number of eosinophilic infiltration was present between giant cells. This infiltration was supported by dense macrophages, lymphocytes, and plasma cells *(Fig. 2-F)*. The outermost composed from granulation tissue that including fibroblasts, fibrocytes and newly formed blood vessels. Muscle bundles were hyalinised *(Fig 2-E)*. In some areas, inflammatory cell infiltration was decreased while sclerosis was increased. In eight cases, arteriosclerotic foci with presence of clefts at their centers composed of lymphocytes, macrophages, fibroblasts, and fibrocytes were found. Some cases did not show any inflammatory cell infiltration around the parasitic cysts (8 cases), some of them were calcified (28 cases) and some others revealed inflammatory cell infiltration (26 cases). On the other hand eosinophils and mononuclear cell infiltration were observed without any sign of parasitic cysts in eight cases. The inflammatory reaction against to cysts and calcified cysts formations was observed at the highest rate in the Diyarbakir province *(Fig. 3)*.

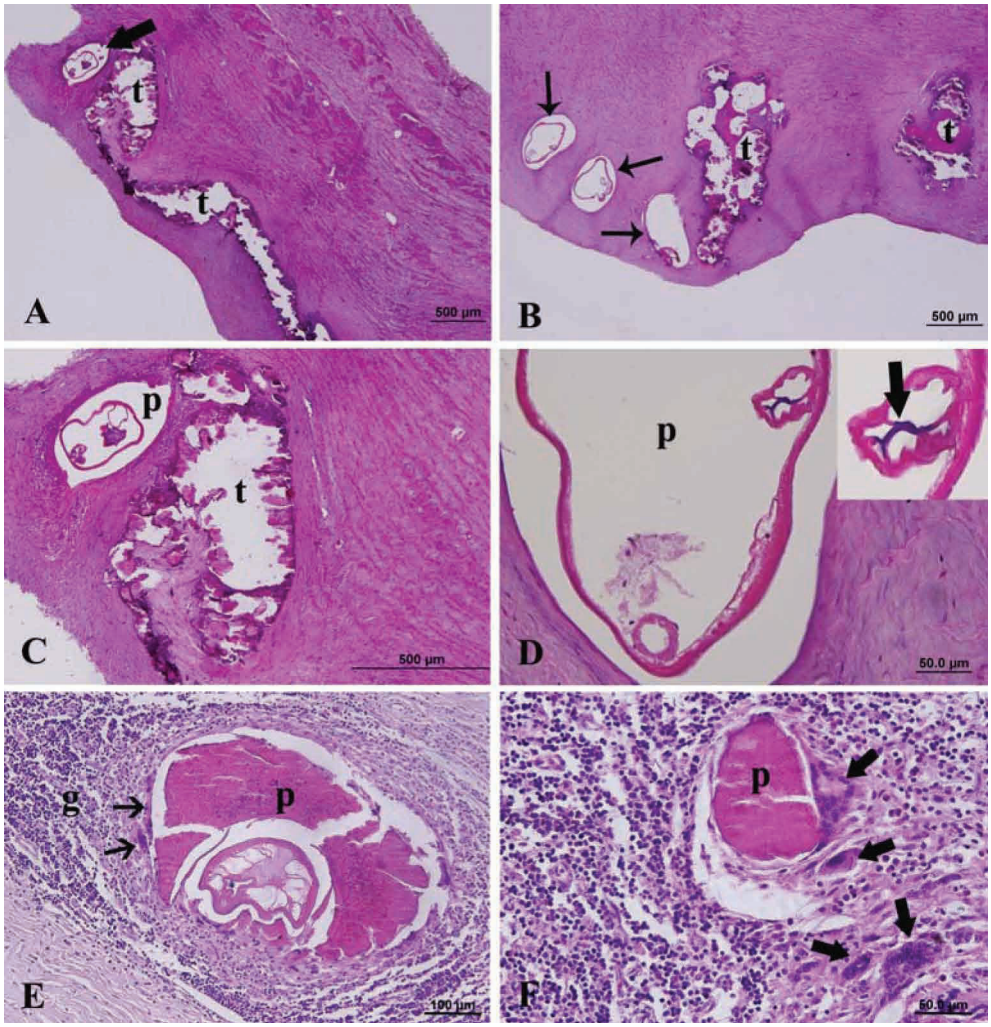

Fig 2. Microscopical aspects of parasitic aortitits. **A-** Calcified tunnels continue along with long axis of intimal surface (t). Parasitic cyst demarcated by a thin connective tissue without any inflammatory reaction *(arrow),* H&E X 40, **B-** Parasitic cysts surrounded by a thin connective tissue and halo in the intimal layer *(arrows)* and parasite tunnels (t) containing hyaline tissue and calcium deposits, H&E X 40, **C-** Calcified wide tunnel (t) progressing in different directions towards the layer of media and parasitic cyst (p) demarcated by the connective tissue, H&E X 100, **D-** An active parasitic cysts (p) surrounded by a large halo and a thin connective tissue, H&E X 100, the closer view of the mikroflaria *(arrow, enlarged figure)*, **E-** Central part of parasitic granuloma is partly caseified in the medial layer, (p) surrounded by giant cells *(arrows)* and connective tissue, H&E X 400, **F-** Completely caseified parasite (p), surrounded by multinucleated giant cells *(arrows),* eosinophils and mononuclear cell infiltration, H&E X 400

Şekil 2. Parazitik aortitisin mikroskobik görünümü. **A-** İntimada uzun eksen boyunca devam eden kalsifiye olmuş tüneller (t). Etrafı ince bir bağ doku ile sınırlandırılmış yangı hücresi bulundurmayan paraziter kist *(ok),* H&E X 40, **B-** İntimada etraflarından ince bir bağ doku ve halo ile çevrili paraziter kistler *(oklar)* içerisinde hyalinize doku ve kalsiyum birikimleri bulunduran parazit tunelleri (t), H&E X 40, **C-** Media katmanına doğru değişik yönlerde ilerleyen kalsifiye olmuş geniş tunel (t) devamında etrafı bağdoku ile sınırlı parazit kisti (p), H&E X 100, **D-** Etrafı ince bir bağ doku ve geniş bir halo ile çevrili aktif parazit kisti (p), H&E X 100, içerisindeki aktif mikroflaria'nın yakından görünümü *(ok, büyütülmüş resim),* **E-** Media katmanında, merkezi kısmen kazeifiye olmuş, çevresinde dev hücreler *(oklar)* ve bağdoku ile sarılı paraziter granülom (p), H&E X 400, **F-** Tamamen kazeifiye parazit (p) etrafında çok çekirdekli dev hücreleri *(oklar),* eozinofil lökositler ve mononükleer hücre infiltrasyonları, H&E X 400

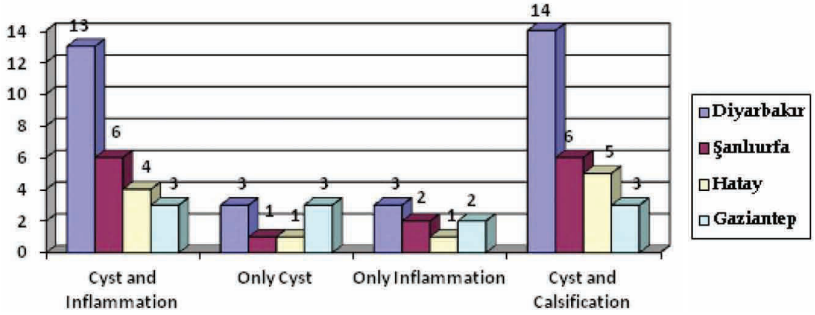

Fig 3. Evaluation of parasitic cysts according to the provinces

Şekil 3. Parazitik kistlerin illere göre değerlendirmesi

Table 1. *Histopathological aspects of parasitic aortitis due to Oncocerca armillata*
Tablo 1. *Onchocerca armillata'nın neden olduğu paraziter aortitisin histopatolojik değerlendirmesi*

Number	Case Number	Inflammation			Sclerosis			Calcification			Parasitic Cyst		
		I	M	A	I	M	A	I	M	A	I	M	A
1	D-18	-	-	-	+	-	-	-	+	-	-	-	-
2	D-68	MEG	ME	M	+	-	-	+	-	-	+	+	-
3	D-23	M	-	-	+	-	-	+	-	-	+	-	-
4	D-58	-	-	ME	-	-	-	-	-	-	-	-	-
5	D-28	ME	M	ME	-	+	-	-	-	-	-	+	+
6	D-17	-	-	-	+	-	-	+	-	-	+	-	-
7	D-75	ME	ME	ME	+	+	-	+	+	-	+	-	-
8	D-7	-	M	M	-	-	-	-	-	-	-	-	-
9	D-12	-	-	M	-	-	+	+	-	-	-	-	+
10	D-69	-	MD	M	+	+	-	-	-	-	+	+	-
11	D-72	ME	ME	MEG	-	+	-	+	+	+	+	+	+
12	D-86	ME	-	MEG	-	+	+	-	+	+	-	+	+
13	D-67	M	M	-	+	-	-	+	-	-	+	-	
14	D-4	ME	MG	M	+	+	+	+	+	-	+	+	-
15	D-3	MG	M	M	+	-	+	+	-	-	+	-	-
16	D-56	-	MG	M	-	+	+	-	+	-	-	+	-
17	D-39	-	M	M	-	-	-	-	-	-	-	-	-
18	D-21	-	M	M	+	-	+	+	+	-	+	+	-
19	D-29	ME	MEG	ME	+	+	-	-	+	-	-	+	-
20	D-44	ME	-	ME	+	-	-	+	+	-	+	+	-
21	D-30	-	M	M	-	-	-	-	-	-	-	-	+
22	S-10	-	-	ME	-	-	+	-	-	-	-	-	+
23	S-75	-	ME	ME	-	-	-	-	-	-	-	-	-
24	S-14	M	-	-	-	-	-	+	-	-	+	-	-
25	S-65	-	ME	M	-	-	-	-	-	-	-	-	-
26	S-64	M	MG	MG	-	+	+	-	+	-	-	+	+
27	S-21	MEG	MEG	MEG	+	+	+	+	+	+	+	+	+
28	S-90	MEG	MEG	MEG	+	+	+	+	+	+	+	+	+
29	S-51	M	-	M	+	-	+	+	-	-	+	-	+
30	S-17	-	ME	-	-	+	-	-	-	-	+	-	+
31	GA-52	-	-	-	+	-	-	+	-	-	+	-	-
32	GA-65	-	-	M	-	-	-	-	-	-	-	-	-
33	GA-1	ME	-	-	+	-	-	+	-	-	+	-	-
34	GA-27	-	ME	-	-	-	-	-	-	-	+	+	-
35	GA-78	-	-	-	-	-	-	-	-	-	-	-	+
36	GA-30	ME	ME	-	-	-	-	-	-	-	-	-	-
37	GA-18	ME	ME	-	-	-	-	-	-	-	+	-	-
38	GA-17	-	-	-	-	-	-	+	+	-	+	+	-
39	H-26	ME	ME	MEG	-	+	+	+	+	+	+	+	+
40	H-86	ME	-	-	+	+	-	+	+	-	+	+	-
41	H-36	-	-	-	+	-	-	+	-	-	+	-	-
42	H-23	M	M	-	+	-	-	+	-	-	+	-	-
43	H-48	ME	MEG	MEG	-	+	+	+	+	+	+	+	+

DISCUSSION

Aortic onchocercosis seen in different parts of the world [3,10,15,18]. Previous studies reported high incidence of onchocercosis in the aorta (50-100%) [1,4,15]. Use of anti-helmentic drugs and pesticides decreased the presence of *Onchocerca* spp. in the both vectors and hosts [13]. In this study, 43 (10.75%) of 400 animals from four different

provinces showed the presence of aortic onchocercosis. This means that antihelmentic drugs were not effectively used in Turkey.

Recent studies showed Onchocercosis have still seen in different parts of the world [11,13,14,17]. Alibasoglu et al.[1] reported that onchocercosis was seen in the southeastern provinces of Turkey in cattle, was not seen in western Anatolia provinces, and it was concluded that the disease was seen in tropical climates. However, according to recent study conducted by Beytut et al.[6] the parasite was also seen at Kars province where the climate is severely cold than that of southern regions, also some other cases reported from Greece [14]. This means that Onchocercosis can also be seen in cold places. It is known that *Onchocerca* spp. is carried by black flies and mosquitoes [8,14]. As these flies can be found all over the world it is hard to establish a direct relationship with climate and the incidence of the disease.

Onchocerca armillata is a parasite originated from *Onchocerca* spp. It is known that flarial forms are found in bloodstream and adult forms are reside in around arcus orta. There is any report about parasitic aortitis caused by other *Onchocerca* species which is located around arcus aorta [1,8,10]. In this study, we decsribed parasitic aortitis due to *Onchocerca armillata* around arcus aorta

In our country the prevalence and pathology of aortic onchocercosis have been only studied by Alibaşoğlu et al.[1] and Beytut et al.[6]. Alibaşoğlu et al.[1] examined the aortas of animals around Cukurova and Western Anatolia regions and they seen intensive infestation in the Cukurova region. Materials of the present study were selected from the cities that are close together and on the same line in the Southeast provinces. Between these cities aortic onchocercosis was mostly seen in Diyarbakir province. This was followed by Sanliurfa, Gaziantep and Hatay provinces. According to *Fig. 3*; only cysts, the inflammatory reaction against to cysts and calcified cyst formations were occurred at the highest rate in the Diyarbakir province. Only the cyst formation and inflammation were observed in all the provinces with almost equal intensity. The data obtained from the present study indicates that antihelmentic and pesticide drugs are not effectively used in the Diyarbakir and Sanliurfa provinces.

Ogundipe et al.[10] reported that in the parasitic cysts, live, dead and calcified tissues were located close to each other. In the present study the finding of degenerated or calcified cysts located close to each other were compatible with Ogundipe et al.[10] and other studies [1,10,16]. Similarly, degenerated or calcified cysts were surrounded by the parasitic granulomas that contains giant cells, eosinophils, macrophages, lymphocytes and fibroblasts were also compatible with previous findings [10].

The absence of any inflammatory reaction around tunnels, and some parasitic cysts was remarkable. However, in some cases, these parasite tunnels were found to be calcified. It was previously reported by many researchers that no inflammatory reaction occur against to live and vibrant forms of parasite [1,15,16]. Some of the information in the literature show that a substance released from live cuticula of parasite body prevents reaction against to the parasite [15,17].

With this study, the prevalence and pathology of *Onchocerca armillata* in cattle was examined in detail in the Southeastern region of Turkey.

REFERENCES

1. Alibaşoğlu M, Gölesuk K, Erturk E, Güler S: Türkiyede sığırlarda görülen onchocerciasis olayları (*Onchocerca armillata Raillet ve Henry 1909*). *Ankara Üniv Vet Fak Derg*, 16, 50-60, 1969.

2. Wildenburg G, Kromer M, Buttner DW: Dependence of eosinophil granulocyte infiltration into nodules on the presence of microfilariae producing *Onchocerca volvulus*. *Parasitol Res*, 82, 117-124, 1996.

3. Bhatia BB: *Onchocerca armillata Railliet and Henry 1909,* a study of the infection in Indian sheep with remarks on its bovine hosts. *Ind Vet J,* 37, 394-397, 1960.

4. Chowdhury N, Chakraborty RL: On concurrent and early aortic Onchocerciasis and Spirocerciasis in domestic goats *(Capra hircus). Z Parasitenkunde,* 42, 207-212, 1973.

5. Gupta PP, Nagpal SK: Spontaneous aortic atherosclerosis in sheep. *Vet Pathol*, 16, 548-552, 1979.

6. Beytut E, Akca A, Bain O: Teat onchocercosis in cows with reference to prevalence, species involved and pathology. *Res Vet Sci*, 78, 45-51, 2005.

7. Oryan A, Valinezhad A, Bahrami S: Prevalence and pathology of camel filariasis in Iran. *Parasitol Res,* 103, 1125-1131, 2008.

8. Maxie MG, Youssef S: Diseases of the vascular system. **In,** Maxie MG, Robinson WF (Eds): Jubb, Kennedy and Palmer's Pathology of Domestic Animals. Vol. 3, pp. 91-92, Elsevier Science Publishing, Inc., USA 2007.

9. Neary JM, Trees AJ, Ekale DD, Tanya VN, Hetzel U, Makepeace BL: *Onchocerca armillata* contains the endosymbiotic bacterium *Wolbachia* and elicits a limited inflammatory response. *Vet Parasitol,* 174, 267-276, 2010.

10. Ogundipe GA, Ogunrinade AF, Akpavie SO: The prevalence, gross lesions and histopathology of aortic onchocerciasis in Nigerian cattle. *Vet Q*, 6, 85-89, 1984.

11. Mtei BJ, Sangha HJN: Aortic onchocercosis and elaeophorosis in traditional TSZ-cattle in Tabora (Tanzania): Prevalance and pathology. *Vet Parasitol*, 36, 165-170, 1990.

12. Achukwi MD, Harnett W, Renz A: *Onchocerca ochengi* transmission dynamics and the correlation of *O. ochengi* microfilaria density in cattle with the transmission potential. *Vet Res,* 31, 611-621, 2000.

13. Grillet ME, Villamizar NJ, Frontado HL, Cortez J, Escalona M, Botto C, Basanez MG: Vector competence of Simulium oyapockense s.l. and S. incrustatum for *Onchocerca volvulus:* Implications for ivermectin-based control in the Amazonian focus of human onchocerciasis, a multi-vector-host system. *Acta Trop*, 107, 80-89, 2008.

14. Otranto D, Torres FD, Papadopoulos E, Petrić D, Ćupina AI, Bain O: Tracking the vector of *Onchocerca lupi* in a rural area of Greece. *Emerg Infect Dis*, 18, 1196-1200, 2012.

15. Cheema AH, Ivochli B: Bovine onchocerciasis caused by *O. armillata* and *O. gutturosa*. *Vet Pathol*, 15, 495-505, 1978.

16. Specht S, Brattig N, Buttner M, Buttner DW: Criteria for the differentiation between young and old *Onchocerca volvulus* filariae. *Parasitol Res,* 105, 1531-1538, 2009.

17. Erttmann KD, Buttner DW: Immunohistological studies on *Onchocerca volvulus* paramyosin. *Parasitol Res,* 105, 1371-1374, 2009.

18. Zak F: Parasitic aortopathy due to *Onchocerca armillata* in cattle. *Path Microbiol,* 43,150, 1975.