Endometrial Extension of Cervical Intraepithelial Neoplasm

Tülay SAYILGAN[1], **Feriha CİNHÜSEYİNOĞLU**[1], **Deniz ÖZCAN**[2]

İstanbul, Turkey

Extension of cervical intraepithelial neoplasia to the endometrium is a rare entity. In this study a seventy one year old patient with CIN 3 which replaced the endometrial tissue as squamous dysplasia is presented. This entity should be considered in the differential diagnosis of squamous epithelial lesions both in currettage and resection specimens of uterus. Though its prognostic significance is not briefly known, recognition of more cases might lead to understand its effects on the clinical course.

Key Words: In situ cervix carcinoma, CIN, Extension to uterus

Gynecol Obstet Reprod Med;14:2 (136 - 138)

Introduction

Extension of cervical intraepithelial neoplasia (CIN) to the endometrium is a rare entity. The lesion can also spread to the vagina, fallopian tubes and the ovaries as well.[1,2] In this study a seventy-one year old patient with CIN 3, which replaced the endometrium as squamous dysplasia is presented. The diagnosis can be difficult from the curettage material, if this entity is not considered.

Case Report

A 71 year old patient gravida 2, para 2, presented to a community hospital with the complaints of postmenopausal bleeding and vaginal discharge. The curetting samples were sent to their pathology section where it had been reported as 'invasive squamous cell carcinoma on the surface of an endocervical polyp' (Figure 1). She was referred to our hospital for total abdominal histerectomy and bilateral salpingo-oophorectomy. The patient was externed without any complications. The whole specimen was submitted for examination. On gross observation, the uterus measured 7,5x6.5x3.5 cm. The endocervical canal appeared stenotic. The endometrium and the myometrium were 0,1 cm. and 1,1 cm. thick respectively. The entire surface of the cervical canal and the endometrial cavity appeared gray-white, wrinkled and skin-like. There was no lesion growing into the endometrial cavity or infiltrating the myometrium. The fallopian tubes showed no abnormality and the ovaries were atrophic. Microscopy revealed that the epithelium of the endocervical surface and crypts consisted of atypical squamous cells with nuclear enlargement, hyperchromasia, irregular nuclear membranes, frequent mitoses (typical or atypical) and loss of polarity throughout the epithelium in most of the slides. Depending on these criteria, it was diagnosed as cervical intraepithelial neoplasia grade 3 (CINIII) according to CIN grading system. Focal CINII areas were also present. The lesion involved the endocervix completely to continue in all of the endometrial samples, except a few endometrial glands and a thin endometrial stroma in only a small area. A thick eosinophylic basal membrane and mononuclear inflammatory infiltration was observed under the lesion (Figure 2). The atypical cells covered the bottom third and focally two thirds of the epithelium in the endometrial samples with maturation on the surface. Hyperchromasia, nuclear membrane irregularity, nuclear crowding were not as severe as in the cervical lesion. The mitosis were fewer. It was evaluated as the extension of the cervical lesion as CINII. The patient is well at present two years after the operation .

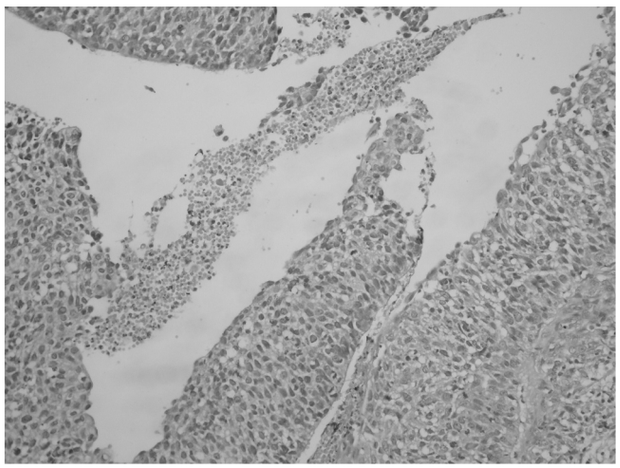

Figure 1: Endometrial curettage samples revealed atypical squamous epithelium fragments. Determination of invasion might be difficult (Hematoxylen and Eosin, magnification x 200)

[1]*Okmeydanı Training Hospital Pathology and* [2]*Head of the Pathology Department, İstanbul*

Adress of Correspondence: *Tülay Sayılgan*
4. Etap 2. Kısım D 5 Blok D:44
Başakşehir İkitelli, İstanbul
tulaysay@gmail.com

Submitted for Publication: *12. 05. 2008*
Accepted for Publication: *28. 06. 2008*

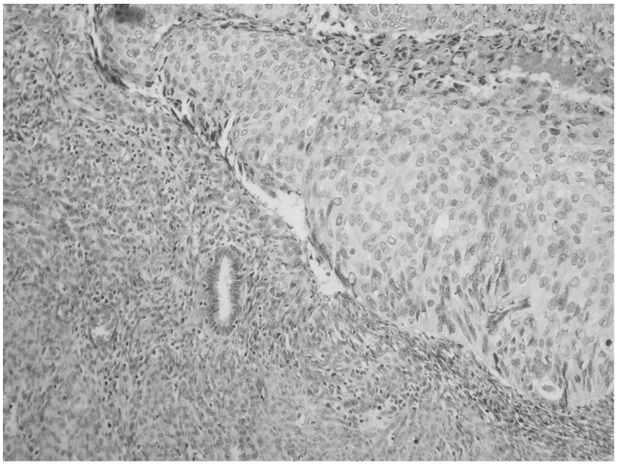

Figure 2: Uterine sections demonstrated the atypical squamous epithelium replacing endometrium excluding a few glands (Hematoxylen and Eosin, magnification x 400)

Discussion

Squamous cell lesions of the endometrium are squamous metaplasia, primary and secondary in situ and invasive squamous cell carcinomas. Benign squamous epithelium in the endometrium is usually a metaplastic process originating from the endometrial reserve cells. Squamous epithelium can also accompany endometrial adenocarcinomas as benign metaplastic epithelium in adenoacanthoma or as a malignant component in mixed adenosquamous carcinoma.[1] The existence of neoplastic squamous epithelium in the endometrium not associated with a malignancy, is a rare event. It can occur either secondary to a cervical intraepithelial or invasive/microinvasive squamous cell carcinoma;[1,2] or as primary squamous cell endometrial carcinoma (PSCCE). PSCCE, in situ or invasive, is very rare. Chronic irritation of intrauterine devices, chronic endometritis, tuberculosis, syphilis, vitamine A deficiency, hypoestrogenemy, prolapsus uteri, HPV infections are defined as predisposing factors. Squamous dysplasia of the endometrium can preceed this lesion. The pathologic diagnosis of PSCCE is based on 'Fluhmann's criteria' which are revised by WHO: (i) no coexisting glandular carcinoma in the endometrium; (ii) no demonstrable connection between the endometrial lesion and the stratified squamous epithelium of the cervix; (iii) no primary cervical carcinoma.[1] In the present case, it was demonstrated that the cervical squamous intraepithelial lesion involved the cervix and the endometrium totally without skipping any areas up to the fallopian tubes. According to Fluhmann's criteria, PSCCE is excluded. It is diagnosed as 'CINIII with endometrial extension'. It is considered to be a secondary event in the endometrium rather than a primary lesion.

Cervical cancer can spread to uterus most commonly in two fashions: Through deep myometrial penetration and by lymphatic dissemination.[1] Another mechanism is direct superficial endometrial extension . This is called 'lateral' or 'horisontal' extension, which can occur upwards as endometrial, tubal and ovarian or rarely downwards as superficial vaginal extension.[1,2] For this type of cancer spreading, it is reported that the cells of the cervical in situ or invasive squamous cell carcinoma mechanically destruct and replace the endometrium. The occurence of squamous cell dysplasia of the endometrium is also explained by the 'field carcinogenesis' theory. According to this concept, various grades of displasia or cancer develop in different areas of the the genital tractus, as a result of the same carcinogenic environment.[1]

Cervical in situ or invasive squamous cell lesions with surface spread into the endometrium are seen at an average age of 60. It is 10 years older than that for cervical cancer without extension.[1] Our case is 71 years old, which is consistent with the literature data. It is reported that almost the entire endometrium is involved with direct continiuity in the cervix, which is also true for our case. Chronic inflammation was present in these cases with pyometra and cervical stenosis.[1] The cervical canal of our case was also clinically stenotic, and the patient was complaining about vaginal discharge and bleeding.

The distinction of invasion and the origin of the atypical squamous epithelium in the currettage material can be confusing (Figure 1). When atypical squamous epithelium is seen in the curretage samples, primary and secondary endometrial squamous cell lesions should also be considered in the differential diagnosis. But the exact diagnosis can only be made from the hysterectomy material.

The previous reports indicate that either cervical or uterine component of similar lesions is invasive/microinvasive in most of the cases.[1,2] Extension of CIN without invasion to the uterus is rare, as seen in our case.

The endometrial extension of invasive cervical cancer is reported to be a poor prognostic factor. But the importance of CIN spreading into endometrium is not sufficiently known, because of the limited number of the cases. It is suggested that, it does not change the stage of the disease; because there is no myometrial invasion.[1] This entity might be more frequent than reported and its prognostic significance should be explored by following up more cases. Abdominal ultrasound or a dilatation curettage might be useful in every CINIII case in order not to miss this entity.

Endometriyuma Yayılım Gösteren Servikal İntraepitelyal Neoplazm

Tülay SAYILGAN, Feriha CİNHÜSEYİNOĞLU

Deniz ÖZCAN

İstanbul, Türkiye

Servikal intraepitelyal neoplazilerin endometriuma yayılımı nadir bir olaydır. Bu çalışmada endometriyuma skuamoz displazi halinde yayılım gösteren 71 yaşında CINIII olgusu sunulmaktadır. Bu antite hem küretaj, hem rezeksiyon piyeslerinde uterusa ait skuamoz lezyonların ayırıcı tanısında yer almalıdır. Prognostik önemi tam olarak bilinmemekle birlikte daha fazla olgunun tanınması ile klinik gidişe olan etkileri saptanabilir.

Anahtar Kelimeler: Servikal intraepitelyal neoplazm, CIN, Endometriyal yayılım

References

1. Kanbour AI, Stock RJ. Squamous cell carcinoma in situ of the endometrium and fallopian tube as superficial extension of invasive cervical carcinoma. Cancer. 1978; 42:570-80.

2. Tan GC, Isa MR, Ng SP, Jamil YM.Unusual form of superficial spreading microinvasive squamous cell carcinoma of uterine cervix involving the endometrium of uterus. J Obstet Gynaecol Res. 2004;30:363-7.