Case Report

Gastrointestinal Stromal Tumor Mimicking Ovarian Tumor

Özlem Seçilmiş KERİMOĞLU[1], Füsun BABA[2], Aybike TAZEGÜL[1], Hüsnü ALPTEKİN[1], Hasan ACAR[1], Çetin ÇELİK[1]

Konya, Turkey

Malignant gastrointestinal stromal tumors are rare mesenchymal tumors originating from the gastrointestinal tract. Making a differential diagnosis with gynecologic masses may be difficult in the preoperative period. The patient was a 45- year-old woman who presented to our clinic with a palpable mass filling the pelvis. The CA 125 value was 42.7 U/ml. She underwent right hemicolectomy, total omentectomy, total abdominal hysterectomy, bilateral salpingo-oophorectomy and bilateral pelvic and para-aortic lymph node dissection since the frozen section assessment of the biopsy from the right colon was reported as a tumoral mass probably originating from the ovary. Tumoral tissue showed diffuse cytoplasmic membraneous staining immunohistochemically with CD117, showed strong focal strong cytoplasmic staining with SMA. It was stained negative with desmin, S-100 and CD34. Molecular analysis of KIT gene was performed, we didn't detect mutations of exon 9 or 11. Surgical exploration of pelvic masses with undetermined origins should be performed in multidiciplinary hospitals including gynecological oncology and surgical oncology teams. Histopathological examinations should be performed by experienced pathologists.

Key Word: Gastrointestinal stromal tumor, Ovary

Gynecol Obstet Reprod Med 2012;18:170-172

Introduction

Gastrointestinal stromal tumors (GIST) are rare mesenchymal tumors originating from the gastrointestinal tract. Its differential diagnosis among possible gynecological masses is hard due to the difficulty in the differential diagnosis using examination methods and radiological imaging methods in the preoperative period and limited contribution of the examination performed using frozen section histopathological evaluation methods intraoperatively.[1,2] In this case report, we aimed to present a patient with a GIST who underwent an operation in our clinic with the prediagnosis of a pelvic mass.

Case Report

A 45 year old patient who had complaints of oligomenorrhea, abdominal and groin pain for the last 4 months presented to our hospital as she felt a palpable swelling in the abdomen. Her medical history did not included any gastrointestinal or gynecological complaints prior to these complaints. While there was a soft mass reaching the umblicus on the physical examination, the uterus was normal in size; however, the ovaries could not be precisely evaluated on the gynecological examination. On abdominal ultrasonography, a big heterogenous mass lesion filling the pelvic area, consisting of approximately 106x87 mm of cystic component in the left upper quadrant and the origin of which could not be exactly distinguished, was detected. Minimal fluid was detected between the neighbouring intestinal loops. The uterus was normal in size; however, the ovaries could not be evaluated due to the pelvic mass on ultrasonography as well. CA 125 was mildly elevated, measured as 42.7 U/ml.

A mass of approximately 15x16 cm in size, filling the whole abdomen, originating from the ceacum was observed intraoperatively. The uterus was normal in size, and the bilateral fallopian tubes and ovaries were atrophic. The general surgery team participated the operation. Right hemicolectomy was performed along with removal of the mass. Furthermore, a 10 cm portion of the intestinal loop in which a mass was detected was excised and an end-to-end anastomosis was performed. The patient was then handed over to the gynecology team after having performed an ileocolic anastomosis. The mass was sent for frozen section examination. Total abdominal hysterectomy, bilateral salpingo-oophorectomy and bilateral pelvic- para-aortic lymph node sampling were performed

[1]Selçuk Univercity Selçuklu Medicine Faculty, Obstetrics and Gynecology and [2]Pathology, Konya

Address of Correspondence: *Özlem Seçilmiş Kerimoğlu*
Selçuk Üniversitesi Selçuklu Tıp Fakültesi Kadın Hastalıkları ve Doğum Ana Bilim Dalı. Konya
ozlemsecilmis@hotmail.com

Submitted for Publication: *11. 07. 2011*
Accepted for Publication: *12. 12. 2011*

since the mass was reported as a possible tumoral mass originating from the ovary according to the frozen section assessment.

On histopathological examination, a 16x12x8 cm portion of smooth, broad-based tumoral mass was observed in the serozal surface of the excised colon segment (Figure 1). Tumor cells comprising fusiform cells histologically showed moderate cellular pleomorphism (Figure 2). The number of mitosis was higher than 15/10 HPF; the Ki 67 score was higher than 10%. The tumoral mass showed diffuse cytoplasmic membraneous staining with CD 117, and focal strong cytoplasmic staining with SMA (Figures 3,4). It was stained negative with desmin, S-100, CD 34. The histopathological diagnosis was reported as malignant gastrointestinal tumor.
Molecular analysis of KIT gene with DNA sequencing was performed to identify mutations of exon 9 and 11 after polymerase chain reaction and amplification of genomic DNA. Our patient had no mutations within KIT exon 9 or 11.

The patient completed the postoperative recovery period was handed over to the medical oncology department for adjuvant chemotherapy.

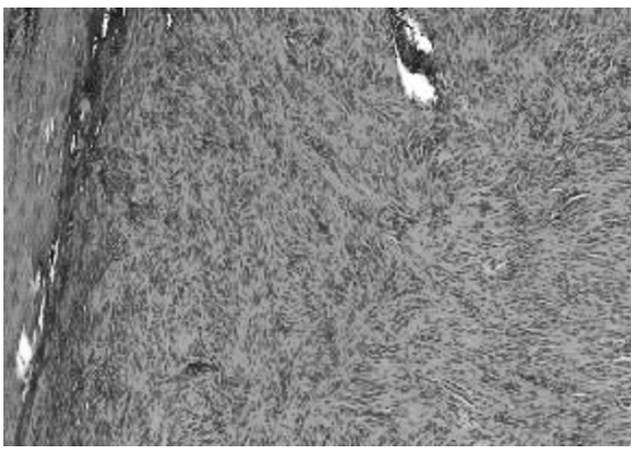

Figure 1: The section that the tumor developing from the intestinal serosa is seen, H&E, x20

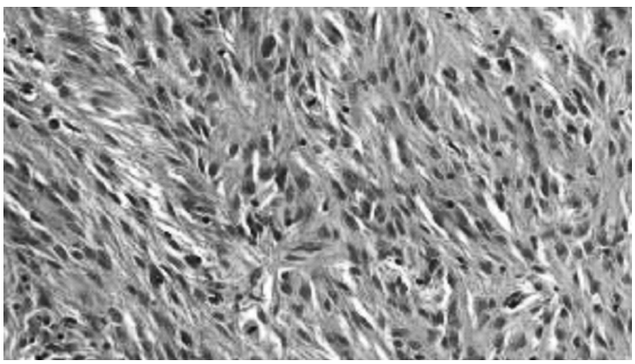

Figure 2: Tumor section comprising fusiform cells, H&E, x80



Figure 3: Tumor cells showing diffuse cytoplasmic staining with CD 117

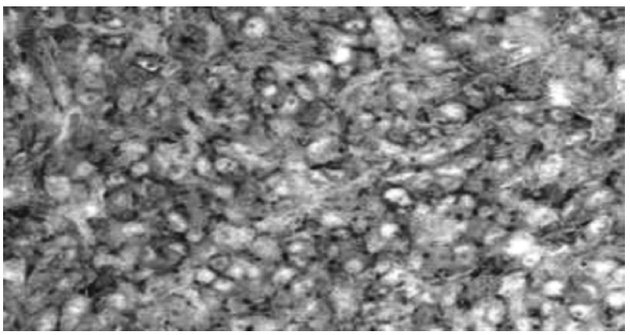

Figure 4: Tumor cells showing focal cytoplasmic staining with SMA

Discussion

Gastrointestinal tumors are among the rare tumors of this system and are most commonly seen in the stomach. In connective tissue, they are thought to originate from cells regulating the autonomous behavior of the gastrointestinal system.[3]

Radiological and histopathological assessments may indicate a gastrointestinal stromal tumor; however, the definite diagnosis can be made immunohistochemically.[4] Most of these tumors express CD 117 (72-94%) and CD 34 (70-78%).

Indiscrimination of GIST with pelvic masses has also been formerly reported. The fact that these masses can seen with mild CA 125 elavation and heterogenous appearaence makes their differential diagnosis with primary or metastatic ovarian neoplasms difficult. As in some case reports like ours, the gastrointestinal origin could only be understood postoperatively.[1,2] The fact that the definite diagnosis can be made immunohistochemically makes frozen section examination difficult.

While postoperative adjuvent terapy is not required for small (<5 cm) tumors with low mitosis rates (<5/50 HPF), treatment with a tyrosine kinase inhibitor (imatinib) is required for large cases with high mitosis rates as in our case.[5] The leading factor increasing the effectiveness of chemotherapy and affecting survival is complete removal of the tumor.

GISTs generally contain activating mutations of KIT proto-oncogene (75%-85%) or less frequently the platelet derived growth factor receptor (PDGFRA) gene (5%-7%) (6-8). Imatinib inhibits receptor tyrosine kinases including KIT and PDGFRA. In addition to complete surgical resection, clinical response to chemotherapy with imatinib may correlate with mutational status of KIT and PDGFRA. Several studies reported that tumours containing KIT exon 11 mutations are more likely to response imatinib treatment when compared with KIT exon 9 mutations or wild types[9-11] Altough the tumoral mass showed diffuse cytoplasmic membraneous staining with CD 117 in our study, we didn't detect mutations of KIT exon 11 or 9 which are the most common.

The possibility of non-gynecological factors of pelvic masses with suspicion of malignancy and obscure origin should be kept in mind and these cases should be operated in centers that possess gynecological oncology, surgical oncology and pathologists experienced in their field.

Over Tümörünü Taklit Eden Gastrointestinal Stromal Tümör: Vaka Sunumu

Malign gastrointestinal tümörler gastrointestinal kanalın mezenşimal kökenli nadir tümörleridir. Ameliyat öncesi dönemde jinekolojik kitlelerle ayırıcı tanısını yapmak güç olabilir. Vaka konusu olan hasta, kliniğimize pelvisi dolduran palpable bir kitle ile başvuran 45 yaşında bir hastadır. Ca 125 ölçümü 42.7 U/ml'dir. Ameliyat sırasında kitlenin frozen kesit değerlendirmesi muhtemelen over kaynaklı tümöral oluşum olarak rapor edildiği için total abdominal histerektomi, bilateral salpingooferektomi, bilateral pelvik-paraaortik lenfadenektomi ve sağ hemikolektomi uygulandı. Tümöral dokununu immünhistokimyasal incelemesinde CD117 ile difüz stoplazmik boyanma, SMA ile kuvvetli fokal stoplazmik boyanma tespit edildi. Demsin, S-100 ve CD34 ile boyanma olmadı. KIT geni moleküler analizi yapıldı ve ekzon 9 veya 11 mutasyonu tespit edilmedi. Kaynağı net olarak belirlenemeyen pelvik kitlelerin cerrahi eksplorasyonu jinekolojik onkoloji ve cerrahi onkoloji ekiplerinin bulunduğu multidisipliner hastanelerde yapılmalı ve histopatolojik değerlendirme, konusunda deneyimli uzmanlarca yapılmalıdır.

Anahtar Kelimeler: Gastrointestinal stromal tümör, Over

References

1. Carlomagno G, Beneduce P: A gastrointestinal stromal tumor (GIST) masquerading as an ovarian mass. World J Surg Oncol 2004:13;2:15.
2. Davies M, Crosbie EJ, Mamtora H, Verma S, Formela L, Slade RJ: Gastrointestinal stromal tumour presenting as an ovarian tumour. J Obstet Gynaecol 2010;30:324-5.
3. de Silva CM, Reid R: Gastrointestinal stromal tumors (GIST): C-kit mutations, CD117 expression, differential diagnosis and targeted cancer therapy with Imatinib. Pathol Oncol Res 2003;9:13-9.
4. Pidhorecky I, Cheney RT, Kraybill WG, Gibbs JF: Gastrointestinal stromal tumors: current diagnosis, biologic behavior, and management. Ann Surg Oncol 2000; 7:705-12.
5. DeMatteo RP: The GIST of targeted cancer therapy: a tumor (gastrointestinal stromal tumor), a mutated gene (c-kit), and a molecular inhibitor (ST1571). Ann Surg Oncol 2002;9:831-9.
6. Medeiros F, Corless CL, Duensing A, et al. KIT-negative gastrointestinal stromal tumors: prof of concept and therapeutic implications. Am J Surg Pathol 2004;28:889-94.
7. Heinrich MC, Corless CL, Duensing A, et al. PDGFRA activating mutations in gastrointestinal stromal tumors. Science 2003;299:708-10.
8. Hirota S, Ohashi A, Nishida T, et al. Gain-of-function mutations of platelet-derived growth factor receptor α gene in gastrointestinal stromal tumors. Gastroenterology 2003; 125:660-7.
9. Verweij J, Casali PG, Zalcberg J, et al. Progression-free survival in gastrointestinal stromal tumours with high-dose imatinib: Randomised trial. Lancet 2004;364:1127-34.
10. Heinrich MC, Owzar K, Corless CL, et al. Correlation of kinase genotype and clinical outcome in the North American Intergroup Phase III Trial of imatinib mesylate for treatment of advanced gastrointestinal stromal tumor: CALGB 150105 Study by Cancer and Leukemia Group B and Southwest Oncology Group. J Clin Oncol 2008;20: 5360-7.
11. Debiec-Rychter M, Sciot R, Le CA, et al: KIT mutations and dose selection for imatinib in patients with advanced gastrointestinal stromal tumours. Eur J Cancer 2006;42:1093-1103.