Pelvic Ectopic Adrenal Tissue Leading to Benign Gynecological Pathologies in a Mosaic Turner's Syndrome Patient: A Case Report

Aslıhan YAZICIOĞLU[1], Özge Senem YÜCEL[1], Mert TURĞAL[1], Ferdi VAİZOĞLU[1,2], Özlem TANAS[3] Kemal BEKSAÇ[4], Bülent TIRNAKSIZ[4], Alp USUBÜTÜN[3], M. Sinan BEKSAÇ[1]

Ankara, Turkey

Benign gynecological pathologies in patients with Turner's syndrome were described in the medical literature. Herein, we present a 39-year-old woman with mosaic Turner's syndrome (45,0X/46,X,i(X)q10) complaining about bleeding and persistent pelvic pain. In physical examination, she presented normal secondary sex development, normal breast, normal pubic and axillary hair. The external genitalia were also normal. Her laboratory examination showed elevated gonadotropin levels, decreased 17betaestradiol levels and normal plasma androgens and cortisol levels. At transabdominal ultrasonography multiple myoma and irregular thickening of the endometrium were suspected. At laparotomy, total abdominal hysterectomy and bilateral salpingectomy were performed. Histopathological examination revealed multiple leiomyoma, secretory endometrium and ectopically localized adrenal tissue. Since its known that both myoma uteri and secretory changes in endometrium develop primarily in woman of reproductive age and their growth is estrogen dependent, the source of estrogen in the present case was thought to be the ectopic adrenal tissue located just beneath the left salpinx. This seems to be the first report of the occurence of benign gynecological pathologies due to the ectopic adrenal tissue in a mosaic Turner's syndrome patient without hormone replacement therapy.

Key Words: Mosaic turner's syndrome, Myoma, Secretory endometrium, Ectopic adrenal tissue

Gynecol Obstet Reprod Med 2012;18:163-165

Introduction

Uterine leiomyomas (fibroids or myomas) are the most common pelvic tumor in women.[1-3] They are benign monoclonal tumors arising from the smooth muscle cells of the myometrium. They arise in reproductive age women and typically present with symptoms of abnormal uterine bleeding or pelvic pain/pressure. Not only the epidemiology of leiomyomas but also secretory changes in the endometrium are parallel to the ontogeny and life cycle changes of the reproductive hormones estrogen and progesterone.[2] Those findings are considered to be unexpected in a patient with Turner's syndrome who is not on a hormone replacement therapy. Herein, we report a case of mosaic Turner's syndrome which had benign gynecological pathologies due to hormonal effect of the ectopic adrenal tissue. The clinician should always suspect an underlying hormone secreting lesion in case of Turner's syndrome with findings of estrogenisation. Finally, to the best of our knowledge this is the first report of association of Turner's syndrome and ectopic adrenal tissue in the same patient.

[1] Department of Obstetrics and Gynecology Hacettepe University Faculty of Medicine, Ankara
[2] Department of Obstetrics and Gynecology Karayazı State Hospital, Erzurum
[3] Department of Pathology Hacettepe University Faculty of Medicine, Ankara
[4] Department of General Surgery Hacettepe University Faculty of Medicine, Ankara

Address of Correspondence: Özlem Seçilmiş Kerimoğlu, Selçuk Univercity Selçuklu Medicine Faculty Department of Obstetrics and Gynecology, Konya ozlemsecilmis@hotmail.com

Submitted for Publication: 30. 11. 2012
Accepted for Publication: 19. 12. 2012

Case Report

A 39-year-old single nulligravid woman admitted to our hospital because of vaginal bleeding and persistent pelvic pain. Her vital signs were normal with an hemotocrit value of 24,8%. Physical examination revealed that woman had the Turner phenotype, with a height of 135cm; weight of 36 kg (body mass indeks: 19.7); cubitus valgus and short webbed neck. She presented normal secondary sex development, normal breast, normal pubic and axillary hair. The external genitalia were also normal. Her family history was also unremarkable, without apparent consanguinity. At transabdominal ultrasonography multiple leiomyoma (the largest having a diameter of 5 cm) and irregular thickening of the endometrium were suspected. The karyotype analysis on peripheral blood lymphocytes confirmed the mosaic Turner's syndrome; (45,0X/46,X,i (X)q10). Her laboratory examination showed elevated gonadotropin levels (FSH, 48.2 IU/l; LH, 20.7 IU/l), decreased 17betaestradiol levels (<20 pg/ml), consistent with postmenopause and normal plasma androgens and cortisol lev-

els. Because of bleeding and persistent pelvic pain we decided to perform exploratory laparotomy. At laparotomy, the uterus was increased to that of 12 cm in lenght with multipl myoma, streak ovaries and a 2 cm diameter solid mass just beneath the left salpinx were observed. The suspicious mass was consulted to general surgeons, they decided to perform frozen section examination, the result was unforeseen, an ectopic adrenal tissue. Total abdominal hysterectomy and bilateral salpingectomy were performed. Histopathological examination confirmed that the uterus was increased in size with multiple leiomyoma (the largest: 5 cm; the smallest: 0.5 cm); secretory endometrium and ectopically localized adrenal tissue just beneath the left salpinx. Microscopic view of the ectopic adrenal tissue is given in Figure 1 and 2.

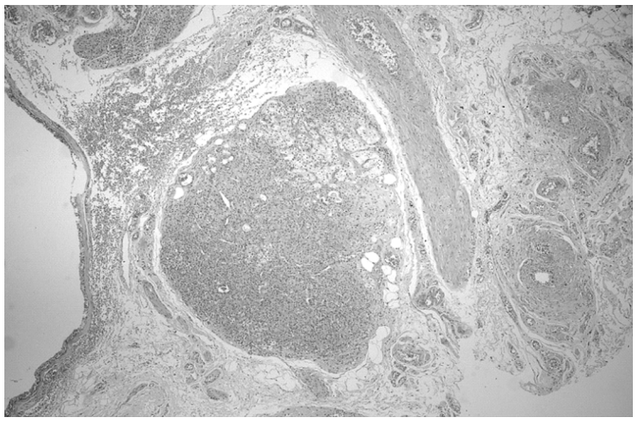

Figure 1: Ectopic adrenal tissue in paratubal area next large vessels, microscopic view [x40, H&E].

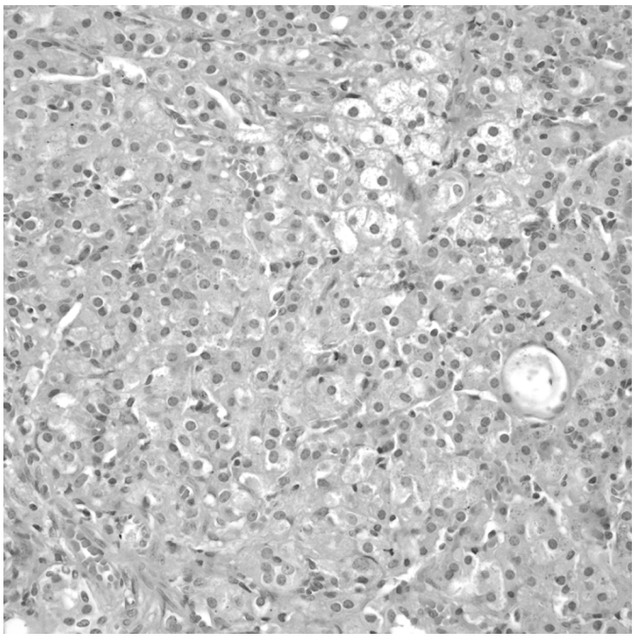

Figure 2: Poligonal cells with large clear cytoplasm resemble zona fasciculata and with large acidophilic granulary cytoplasm resemble zona reticularis of adrenal gland [x40, H&E].

Since its known that both myoma uteri and secretory changes in endometrium develop primarily in woman of reproductive age and their growth is estrogen dependent, the source of estrogen in the present case was thought to be the ectopic adrenal tissue. Postoperatively, the patient did well and on fifth postoperative day discharged home.

Discussion

Uterine leiomyomas are benign monoclonal tumors arising from the smooth muscle cells of the myometrium.[1-3] Myomas are clinically apparent in approximately 12-25% of reproductive age women and noted on pathological examination in approximately 80% of surgically excised uteri.[2,4,5]

The endometrial lining undergoes cyclic regeneration under the influence of estrogen and progesteron; the proliferation of the endometrium is followed by secretory changes. If there is inadequate stimulation of the lining, due to lack of hormones, the endometrium remains thin and inactive. On the other hand; the endometrium that is chronically exposed to estrogen and progesterone, may become thick and irregular. Not only the epidemiology of leiomyomas but also secretory changes in the endometrium are parallel to the ontogeny and life cycle changes of the reproductive hormones estrogen and progesterone.[2] Findings of myoma and secretory changes in endometrium are considered to be unexpected in a patient with Turner's syndrome who is not on a hormone replacement therapy. Since the case we described here had a hormone profile consistent with postmenopause (FSH, 48.2 IU/l; LH, 20.7 IU/l; 17betaestradiol <20 pg/ml), the endogenous source of steroid hormones thought to be the ectopically located adrenal tissue. A review of the literature revealed that none has reported the presence of characteristacally benign gynecological pathologies in a patient with mosaic Turner's syndrome due to the hormone secretion from ectopic adrenal tissue.

In conclusion, our aim in this report is to alert the clinicians about a rare and possibly unique case of an estrogen dependent condition that may develop in women with mosaic Turner's syndrome due endogenous hormone secretion other than ovaries.

Mozaik Turner's Sendromu Olan Bir Hastada Pelvik Ektopik Adrenal Dokunun Neden Olduğu Bening Jinekolojik Patolojiler: Olgu Sunumu

Tıp literatüründe, Turner's sendromu olan hastalarda benign jinekolojik patolojilerin varlığı tanımlanmıştır. Burada, 39 yaşında mozaik Turner's sendrom'lu (45,0X/46,X,i(X)q10), kanama ve pelvik ağrı şikayetleri olan bir olgu tartışıldı. Yapılan fizik muayenede, hastada normal sekonder seks gelişimi, normal meme, pubik ve aksiller kıllanma mevcuttu. Dış genital organ-

lar da normaldi. Laboratuvar testlerinde gonadotropin düzeylerinde yükselme, 17 betaöstradiol düzeylerinde azalma ile normal plazma androjen ve kortizol düzeyleri görüldü. Yapılan transabdominal ultrasonografide multipl miyomlar ve endometriyumda düzensiz kalınlaşmadan şüphelenildi. Total abdominal histerektomi ve bilateral salpenjektomi gerçekleştirildi. Histopatolojik incelemede multipl leiomyomlar, sekretuar endometrium ve ektopik yerleşimli adrenal doku tespit edildi. Miyom ve endometriumda sekretuar değişiklikler primer olarak üreme çağındaki kadınlarda geliştiği ve bunların gelişiminin östrojene bağımlı olduğu bilindiği için, tartışılan olguda östrojen kaynağının sol salpenksin hemen altında yer alan ektopik adrenal doku olduğu düşünüldü. Bu, hormon replasman tedavisi almayan mozaik Turner's sendromu olan bir hastada ektopik adrenal dokuya bağlı benign jinekolojik patolojilerin meydana geldiği ilk olgu olarak görülmektedir.

Anahtar Kelimeler: Mozaik turner's sendromu, Miyom, Sekretuvar endometriyum, Ektopik adrenal doku

References

1. Day Baird D, Dunson DB, Hill MC, et al. High cumulative incidence of uterine leiomyoma in black and white women: ultrasound evidence. Am J Obstet Gynecol 2003; 188:100.
2. Buttram VC Jr, Reiter RC. Uterine leiomyomata: etiology, symptomatology, and management. Fertil Steril 1981; 36:433.
3. Serden SP, Brooks PG. Treatment of abnormal uterine bleeding with the gynecologic resectoscope. J Reprod Med 1991;36:697.
4. Cramer SF, Patel A. The frequency of uterine leiomyomas. Am J Clin Pathol 1990;94:435.
5. Downes E, Sikirica V, Gilabert-Estelles J, et al. The burden of uterine fibroids in five European countries. Eur J Obstet Gynecol Reprod Biol 2010;152:96.