Kafkas Univ Vet Fak Derg
24 (2): 311-314, 2018
DOI: 10.9775/kvfd.2017.18745

Kafkas Universitesi Veteriner Fakultesi Dergisi
Journal Home-Page: http://vetdergi.kafkas.edu.tr
Online Submission: http://submit.vetdergikafkas.org

Case Report

Pathomorphological and Immunohistochemical Findings of Subacute Lobullary Calcifying Panniculitis in Two Cats [1]

Mehmet Eray ALCIGIR [1,a] Tuncer KUTLU [2] Gunay ALCIGIR [1]

[1] *Presented as a poster in the 4th International Conferences and Exhibition on Pathology, July 13-15, 2015 New Orleans, USA*
[1] Ankara University, Faculty of Veterinary Medicine, Department of Pathology, TR-06110 Diskapi, Ankara - TURKEY
[2] Mustafa Kemal Univ., Faculty of Veterinary Medicine, Department of Pathology, TR-31060 Alahan, Antakya/Hatay - TURKEY

Article Code: KVFD-2017-18745 Received: 18.09.2017 Accepted: 15.01.2018 Published Online: 15.01.2018

How to Cite This Article

Alcigir ME, Kutlu T, Alcigir G: Pathomorphological and immunohistochemical findings of subacute lobullary calcifying panniculitis in two cats. *Kafkas Univ Vet Fak Derg,* 24 (2): 311-314, 2018. DOI: 10.9775/kvfd.2017.18745

Abstract

This report aimed to reveal the characteristics of calcifying panniculitis in two cats. Two biopsies taken from the lumbosacral region of an 8-month old and a 1-year old, male, mixed breed cats were evaluated. Macroscopically, there were masses of different sizes varying from 1.5 to 2.5 cm in diameter. The masses had a generally firmness and were grayish-white in colour. Histopathology revealed necrotic and degenerative lipocytes in lobules of subcutaenous fat tissue. In some areas, there were lymphocyte, macrophage and neutrophil leukocytes infiltrations and connective tissue proliferation. There were also large calcifying areas at the centre of degenerated-necrotic fat lobules. Alizarin Red S detected the calcifying areas and Masson's trichrome differentiated connective tissue proliferation. In ABC-P, CD3 slightly reacted with lymphocytes and lymphoblasts. Vimentin moderately reacted with connective tissue proliferation at the periphery of the necrotic areas and the septum. A1AC reacted in the cytoplasm of macrophages and peripheral necrotic areas. No reaction was determined with A1AT. In conclusion, such cases have not been documented in veterinary pathology. It is believed that the two cats possibly had a renal deficiency problem or nephrotic syndrome in the pathogenetic mechanism. It was also considered that A1AC (serine proteinase inhibitor) expressions could have a role in such cases despite there being no A1AT (another serine proteinase inhibitor) expression.

Keywords: *Calcifying panniculitis, Cat, Immunohistochemistry, Pathomorphology*

İki Kedide Karşılaşılan Subakut Lobüller Kalsifiye Panniküllitisin Patomorfolojik ve İmmunohistokimyasal Bulguları

Öz

Sunulan bu iki olguda kedilerdeki kalsifiye panniküllitisin karakteristik özelliklerinin açığa çıkarılması amaçlandı. Sekiz aylık ve bir yaştaki iki erkek, tekir kedide lumbosakral bölgeden alınan biyopsiler değerlendirildi. Makroskopik olarak çapları 1.5-2.5 arasında değişen, sert kıvamda beyazımsı kitleler mevcuttu. Histopatolojik incelemede deri altı yağ dokusundaki lobüllerde dejeneratif ve nekrotik lipositler gözlendi. Bazı alanlarda lenfosit, makrofaj ve nötrofil lökosit infiltrasyonları ile bağ doku proliferasyonu vardı. Ayrıca dejenere-nekrotik yağ lobüllerinin merkezinde geniş kalsifiye alanlar da gözlendi. Alizarin Red S boyaması ile kalsifiye alanların, Masson'un trikrom boyamasıylada bağ doku proliferasyonunun ayrımını yapıldı. ABC-P yönteminde, CD3 lenfosit ve lenfoblastlarla hafif reaksiyonlar verdi. Vimentin nekrotik alanlarda ve septumda yer alan bağ doku proliferasyonlarıyla orta şiddette reaksiyon verdi. A1AC makrofajların sitoplazmasında ve perifer nekrotik alanlarda reaksiyon verdi. Sonuç olarak bu türden vakalar veteriner patolojide bildirilmemiştir. Her iki kedide de gelişen lezyonların patogenetik mekanizmasında böbrek yetmezliği ya da böbrek kökenli bir sendrom olabileceği düşünülmektedir. Ayrıca, serin proteinaz inhibitörü olan A1AT ekspresyonu olmamasına karşın başka bir serin proteinaz inhibitörü olan A1AC ekspresyonlarının bu tür olgularda rolü olduğuna inanılmaktadır.

Anahtar sözcükler: *İmmunohistokimya, Kalsifiye panniküllitis, Kedi, Patomorfoloji*

INTRODUCTION

A panniculitis is a group of heterogeneous disease whose hallmark is inflammation of subcutaneous adipose tissue or panniculus adiposus [1]. The inflammation frequently affects the deep dermis. In the etiology, there are generally infectious agents, foreign bodies, vitamin E deficiency, trauma, pancreatic disease, vasculitis, drug eruption and

İletişim (Correspondence)
+90 326 245 5313
tuncerkutlu83@gmail.com

lupus erythematosus in human beings. The disease may sometimes develop after steroid application, exposure to cold air or ice and α1-antichymotrypsin (A1AC), α1-antitrypsin (A1AT) deficiency, especially in humans. It has also been documented that the etiology of Weber Christian disease in humans remains unknown. The clinical classification of panniculitis has always been a problem in human dermatology, so classification has been performed on the basis of histological appearance. In medicine, these inflammatory changes of subcutaneous fat tissue can be classified in several types, although lobular (fat lobules), septal (interlobular septa including connective tissue) and diffuse (both fat lobules and septa) forms of panniculitis are found according to distribution in veterinary medicine [2]. The classification can be diversified into many types related to the etiology. Four main types have been defined as: 1) lobular panniculitis without vasculitis, 2) lobular panniculitis with vasculitis 3) septal panniculitis without vasculitis, 4) septal panniculitis with vasculitis [3]. Although calcifying panniculitis has been known since the 1980s, it is seen in the classification as a special topic [4-10]. That type of panniculitis has been generally reported in humans with renal failure and has primarily involved anticoagulant-like heparin injection sites [4,9]. The place of calcifying panniculitis has not been conclusive despite being known as a sub-class of lobular panniculitis without vasculitis [11]. It is a peculiar form of calcinosis cutis which belongs to the spectrum of calciphylaxis [4]. The most possible reason is the disturbance of the calcium-phosphate balance [12]. Macroscopically, lesions are seen as symmetrical violaceous to black patches or plaques. They frequently develop on the legs, and sometimes on the upper extremities and trunk. The lesions can be enlarged with necrotic and black eschar tissues. Over time, ulcers may open from those areas of subcutaneous necrosis. Microscopically, there is mucinous degeneration of fat tissue, lymphocytic vasculitis and adventitia and medial calcium deposits within adipose lobules of the interstitial connective region [4,7,10,11]. The aim of this report was to determine the different characteristics of calcifying panniculitis in two cats.

CASE HISTORY

Two brother cats, aged 8 months and 12 months old were brought to a private veterinary clinic with complaints of inappetence, depression and occasional jaundice. In clinical examination, there was seen to be cachexia and tenderness to abdominal palpation. The left lumbosacral region of the dorsal trunk in both cats was seen to be painful and partly ulcerated with eschar masses. Blood samples were collected from the cats and sent to a private veterinary laboratory for examination of blood parameters. It was then decided to remove the masses surgically and they were sent for diagnosis to the Pathology Department of the Veterinary Medicine Faculty of Ankara University. After macroscopic examination, tissue samples were taken from the lesions for histopathology examination. The samples were fixed in 10% formalin, processed routinely and embedded in paraffin. Sections were cut from the paraffin blocks of 5 µm thickness and stained with haematoxylin-eosin (H&E), Alizarin Red S and Masson's trichrome methods. After the histochemical staining, the indirect immunoperoxidase method (ABC-P) was applied using CD3, CD4, vimentin, alpha-1 antitrypsin and alpha-1 antichymotrypsin antibodies. The tissue sections were deparaffinized with xylene and rehydrated in decreasing dilutions of alcohol. Then, the sections were washed with phosphate buffered saline (PBS; pH 7.4). Endogenous peroxidase activity was blocked with 0.3% H_2O_2 for 20 min. The sections were processed with 0.1% trypsin at 37°C for 30 min. After the PBS washes, sections were incubated with protein blocking sera (Peroxidase Detection System, Novocastra, RE7110-K, Leica Biosystems). The sections were treated with primary antibodies (polyclonal rabbit alpha-1 antitrypsin-1/100, Abcam, monoclonal mouse anti-vimentin, clone V9, 1/100, Dako, polyclonal rabbit anti alpha-1 antichymotrypsin- 1/50, Abcam, polyclonal rabbit anti CD3 1/50, antibodiesonline, monoclonal mouse anti CD4, 1/100, Dako) in a humidified chamber for 1 h at room temperature.. Then, biotinylated secondary antibody and streptavidin peroxidase complex (Peroxidase Detection System, RE7110-K, Novocastra, Leica Biosystems) were consecutively applied for 30 min each, and the section was washed 3 times with PBS between the applications. Control samples were treated with PBS instead of primary antibodies. As the chromogen, 3-amino- 9-ethylcarbazole (AEC) (Santa Cruz Biotechnology Inc.) was selected. Counterstaining was performed with Gill's haematoxylin. Sections were mounted with glycergel and examined under a light microscope (Leica).

Macroscopically, the mass had focal features of elastic consistency and was grayish-yellow in colour in the 8-month old cat. The mass weighed 1.5 g and measured 1.5x1.3x0.5 cm. In the elder cat, there were three masses of the same appearance as the first one. The masses weighed a total of 7 g and measured 2.5x1.5x1.3 cm, 1.5x2x1.2 cm, and 1.5x1x0.7 cm.

Microscopic examination revealed necrotic and degenerated fat cells in lobules of subcutaneous fat tissue *(Fig. 1A-B)*. In some areas, lymphocyte, macrophage and neutrophile leukocyte infiltrations and connective tissue proliferation were observed. There were also large calcifying areas at the centre of the degenerated-necrotic fat lobules. Calcifying areas were detected with Alizarin Red S stain and connective tissue proliferation was detected with Masson's trichrome stain *(Fig. 1C)*.

Immunohistochemical staining for CD3 slightly reacted with lymphocytes and lymphoblasts *(Fig. 1D)*. Vimentin moderately reacted with connective tissue proliferation at the periphery of necrotic areas and the septum *(Fig. 1E)*. A1AC reacted in the cytoplasm of macrophages and

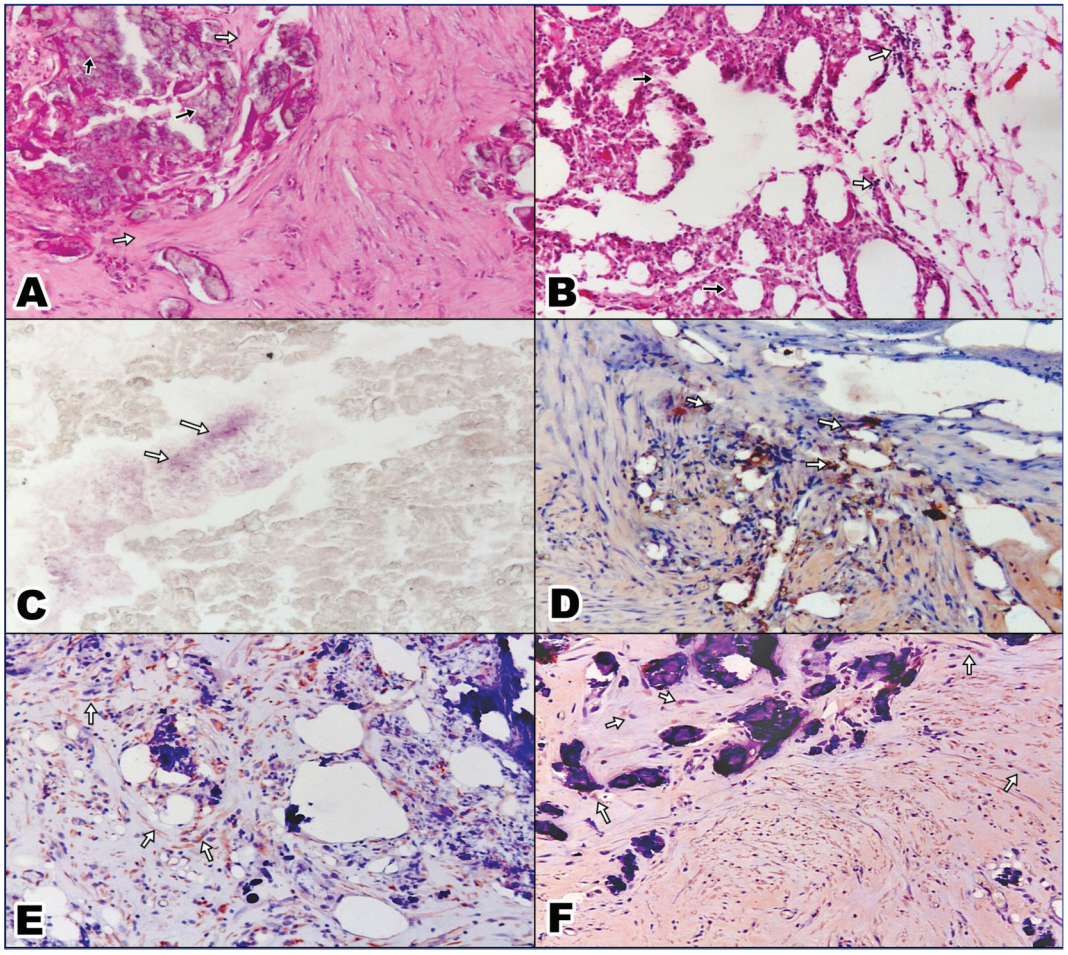

Fig 1. A- Degenerated and necrotic fat *(black arrow)* and collagen *(white arrows)* tissue, x100, H&E; **B-** Degenerated fat cells *(black arrows)* and inflammatory cell infiltration *(arrows)*, x100, H&E; **C-** Calcium deposits in fat tissue *(arrows)*, x100, Alizarin Red S Stain; **D-** CD3 positive T lymphocytes *(arrows)*, x100, ABC-P; **E-** Vimentin-positive fibrocytes *(arrows)*, x100, ABC-P; **F-** A1AC positivity in macrophages *(arrows)*, x100, ABC-P

peripheral necrotic areas *(Fig. 1F)*. CD4 and A1AT were negative.

DISCUSSION

In these two cases, the clinical examination together with the results from the blood parameters suggested an inflammatory skin disease which may have been acute or sublinical in a disease connected to one of the internal organs. The anamnesis was useful for the clinician as vaccinations and parasite therapy had been administered to both cats 2.5 months and 1 month ago, respectively. However, the blood parameters demonstrated different results with low RBC, haemoglobin and high creatinine, calcium, phosphorus and WBC. From these results it was considered that a renal problem and anaemia may be related to eritropoetin dys-synthesis m. Patho-morphologically, lobular evaded necrotic adipocytes with severe inflammation in H&E staining and calcium deposits in Alizarin Red S staining and fibrocytic and fibroblastic proliferation in Masson's trichrome staining revealed calcification in all the masses. Calcifying panniculitis has been reported in literature together with fatigue and a severe condition when considering calciphylaxis and nephrotic syndrome or renal failure in human counterparts [5,7,8,10]. However, despite the lack of appetite and mild cachexia, both cats appeared healthy and not in a serious condition. Histopathologically however, calcium deposits have not been reported to be dense on small or large vessels except on the interstitium although there have been a few reports [4,5]. Unlike other reports in literature and in humans, connective tissue proliferation was noticeable in this study and there was seen to be a tendency to granulomatous inflammation in one of the masses. Immunohistochemically, CD3 confirmed T-lymphocytes even though CD4 was negative for B-lymphocytes. Vimentin showed fibrocytic and fibroblastic proliferation developing at the periphery of necrotic areas. On the other hand, AAT was negative. ACT reacted in macrophages on the periphery of necrotic areas and between adipocytes and also in collagen bundles. In a few reports in recent years, emphasis has been placed on the relationship between alpha-1 antitrypsin (AAT) and alpha-1 antichymotrypsin (ACT) and panniculitis [13,14].

ACT and AAT are members of the serine protease inhibitor (serpin) superfamily of proteins [15,16]. AAT plays a critical role by blocking the proinflammatory effect of neutrophil leukocytes [15]. ACT also inhibits chymotrypsin-like serine proteases, with neutrophil cathepsin G thought to be the main target. It can also inhibit mast cell chymases and angiotensin-converting enzyme proteases which have a role in active vasoconstriction. Rajpara et al.[13] reported that there is a relationship between overactivity of membrane bound serine proteases and neutrophil elastases in subcutaneous fat tissue. However, no immunohistochemical study was applied in terms of localization of positivities. In the current cases, AAT was applied and found to be negative, suggesting that there was no relationship between them, although it was considered that ACT might have a role in the pathogenesis of panniculitis. The ACT positivities from the cases can be considered to support that there is a connection between patients with renal failure and calciphylaxis.

In conclusion, this report is the first in respect of panniculitis classification in veterinary medicine in Turkey. It can be considered of guidance for researchers studying the role of serine protease inhibitors for other types of panniculitis cases in kidney-related disorders.

REFERENCES

1. Anonymous: "panniculitis" at Dorland's Medical Dictionary. http://web.archive.org/web/20090521170644/http://www.mercksource.com/pp/us/cns/cns_hl_dorlands_split.jsp?pg=/ppdocs/us/common/dorlands/dorland/six/000077803.htm; *Acessed:* 20.03.2015.

2. Ginn PE, Mansell JEKL, Rakich PM: The skin and appendages. **In,** Maxie MG (Ed): Pathology of Domestic Animals. 5th edn., 745-746. Elsevier, Philadelphia, PA, 2007.

3. DermNet NZ: Panniculitis Online access: http://dermnetnz.org/dermal-infiltrative/panniculitis.html, *Accessed:* 20. 03.2015.

4. Buchet S, Blanc D, Humbert P, Derancourt C, Arbey-Gindre F, Atallah L, Agache P: Calcifying panniculitis. *Ann Dermatol Venereol,* 119 (9): 659-666, 1992.

5. Campanelli A, Kaya G, Masouyé I, Borradori L: Calcifying panniculitis following subcutaneous injections of nadroparin-calcium in a patient with osteomalacia. *Br J Dermatol,* 153 (3): 657-660, 2005. DOI: 10.1111/j.1365-2133.2005.06748.x

6. Elamin EM, McDonald AB: Calcifying panniculitis with renal failure: A new management approach. *Dermatology,* 192 (2): 156-159, 1996. DOI: 10.1159/000246347

7. Laurent R, Thiery F, Saint-Hillier Y, Blanc D, Agache P: Calcifying panniculitis associated with renal insufficiency: A tissue calciphylaxis syndrome. *Ann Dermatol Venereol,* 114 (9): 1073-1081, 1987.

8. Lugo-Somolinos A, Sánchez JL, Méndez-Coll J, Joglar F: Calcifying panniculitis associated with polycystic kidney disease and chronic renal failure. *J Am Acad Dermatol,* 22 (5 Pt 1): 743-747, 1990. DOI: 10.1016/0190-9622(90)70101-M

9. Koch Nogueira PC, Giuliani C, Rey N, Saïd MH, Cochat P: Calcifying panniculitis in a child after renal transplantation. *Nephrol Dial Transplant,* 12 (1): 216-218, 1997.

10. Richens G, Piepkorn MW, Krueger GG: Calcifying panniculitis associated with renal failure: A case of Selye's calciphylaxis in man. *J Am Acad Dermatol*, 6 (4): 537-539, 1982. DOI: 10.1016/S0190-9622(82)70046-5

11. Poelman SM, Sasseville D: A Practical Approach to Panniculitis. Dearmatology Rounds. Division of Dermatology, Mc Gill University Health Center, Quebec, Canada, 6 (5); 1-6, 2007.

12. Walsh JS, Fairley JA: Calcifying disorders of the skin. *J Am Acad Dermatol,* 33, 693-706, 1995. DOI: 10.1016/0190-9622(95)91803-5

13. Rajpara A, Erickson C, Driscoll M: Review of alpha-1-antitrypsin deficiency associated panniculitis. *Open Dermatol J,* 4, 97-100, 2010.

14. Bleumink E, Klokke HA: Protease-inhibitor deficiencies in a patient with Weber-Christian panniculitis. *Arch Dermatol,* 120 (7): 936-940, 1984. DOI: 10.1001/archderm.1984.01650430122023

15. Stoller JK, Aboussouan LS: Alpha-1 antitrypsin deficiency. *Lancet*, 365, 2225-2236, 2005. DOI: 10.1016/S0140-6736(05)66781-5

16. Travis J, Salvesen GS: Human plasma proteinase inhibitors. *Am Rev Biochem,* 52, 655-709, 1983. DOI: 10.1146/annurev.bi.52.070183.003255