Isolated Superior Gluteal Nerve Mononeuropathy in Patient with Rheumatoid Arthritis

Romatoid Artritli Bir Hastada İzole Superior Gluteal Sinir Mononöropatisi

İbrahim Halil Ural[1], Hasan Kerem Alptekin[2], Leyla Ataş Balcı[2]

[1]Department of Physical Medicine and Rehabilitation, Bahçeşehir University Medical Faculty, İstanbul, Turkey
[2]Department of Physiotherapy and Rehabilitation, Bahçeşehir Health Sciences Faculty, İstanbul, Turkey

Cite this article as: Ural İH, Alptekin HK, Ataş Balcı L. Isolated Superıor Gluteal Nerve Mononeuropathy in Patient with Rheumatoıid Arthritis. JAREM 2017; 7: 152-7.

ABSTRACT

Isolated mononeuritis multiplex may be rarely seen in patients with rheumatoid arthritis. Superior gluteal nerve palsies may result especially from iatrogenic causes, such as total hip arthroplasty operations. Patients complain of burning pain spreading to the lateral side of the thigh region. As our patient had bilateral hip dysplasia and rheumatoid arthritis at the same time, thorough examination was conducted with abdominal magnetic resonance imaging (MRI)'s, multiple electroneuromyography (ENMG) and laboratory studies. Malign illnesses such as aneurysms and tumoral lesions were eliminated. As the patient was diagnosed as mononeuritis multiplex due to Rheumatoid Arthritis, she began to use gabapentin 800 mg three times a day and alpha-lipoic acid 600 mg once a day for 6 months. In addition, she had a physical therapy cure with conventional Transcutaneous Electrical Nerve Stimulation (TENS), continuous Ultrasound (US), hot pack, strengthening and relaxation exercises for the lumbosacral region lasting for three weeks. Most of her complaints subsided after the treatment. Isolated superior gluteal nerve mononeuropathy due to rheumatoid arthritis is a rare presentation and should be thoroughly evaluated and followed for appropriate cures.

Keywords: Superior gluteal nerve, rheumatoid arthritis, mononeuritis multiplex

ÖZ

Romatoid artritli hastalarda izole mononöritis multipleks nadir izlenir. Superior gluteal sinir palsileri total kalça protezi gibi operasyonlar sonrası iatrojenik gerçekleşir. Hastalar lateral uyluk ağrısından şikayet ederler. Hastamızın aynı anda hem bilateral kalça displazisi hem de romatoid artrit hastalığı olması nedeniyle abdominal manyetik rezonans (MR) ve çoklu elektronöromyografi (ENMG) ve laboratuvar çalışmaları yapıldı. Anevrizm ve tümöral lezyonlar gibi malign durumlar öncelikle elendi. Hastanın tanısı romatoid artrite bağlı mononöritis multipleks olarak teşhis edildikten sonra günde 3 kez 800 mg gabapentin ve günde bir kez alfa-lipoik asit 600 mg 6 ay boyunca tedavide kullanıldı. Ek olarak lumbosakral bölge için fizik tedavide konvansiyonel TENS, sıcak paket, kontinue ultrason, güçlendirme ve gevşeme egzersizleri tercih edildi. Şikayetlerinin büyük kısmı tedavi sonrası geriledi. Romatoid artrite bağlı izole superior gluteal sinir mononöropatisi nadir görülen bir durumdur ve de detaylı değerlendirilip uygun şekilde tedavi edilmelidir.

Anahtar kelimeler: Superior gluteal sinir, romatoid artrit, mononöritis multiplex

INTRODUCTION

The superior gluteal nerve originates from the dorsal branch of the L4-S1 roots of the lumbosacral plexus and leaves the pelvis posteriorly after passing through the foramen suprapriformis over the piriformis muscle and proceeds between gluteus medius and gluteus minimus muscle. It goes through in a sheath with the superior gluteal artery and superior gluteal vein along the nerve tract. It innervates gluteus medius, gluteus minimus and tensor fasciae latae muscles. The Inferior gluteal nerve originates from the dorsal branches of L4-S2 innervates gluteus maximus muscles (1, 2). The superior gluteal nerve and inferior gluteal nerves are rarely damaged in isolation except when there are iatrogenic causes. Total hip arthroplasty is reported as a frequent cause of superior gluteal nerve neuropathy, whereas trauma, iliac artery aneurysm, intraabdominal and intrapelvic masses, endometriosis, schwannoma, sports injuries, priformis muscle hypertrophy, or extracorporeal shock wave lithotripsy are seldom reasons (1, 3, 4-9). Patients with superior gluteal nerve injuries complain about burning, stinging and pain spreading to the hips, the lateral side of thighs and groin.

Rheumatoid arthritis (RA) is a chronic inflammatory disease that affects small joints and can lead to damage of various systems in later stages. It is also known that the modalities used in treatment may result in systemic complications. Peripheral nervous system injuries may accompany patients with rheumatoid arthritis. It is stated that these injuries are caused by immune deposits accumulated in vasa nervorum as the disease progresses. Patients with rheumatoid arthritis may have mononeuropathies and polineuropathies as peripheral nervous system involvements (10-12).

We report a case with rheumatoid arthritis and bilateral developmental hip dysplasia treated for a long time, who had developed superior gluteal nerve damage.

Address for Correspondence / Yazışma Adresi: Hasan Kerem Alptekin, E-mail: kalptekin79@hotmail.com

Received Date / Geliş Tarihi: 21.05.2016 **Accepted Date / Kabul Tarihi:** 23.02.2017
© Copyright 2017 by Gaziosmanpaşa Taksim Training and Research Hospital. Available on-line at www.jarem.org
© Telif Hakkı 2017 Gaziosmanpaşa Taksim Eğitim ve Araştırma Hastanesi. Makale metnine www.jarem.org web sayfasından ulaşılabilir.
DOI: 10.5152/jarem.2017.1211

CASE PRESENTATION

A 59-year-old woman complained of pain spreading to her left hip, 1/3 upper lateral side of her thigh and groin for the last 3 months. Pain was sudden, sharp, sustained for a few seconds and automatically declined. Pain was seen during activity or rest and was not relieved by heat or cold. Pain was controlled for a short time by various painkillers that she had taken by herself. Since her twenties she was followed with the diagnosis of rheumatoid arthritis. She was using meloxicam 15 mg once a day and 12.5 mg of methotrexate once weekly as a medical treatment. She refused to get operated for hip arthroplasty although she was diagnosed as having developmental dysplasia of the hip.

After having two rheumatoid arthritis flares 3 months and 9 months before the pain started, her methotrexate dose was increased to 50 mg. Methotrexate was used in a subcutaneous form twice a weekly. When rheumatologist was consulted, they stated that they were using a high dose of methotrexate before switching to Anti -Tumor Necrosis Factor (Anti-TNF). Though her medication was titrated, the last flares were prolonged. Her complaints started 3 months after her last RA episode. She was prediagnosed as meralgia paresthetica according to the results of Electroneuromyography (ENMG) analysis (Figure 1) and was recommended to take asemetacin 60 mg twice a day, thiocolchicoside 4 mg twice a day, and intramuscular diclofenac once a day for 10 days. Because of repeated normal ENMG analysis (Figure 2) results and no improvement despite the treatment for a month, the patient was referred to our outpatient clinic. During this period, she was recommended to reduce her dose of methotrexate to 10 mg once a week according to improved laboratory findings and complaints about bilateral developmental dysplasia, limited range of motion and tenderness around the hip joints recorded at the physical examination. However, the hip pain with physical activity was not consistent with the main problems. The motion of lumbar spine was in the normal range and painless. Bilateral minimal lumbar paravertebral muscle spasm was present. A straight leg raising test was painless. Both hip muscle strength was at the 4/5 level. The strength measurements of the left hip abductor muscle were painful. There was hypoesthesia on the proximal part of left thigh when compared with the right side, but not relevant with any dermatomal field. Lower extremity reflexes were normal. There were no pathological reflexes.

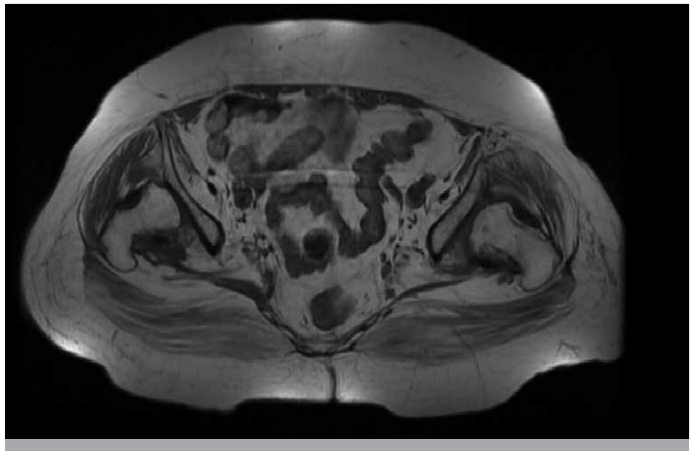

Figure 1. ENMG Results 1st page
ENMG: electroneuromyography

The previous results of Erythrocyte Sedimentation Rate (ESR), (C-Reactive Protein) CRP, blood count, blood chemistry, and urine biochemistry were within normal range. It was determined that there was partial axonal degeneration in the left inferior gluteal nerve and complete axonal degeneration in the left superior gluteal nerve on the repeated ENMG analysis (Figure 3). When neurology specialist was consulted, the inferior gluteal nerve lesions were supposed to have developed after intramuscular injections. In order to reveal the differential diagnosis of nerve involvement, abdominal, lumbosacral region and lumbosacral plexus Magnetic Resonance Imaging (MRI) was obtained. Cancer indicators were also examined to investigate intra-abdominal malignancy. No evidence of malignancy was found. Abdominal MRI was normal. Dysplasia in both hips, left coxarthrosis and minimal displacement of the femur to superior was revealed by the pelvic MRI (Figure 4, 5). There was spondylosis in the lumbosacral region in addition to no plexus pathology at lumbosacral MRI (Figure 6-8).

Written informed consent was obtained from the patient for her medical records to be used in a case report. She started to orally use gabapentin 800 mg three times a day, etodolac 400 mg twice a day, paracetamol 500 mg 4 times a day, and alpha-lipoic acid 600 mg once a day. The maximum gabapentin dosage for neuropathic pain was 3600 mg daily, but daily dosage of 2400 mg was

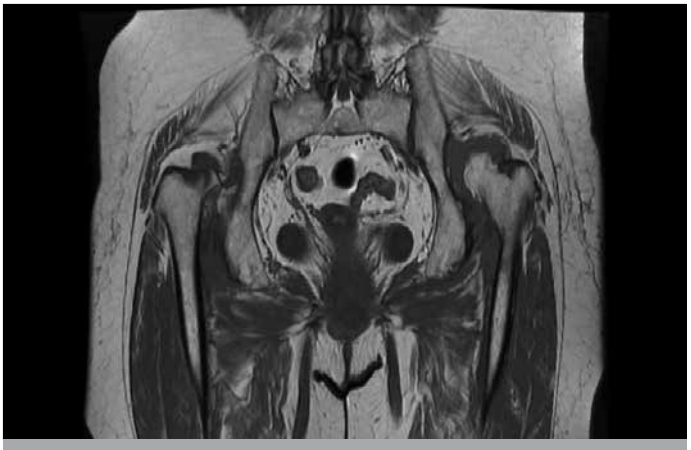

Figure 2. ENMG Results 2nd page
ENMG: electroneuromyography

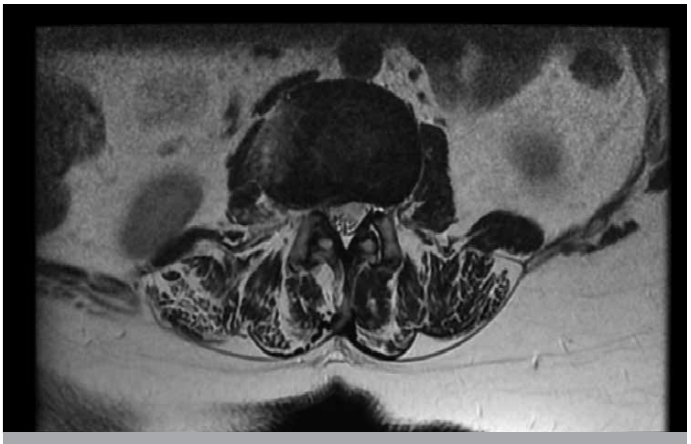

Figure 3. ENMG Results 3rd page
ENMG: electroneuromyography

Figure 4. Axial MRI section of hip
MRI: magnetic resonance imaging

Figure 5. Coronal MRI section of hip
MRI: magnetic resonance imaging

Motor Nerve Conduction Study

Site	Latency (ms)	Amplitude	Area	Segment	Distance (mm)	Interval (ms)	NCV (m/s)	NCV N.D.
Tibial, L								
Ankle	4,85ms	16,29mV	23,03mVms	Ankle		4,85ms		
Popliteal	12,55ms	9,91mV	15,77mVms	Ankle - Popliteal	375mm	7,70ms	**48,7m/s**	
Peroneal, L								
Ankle	3,4ms	5,65mV	12,52mVms	Ankle		3,40ms		
Head of fibula	9,4ms	4,94mV	12,10mVms	Ankle - Head of fibula	295mm	6,00ms	**49,2m/s**	
Popliteal	11,25ms	5,05mV	12,40mVms	Head of fibula - Popliteal	90mm	1,85ms	**48,6m/s**	
Tibial, R								
Ankle	4,35ms	11,36mV	14,73mVms	Ankle		4,35ms		
Popliteal	12,25ms	7,73mV	11,45mVms	Ankle - Popliteal	385mm	7,90ms	**48,7m/s**	
Peroneal, R								
Ankle	3,05ms	8,31mV	18,20mVms	Ankle		3,05ms		
Head of fibula	9,25ms	7,42mV	18,11mVms	Ankle - Head of fibula	300mm	6,20ms	**48,4m/s**	
Popliteal	11,15ms	7,15mV	17,64mVms	Head of fibula - Popliteal	95mm	1,90ms	**50,0m/s**	

F-wave Study

Nerve	Tibial	Side	Left		
Stim. Site	Ankle	Rec. Site	AH	Distance	
M-Latency	3ms	M-Amplitude	15,31mV	F-Occurrence	11/12,92

	Min.	Max.	Mean		
F-Latency	**43.9ms**	48.4ms	46.7ms	F-Lat. N.D.	
F-Amplitude	50.00uV	160.0uV	99.09uV		
FWCV				FWCV N.D.	

F-wave Study

Nerve	Peroneal	Side	Left		
Stim. Site	Ankle	Rec. Site		Distance	
M-Latency	3,6ms	M-Amplitude	5,59mV	F-Occurrence	5/16,31

	Min.	Max.	Mean		
F-Latency	**40.0ms**	44.0ms	42.7ms	F-Lat. N.D.	
F-Amplitude	40.00uV	160.0uV	72.00uV		
FWCV				FWCV N.D.	

F-wave Study

Nerve	Tibial	Side	Right		
Stim. Site	Ankle	Rec. Site	AH	Distance	
M-Latency	3,6ms	M-Amplitude	10,29mV	F-Occurrence	12/12,100

Figure 6. Lumbar L2-L3 axial MRI
MRI: magnetic resonance imaging

enough with a combination of alpha-lipoic acid 600 mg once a day. The use of etodolac and paracetamol was terminated three weeks later, while other medical treatment was continued for 6 months. The physical therapy program included conventional Transcutaneous Electrical Nerve Stimulation (TENS), continuous Ultrasound (US), hot pack, and strengthening and relaxation exercises for lumbosacral, paravertebral and hip muscles. This program was continued for three weeks and then she was recommended to continue the exercises at home. Her complaints reduced by half at the third month and almost entirely at the sixth month. The regeneration findings in the inferior gluteal nerve and the degeneration and regeneration findings in the superior gluteal nerve were evident at the ENMG after six months.

DISCUSSION

Isolated superior gluteal nerve injury that causes pain, burning, stinging and weakness at the lateral side of thighs and groin is seen rarely (13).

Hip arthroplasty or revision arthroplasties are more common than any other reason as the etiological cause of superior gluteal nerve injuries. Surgical procedures are performed by considering a "safe zone" that the distance between the surgical region and superior gluteal nerve tract. The distance from the greater trochanter to the superior gluteal nerve is usually measured. But the safe zone has been described differently by some authors (1, 14). Therefore, interventional procedures except the safe zone may injure the superior gluteal nerve.

Motor Nerve Conduction Study

Site	Latency (ms)	Amplitude	Area	Segment	Distance (mm)	Interval (ms)	NCV (m/s)	NCV N.D.
Tibial, L								
Ankle	4,85ms	16,29mV	23,03mVms	Ankle		4,85ms		
Popliteal	12,55ms	9,91mV	15,77mVms	Ankle - Popliteal	375mm	7,70ms	**48,7m/s**	
Peroneal, L								
Ankle	3,4ms	5,65mV	12,52mVms	Ankle		3,40ms		
Head of fibula	9,4ms	4,94mV	12,10mVms	Ankle - Head of fibula	295mm	6,00ms	**49,2m/s**	
Popliteal	11,25ms	5,05mV	12,40mVms	Head of fibula - Popliteal	90mm	1,85ms	**48,6m/s**	
Tibial, R								
Ankle	4,35ms	11,36mV	14,73mVms	Ankle		4,35ms		
Popliteal	12,25ms	7,73mV	11,45mVms	Ankle - Popliteal	385mm	7,90ms	**48,7m/s**	
Peroneal, R								
Ankle	3,05ms	8,31mV	18,20mVms	Ankle		3,05ms		
Head of fibula	9,25ms	7,42mV	18,11mVms	Ankle - Head of fibula	300mm	6,20ms	**48,4m/s**	
Popliteal	11,15ms	7,15mV	17,64mVms	Head of fibula - Popliteal	95mm	1,90ms	**50,0m/s**	

F-wave Study

Nerve	Tibial	Side	Left		
Stim. Site	Ankle	Rec. Site	AH	Distance	
M-Latency	3ms	M-Amplitude	15,31mV	F-Occurrence	11/12,92

	Min.	Max.	Mean		
F-Latency	**43.9ms**	48.4ms	46.7ms	F-Lat. N.D.	
F-Amplitude	50.00uV	160.0uV	99.09uV		
FWCV				FWCV N.D.	

F-wave Study

Nerve	Peroneal	Side	Left		
Stim. Site	Ankle	Rec. Site		Distance	
M-Latency	3,6ms	M-Amplitude	5,59mV	F-Occurrence	5/16,31

	Min.	Max.	Mean		
F-Latency	**40.0ms**	44.0ms	42.7ms	F-Lat. N.D.	
F-Amplitude	40.00uV	160.0uV	72.00uV		
FWCV				FWCV N.D.	

F-wave Study

Nerve	Tibial	Side	Right		
Stim. Site	Ankle	Rec. Site	AH	Distance	
M-Latency	3,6ms	M-Amplitude	10,29mV	F-Occurrence	12/12,100

Figure 7. Lumbar L4-L5 axial MRI
MRI: magnetic resonance imaging

In our case, superiorly displaced hip dysplasia did not affect nerve tract. The complaints that arose recently could not be explained by hip dysplasia lasting from childhood. Isolated superior gluteal nerve injury may occur due to the compression of the structures in the pelvic and abdominal area.

The problems of superior gluteral arteries that go along in the same sheath with the nerve may also cause superior gluteal nerve injuries (3). No aneurysm was found in the abdomen or pelvis at MRI in our case.

The hypertrophy of piriformis muscle caused by intensive sport activities may also affect the superior gluteal nerve (7). The findings in our case did not support that hypothesis. Rheumatoid arthritis can cause serious disability and destruction of joints and bones. Although extra-articular complications are seen more frequently, central nervous system problems and peripheral nervous system problems such as carpal tunnel syndrome are observed in less than 1% of patients. Peripheral nervous system complications of rheumatoid arthritis may be caused by vasculitis. Mononeuritis multiplex, sensorimotor polyneuropathy and autonomic neuropathy in vasa nervorum are ischemic damage and demyelination that are results of accumulation of immune complex deposits. Patients with rheumatoid arthritis that have frequent and serious flares may develop such complications (11). It has been reported that pain and weakness complaints might be seen as a result of the angulation of nerve fibers in patients with rheumatoid arthritis in some studies. However, this situation usually appears as myopathic problems (11). The accumulation of immune complexes formed between the IgG and Rheumatoid Factor (RF) may result in vasculitis. Those complexes are more frequently observed in cases that have high RF and long-term diseases (10). The drugs used in patients with rheumatoid arthritis may occasionally show neurotoxic effects. Methotrexate can have adverse effects on peripheral nerves. It has been reported that lumbosacral plexopathy characterized by progressive weakness of the peripheral nerves may present as a side effect of methotrexate (15).

In our case the complaints arose after serious inflammatory flares. The formation of immune complex deposits and the possibility of mononeuritis multiplex may increase during the at-

Patient:
Patient ID: 2015/4204
Sex: Female

Date of Birth: 12.02.1957
Age: 58 Years 9 Months

DUYSAL ILETIM INCELEMELERI

Nerve / Sites	Rec. Site	Peak Lat ms	Lat. ms	Distance cm	Velocity m/s	Amp.2-3 µV	Amp.1-2 µV	Ampl. µV
L SURAL - Lat Malleolus								
Cr	Lat Malleol	4,25	3,15	14	44,4	11,7	13,3	13,3
2		4,25	3,40			9,0	13,8	13,8
L SUP PERONEAL - Foot								
Lateral Cr	Bilek	3,35	2,60	12	46,2	10,4	9,7	10,4

MOTOR ILETIM INCELEMELERI

Nerve / Sites	Latency ms	Ampl mV	Distance cm	Velocity m/s	Dur. ms	Area mVms	Amp.2-4 mV
L COMM PERONEAL - EDB							
Bilek	3,70	5,2			6,80	18,6	6,7
Fib Basi	10,25	4,5	32,5	49,6	7,10	17,6	6,0
L TIBIAL (KNEE) - AH							
Bilek	4,55	8,5			5,15	22,1	12,7
Dizardi	12,85	7,6	37	44,6	5,45	20,5	11,7

EMG Summary Table									
	Spontaneous					MUAP			Recruitment
	IA	Fib	PSW	Fasc	H.F.	Amp	Dur.	PPP	Pattern
L. TIB ANTERIOR	N	None	None	None	None	N	N	N	Reduced
L. GASTROCN (MED)	N	None	None	None	None	N	N	N	Reduced
L. VAST LATERALIS	N	None	None	None	None	1+	N	N	Reduced
L. RECT FEMORIS	N	None	None	None	None	1+	N	N	Reduced
L. T FASCIA LATA	N	2+	2+	None	None	2+	2+	N	Reduced
L. GLUTEUS MED	N	2+	2+	None	None	2+	2+	N	Reduced
R. T FASCIA LATA	N	None	None	None	None	1+	N	N	N
R. GLUTEUS MED	N	None	None	None	None	1+	N	N	N
R. GLUTEUS MAX	N	None	None	None	None	N	N	1+	N
L. GLUTEUS MAX	N	1+	None	None	None	1+	N	N	N

Figure 8. Lumbar sagittal MRI
MRI: magnetic resonance imaging

tacks. Despite the rare clinical presentation, our case should be described as "acute sensorimotor mononeuropathy" in superior gluteal nerve.

CONCLUSION

In conclusion, mononeuritis multiplex may rarely be seen in patients with rheumatoid arthritis as any peripheral nerve problems. It has to be considered especially in acute neuropathic symptoms at the lower extremities. In addition, because of mixing the clinical findings of mononeuritis multiplex with radiculopathy or entrapment neuropathies, detailed ENMG examination, which is important for accurate early diagnosis of the problem, must be added to detailed history and clinical examination.

Informed Consent: Written informed consent was obtained from patient who participated in this study.

Peer-review: Externally peer-reviewed.

Author Contributions: Concept - H.K.A.; Design - L.A.B.; Supervision - H.K.A.; Resources - İ.H.U.; Materials - İ.H.U.; Data Collection and/or Processing - L.A.B.; Analysis and/or Interpretation - İ.H.U.; Literature Search - L.A.B.; Writing Manuscript - H.K.A.; Critical Review - H.K.A.

Conflict of Interest: No conflict of interest was declared by the authors.

Financial Disclosure: The authors declared that this study has received no financial support.

Hasta Onamı: Yazılı hasta onamı bu çalışmaya katılan hastadan alınmıştır.

Hakem Değerlendirmesi: Dış bağımsız.

Yazar Katkıları: Fikir - H.K.A.; Tasarım - L.A.B.; Denetleme - H.K.A.; Kaynaklar - İ.H.U.; Malzemeler - İ.H.U.; Veri Toplanması ve/veya İşlemesi - L.A.B.; Analiz ve/veya Yorum - İ.H.U.; Literatür Taraması - L.A.B.; Yazıyı Yazan - H.K.A.; Eleştirel İnceleme - H.K.A.

Çıkar Çatışması: Yazarlar çıkar çatışması bildirmemişlerdir.

Finansal Destek: Yazarlar bu çalışma için finansal destek almadıklarını beyan etmişlerdir.

REFERENCES

1. Lammy S. Anatomical Course Demarcating the Safe Area for the Superior Gluteal Nerve. Mcgill J Med 2009; 12: 23-6.
2. Diop B, Parrate B, Tatu L, Vuillier F, Faure A, Monnier G. Anatomical bases of superior gluteal nerve entrapment syndrome in the suprapiriformis foramen. Surg Radiol Anat 2002; 24: 155-9. [CrossRef]
3. Grisold W, Karnel F, Kumpan W, Hitzenberger P, Zifko U. İliac artery aneurysm causing supperior gluteal nevre lesion. Muscle Nerve 1990; 22: 1717-20. [CrossRef]
4. Abitbol JJ, Gendron D, Laurin CA, Beaulieu MA. Gluteal nerve damage following total hip arthroplasty: A prospective analysis. J Arthroplasty 1990; 5: 319-22. [CrossRef]
5. Reddy S, Porter D, Patton JT, Al-Nafussi A, Beggs I. Endometriosis of the superior gluteal nevre. Skeletal Radiol 2007; 36: 879-83. [CrossRef]
6. Kwon NY, Oh HM, Ko YJ. Multiple Lower Extremity mononeuropathies by segmental schwannomatosis: A Case Report. Ann Rehabil Med 2015; 39: 833-7. [CrossRef]
7. Mondelli M, Martelli G, Greco G, Ferrari F. Mononeuropathies of inferior and superior gluteal nerves due to hypertrophy of piriformis muscle in a basketball player. Muscle Nerve 2008; 38: 1660-2. [CrossRef]
8. Miguel-Perez M, Ortiz-Sagrista JC, Lopez I, Perz-Bellmunt A, Llusa M, Alex L, et al. How to avoid injuries of the superior gluteal nerve. Hip Int 2010; 20: 26-31. [CrossRef]
9. Donfrio PD, Bird SJ, Assimos DG, Mathes DD. Iatrogenic superior gluteal mononeuropathy. Muscle Nerve 1998; 21: 1794-6. [CrossRef]
10. Duquerroy S, Stura EA, Bressanelli S, Fabiane SM, Vaney MC, Beale D, et al. Crystal Structure of a Human Autoimmune Complex between IgM Rheumatoid Factor RF61 and IgG1 Fc Reveals a Novel Epitope and Evidence for Affinity Maturation. J Mol Biol 2007; 368: 1321-31. [CrossRef]
11. Prete M, Racanelli V, Digiglio L, Vacca A, Dammacco F, Perosa F. Extra-articular manifestations of rheumatoid arthritis: An update. Autoimmun Rev 2011; 11: 123-31. [CrossRef]
12. Rosenbaum R. Nuromuscular complications of connective tissue diseases. Muscle Nerve 2001; 24: 154-69. [CrossRef]
13. Craig A. Entrapment neuropathies of the lower extremity. PM R 2013; 5: 31-40. [CrossRef]
14. Martinoli C, Miguel-Perez M, Padua L, Gandolfo N, Zicca A, Tagliafico A. Imaging of neuropathies about the hip. Eur J Radiol 2013; 82: 17-26. [CrossRef]
15. Verstappen CCP, Heimans JJ, Hoekman K, Postma TJ. Neurotoxic complications of chemotherapy in patients with cancer. Drugs 2003; 63: 1549-63. [CrossRef]