Erciyes Med J 2016; 38(3): 99-105 • DOI: 10.5152/etd.2016.150070

ORIGINAL INVESTIGATION

An Attempt to Keep Flaps Alive with Artificial Perfusion in Rabbits

İrfan Özyazgan[1], Onurkan İdacı[1], Olgun Kontaş[2]

ABSTRACT

Objective: In free flap surgery, the condition of recipient vessels may not be appropriate for anastomosis because of anatomical factors or acquired features such as tumoral invasion, surgical treatment, or radiotherapy. Furthermore, free flap surgery is time-consuming, expensive, demanding, and more prone to complications. The aim of this study was to test the hypothesis that maintaining free flap perfusion with a temporary artificial system without microanastomosis until revascularization is adequate for flap vitality.

Materials and Methods: We studied a total of 14 rabbits, which were placed into two groups: control and experimental. A 5×5 cm free skin island flap was elevated on the caudolateral scapular region. In the experimental group, the artery and vein of the flaps were cannulated and a 5 cc/h plasma infusion was artificially started prior to flap fixation. In the control group, the flaps were designed and sutured to the recipient area without perfusion.

Results: The animals did not live long enough for us to analyze the maintenance of the clinical flap vitality. However, it was found that flap tissues in the experimental group were vital during the first 6 days after surgery, while composite graft tissues in the control group resulted in necrosis on day 3 in histopathological examination.

Conclusion: Our experimental model proves that the artificial flap perfusion model with plasma perfusion extends the duration of tissue viability compared with that with non-perfusion (control group). This result could be improved with further investigations and may lead to the development of many future innovations.

Keywords: Extra-corporeal circulation, free flap, plasma infusion

This study was presented in 34th National Turkish Plastic, Reconstructive and Aesthetic Surgery Congress, 31 October-4 November 2012, Antalya, Turkey.

[1]Department of Plastic, Reconstructive and Esthetic Surgery, Erciyes University School of Medicine, Kayseri, Turkey

[2]Department of Pathology, Erciyes University School of Medicine, Kayseri, Turkey

Submitted
01.03.2016

Accepted
16.05.2016

Correspondence
Dr. İrfan Özyazgan, Erciyes Üniversitesi Tıp Fakültesi, Plastik, Rekonstrüktif ve Estetik Cerrahi Anabilim Dalı, Kayseri, Türkiye
Phone: +90 532 666 37 67
e.mail: ozyazganirfan@gmail.com

©Copyright 2016 by Erciyes University School of Medicine - Available online at www.erciyesmedj.com

INTRODUCTION

The reconstruction of soft tissue defects is among the main practices in plastic surgery. Traditionally, the reconstructive method used for closing such a defect is selected according to the "reconstructive ladder" principle (1). In this ladder, the reconstructive procedures are arranged from easier to complex, where the primary suture is the first step and free flap surgery is the last step and the most demanding choice according to the requirement of the defect.

In free flap surgery, the condition of the recipient arteries and veins and the blood flow in this localization are of great importance. The recipient vessels planned for anastomosis may have been damaged for reasons such as trauma, surgical operation, tumoral invasion, atherosclerosis, or radiotherapy (2-8).

Anastomosis of the vessels in free flap surgery often requires microsurgery, which is a time-consuming, costly, and onerous process; is vulnerable to complications; and requires special expertise. The unavailability or inappropriateness of recipient vessels necessitates the use of vein grafts, and this prolongs the process. Regardless of how successfully the initial stages of the procedure are completed, there is still a risk of anastomotic thrombosis in the next stage. The purpose of this study was to investigate the possibility of achieving flap survival with a temporary artificial perfusion until the revascularization from the recipient area becomes adequate to maintain flap vitality.

MATERIALS and METHODS

This study was performed with the consent of the local ethics committee (TSU-10-3288, 10/50) in the Hakan Çetinsaya Experimental and Clinical Research Center of Erciyes University. The experimental animals (14 female New Zealand rabbits, 3000–5000 gm) were fed on standard rabbit food and water. According to the statistical power analysis, the experimental and control groups were formed with seven rabbits in each.

Anesthesia for the surgical operations was instituted with an intramuscular 40 mg/kg ketamine (Ketalar®, Pfizer; İstanbul, Turkey) and 5 mg/kg xylazine (Rompun®, Bayer; İstanbul, Turkey) injection. For surgical infection pro-

phylaxis, intramuscular 100 mg/kg ampicillin–sulbactam (Sulcid®, İ. E. Ulagay; İstanbul, Turkey) was injected.

Flap model

In the study, a 5×5 cm island flap, including the panniculus carnosus tissue, supplied by the skin perforators stemming from the thoracodorsal artery and located in the caudolateral region of the scapula was used (9). During the posterior, dorsal, and ventral margin incisions, the readily visible vascular structures under the flap were spared. After the skin incision in the anterior flap margin, the vascular pedicle was traced deeply and toward the subscapular vessels until an adequate length was obtained, and was then ligated and cut. Thus, a cutaneous free flap with an approximately 2 cm long vascular pedicle was obtained (Figure 1).

A full-thickness skin graft of the same size as the flap was obtained from the contralateral symmetrical anatomic location.

Experimental group

The obtained free flap was kept moist and the procedure was carried out under a surgical microscope. The artery and vein of the flap were skeletonized, both supplied with a 24-gauge angiocath and ligated with a 6-0 silk suture. The vascular bed was cleared of possible clots with 5000 IU heparinized saline solution diluted in a ratio of 1:20 and injected via the arterial cannula (Figure 1).

This flap was fixed with staplers contralateral to the full-thickness skin graft donor area and the vascular pedicle was preserved. The angiocaths in the artery and vein were sutured to the skin of the rabbit (Figure 1).

For extra-corporeal infusion of the rabbit skin island flap, plasma was used, as in the study by Maeda et al. (10). Human plasma from the Blood Center of Erciyes University Hospital that was unsuitable for clinical use as its expiry date was about to pass was used and 250 mg ampicillin–sulbactam was added per bag. By means of an infusion pump (Body Guard 323, Caesarea Medical Electronics Ltd; Lichtenstein, Germany), perfusion from an arterial cannula at a rate of 5 cc/h was achieved and the venous return was left to drain freely.

In order to prevent the designed infusion setup from breaking down or being damaged through the movement of the rabbit, a cage large enough to accommodate only one rabbit at a time was made that allowed the rabbit to move forward and backward but not to turn horizontally or vertically.

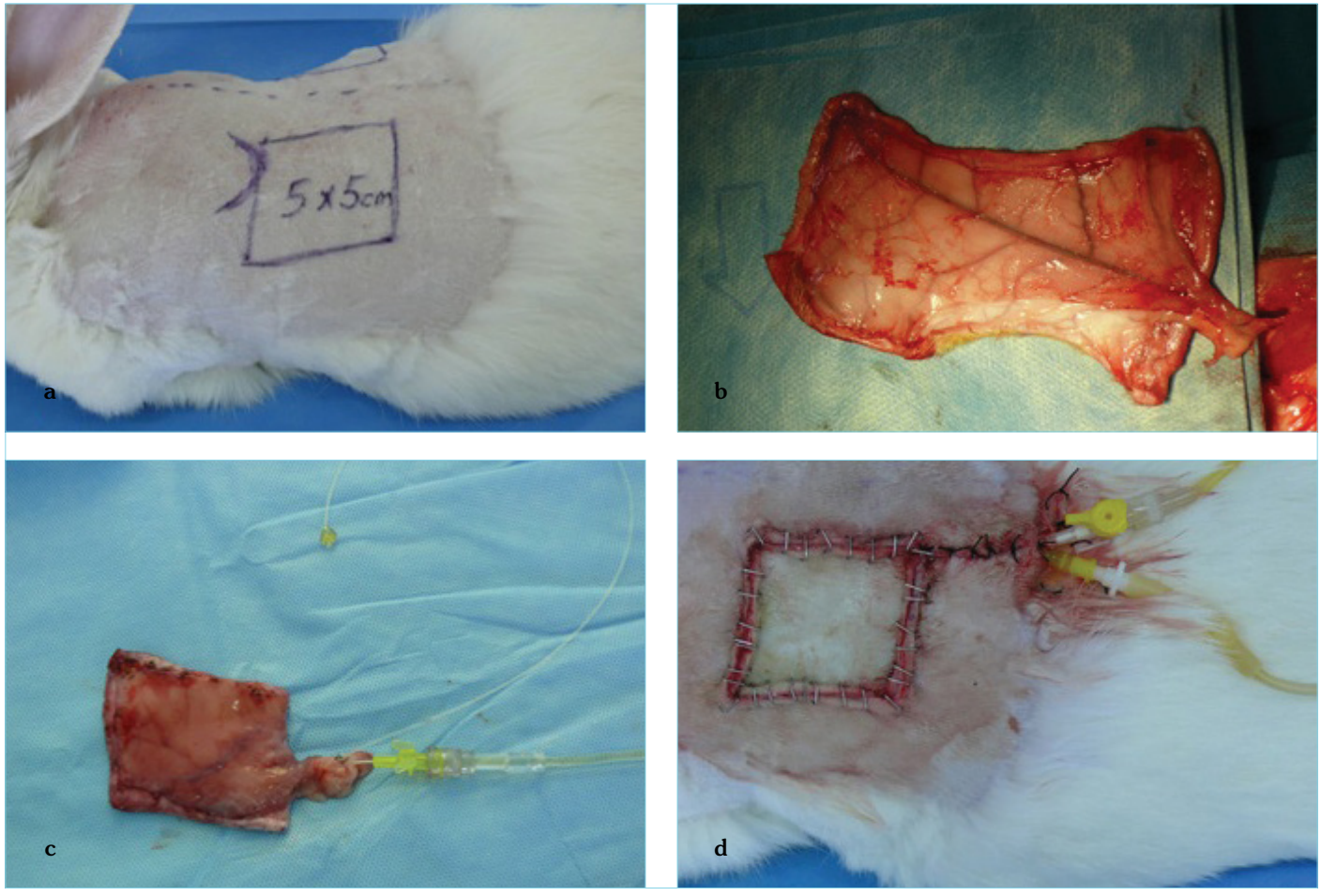

Figure 1. a-d. (a) The plan of the skin island located in the caudal region of the scapula and supplied by skin perforators of the thoracodorsal artery. (b) Lifting of the flap and isolation of vessels. (c) Cannulation of the flap vessels and testing of the circulation. (d) Fixation of the flap to the bed and of cannulas to the skin

Control group

In the control group, the free flap was removed and fixed as a composite graft to the full-thickness skin graft donor area, without the flap vessels being cannulated. The flap donor area, however, was covered with the full-thickness skin graft.

Histopathological study

For comparison of the groups, originally calculation of the vital areas of the flaps and grafts, according to their macroscopic appearances, and statistical assessment of the findings were planned; however, later it was decided to investigate the vitality histopathologically with the samples taken from the tissue, as it was impossible in the late period to make a macroscopic assessment of flap vitality for reasons to be mentioned later. To this end, full-thickness samples of 2 x 0.1 cm were taken from the edges of the flaps of both groups on different days of the study. The samples were prepared and stained with hematoxylin eosin for analysis under a light microscope, and were photographed. The decision was made regarding the viability of the tissues by considering the histopathological findings, such as 1) presence of the epidermis over the dermis, 2) visibility of the individual fibers comprising the dermal collagens, 3) an assumption of a homogenous, eosinophilic and opaque appearance by the dermis, 4) visibility of the cell nuclei, 5) visibility of the cell membrane, 6) the skin appendices' vitality, 7) presence of a typical histological hair follicle epithelial structure.

Findings

The study was started with the animals in the experimental group, which required careful attention since they were more troublesome. It was observed on the first post-operative day in all subjects that although the flow of plasma from the venous cannula was discontinued, it seeped from the edges of the wounds; therefore, perfusion was continued.

The arterial cannula came out in three subjects on the post-operative second and third day owing to the rabbits' unpreventable movement. The first, second, and third rabbit died on the post-operative 7th, 6th, and 8th days, respectively. Another three rabbits died on the post-operative 4th and 6th days while plasma infusion was going on. Upon the unanticipated failure experienced in the first six subjects in the experimental group, the number planned for the group distribution was modified and the number of subjects in the experimental group was increased by transferring three animals from the control group.

Plasma infusion was continued for 6 days in two of the remaining four rabbits and for 7 days in the other two after the enlargement of the experimental group. Upon the observation of clinical impairment of the circulation in the flap, on post-operative day 6, in the first of the rabbits that had received plasma infusion for 6 days, a biopsy was taken. The second of the rabbits, which had infusion for 6 days, was assessed on the 4th, 5th, and 6th days with incision biopsy. The first of the rabbits receiving plasma infusion for 7 days was found dead after a biopsy was taken from the flap on the 7th day. Incision biopsy was taken, on the post-operative 3rd, 5th, and 7th days, while they were still alive, from the other rabbits receiving infusion for 7 days.

The flaps of the four control group subjects were similarly removed and fixed to the recipient areas that had been prepared, and were monitored without plasma infusion. Histopathological samples were also taken from the subjects on the same days as in the experimental group. The subjects were found dead on the post-operative 9th and 10th days.

RESULTS

Clinical observations

It was observed that the flaps in the experimental group had clinically superior turgor and tonus, with a yellowish color, and a temperature closer to that of the surrounding tissues throughout the period they received plasma from the first post-op day onward. However, the turgor, tonus, and temperatures of the tissues monitored as a composite graft in the control group were lower than those of the surrounding tissues and those of the experimental group, with sporadic changes of color from brown to black (Figure 2).

Histopathological study

In the specimens taken from the flaps in the control group on the 3rd day, an increasing burden of infection, disintegration of the

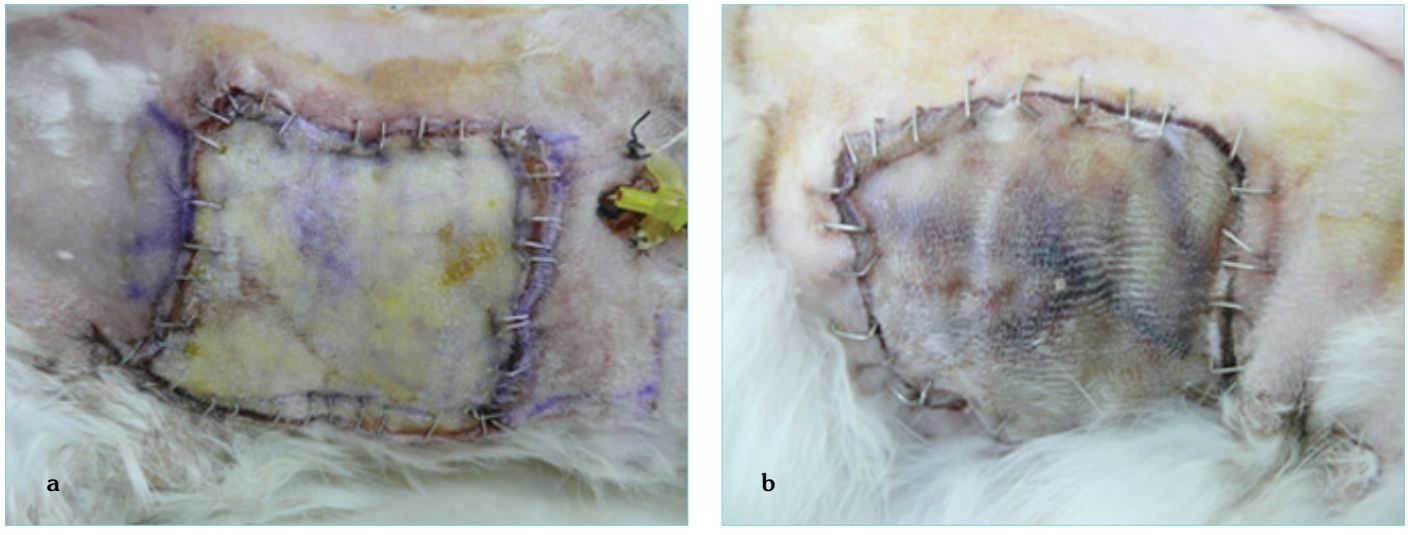

Figure 2. a, b. Appearance of (a) the flap tissue in the experimental group and (b) the composite graft in the control group on the 6th post-operative day

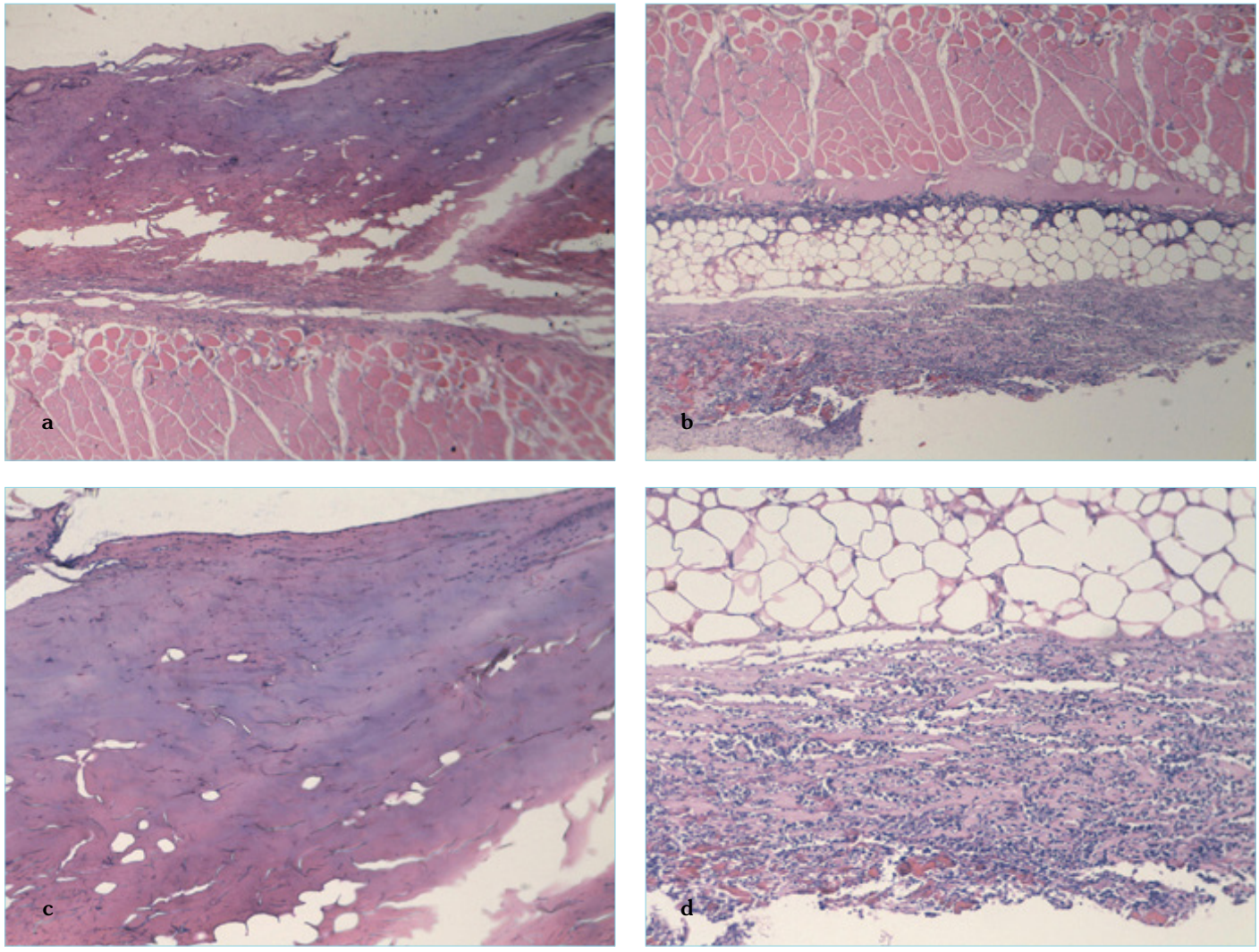

Figure 3. a-d. General appearance of the superficial (a) and deep (b) sections of the skin in the control group on post-operative day 3. The epidermis is not noticeable; the tissue has a homogenous eosinophilic appearance with striated muscle tissue underneath. There is intensive cellular infiltration beneath the subcutaneous adipose tissue. (×40, H-E). A close-up view of the superficial (c) and deep (d) sections of the skin in the control group on post-operative day 3. The dermis collagen has become homogenized, collagen fibers are indistinguishable, and there is no inflammatory cell infiltration. Intensive neutrophil and, to a lesser degree, macrophage and mononuclear cells in inflammatory infiltration can be seen (×100, H-E)

epidermis, and necrosis of the dermal, subcutaneous adiposal, and muscular tissues were observed (Figure 3).

In the pathological examination of the specimens taken from the flaps in the experimental group on the 4th, 5th, and 6th days, the tissues appeared completely vital. The integrity of the epidermis was preserved; the cutaneous appendices, dermis, subcutaneous, adipose, and muscular tissues were healthy; and a proteinous fluid existed in the vascular structures included in the sectional area (Figure 4, 5).

DISCUSSION

A multitude of research has been carried out and suggestions made to reduce the wide range of complications encountered during free flap applications. The ratio of vascular thrombosis reported in free flap surgery varies between 5.1% and 9.9% (11-13), and for the prevention of this complication, in addition to the suggestions of agents such as botulinum toxins, low molecular weight heparins, aspirin, prostaglandins, dextran inhibitors, and other various agents (14-22), studies on anastomosis have also been carried out (23-29).

Vascular thrombosis of the anastomosed vessels can lead to flap necrosis unless eliminated, and this will require the need for additional operations. In free tissue transplantation, the condition of the recipient vessels is also important and sometimes there may be occasions when a vessel has been damaged owing to trauma or radiotherapy. The risk of thrombosis in the vessels of the recipient region due to radiotherapy has also increased (2-6). In the absence of an appropriate vessel near the defect, or when the present ones are unsuitable for anastomosis for the reasons mentioned above, vessel grafts may be necessary; this not only makes the procedure more difficult, but also causes an increase in complications resulting from using a vessel graft (30).

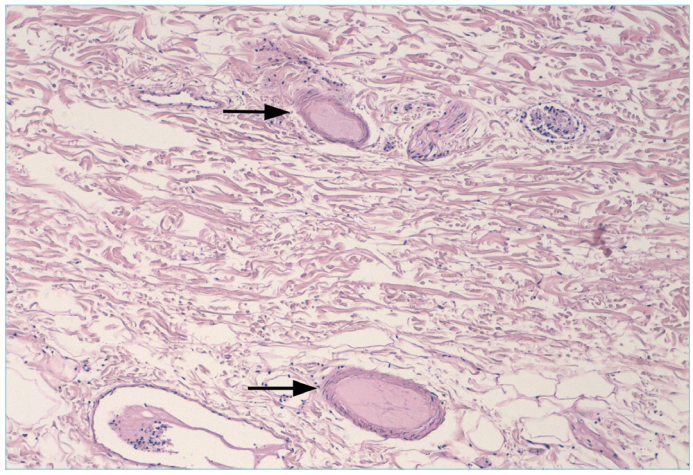

Figure 4. A close-up view of deep section of the skin in the experimental group on post-operative day 5 (×100, H-E). The presence of intravenous, homogenous, eosinophilic, and proteinous material in the lumen of the deep dermal veins should be noted (marked with arrows)

Except for the above-mentioned studies, which aimed at increasing the success rate in free flaps, there are no detailed studies directed at enabling free flaps to survive through an alternative circulation.

In transplantation and replantation operations, circulation of the organ or tissues has been terminated temporarily, similar to in free flap procedures. In these operations, it is essential that the viability of the tissues is preserved until the circulation is re-established. It has been demonstrated that perfusion of the tissues by Krebs-Ringer bicarbonate-glucose buffer solution, which contains sex hormones, can preserve the uterus for 48 h (31). Moreover, there are reports of perfusion methods also being used for organs such as the liver, the brain, amputated extremities, and flaps (32-35).

It is interesting that although there are a large number of studies on tissue preservation in transplantation and replantation procedures, the data obtained from these studies are not linked to free flap transfer. In the literature in English, the first, and so far unique, study containing information regarding the survival of flap tissue

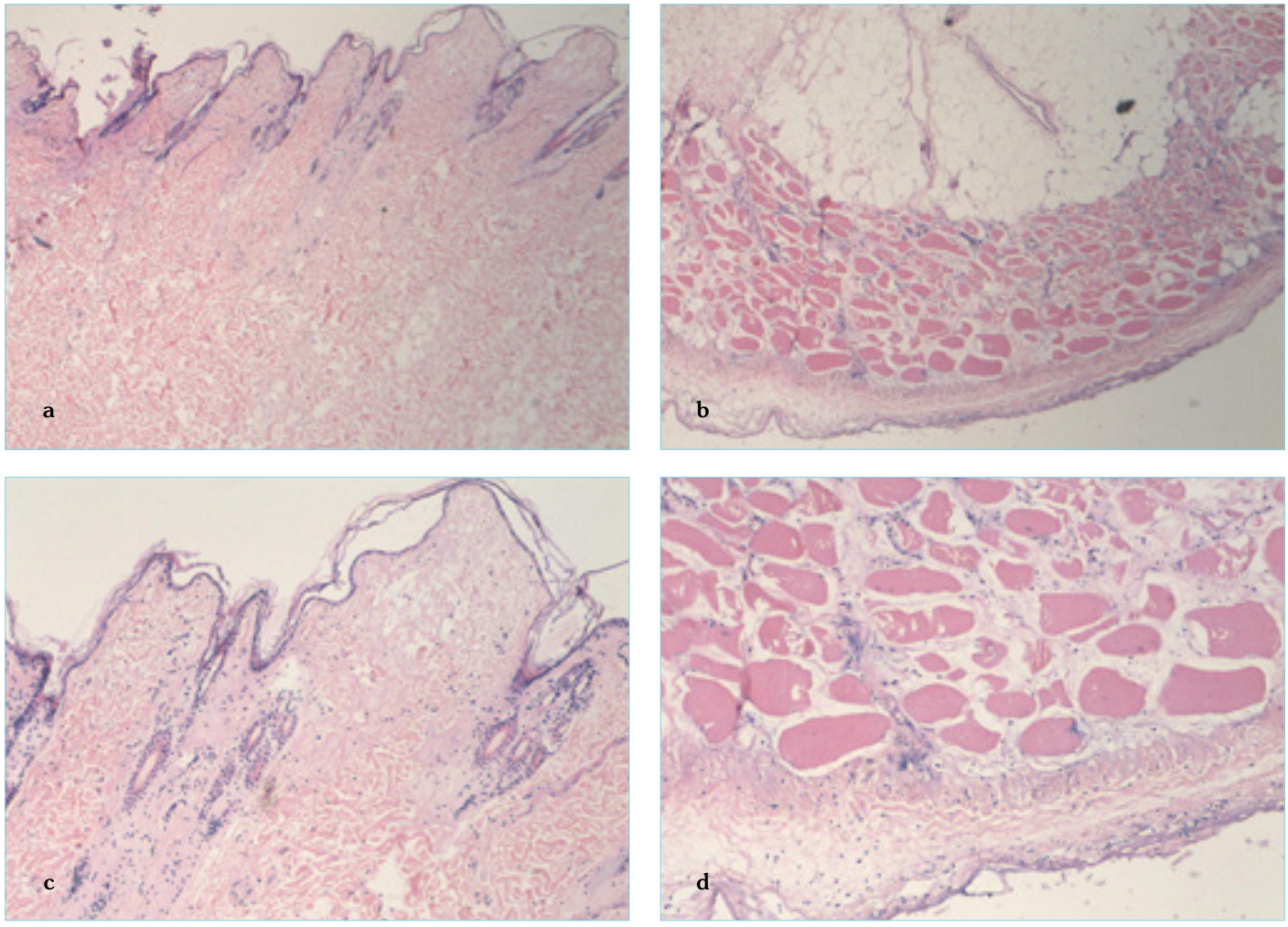

Figure 5. a-d. General appearance of the superficial (a) and deep (b) sections of the skin in the experimental group on post-operative day 6. The epidermis and dermis have normal histological appearance. Healthy deep dermal subcutaneous and striated muscular structures are visible (×40, H-E). A close-up view of the superficial (c) and deep (d) sections of the skin in the experimental group on post-operative day 6. While the epidermis is thin with a thickness of 1–3 cells, the dermis appears to be within a normal range. Slight degeneration and fibrosis can be observed in the striated muscular tissue (×100, H-E)

through extra-corporeal circulation was that by Maeda et al. (10) in 1993. This experimental study was conducted on venous flaps at a time when venous flaps were just beginning to take their place on the agenda of plastic surgery. Maeda et al. (10) perfused the thoracoepigastric vein-based flap with several solutions and showed that the flaps perfused with autologous plasma survived for 3 days. In the present study, instead of venous flaps, we tested a conventional, axially patterned flap model—the primary choice in clinical applications—in which the blood coming from the artery is drained by the vein.

The study by Maeda et al. (10) reports that in a preliminary study when the draining end of the vein is cannulated and perfusate is drained out, the cannula becomes blocked. The authors, therefore, abandoned this operation and did not cut off the draining vein, thus preserving its connection with normal anatomic circulation. However, since the model used by Maeda et al. is not an entirely extra-corporeal circulation model, it was not chosen in our study. In view of the extra load on the systemic circulation and possible allergic reactions caused by the infused plasma when the venous return is allowed to join the systemic circulation, the venous return was allowed to drain freely in our study.

In the present study, oxygenation was originally considered for the perfusion system by pumping oxygen or air through the plasma; however, it was later abandoned not only because it was known that the infusion pump would sense the air bubbles and automatically abort infusion, but also because Maeda et al. (10), in their study, demonstrated that plasma can provide flap survival even when it is not oxygenized.

The revascularization of flaps from the peripheral tissue starts on the postıoperative 4th to 5th day, and anastomosis occurs with the flap vessels (36). It is known that in experimental studies, revascularization sufficient to keep the flaps alive is completed within 5–10 days (37). It has also been reported that the vascular pedicle of the free flap transferred to the recipient site in a pig was ligated at various times and the crucial period for its vascularization from the wound bed to enable the flap to survive was 8 days (38). Our failure to enable the subjects to survive longer than 8 days unfortunately made it impossible to assess the vitality of the flaps through clinical observations.

The 5 cc/h perfusion rate, which was used in our study, was determined on the basis of this knowledge and the study by Maeda et al. (10) (5 cc/h for 3 x 4 cm, 65 gm flap).

In this study, the absence of a bank to provide autologous rabbit plasma and the necessity of destroying an impermissibly large number of rabbits in the existing circumstances (some 200 rabbits throughout the study) obliged us to use human plasma. In our opinion, human plasma would cause antigenically less sensitivity than other blood products, and is easily obtainable in large quantities. Despite the abundance of research on the xenotransfusion of red blood cells, our failure to encounter any data in the literature on inter-species plasma transfusion led us to do a preliminary study (39). In this study, no acute reaction was observed in a one-week period following the intravenous infusion of 20 cc human plasma into the systemic circulation of the rabbit, and the experiment was thus planned accordingly. Our failure to provide autologous plasma is one of the limiting factors in our study. Once the procurement of autologous plasma is achieved, one of the possible causes of mortality in the study could be eliminated.

Since none of the subjects lived long enough to permit the observation of the clinical life of the flaps, the long-term outcomes of the study could not be obtained; the results of an approximately 6-day long histopathological study, however, shed some light on the findings. However, histopathological studies demonstrated that the tissues followed up as the composite graft in the control group were necrotic on the 3rd day and afterwards, while the flaps in the experimental group perfused extra-corporeally with human plasma looked vital until the 6th day. This indicates that extra-corporeal perfusion, even by way of xenotransfusion, contributes to flap survival and prolongs the period during which it remains vital.

Although the causes of mortality could not be clarified in our study, we believe that either the late reactions of xenotransfusion or the cage that was built for the purpose of preserving the system but limited the natural movements and caprophagia requirements of the animal could be responsible. The fact that the animals in the control group also did not survive for longer than 9–10 days increases the probability that the subjects died from lack of movement, given that xenotransfusion cannot singly be the cause of death.

Another drawback of our study is the special cage, which restricted the animals' movements to protect the perfusion system. It was understood from the animals' food and water consumption that they did not suffer from any nutritional problem during the 7-day period during which they were kept in the cage. However, early mortality may have resulted from the fact that they were unable to conduct caprophagia and their natural movements were restricted.

Therefore, our study has some important drawbacks such as 1) lack of autologous plasma perfusion and 2) failure to ensure the subjects survived long enough for the macroscopic demonstration of flap life. Clearer outcomes could be procured from a study model in which autologous plasma perfusion and perfusate oxygenation can be achieved and by utilizing a perfusion method that is not affected by the movements of the subjects.

CONCLUSION

In conclusion, we observed that extra-corporeal circulation with plasma is effective in axial free flaps by prolonging the period during which the flap remains vital. We believe that if autologous plasma is obtained and the perfusion system is improved, flap survival could be achieved with the realization of extra-corporeal perfusion that is sufficient to allow the flap to have a chance to revascularize.

Ethics Committee Approval: Ethics committee approval was received for this study from Erciyes University Local Ethics Committee for Animal Experiments (HADYEK) (10/50).

Informed Consent: N/A.

Peer-review: Externally peer-reviewed.

Authors' Contributions: Conceived and designed the experiments or case: İÖ, Oİ. Performed the experiments or case: İÖ, Oİ. Analyzed the data: İÖ, Oİ, OK. Wrote the paper: İÖ. All authors have read and approved the final manuscript.

Conflict of Interest: No conflict of interest was declared by the authors.

Financial Disclosure: The authors declared that this study has received Erciyes University Scientific Research Unit (TSU-10-3288).

REFERENCES

1. Hansen SL, Young DM, Lang P, Sbitany H. Flap classification and applications. In; Neligan PC (Chief editor), Gurtner GC (volume editor). Plastic Surgery 3rd ed. Volume 1, London: Elsevier Saunders, 2013.p.511-572.
2. Halle M, Ekström M, Farnebo F, Tornvall P. Endothelial activation with prothrombotic response in irradiated microvascular recipient veins. J Plast Reconstr Aesthet Surg 2010;63(11): 1910-6. [CrossRef]
3. Fosnot J, Fischer JP, Smartt JM Jr, Low DW, Kovach SJ 3rd, Wu LC, et al. Does previous chest wall irradiation increase vascular complications in free autologous breast reconstruction? Plast Reconstr Surg 2011; 127(2): 496-504. [CrossRef]
4. Gürlek A, Miller MJ, Amin AA, Evans GR, Reece GP, Baldwin BJ, et al. Reconstruction of complex radiation-induced injuries using free-tissue transfer. J Reconstr Microsurg. 1998; 14(5): 337-40. [CrossRef]
5. Guelinckx PJ, Boeckx WD, Fossion E, Gruwez JA. Scanning electron microscopy of irradiated recipient blood vessels in head and neck free flaps. Plast Reconstr Surg 1984; 74(2): 217-26. [CrossRef]
6. Krag C, Holck S, DeRose G, Lyczakowski T, Freeman CR. Healing of microvascular anastomoses. A comparative study using normal and irradiated recipient vessels for experimental free flaps in rabbits. Scand J Plast Reconstr Surg 1982; 16(3): 267-74. [CrossRef]
7. Cigna E, Lo Torto F, Parisi P, Felli A, Ribuffo D. Management of microanastomosis in patients affected by vessel diseases. Eur Rev Med Pharmacol Sci 2014; 18(22): 3399-405.
8. Takamatsu A, Harashina T, Inoue T. Selection of appropriate recipient vessels in difficult, microsurgical head and neck reconstruction. J Reconstr Microsur 1996; 12(8): 499-507. [CrossRef]
9. Angel MF, Khazanchi RK, O'Brien BM. The anatomy of the subscapular artery and its effects on flap design in the rabbit. Ann Plast Surg 1990; 24(2): 152-5. [CrossRef]
10. Maeda M, Fukui A, Tamai S, Mii Y, Miura S. Extracorporeal circulation for tissue transplantation (in the case of venous flaps). Plast Reconstr Surg 1993; 91(1): 113-24. [CrossRef]
11. Kroll SS, Schusterman MA, Reece GP, Miller MJ, Evans GR, Robb GL, et al. Timing of pedicle thrombosis and flap loss after free-tissue transfer. Plast Reconstr Surg 1996; 98(7): 1230-3. [CrossRef]
12. Khouri RK, Cooley BC, Kunselman AR, Landis JR, Yeramian P, Ingram D, et al. A prospective study of microvascular free-flap surgery and outcome. Plast Reconstr Surg 1998; 102(3): 711-21. [CrossRef]
13. Bianchi B, Copelli C, Ferrari S, Ferri A, Sesenna E. Free flaps: outcomes and complications in head and neck reconstructions. J Craniomaxillofac Surg 2009; 37(8): 438-42. [CrossRef]
14. Janz BA, Thomas PR, Fanua SP, Dunn RE, Wilgis EF, Means KR Jr. Prevention of anastomotic thrombosis by botulinum toxin B after acute injury in a rat model. J Hand Surg Am 2011; 36(10): 1585-91. [CrossRef]
15. Fathi M, Fathi H, Mazloumi M, Khalilzadeh O, Amanpour S, Meysamie A, et al. Preventive effect of botulinum toxin A in microanastomotic thrombosis: a rabbit model. J Plast Reconstr Aesthet Surg 2010; 63(10): e720-4. [CrossRef]
16. Eom JS, Koh KS, Al-Hilal TA, Park JW, Jeon OC, Moon HT, et al. Antithrombotic efficacy of an oral low molecular weight heparin conjugated with deoxycholic asset on microsurgical anastomosis in rats. Thromb Res 2010; 126(3): e220-4. [CrossRef]
17. Brands MT, van den Bosch SC, Dieleman FJ, Bergé SJ, Merkx MA. Prevention of thrombosis after microvascular tissue transfer in the head and neck. A review of the literature and the state of affairs in Dutch Head and Neck Cancer Centers. Int J Oral Maxillofac Surg 2010; 39(2): 101-6. [CrossRef]
18. Hanasono MM, Butler CE. Prevention and treatment of thrombosis in microvascular surgery. J Reconstr Microsurg 2008; 24(5): 305-14. [CrossRef]
19. Lewis CM, Deschler DG. Desirudin reduces the rate of microvenous thrombosis in a rat model. Laryngoscope 2008; 118(7): 1149-52. [CrossRef]
20. Nayak VK, Deschler DG. Clopidogrel use for reducing the rate of thrombosis in a rat model of microarterial anastomosis. Arch Otolaryngol Head Neck Surg 2005; 131(9): 800-3. [CrossRef]
21. Lee KS, Suh JD, Han SB, Yoo JC, Lee SJ, Cho SJ. The effect of aspirin and prostaglandin E(1) on the patency of microvascular anastomosis in the rats. Hand Surg 2001; 6(2): 177-85. [CrossRef]
22. Lewis CM, Deschler DG. Desirudin reduces the rate of microvenous thrombosis in a rat model. Laryngoscope 2008; 118(7): 1149-52. [CrossRef]
23. Miyamoto S, Okazaki M, Ohura N, Shiraishi T, Takushima A, Harii K. Comparative study of different combinations of microvascular anastomoses in a rat model: end-to-end, end-to-side, and flow-through anastomosis. Plast Reconstr Surg 2008; 122(2): 449-55. [CrossRef]
24. Klöppel M, Tudor C, Kovacs L, Papadopulos NA, Höhnke C, Himsl I, et al. Comparison of experimental microvascular end-to-end anastomosis via VCS-Clips versus conventional suture technique in an animal model. J Reconstr Microsurg 2007; 23(1): 45-9. [CrossRef]
25. Stewart RB, Bass LS, Thompson JK, Nikoi ND, Becker G, Kung RT. Improved microvessel repair: laser welding with an anti-thrombotic solder. Lasers Surg Med 2002; 31(1): 36-40. [CrossRef]
26. Ichikawa M, Muneshige H, Ikuta Y. Comparison of tensile strength and thrombus formation between mechanical microvascular anastomoses using a biodegradable ring device and sutured anastomoses. J Reconstr Microsurg 2002; 18(2): 131-6. [CrossRef]
27. Pikoulis E, Burris D, Rhee P, Nishibe T, Leppäniemi A, Wherry D, et al. Rapid arterial anastomosis with titanium clips. Am J Surg 1998; 175(6): 494-6. [CrossRef]
28. Zhong C, Tang NX, Zheng CF, Xu YW, Wang TD. Experimental study on microvascular anastomosis using a dissolvable stent support in the lumen. Microsurgery 1991; 12(2): 67-71. [CrossRef]
29. Nakayama Y, Soeda S, Iino T, Uchida A. Is the sleeve anastomosis a risky technique? Br J Plast Surg 1987; 40(3): 288-94. [CrossRef]
30. Kroll SS, Schusterman MA, Reece GP, Miller MJ, Evans GR, Robb GL, et al. Choice of flap and incidence of free flap success. Plast Reconstr Surg 1996; 98(3): 459-63. [CrossRef]
31. Bulletti C, Jasonni VM, Martinelli G, Govoni E, Tabanelli S, Ciotti PM, et al. A 48-hour preservation of an isolated human uterus: endometrial responses to sex steroids. Fertil Steril 1987; 47(1): 122-9. [CrossRef]
32. Kamada N, Calne RY, Wight DG, Lines JG. Orthotopic rat liver transplantation after long-term preservation by continuous perfusion with fluorocarbon emulsion. Transplantation 1980; 30(1): 43-8. [CrossRef]
33. Sloviter HA, Kamimoto T. Erythrocyte substitute for perfusion of brain. Nature 1967; 216(5114): 458-60. [CrossRef]
34. Constantinescu MA, Knall E, Xu X, Kiermeir DM, Jenni H, Gygax E, et al. Preservation of amputated extremities by extracorporeal blood perfusion; a feasibility study in a porcine model. J Surg Res 2011; 171(1): 291-9. [CrossRef]
35. Usui M, Ishii S, Muramatsu I. An experimental study on the effect of fluorocarbon on the preservation of free skin flaps in the rabbit. Clin Orthop Relat Res 1983; 175: 273-9.
36. Daniel RK, Kerrigan CL. Principles and physiology of skin flap surgery. In: Mc Carthy Plastic Surgery, Ed McCarthy JG, Plastic Surgery, Vol I, 1990, Philadelphia: WB Sounders Co. p. 275-328.
37. Fisher J, Gingrass MK. Basic principles of skin flaps. In: Georgiade GS, Georgiade NG, Riefkohn R, Barwick WJ Eds. Text book of Plastic Maxillofacial and Reconstructive Surgery, 3rd ed. Baltimore: Williams and Wilkins, 1997, p.19-29.
38. Black MJM, Chait L, O'Brien BMC, Sykes PJ, Sharzer LA, et al. How soon may the axial vessels of a surviving free flap be safely ligated? A study in pigs. Br J Plast Surg 1978; 31: 295-9. [CrossRef]
39. Roux FA, Saï P, Deschamps JY. Xenotransfusions, past and present. Xenotransplantation 2007; 14(3): 208-16. [CrossRef]