ARAŞTIRMA/ORIGINAL ARTICLE

Gülhane Tıp Derg 2015;57: 102-106
© Gülhane Askeri Tıp Akademisi 2015
doi: 10.5455/gulhane.173504

A novel platelet concentrate for guided bone regeneration: Titanium Prepared Platelet-Rich Fibrin (T-PRF):

Mustafa TUNALI (*), Hakan ÖZDEMİR (**), Zafer KÜÇÜKODACI (***), Şeref EZİRGANLI (****), Emre BARIŞ (*****), Serhan AKMAN (******), Arzu ATAY (*******), Erhan FIRATLI (********)

SUMMARY

In our previous studies, we developed a novel platelet-rich product that we called titanium-prepared platelet-rich fibrin (T-PRF). T-PRF is based on the hypothesis that titanium may be more effective at activating platelets than the silica activators used with glass tubes in Chouckroun's platelet-rich fibrin (PRF). This study aimed to assess the effects of T-PRF on bone augmentation in a rabbit calvaria model. Twenty-four adult male New Zealand rabbits were used in the study. T-PRF alone, inorganic bovine bone (ABB), and T-PRF + ABB were used in the experimental groups. No material was used in the control group. Half of the animals were sacrificed after one month, and the remaining animals were sacrificed 3 months later. A histomorphometric evaluation was performed to compare new bone formation among the groups. More new bone areas were determined in the T-PRF group than the other three groups. While less new bone formation was observed than in the T-PRF group, more new bone formation occurred in the ABB and T-PRF + ABB groups when compared to the control group. Basing on the results of this study, we can say that T-PRF membrane can be successfully used for bone augmentation.

Key words: *Tissue Engineering; Biomaterial(s); Guided Bone Regeneration; T-PRF; Regenerative medicine*

ÖZET

Yönlendirilmiş Kemik Rejenerasyonu İçin Yeni Bir Trombositten Zengin Ürün: Titanyum Destekli Trombositten Zengin Fibrin

Önceki çalışmalarımızda, titanyum destekli trombositten zengin fibrin (T-PRF) olarak adlandırdığımız yeni bir trombositten zengin ürün geliştirdik. T-PRF fikri Chouckroun'un trombositten zengin fibrininde (PRF) titanyumun, trombositlerin aktivasyonunda cam tüplerdeki silika aktivatörlerden daha etkili olabileceği hipotezinden doğdu. Bu çalışmanın amacı T-PRF'nin kemik ogmentasyonundaki etkinliğini, tavşan kafatası modelinde değerlendirmektir. Çalışmada yirmi dört adet yetişkin erkek Yeni Zellanda tavşanı kullanılmıştır. Tek başına T-PRF, inorganik sığır kaynaklı kemik grefti (ABB) ve T-PRF + ABB ü deneysel gruplarda kullanılmışlardır. Kontrol grubunda hiçbir materiyal kullanılmamıştır. Deney hayvanlarının yarısı 1 ay sonra, diğer yarısı ise 3 ay sonra sakrifiye edilmiştir. Gruplardaki yeni kemik oluşumunu karşılaştırmak amacı ile histomorfometrik değerlendirme yapılmıştır. Diğer üç gruba göre T-PRF grubunda daha fazla yeni kemik alanları belirlenmiştir. T-PRF grubuna göre daha az yeni kemik oluşumu görülmesine ragmen, ABB ve T-PRF+ABB gruplarında, kontrol grubu ile karşılaştırıldıklarında, daha fazla yeni kemik oluşumu gözlenmiştir. Bu çalışmanın sonuçlarına dayanarak, T-PRF membranın kemik ogmentasyonunda başarılı bir şekilde kullanılabilir olduğunu söyleyebiliriz.

Anahtar Kelimeler: Doku Mühendisliği; Biyomateriyal(ler); Yönlendirilmiş Kemik Rejenerasyonu; T-PRF; Rejeneratif tıp

*Department of Periodontology, Gulhane Military Medical Academy, Haydarpaşa Training Hospital, Istanbul, Turkey.
**Department of Periodontology, School of Dentistry, Osmangazi University, Eskisehir, Turkey.
***Department of Medical Pathology, Gulhane Military Medical Academy, Haydarpaşa Training Hospital, Istanbul, Turkey.
****Department of Oral Surgery, School of Dentistry, Bezmialem Vakif University, Istanbul, Turkey.
*****Department of Oral Pathology, School of Dentistry, Gazi University, Ankara, Turkey.
******Department of Prosthetic Dentistry, School of Dentistry, Selcuk University, Konya, Turkey .
*******Department of Prosthetic Dentistry, Gulhane Military Medical Academy, Haydarpaşa Training Hospital, Istanbul, Turkey.
********Department of Periodontology, School of Dentistry, Istanbul University, Istanbul, Turkey

Ayrı Basım İsteği: Mustafa Tunalı,
Department of Periodontology,
Haydarpaşa Training Hospital, Gulhane Military Medical Academy,
Üsküdar, Istanbul, Türkiye
Tel: +90 532 7772570
E-mail: mustafatunali@hotmail.com

Makalenin Geliş Tarihi: Nov 25, 2014 • **Kabul Tarihi:** Feb 22, 2015 • **Çevrim İçi Basım Tarihi:**30 Haziran 2015

Introduction

Using platelet-rich products has become common in many branches of medicine and dentistry in recent years (1). PRF, which was first developed by Chouckroun (2), has attracted attention among the platelet-rich products (3-7). Unlike other platelet-rich products, PRF does not require anticoagulant, bovine thrombin, or any other gelling agents (3). PRF is completely autogenous, and its protocol is open and free, leading to its widespread use. Moreover, other studies have proved that PRF includes many growth factors, such as platelet-derived growth factor AB (PDGF-AB), transforming growth factor-1 (TGF-1), and vascular endothelial growth factor (VEGF), which are the advantages of this product (8). Successful studies have been reported with PRF (9-18).

Nevertheless, silica in the glass tube is required for the formation of platelet aggregation and fibrin in PRF. Some physicians (19) worry about a possible health hazards with glass-evacuated blood collection tubes with silica activators. O'Connell (19) described the unavoidable silica contact. O'Connell (19) claimed that the silica particles used in the glass tubes, although dense enough to sediment with the red blood cells, are sufficiently small for a fraction to remain in colloidal suspension in the buffy coat, fibrin, and platelet-poor plasma layers and will thus contaminate any therapeutic application to the patient.

The PRF resorption period is 7-11 days in vivo in humans, which is successful in soft-tissue healing; however, its success with guided bone regeneration (GBR) and guided tissue regeneration (GTR) techniques in bone healing remains unclear (6).

In our initial trials, we observed that titanium-induced platelet aggregation similar to glass tubes, and the clot produced in the titanium tubes was clinically identical compared to glass tubes. We also established that the fibrin carpet formed with titanium had a firmer network structure (20), and the resorption in the tissue was longer (21). This material is also used to avoid any short and/or long-term negative effects of dry glass or glass-coated plastic tubes and to eliminate the concerns regarding silica (19). To date, no study has had the accurate protocol to indicate that PRF and/or T-PRF are effective in bone healing, nor has any study clearly assessed early and late-stage bone healing. This study aimed to evaluate the histological and histomorphometric effects of T-PRF on a rabbit bone model.

Materials and methods

Twenty-four New Zealand white rabbits aged 5 months with an average weight of 3 kg were used in this study.

The experimental procedures for this study were approved by the Institutional Review Board and Animal Use Committee of the Cumhuriyet University, Faculty of Medicine (B.30.2.CUM.0.01.00.00-50/85). This study was conducted according to the principles of the Basel Declaration 2010. The study was conducted following the accepted guidelines for the care and use of laboratory animals for research. All of the animals were housed in a standard cage in an experimental animal room (22–24°C, 55–70% humidity, 1 atm, and 12-h light/dark cycle). They were fed with a standard laboratory diet, and drinking water was available ad libitum during the experiment.

Study design and experimental procedures

The rabbits were divided into four groups (one control group and three experimental groups), and each group contained six animals. The materials used were T-PRF, inorganic bovine bone (ABB) with a 0.25–1 mm particle size (Bio-Oss®; Geistlich Biomaterials, Wolhusen, Switzerland), and T-PRF + ABB. Any materials that were used with the titanium barriers in the experimental groups were not used in the control group. Half of the animals from each group were sacrificed after 1 month, and the remaining animals were sacrificed after 3 months.

Presurgically, stiff dome-shaped pure titanium barriers with a diameter of 8 mm, a height of 4 mm, and a thickness of 0.3 mm were moulded commercially. There was a hole with a diameter of 3 mm at the top of the barriers, and a Teflon cover was made for the hole. All of the barriers were cleaned in a series of alcohol solutions in an ultrasonic bath to remove possible contaminants. Then, the barriers were sterilised by autoclave.

Surgical procedure

All of the rabbits were given an intramuscular antibiotic, 50-mg/kg ceftriaxone (Rocephin; Roche, Basel, Switzerland) every 24 h for 4 days, starting 1 day before surgery. They were also given an intramuscular analgesic, 4-mg/kg carprofen (Rimadyl; Pfizer, New York, IL, USA), every 24 h for 3 days, starting immediately after the operation. All of the operations were conducted under sterile conditions. The rabbits were anaesthetised using an intramuscular injection of 10-mg/kg xylazine hydrochloride (Rompuns; Bayer, Leverkusen, Germany) and 50-mg/kg ketamine hydrochloride (Ketasol® 10%; Richter Pharma AG, Wels, Austria). After administering general anaesthesia, the scalps of the rabbits were shaved, and the skin was disinfected with a povidone-iodine solution before the operation. A skin incision, approximately 4 cm in length over the linea media, was made to dissect the skin from the skull. A skin flap was raised laterally using a small sharp periosteal elevator, and then the periosteum was incised and lifted to expose the parietal bone on both sides of the midline. At the experimental and control sites, nine smaller holes were drilled around the central hole using a burr approximately 1.5 mm in diameter under profuse irrigation with sterile saline to induce bleeding from the marrow space. Care was taken to irrigate the wounds thoroughly. Two barriers were used for every rabbit. The borders of the barriers were glued to the bone with N-butyl-2-cyanoacrylate (Histoacryl®; B.Braun, Melsungen, Germany). In group 1 (control group), only decortications were performed on the parietal bone. In group 2, T-PRF was used. Blood samples from 12 rabbits were used for the T-PRF operations. Titanium tubes were made from grade IV titanium. A total of 10 ml of blood from each rabbit was drawn with a syringe from the marginal vein on the right or left ear in one attempt and transferred to titanium tubes. The blood samples were collected rapidly, and the tubes were immediately centrifuged at 3,500 rpm for 15 min (21) using a table centrifuge (EBA 20, Andreas Hettich GmbH & Co. KG, Tuttlingen Germany) at room temperature. After centrifugation, the clots were removed from the tubes using sterile tweezers, separated from the base of red blood cells (RBC), and pressed between two pieces of gauze. In group 3, inorganic bovine bone (ABB) graft material was used. In group 4, T-PRF + ABB were used. The graft materials with rabbit blood were filled through a hole on top of the barriers. The titanium barriers in all of the groups including control group were covered by a teflon cover to prevent the invasion of the soft tissues (Fig. 1). The remaining skin was carefully sutured with resorbable 3/0 polyglactin 910 sutures (Vicryl; Ethicon, Somerville, NJ, USA). All of the rabbits were examined for wound cleaning every other day for 2 weeks.

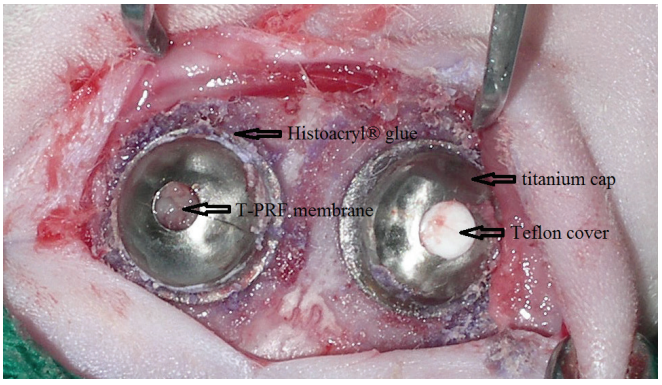

Figure 1. Clinical photograph. A cutaneous flap was lifted and the parietal bone was exposed. Nine smaller holes were drilled around the central hole using a round burr with a diameter of approximately 1.5 mm. The titanium cap was fixed to the bone with Histoacryl® glue. The graft materials with rabbit blood were filled through a hole on top of the barriers. The hole on top of the titanium barrier was covered by a Teflon cover.

Specimen preparation

We sacrificed all of the animals employing an overdose of 200-mg/kg IV pentobarbital, and dissected the calvarium out of the soft tissue. We took biopsies, involving the calvarium and two titanium barriers using a surgical burr fixed to a low-speed electrical hand-tool and conserved them in 10% buffered formaldehyde. We removed the calcium from the samples using 10% formic acid and then dehydrated. We removed the samples vertically from a section approximately 3-mm thick in the middle of the decalcification and embedded them in paraffin.

Histological analysis

We obtained nearly 5mm-thick sections, and stained them with haematoxylin–eosin (H&E), and van Gieson Trikrom (Trc) for analysis under light microscope. A single examiner blinded to the identity of the samples did the histological analysis. The connective and/or granulation tissue, bone formation, bone marrow, and presence of grafted material of the sections were assessed using a light microscope.

Histomorphometric analysis

Another examiner blinded to the treatment did the histomorphometric analysis. To observe further mineralised bone formation, we took the images of the histological sections from three various parts of each section with a digital camera under

polarised light. We employed a photo-light microscope with an attached camera to take pictures (X400) from each section; We loaded the pictures into a computer to analyse them histomorphometrically. The bone areas (mm²) formed newly in each picture were evaluated with the histomorphometry software (Leica QWin Plus V 3.3.1; Leica Microsystems Ltd Stereo & Macroscope Systems CH-9435 Heerbrugg, Switzerland), and their mean values were established.

Statistical analysis

The data obtained were evaluated with Kruskal–Wallis analysis of variance followed by the Tukey test for pairwise comparisons (intergroup comparison) and the Mann-Whitney U test (intragroup comparison) after normality was established with the Kolmogorov–Smirnov test. P values less than 0.05 were regarded as statistically significant. For the statistical analysis, we employed SPSS version 14 (SPSS Inc., Chicago, IL). Since the test and control groups were not considered to be independent, a prior statistical power analysis was done using a software program (PC-Size, Dallal GE, Boston, MA, USA), under the hypothesis of normality for the variables examined. Six animals from each group was efficient enough to reveal difference in new bone area with the calculations at the 5% significance level with 81% statistical accuracy (22).

Results

No surgical complications occurred during the operation. After the intervention, the animals recovered without postoperative signs of infection. One rabbit was lost after general anaesthesia and in the first month during the study. This rabbit was replaced with another rabbit. After the operation, the rabbits were assessed once a week on a regular basis.

Histological analysis

In all of the specimens, bone formation had occurred to a much higher degree in the centre than in the periphery of the dome-shaped tissue. A layer of dense fibrous connective tissue lined the entire periphery of the dome-shaped tissue in all groups. There was higher active bone formation in the first and third months in the T-PRF group than in the other three groups (Figure 2). The resorption of the T-PRF membrane was not completed in the first month in the T-PRF group (Fig. 3). No signs of resorption was present in the ABB graft particles in the first month. However, osteoclastic activity was detected in the third month in the ABB and ABB+T-PRF groups (Fig. 2). Osteoclastic activity in the ABB+T-PRF group was not statistically higher than in the ABB group. The titanium barriers were almost completely filled with loose and hard tissue in the T-PRF, ABB, and ABB+T-PRF groups but was not completely filled in the control group.

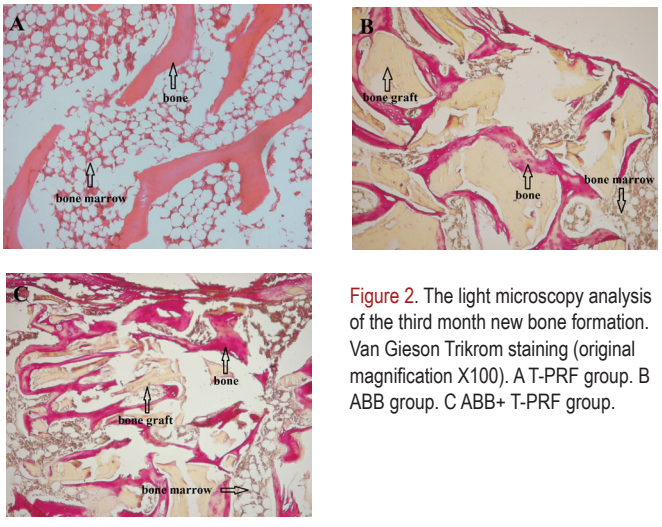

Figure 2. The light microscopy analysis of the third month new bone formation. Van Gieson Trikrom staining (original magnification X100). A T-PRF group. B ABB group. C ABB+ T-PRF group.

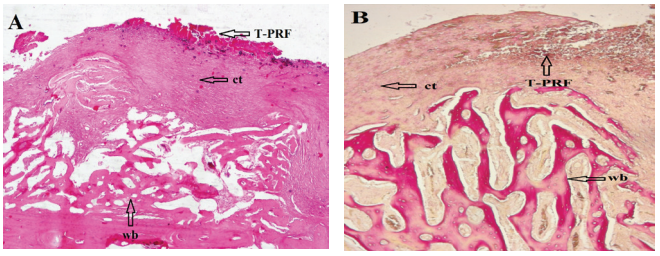



Figure 3. Active bone formation in the first month in the T-PRF group. A Hematoxylin and eosin staining (original magnification X40). Woven bone area (wb), dense fibrous connective tissue (ct), T-PRF membrane remains (T-PRF). B Van Gieson Trikrom staining (original magnification X100). Woven bone area (wb), dense fibrous connective tissue (ct), T-PRF membrane remains (T-PRF). C Polarized light photo (original magnification X20) New bone area boundaries are observed.

Histomorphometric analysis

When histomorphometric values of new bone formation in the first and third months were compared, more new bone formation was observed in the third month than at the first month for all of the groups. The differences between the groups were examined in terms of histomorphometric values, and the T-PRF had more new bone formation than the other three groups. No statistical significance was noted between ABB and ABB+ T-PRF groups (Figure 4, 5).

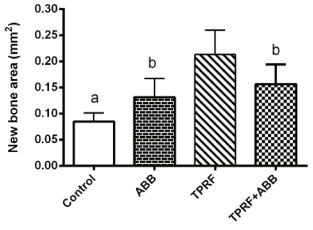

Figure 4. New bone area (mm2) of all groups one month after operation. (p<0.05) ap<0.05 versus T-PRF, ABB, T-PRF+ABB; bp<0.05 versus Control and T-PRF.

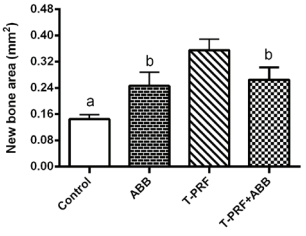

Figure 5. New bone area (mm2) of all groups three months after operation. (p<0.05) ap<0.05 versus T-PRF, ABB, T-PRF+ABB; bp<0.05 versus Control and T-PRF.

Discussion

According to the results of this study, T-PRF membrane was able to remain in the tissues for at least 1 month, which was sufficient time for the initiation of formation of new bone. T-PRF produced significantly more new bone than the control group when used alone as a membrane in a model of rabbit bone healing. In addition, when compared to bone grafting, T-PRF had a similar osteoconductive effect but was superior in terms of the amount of new bone. The maturation of new bone was faster in the T-PRF group than in the bone grafting group. Because the resorption of ABB bone graft was not completed in the 3rd month, new bone formation must occur much later. While the osteoconductive features were good in the T-PRF + ABB group, the graft resorption amount was si-

milar to the bone graft group. Consequently, the formation of new bone cannot occur quickly in the T-PRF + ABB group than in the ABB group.

In previous in vivo studies conducted using Chouckroun's PRF in rabbits (23, 24), the classic PRF protocol used in human subjects was not changed, and the material obtained was accepted as PRF. However, because obtaining a sufficient amount of blood in a short period of time from a rabbit, which Dohan et al. (25) considers to be a rather small animal, is not possible, in vivo studies of PRF on larger number of animals are necessary. Dohan et al. (25) asserted that the PRF-like product obtained from rabbits using the human protocol was not actually PRF and that rabbit studies would not produce accurate results. In preliminary trials in rabbits using the human PRF protocol to produce T-PRF, we encountered the same product described by Dohan et al. [25]. Although we adjusted the duration of the blood collection based on the human protocol, we observed that the structure did not change, and we were not able to obtain clinically complete T-PRF with the desired consistency. These results led us to experiment with protocols to produce platelet-rich products in rabbits based on the structural differences between human and rabbit blood (21). Based on this hypothesis, we gradually increased the duration and speed of centrifugation. After obtaining a clinical product similar to T-PRF, centrifugation of rabbit blood for 15 min at 3,500 rpm showed optimal fibrin formation based on observations using SEM. Clinically mature T-PRF clots were observed in all of test animals (6 rabbits) when their blood was centrifuged using the protocol of 15 min at 3,500 rpm.

This study is the first T-PRF bone-healing model using accurate protocol developed for the rabbits. In our previous study using a soft tissue healing model (21), we reported that the resorption period of T-PRF in tissue was long and showed that T-PRF could have longer effects on rabbits that had faster metabolism than PRF, which has a resorption time of 7-11 days in humans (26). In this study on bone healing, the osteoconductive property of T-PRF was good, and T-PRF membrane remains were observed in the first month controls when used as a membrane alone. Successful results have been obtained in the soft tissues and sinuses in studies using PRF in humans (9-18).

However, PRF was generally used with bone grafts in GBR and GTR studies (16). Chouckron et al. (7) claimed that PRF decreased the bone graft resorption time. We did not observe this condition in T-PRF in our study. Nevertheless, we believe that whether the leukocyte-rich fibrin product T-PRF brings antibacterial features to the graft (27) and whether T-PRF brings short-and long-term benefits to the graft factors in the region are questions that should be explored.

In conclusion, within the limitations of our study, we demonstrated that platelet-rich product aggregated with titanium could be used instead of a bone graft in a bone healing model and could produce more new bone in less time than when used alone. However, investigating the markers of bone healing and future animal studies with the accurate protocol will be extremely useful to understand comprehensively the effectiveness of the newly developed product.

References

1. Cieslik-Bielecka A, Dohan Ehrenfest DM, Lubkowska A, et al. Microbicidal properties of Leukocyte- and Platelet-Rich Plasma/Fibrin (L-PRP/L-PRF): new perspectives. J Biol Regul Homeost Agents 2012; 26:43-52.
2. Choukroun J, Adda F, Schoeffler C, et al. An opportunity in perio-implantology: the PRF. Implantodontie 2001; 42:55-62 [in French].
3. Dohan DM, Choukroun J, Diss A, et al. Platelet-rich fibrin (PRF): a second-generation platelet concentrate. Part I: technological concepts and evolution. Oral Surgery, Oral Medicine, Oral Pathology, Oral Radiology, and Endodontics 2006; 101:e37-44.
4. Dohan DM, Choukroun J, Diss A, et al. Platelet-rich fibrin (PRF): a second-generation platelet concentrate. Part III: leucocyte activation: a new feature for platelet concentrates? Oral Surgery, Oral Medicine, Oral Pathology, Oral Radiology and Endodontics 2006; 101:e51-5.
5. Dohan Ehrenfest DM, Rasmusson L, Albrektsson T. Classification of platelet concentrates: from pure platelet-rich plasma (P-PRP) to leucocyte- and platelet-rich fibrin (L-PRF). Trends in Biotechnology 2009; 27:158-67.
6. Choukroun J, Diss A, Simonpieri A, et al. Platelet-rich fibrin (PRF): a second-generation platelet concentrate. Part IV: clinical effects on tissue healing. Oral Surgery, Oral Medicine, Oral Pathology, Oral Radiology and Endodontics 2006; 101:e56-60.
7. Choukroun J, Diss A, Simonpieri A, et al. Platelet-rich fibrin (PRF): a second-generation platelet concentrate. Part V: histologic evaluations of PRF effects on bone allograft maturation in sinus lift. Oral Surgery, Oral Medicine, Oral Pathology, Oral Radiology and Endodontics 2006; 101:299-303.
8. Dohan DM, Choukroun J, Diss A, et al. Platelet-rich fibrin (PRF): a second-generation platelet concentrate. Part II: platelet-related biologic features. Oral Surgery, Oral Medicine, Oral Pathology, Oral Radiology and Endodontics 2006; 101:45-50.
9. Del Corso M, Sammartino G, Dohan Ehrenfest DM. Clinical evaluation of a modified coronally advanced flap alone or in combination with a platelet-rich fibrin membrane for the treatment of adjacent mul-tiple gingival recessions: a 6-month study. Journal of Periodontology 2009; 80:1694-7.
10. Huang FM, Yang SF, Zhao JH, et al. Platelet-rich fibrin increases proliferation and differentiation of human dental pulp cells. Journal of Endodontics 2010; 36:1628-32.
11. Sharma A, Pradeep AR. Autologous platelet rich fibrin in the treatment of mandibular degree II furcation defects: a randomized clinical trial. Journal of Periodontology 2011; 82:1396-403.
12. Simonpieri A, Choukroun J, Del Corso M, et al. Simultaneous sinus-lift and implantation using microthreaded implants and leukocyte- and platelet-rich fibrin as sole grafting material: a six-year experience. Implant Dentistry 2011; 20:2-12.
13. O'Connell SM, Impeduglia T, Hessler K, et al. Autologous platelet-rich fibrin matrix as cell therapy in the healing of chronic lower-extremity ulcers. Wound Repair and Regeneration 2008; 16:749-56.
14. Braccini F, Tardivet L, Dohan Ehrenfest DM. The relevance of Choukroun's Platelet-Rich Fibrin (PRF) during middle ear surgery: preliminary results. Revue de

Laryngologie Otologie Rhinologie 2009; 130:175-80 [in French].

15. Baeyens W, Glineur R, Evrard L. The use of platelet concentrates: platelet-rich plasma (PRP) and platelet-rich fibrin (PRF) in bone recon-struction prior to dental implant surgery. Revue Medicale de Bruxelles 2010; 31:521-7 [in French].
16. Inchingolo F, Tatullo M, Marrelli M. Trial with Platelet-Rich Fibrin and Bio-Oss used as grafting materials in the treatment of the severe maxillar bone atrophy: clinical and radiological evaluations. European Review for Medical and Pharmacological Sciences 2010; 14:1075-84.
17. Toffler M, Toscano N, Holtzclaw D. Osteotome-mediated sinus floor elevation using only platelet-rich fibrin: an early report on 110 patients. Implant Dentistry 2010; 19:447-56.
18. Gürbüzer B, Pikdöken L, Tunali M, et al. Scintigraphic evaluation of osteoblastic activity in extraction sockets treated with platelet-rich fibrin J Oral Maxillofac Surg 2010; 68(5):980-9.
19. O'Connell SM Safety issues associated with platelet-rich fibrin method. Oral Surgery, Oral Medicine, Oral Pathology, Oral Radiology and Endodontics 2007; 103:587-93.
20. Tunalı M, Özdemir H, Küçükodacı Z, et al. A Novel Platelet Concentrate: Titanium Prepared Platelet-Rich Fibrin (T-PRF). Biomed Res Int 2014; 209548.
21. Tunalı M, Özdemir H, Küçükodacı Z, et al. In vivo evaluation of titanium-prepared platelet-rich fibrin (T-PRF): a new platelet concentrate. Br J Oral Maxillofac Surg 2013; 5:438-43.
22. Lee E-H, Kim J-Y, Kweon HY, et al. A combination graft of low- molecular-weight silk fibroin with Choukroun platelet-rich fibrin for rabbit calvarial defect. Oral Surgery, Oral Medicine, Oral Pathology, Oral Radiology and Endodontics 2010; 109:33-8.
23. Ezirganli S, Polat S, Barıs¸ E, et al. Comparative investigation of the effects of different materials used with a titanium barrier on new bone formation. Clinical Oral Implants Research 2013; 24:312-9.
24. Ozdemir H, Ezirganli S, Isa Kara M, et al. Effects of platelet rich fibrin alone used with rigid titanium barrier. Arch Oral Biol 2013; 58:537-44.
25. Dohan Ehrenfest DM, Del Corso M, Inchingolo F, et al. Selecting a relevant in vitro cell model for testing and comparing the effects of a Choukroun's platelet-rich fibrin (PRF) membrane and a platelet-rich plasma (PRP) gel: tricks and traps. Oral Surgery, Oral Medicine, Oral Pathology, Oral Radiology and Endodontics 2010; 110:409-11.
26. Dohan Ehrenfest DM, de Peppo GM, Doglioli P, et al. Slow release of growth factors and thrombospondin-1 in Choukroun's platelet-rich fibrin (PRF): a gold standard to achieve for all surgical platelet concentrates technologies. Growth Factors 2009; 27:63-9.
27. Cieslik-Bielecka A, Dohan Ehrenfest DM, Lubkowska A, Bielecki T. Microbicidal properties of Leukocyte- and Platelet-Rich Plasma/Fibrin (L-PRP/L-PRF): new perspectives. J Biol Regul Homeost Agents 2012; 26(2 Suppl 1):43-52.

Acknowledgements

"I affirm that we have no financial affiliation (e.g., employment, direct payment, stock holdings, retainers, consultantships, patent licensing arrangements or honoraria), or involvement with any commercial organization with direct financial interest in the subject or materials discussed in this manuscript, nor have any such arrangements existed in the past three years. Any other potential conflict of interest is disclosed."

This study was supported by Scientific Research Project Coordination Center of Gulhane Military Medical Academy.