Volume: 30, Issue: 2, April 2019 pp: 117-120 ORIGINAL ARTICLE

EARLY RESULTS OF ANTERIOR CERVICAL DISCECTOMY AND FUSION WITH INTERBODY CAGES

Burcu GÖKER[1]

[1]*Department of Neurosurgery, Istinye University Medical Faculty, Liv Hospital Ulus, Istanbul, Turkey.*

ORCID Numbers:
Burcu GÖKER: 0000-0002-6084-8690

Address: Burcu Göker,
Department of Neurosurgery, Istinye University Medical Faculty, Istanbul, Turkey.
Phone: +90 532 641 98 22
E-mail: burcugoker79@yahoo.com
Received: 11th December, 2018
Accepted: 22th February, 2018

ABSTRACT

Introduction: Anterior cervical discectomy and fusion (ACDF) with interbody cages has been widely used for cervical degenerative disc disease (DDD) along with the other procedures (simple discectomy, cervical disc arthroplasty, ACDF with plating etc.) The aim of the study is to analyze the clinical outcomes measured by Visual Analog Scale (VAS) scores and Odom's criteria after ACDF with blade polyetheretherketone (PEEK) cage plus bioactive bone graft substitute.

Materials and Methods: 83 patients operated by a single neurosurgeon on for singel-level or multi-level ACDF with bladed PEEK cage was evaluated retrospectively. Clinical outcome scores measured by VAS scores and Odom's criteria; postoperative fusion rates were analyzed on postoperative cervical radiographs. Early postoperative complications, implant failures and progression to adjacent segment disease were investigated.

Results: In our study, one-level ACDF was performed on 51 patients, two-level ACDF was performed on 29 patients and three level ACDF was performed on 3 patients. 91.6 % (76 patients) of the patients presented with radiculopathy, whereas, 8.4 % (7 patients) of the patients presented with radiculomyelopathy. Mean follow-up is 18 months (range 1-32 months). VAS scores were improved in 97.6 % of the patients. According to Odom's criteria, 95 % of the patients evaluated the surgery success as excellent; 5% of the patients evaluated the surgery success as good. All of the patients with radiculopathic symptoms fully recovered, whereas, 4 patients (57.2 %) with radiculomyelopathy had improved, whereas in 3 patients (42.8 %) neurological status did not changed postoperatively. Symptomatic adjacent segment disease was not encountered in any of the cases. As for early postoperative complications, one patient had a cerebro-spinal fluid (CSF) fistula which required second operation along with a lumbar drainage, 30 % of the patients had transient difficulty of swallowing which resolved in 2-3 days, in 92 % of patients fusion was achived. No mortality was noted.

Conclusions: ACDF procedure is an effective treatment for cervical DDD. ACDF with bladed cages have higher fusion rates and less implant subsidence. Our study has favorable fusion results with acceptable complication rates.

Keywords: Cervical disc herniation, Anterior cervical discectomy and fusion, Polyetheretherketone cage, Outcome assesment

Level of Evidence: Retrospective clinical study, Level III

INTRODUCTION

Cervical DDD are commonly encountered during daily practice. Until 1950, posterior approaches were popular for cervical DDDs. However, on 1958, after Smith and Robinson introduced the technique of anterior cervical discectomy with autologous graft, anterior techniques were preferred generally over posterior techniques [3,13]. Nowadays, there are several options for cervical decompression for these cases such as ACDF, simple discectomy, cervical disc arthroplasty, ACDF with plating. Nonetheless, there has not been an established gold standard treatment for these patients. In some studies, simple discectomy was favored amongst other techniques, whereas some authors claimed better clinical and radiological

results with ACDF procedures which restore neural foramen height [2,9,16]. In general, simple discectomy is preferred for cases with soft and novel disc herniations, whereas, ACDF is favored for hard disc herniations with DDD. Nowadays, cages with blades and artificial grafts are being used instead of autologous grafts because of the shortened operating time, reduced complication rate along with an adequate fusion. It has been stated that cages with blades had favorable fusion outcomes without the need of plating in single level herniations [4]. Even though, the fusion methods had favorable outcomes, there has been some complications regarding the graft material, such as the loss of cervical alignment and implant subsidence. Fusion with plating was suggested in order to enhance fusion and avoid these complications, especially for multilevel disc herniations. But this technique also had its downfalls, such as, loosening and breakage of the screws, increased rate of postoperative dysphagia, especially with multilevel ACDF procedures [6,14]. Novel techniques, such as, ACDF with blade stand-alone PEEK cage has been described in the literature which enables adequate fusion without plating and its additional complications [10].

In this study, early results of ACDF with bladed PEEK cages were analyzed according to VAS scores, Odom's criteria and postoperative lordosis angle measurements.

MATERIALS AND METHODS

Patient Selection

Between May 2015 and March 2018, 83 patients with cervical DDD, had a single level or multi-level ACDF procedure with bladed PEEK cages using bioactive bone graft substitute (putty) at the Neurosurgical Department. We have retrospectively collected all of the patients' data.

Inclusion criterias were; having cervical DDD with radiculopathy or radiculomyelopathy, not being responsive to 6 weeks of conservative treatment or patients presented with neurogical deficits. Exclusion criterias were; previous cervical spine surgery, history of trauma or tumor. Informed consent was obtained from every patient.

Evaluation

As an outcome measure, VAS scores and Odom's criteria were used and radiological studies for each patient were analyzed retrospectively. Demographic data, postoperative surgery-related complications were noted.

VAS scores ranged from 1-10 measuring pain relief after the surgery. Each patient was asked to define a spesific score pre and postoperatively. Odom's criteria was graded as poor, fair, good, excellent, depending on the satisfactory results of the surgery.

Antero-posterior and lateral cervical x-ray and cervical magnetic resonance imaging (MRI), were performed on all patients preoperatively **(Figure-1).**

Evaluation of the implants and fusion were made with anteroposterior and lateral radiographs postoperatively **(Figure-2).**

Degenerative changes in the adjacent segments were evaluated with MRI during follow-up visits. Implant failure or subsidence was noted if existed.

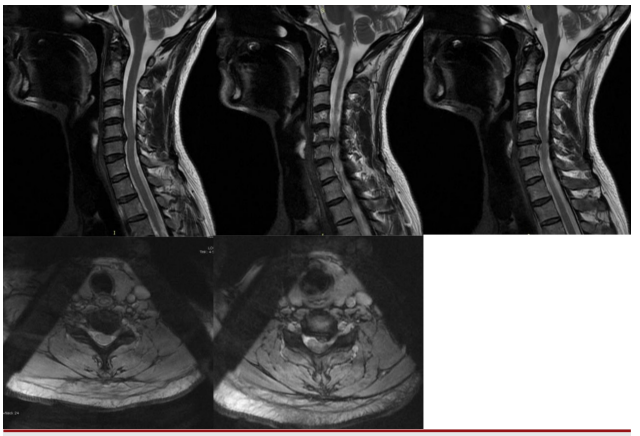

Figure-1. Preoperative T2-weighted sagittal-axial MRI revealing disc prolapse and spinal cord compression at the C5-C6 level.

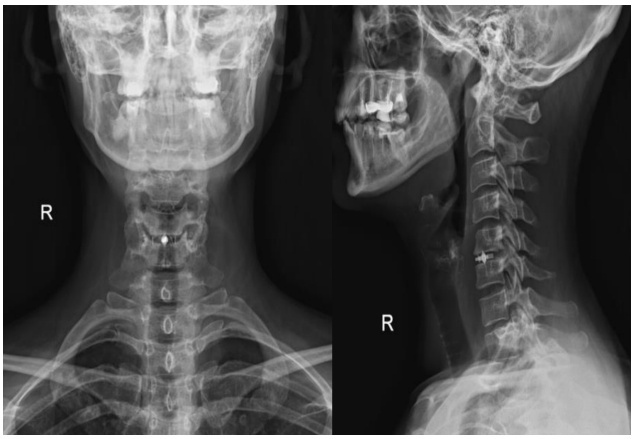

Figure-2. Postoperative antero-posterior and lateral plain X-ray at 12 months presenting the implant

Operative Technique

Under intratracheal general anesthesia in a supine position with the head slightly extended, the platysma was cut in a

standard fashion, and a blunt dissection was made to the anterior aspects of the cervical vertebrae. After verifying the vertebral level with fluoroscopic control, anterior cervical microdiscectomy was made under the operating microscope. The posterior longitudinal ligament was opened and the dura was seen. Both endplates were scratched out by curettes. In cases with hard disc herniations, posterior part of the inferior and superior corpus was drilled in each level. After measurement of the height and depth of the intervertebral space, an appropriate lordotic blade PEEK cage (LorX®, Tria Spine, Germany) was inserted into the intervertebral space with 1 mL demineralized bone matrix inside it and cage was locked to upper and lower vertebra by turning a screw 90 degree clockwise. With the aid of the fluoroscopic control, cage dimensions and proper cage localization was verified. After the hemostasis, wound was closed in a standard fashion. Neuromonitoring was used for the patients presented with myelopathy clinically or if spinal cord T2 hyperintensity changes were seen on MRI.

RESULTS

The mean age of the patients was 46.5 years (range, 25 to 74 years). The study included 47 (56.6 %) female and 36 (43.4 %) male patients. Radiculopathy was the leading symptom in this series. 76 patients were presented with radiculopathy (91.6 %), whereas, seven patients were presented with myelopathy (8.4 %). Interestingly, preoperative motor weakness of triceps muscle was noted in the C6-7 disc herniations, whereas in the other segments the incidence of motor weakness is low (C4-5, C5-6). The mean duration of symptoms was 6 weeks (between 1 week and 9 months). The mean follow-up time was 18 months.

72 % of the patients had soft disc herniation. C5-6 disc level was found to be the most common level amongst others (**Table-1**).

Table-1. Patients distrubation according to operated levels.

Operated Levels	Number
C3-4	1
C4-5	2
C5-6	30
C6-7	18
C4-5, C5-6	11
C5-6, C6-7	18
C4-5, C5-6, C6-7	3

One-level ACDF was performed on 51 of the patients, two-level ACDF was performed on 29 patients and three level ACDF was performed on 3 patients.

VAS scores were obtained on 1st and 3th month of the follow-up visits. VAS scores of 3th month follow-up controls, decreased in 81 patients (97.6 %) when compared with the preoperative VAS scores. The mean preoperative VAS score was found 8.7, whereas it was found 2.9 postoperatively. It was noted that these results were correlated with the final radiographic results. 95 % of the patients evaluated surgery's success as excellent according to Odom's criteria, 5 % of the patients rated the surgery's success as good. None of the patients had kyphotic or lordotic deformity on follow-up visits. On postoperative plain radiographs, there was no sign of implant failure or implant subsidence in any of the cases. Furthermore, follow-up MRI revealed that there was no serious progression of adjacent segment disease along with the adequate fusion in the fused levels in all of the patients.

As for early postoperative complications, one patient had CSF fistula which required second operation along with a lumbar drainage. 30 % of the patients had a transient difficulty in swallowing which resolved in 3 days' time. No wound infection and mortality was noted.

DISCUSSION

Nowadays, anterior cervical procedures differ as a means of technical approach (simple discectomy, anterior cervical discectomy + fusion with autologous graft (Cloward and Smith-Robinson technique) anterior cervical discectomy + fusion with cage, anterior cervical discectomy + disc arthroplasty with disc prosthesis, anterior cervical discectomy + fusion with plating with or without corpectomy etc.) and surgical indications.

Regarding anterior cervical procedures, most common topic under discussion is whether to perform fusion along with the anterior cervical discectomy. Simple discectomy without fusion has lots of advantages, in addition to its certain disadvantages. Advantages of simple discectomy includes, simplicity of the procedure, shortened time of surgery, less complication rates when compared to surgery with fusion techniques and cost-effectiveness of the procedure [5]. Disadvantages of simple discectomy are, postoperative segmental kyphosis, loss of cervical lordosis, alteration of cervical alignment and consequently axial neck pain [17]. Besides, Aydın et al, reported that it is advisable to preserve the disc material subtotally in order to maintain disc height, in their study of anterior contralateral cervical discectomy approach [1]. This approach may be an alternative for

simple discectomy procedure, especially for soft, lateral and paramedian located disc herniations.

There are some controversial studies showing different fusion rates after simple discectomy and discectomy with fusion. In a prospective study, same fusion rates were encoutered (approximately 40 %) when one level simple discectomy cases were compared to the cases of fusion + autologous graft w/o plating [12]. On the other hand, another study claims to have better fusion results after ACDF procedures [15]. Fraser et al, demonstrated the fusion rates to be 92.1 %, 79.9 %, and 65 % for one-level, two-level, and three-level ACDF, respectively, in a meta-analysis of 2682 patients [6]. In our study, fusion rates were consistent with the recent literature.

However, ACDF techniques, especially with plating, have their disadvantages like implant dislodgement, dysphagia and adjacent segment disease along with some important advantages like improved sagittal alignment and stability [15]. Most common complication after ACDF operation is dysphagia occurring almost in 21 % of patients after ACDF procedures [7]. In our study, dysphagia rates were similar when compared to recent literature (30 %). In all cases dysphagia resolved in one week.

Regarding all of these advantages and disadvantages of ACDF and simple discectomy techniques, anterior cervical discectomy + disc arthroplasty with disc prosthesis has become popular among surgeons [8,11]. Since cervical disc arthroplasty preserves motion better than ACDF procedures and prevents fusion related complications, it is advantageous amongst other procedures. Because of these reasons, patients may have early mobilization and gain early functional mobility.

REFERENCES

1. Aydın Y, Kaya RA, Can SM, Türkmenoğlu O, Çavuşoğlu H, Ziyal IM. Minimally invasive anterior contralateral approach for the treatment of cervical disc herniation. *Surg Neuro* 2005; 63(3): 210-219.
2. Bertalanffy H, Eggert HR. Complications of anterior cervical discectomy without fusion in 450 consecutive patients. *Acta Neurochir (Wien)* 1989; 99(1-2): 41-50.
3. Cloward RB. The anterior approach for removal of ruptured cervical disc. *J Neurosurg* 1958; 16: 602-607.
4. Dagli M, Er U, Şimşek S, Bavbek M. Late results of anterior cervical discectomy and fusion with interbody cages. *Asian Spine J* 2013; 7(1): 34–38.
5. Donaldson JW, Nelson PB. Anterior cervical discectomy without interbody fusion. *Surg Neurol* 2003; 57 (4): 219-224.
6. Fraser JF, Härtl R. Anterior approaches to fusion of the cervical spine: A meta-analysis of fusion rates. *J Neurosurg Spine* 2007; 6: 298–303.
7. Grasso G, Landi A. Long-term clinical and radiological outcomes following anterior cervical discectomy and fusion by zero-profile anchored cage. *J Craniovertebr Junction Spine* 2018; 9(2): 87–92.
8. Guinto F. CT demonstration of disk regression after conservative therapy. *Am J Neuroradiol* 1984; 5(5): 632-633.
9. Hirsch C. Cervical disc rupture: diagnosis and therapy. *Acta Orthop Scan* 1964; 30: 172-186.
10. Kapetanakis S, Thomaidis T, Charitoudis G, Pavlidis P, Theodosiadis P, Gkasdaris G. Single anterior cervical discectomy and fusion (ACDF) using self- locking stand-alone polyetheretherketone (PEEK) cage: evaluation of pain and health-related quality of life. *J Spine Surg* 2017; 3: 312-322.
11. Komori H, Okawa A, Haro H, Muneta T, Tamamoto H, Shinomiya K. Contrast-enhanced magnetic resonance imaging in conservative management of lumbar disc herniation. *Spine* 1998; 23(1): 67-73.
12. Savolainen S, Rinne J, Hernesniemi J. A prospective randomized study of anterior single-level cervical disc operations with long-term follow-up: surgical fusion is unnecessary. *Neurosurgery* 1998; 43(1): 51-55.
13. Smith GW, Robinson RA. The treatment of certain spine disorders by anterior removal of the intervertebral disc and interbody fusion. *J Bone Joint Surg Am* 1958; 40-A: 624-662.
14. Song KJ, Taghavi CE, Lee KB, Song JH, Eun JP. The efficacy of plate construct augmentation versus cage alone in anterior cervical fusion. *Spine* 2009; 34: 2886-2892.
15. Song KJ, Choi BW, Jeon TS, Lee KB, Chang H. Adjacent segment degenerative disease: Is it due to disease progression or a fusion-associated phenomenon. Comparison between segments adjacent to the fused and non-fused segments? *Eur Spine J* 2011; 20: 1940–1945.
16. Thorell W, Cooper J, Hellbusch L, Leibrock L. The long term outcome of patients undergoing anterior cervical discectomy with and without intervertebral bone graft placement. *Neurosurgery* 1998; 43: 268-273.
17. White BD, Fitzgerald JJ. To graft or not to graft: rationalizing choice in anterior cervical discectomy. *British J Neurosurg* 2005; 19(2): 148-154.