Diagn Interv Radiol 2017; 23:390–397
© Turkish Society of Radiology 2017

NEURORADIOLOGY
ORIGINAL ARTICLE

A combined VBM and DTI study of schizophrenia: bilateral decreased insula volume and cerebral white matter disintegrity corresponding to subinsular white matter projections unlinked to clinical symptomatology

Aslıhan Onay*
Hale Yapıcı Eser*
Çiğdem Ulaşoğlu-Yıldız
Selçuk Aslan
Erhan Turgut Talı

PURPOSE
Grey matter and white matter changes within the brain are well defined in schizophrenia. However, most studies focused on either grey matter changes or white matter integrity separately; only in limited number of studies these changes were interpreted in the same frame. In addition, the relationship of these findings with clinical variables is not clearly established. Here, we aimed to investigate the grey matter and white matter changes in schizophrenia patients and exhibit the relation of these imaging findings with clinical variables.

METHODS
A total of 20 schizophrenia patients and 16 matched healthy controls underwent magnetic resonance imaging to investigate the grey matter and white matter alterations that occur in schizophrenia patients using voxel-based morphometry (VBM) and whole brain voxel-wise analysis of diffusion tensor imaging (DTI) parameters with SPM8, respectively. While the preprocessing steps of VBM were performed with the default parameters of VBM8 toolbox, the preprocessing steps of DTI were carried out using FSL. Additionally, VBM results were correlated with clinical variables.

RESULTS
Bilateral insula showed decreased grey matter volume in schizophrenia patients compared with healthy controls ($P < 0.01$). The opposite contrast did not show a significant difference. Psychiatric scores, duration of illness, and age were not correlated with the decreased grey matter volume of insula in schizophrenia patients. DTI analysis revealed a significant increase in mean, radial, and axial diffusivity, mainly of the fibers of bilateral anterior thalamic radiation and superior longitudinal fasciculus with left predominance, which intersected with bilateral subinsular white matter ($P < 0.05$).

CONCLUSION
Our findings suggest that insula may be the main affected brain region in schizophrenia, which is also well supported by the literature. Our results were independent of disease duration and schizophrenia symptoms. White matter alterations were observed within bilateral anterior thalamic radiation and superior longitudinal fasciculus that intersects with subinsular white matter. Studies with larger sample sizes and more detailed clinical assessments are required to understand the function of insula in the neurobiology of schizophrenia.

From the Departments of Radiology (A.O. ✉ *aslionay@gmail.com, aslionay@kuh.ku.edu.tr)* and Psychiatry (H.Y.E.), Koç University School of Medicine, İstanbul, Turkey; Hulusi Behçet Life Sciences Research Center (Ç.U.Y.), İstanbul University İstanbul School of Medicine, İstanbul, Turkey; the Departments of Psychiatry (S.A.) and Radiology (E.T.T.), Gazi University School of Medicine, Ankara, Turkey.

*These authors contributed equally to this study.

Received 6 November 2016; revision requested 18 January 2017; last revision received 26 February 2017; accepted 7 April 2017.

DOI 10.5152/dir.2017.16519

Schizophrenia is a chronic disorder with abnormalities in perception, thinking, and behavior and presentation of negative symptoms (1). Though there have been many advances in the treatment of schizophrenia, it is still difficult to achieve recovery and current treatments may only alleviate some of the symptoms of schizophrenia, instead of treating the underlying pathology (2). Schizophrenia patients are heterogeneous in their clinical findings and a well-defined, common pathology was not elucidated to allow for identification of curative treatments.

The neuroimaging studies about the neurobiology of schizophrenia have focused on brain connectivity, brain function, and changes in grey matter volumes (3). Meta-analysis of imaging studies suggest that the bilateral insula, thalamus, dorsolateral prefrontal cortex, medial frontal gyrus and posterior cingulate gyrus, superior temporal cortex,

You may cite this article as: Onay A, Yapıcı Eser H, Ulaşoğlu-Yıldız Ç, Aslan S, Talı ET. A combined VBM and DTI study of schizophrenia: bilateral decreased insula volume and cerebral white matter disintegrity corresponding to subinsular white matter projections unlinked to clinical symptomatology. Diagn Interv Radiol 2017; 23:390–397.

bilateral hippocampal–amygdala region, middle frontal and left medial temporal lobe show decreased grey matter volumes in schizophrenia (2, 4, 5). Decreased volume in each region may be related to a different clinical presentation of schizophrenia. Some studies showed that superior temporal lobe changes were correlated with formal thought disorders (6), hallucinations, and the duration and type of antipsychotic treatment (7), while left prefrontal cortex volume was correlated with functioning (8).

On the other hand, schizophrenia patients may also show white matter disintegrity even in very early stages (9), and some of these white matter changes were also reported to correlate with clinical measures as neurocognitive symptoms and negative symptoms (10, 11). However, white matter analysis showed that multiple circuits were involved in the disorder (12), and they may be related to different phenotypes of the disorder or converging functions of these circuits.

Because of different hypotheses, methods, and regions of interest used in the studies, the results have not always been reproducible. Therefore, it is important to accumulate new evidence from different patient groups and study the clinical correlates of the observed volumetric differences.

In this study, we aimed to present our imaging findings of 20 schizophrenia patients and 16 matched healthy participants and study the correlation of grey matter volume differences with clinical variables.

Methods

Participants

Participants were selected from inpatients and outpatients that were treated at the Department of Psychiatry. Our local ethics committee approved the study. Patients who accepted a magnetic resonance imaging (MRI) scan and signed a written informed consent were included in the study. For inpatients, a family member also contributed to the consent of the patient.

We matched 16 healthy controls for education, gender, marital status, work status, and handedness with 20 schizophrenia patients whose diagnoses were given based on DSM-IV criteria.

For schizophrenia patients, study inclusion criteria were schizophrenia diagnosis according to DSM-IV criteria; duration of illness for >1 year; lack of substance abuse history. Study exclusion criteria were age below 18 years, any additional axis I or II diagnosis, history of a complicated medical disorder or any neurologic disorder including history of head trauma that might result in cognitive dysfunction or grey matter loss. Clinical assessment of schizophrenia patients included the scale for the assessment of positive symptoms (SAPS), scale for the assessment of negative symptoms (SANS), brief psychiatric rating scale (BPRS), and global assessment of functioning (GAF) scores. These tests were either extracted from concurrent hospital registry data or were performed as part of physician evaluations at the day of imaging. Additional information was gathered through the hospital's registry database. All patients were on neuroleptic treatment (5 of them were using clozapine) and they had illness duration more than 1 year.

Healthy controls were chosen from a community sample after a face-to-face structured interview with H.Y.E. interviewers who were not diagnosed with any psychiatric disorders and did not have any first-degree relatives with any psychiatric disease were chosen as controls.

Sociodemographic variables of patients and controls are given in Table 1.

Structural MRI

All subjects were scanned with 1.5 T GE Signa MRI scanner and 8-channel phase array coil. The examination protocol included volumetric scans and diffusion tensor imaging (DTI). The imaging parameters of DTI were as follows: single shot EPI sequence, TR, 100000 ms; TE, 104.6 ms; flip angle, 90; FOV, 100 cm; slice thickness, 4 mm; number of direction, 25. Volumetric scans were obtained using a three-dimensional volumetric spoiled gradient recalled-echo sequence in sagittal plane with the following parameters: TE, 5.448 ms; TR, 12.392 ms; flip angle, 20; matrix size, 256×160 mm; FOV, 80 cm; voxel size: 1.0×1.0×1.0 mm; slice thickness, 1.0 mm. Volumetric scans were oriented perpendicular to the anterior posterior commissure line.

Analysis of grey matter volume

Image preprocessing was performed by VBM8 using SPM 8 (SPM; Wellcome Department of Cognitive Neurology; www.fil.ion.ucl.ac.uk) running on MATLAB 13 (www.

Main points

- We aimed to determine grey matter and white matter changes in schizophrenia patients and exhibit the relation of these imaging findings with clinical variables.
- Grey matter changes were analyzed by voxel-based morphometry and white matter alterations were tested by diffusion tensor imaging.
- We found decreased grey matter volume only in bilateral insula, but it had no correlation with clinical variables.
- White matter alterations were observed within bilateral anterior thalamic radiation and superior longitudinal fasciculus that intersects with subinsular white matter.
- We suggest that insula might be the main affected brain region in schizophrenia.

Table 1. Demographics and clinical characteristics of the study populations

	Schizophrenia patients n=20	Healthy controls n=16	*P*
Age, years	36.5±10.5	34.4±9.1	0.39
Gender (F/M), n	10/10	9/7	0.75
Education, years	10.7±3.5	11.3±3.3	0.79
SANS (n=19)	20.1±13.4 (5–46)		
SAPS (n=19)	38.2±22.5 (8–86)		
BPRS (n=19)	24±12.2 (9–62)		
GAF (n=18)	61.4±11.7 (40–75)		
Age at disorder onset (n=16), years	25.2±7.2 (14–37)		
Duration at illness (n=16), years	10.7±8.9 (1–32)		

Data are presented as mean ± standard deviation (range).
F/M, female/male; SANS, scale for the assessment of negative symptoms; SAPS, scale for the assessment of positive symptoms; BPRS, brief psychiatric rating scale; GAF, global assessment of functioning.

mathworks.com). Files that were originally in DICOM format were converted to analyze format. All of the naive T1-weighted images were manually reorientated by setting the coordinate origin of each image on anterior commissure. The default parameters of VBM8 toolbox were used for preprocessing steps. Briefly, the T1-weighted images were bias-corrected and a spatially adaptive non-local means filter was used to eliminate MRI inhomogeneities and avoid noise, respectively. A classical Markov random field model was performed as a spatial constraint in order to provide further improvement in signal-to-noise ratio. Registration into standard MNI space comprised a linear affine transformation and nonlinear deformation using high dimensional DARTEL normalization. Non-brain tissues were stripped off and brain tissue were segmented into grey matter, white matter, and cerebrospinal fluid. Afterwards, segmented grey matter and white matter images were multiplied by the nonlinear components that were derived from normalization matrix. Eventually, modulated grey matter and white matter images were generated to calculate the actual grey matter and white matter volumes. Normalization quality of the unsegmented, normalized images was visually inspected. We calculated the covariance between normalized segmented images to identify any outliers for artifacts or preprocessing errors. Modulated and segmented images were spatially smoothed by using a Gaussian kernel filter set at 8 mm full with half maximum (FWHM). An absolute threshold masking value of 0.3 was selected for grey matter volumes. Regions with significant grey matter volume differences between schizophrenia patients and controls were tested using two-sample t-test in SPM8 based on a voxel-level and cluster-level height threshold of $P < 0.05$ (FWE-corrected).

Regions-of-interest (ROIs) of clusters that showed a significant group difference were extracted using MarsBar 0.41 (http://marsbar.sourceforge.net/) and mean grey matter volumes of the significant ROI was calculated for each patient using log_roi_batch v2.0 function in Matlab (http://www.aimfeld.ch).

Diffusion tensor imaging

The preprocessing of DTI data was performed by FSL (version 5.0.6), the FMRIB Software Library (http://fsl.fmrib.ox.ac.uk/fsl) (Smith et al., 2004). Firstly, diffusion-weighted data were corrected for motion and eddy current artifacts by using FMRIB's diffusion toolbox. Then, brain extraction tool was used to extract images for removing non-brain tissue and for each subject a binary brain mask was created. Next, a diffusion tensor model was fitted in each voxel and diagonal elements (λ_1, λ_2, λ_3), fractional anisotropy (FA) and mean diffusivity (MD) images were generated using FSL's DTIFIT. Axial diffusivity (AD) maps were created from λ_1 and radial diffusivity (RD) maps were calculated with $\lambda_{23} = (\lambda_2 + \lambda_3)/2$. All subjects' maps were aligned to FMRIB58-FA template in Montreal Neurological Institute (MNI) 152 standard space and re-sampled to a spatial resolution 1×1×1 mm^3 using FMRIB's nonlinear registration tool FNIRT. In the same manner, the transformations were applied to the AD, MD, and RD maps for each subject. Finally, the quality of the normalized images was checked by visual inspection.

Table 2. Results of whole-brain voxel-wise group comparison of grey volume (schizophrenia patients < healthy controls)

Grey matter region	Cluster size (voxel)	MNI peak coordinates			T	Z	$P_{FWE\text{-}corrected}$
		x	y	z			
Right insula	111	39	12	0	6.15	5.01	0.001
Left insula	26	-45	3	1	5.91	4.87	0.009

MNI, Montreal neurological institute; FWE, family-wise error.

Statistical analysis

Statistical analysis was performed using SPSS (IBM SPSS Statistics for Windows, version 21.0, IBM Corp.). Nonparametric t-test or chi-square test was used in comparing demographical differences between groups for continuous variables and categorical variables, respectively.

Correlation analysis of behavioral and grey matter ROI data was performed as follows. First, data were examined for normality with visual histograms and both the Kolmogorov-Smirnov and Shapiro-Wilk tests. Correlation coefficients were calculated to assess bivariate associations between individual mean volume of the ROIs and clinical variables such as age, duration of illness, SAPS, SANS, BPRS, and GAF scores using Pearson correlation test for normally distributed data, and Spearman's rank-order correlation test for non-normally distributed data. P values smaller than 0.004 were considered significant using Bonferroni adjusted alpha level of 0.05/12 = 0.004 for multiple comparisons.

Whole-brain voxel-wise analysis of whole brain white matter integrity was performed using statistical parametric mapping (SPM 8) software (http://www.fil.ion.ucl.ac.uk/spm). A Gaussian kernel of 8 mm FWHM was used to smooth the FA, AD, MD, and RD maps. In order to eliminate voxels of grey matter and cerebrospinal fluid, a group-averaged map was created from normalized but unsmoothed FA maps of each subject and then binarized using a cutoff value of 0.2. In this way, only voxels surviving this threshold were included in the group analyses. The significance of the differences between the schizophrenia patients and healthy controls were calculated by applying general linear models to FA, AD, MD, and RD maps, separately using a voxel-wise height threshold of P value less than 0.0005 combined with a cluster-level family-wise error (FWE) correction for multiple comparisons.

Results

Schizophrenia patients demonstrated decreased grey matter volume only in bilateral insula (Table 2, Fig. 1). VBM analysis revealed right insula predominance in grey matter decrease at cluster forming height threshold FWE-corrected $P < 0.05$ combined with a cluster-level FWE correction. In whole-brain comparisons, larger decreases were observed in grey matter volume of right insula (cluster-level FWE-corrected $P = 0.001$; cluster size: 111 voxels, MNI peak coordinates: 39 12 0) compared with left insula (cluster-level FWE-corrected $P = 0.009$; cluster size: 26 voxels, MNI peak coordinates: -45 3 1). In contrast, healthy control subjects did not have any grey matter regions with a decreased volume compared with schizophrenia patients.

None of the clinical variables (SANS, SAPS, BPRS, and GAF scores, age, and duration of illness) were significantly correlated with grey matter volume of insula in patients diagnosed with schizophrenia ($P > 0.004$; Table 3 and Fig. 1). did not analyze the as-

Table 3. Correlation analyses between clinical variables and insula grey volume in patients with schizophrenia

	Area showing decreased grey matter volume			
	Left insula		Right insula	
Clinical variable	*r*	*P*	*r*	*P*
SANS (n=19)	$r_s = 0.352$	0.139	$r_s = 0.198$	0.417
SAPS (n=19)	$r = -0.044$	0.857	$r = -0.210$	0.387
BPRS (n=19)	$r_s = 0.023$	0.926	$r_s = 0.182$	0.455
GAF (n=18)	$r_s = 0.089$	0.726	$r_s = 0.140$	0.579
Duration of illness (n=16)	$r = -0.427$	0.099	$r = -0.329$	0.213
Age (n=20)	$r = -0.262$	0.264	$r = 0.071$	0.766

Bonferroni-adjusted alpha level: $P < 0.004$ (0.05/12).
r, Pearson correlation coefficient, r_s, Spearman's rank correlation coefficient; SANS, scale for the assessment of negative symptoms; SAPS, scale for the assessment of positive symptoms; BPRS, brief psychiatric rating scale; GAF, global assessment of functioning.

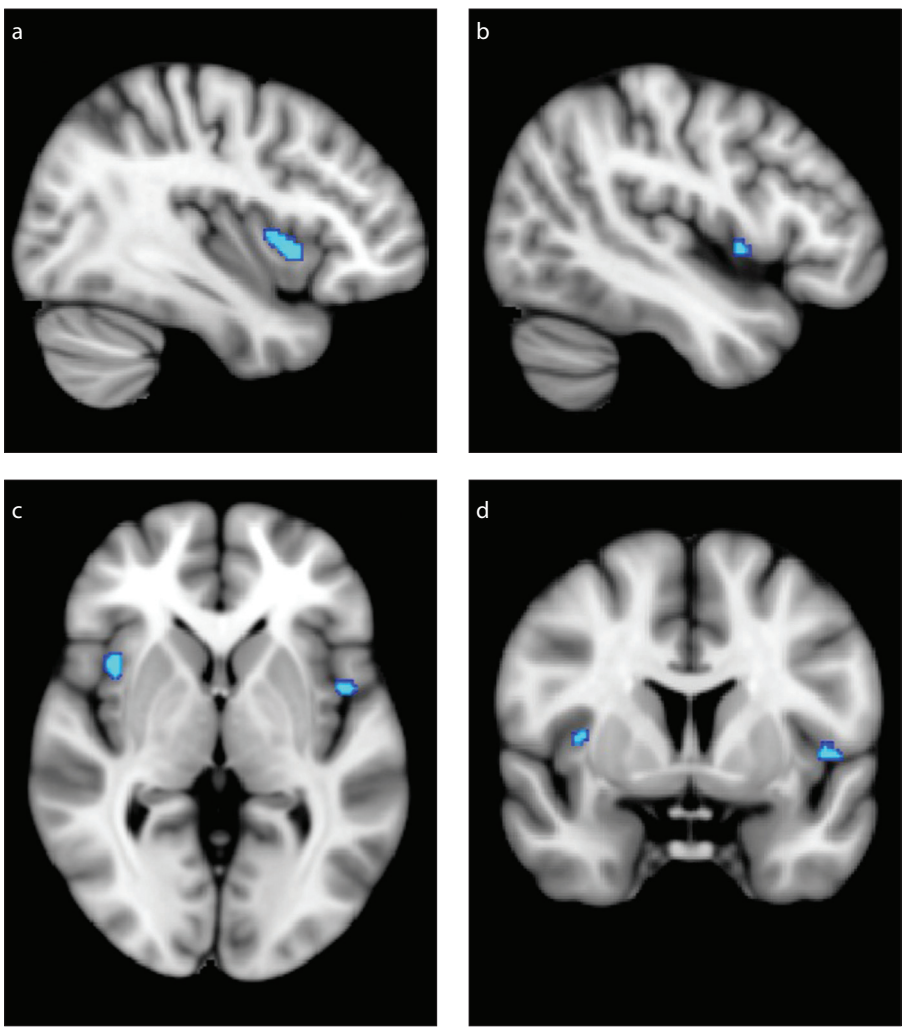

Figure 1. a–d. Voxel-wise group comparison of grey matter: right sagittal **(a)**, left sagittal **(b)**, axial **(c)**, and coronal **(d)** images show decreased grey matter volume in patients with schizophrenia in right (height threshold FWE-corrected, $P < 0.05$; cluster level FWE-corrected, $P = 0.001$; MNI peak coordinate, 39 12 0; cluster size, 111 voxels) and left insula (height threshold FWE-corrected, $P < 0.05$; cluster level FWE-corrected, $P = 0.009$; MNI peak coordinate, -45 3 1; cluster size, 26 voxels). Clusters are superimposed on the MNI 152 T1 (1 mm) template image.

sociation of subtypes of schizophrenia with the grey matter measurements because of the small sample size.

FA values were not significantly different between schizophrenia patients and healthy controls. However, in whole-brain comparisons, the SPM two-sample t-test revealed that patients with schizophrenia displayed increased AD in left superior longitudinal fasciculi (t=4.56, $P = 0.016$; Fig. 2), increased MD in bilateral superior longitudinal fasciculus with left predominance and bilateral anterior thalamic radiation (cluster in left hemisphere: t=5.81, $P < 0.001$; cluster in right hemisphere: t=5.03, $P = 0.006$; Fig. 3), and increased RD in left anterior thalamic radiation (t=4.63, $P = 0.027$; Fig. 4) compared with healthy subjects (Table 4). The localizations of significant white matter differences corresponded to bilateral anterior thalamic radiation and superior longitudinal fasciculus, which intersected with bilateral subinsular white matter (Fig. 5).

Discussion

Our study showed that schizophrenia patients have decreased grey matter volume in bilateral insula. Besides its role in addiction, insula has been recently found to be related to impulsivity, interceptive awareness (13), cognition (14), and emotion regulation (15). Studies with larger samples showed that depression w associated with bilaterally decreased insula volumes (16). In our study, insula volume was found decreased bilaterally in patients with schizophrenia compared with normal controls, consistent with other reports (2, 17, 18). Decreased insula volumes were reported even in first episode schizophrenia cases (19–21).

We found that decreased insula volume was not associated with total positive and negative symptom scores, disease duration or functionality. However, we did not measure the insight or quality of life. Keeping in mind that our study did not have measures for mood and functionality symptoms, it may be concluded that grey matter decrease in insula may be the main pathology in schizophrenia patients independent of the clinical presentation. In previous studies, decreased insula volume was found to be associated with poor functional outcome (7), somatic delusions (22), severity of auditory hallucinations (23), reduced insight of the illness (24), and quality of life (25). However, reduced insular volume was also reported to differentiate schizophrenia

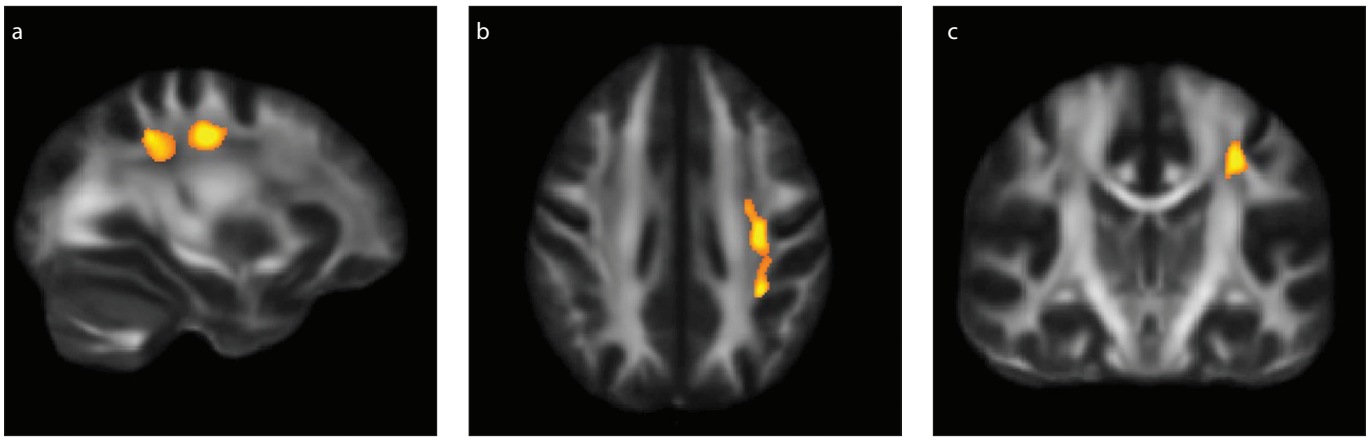

Figure 2. a–c. Voxel-wise group comparison of axial diffusivity (AD): left sagittal **(a)**, axial **(b)**, and coronal **(c)** images show increased AD (height threshold uncorrected, $P < 0.0005$; cluster level FWE-corrected, $P = 0.002$) in patients with schizophrenia within left superior longitudinal fasciculus. Clusters are superimposed on the FMRIB58_FA (1 mm) image (MNI peak coordinate, -30 -20 40; cluster size, 1749 voxels).

Table 4. Results of whole-brain voxel-wise group comparison of axial, mean, and radial diffusivity (schizophrenia patients > healthy controls)

DTI measurement	Cluster size (voxel)	MNI peak coordinates	White matter tract*	T_{max}	$P_{FWE\text{-}corrected}$
Axial diffusivity	1749	-30 -20 40	Left SLF	4.56	0.016
		-31 -40 40	Left SLF		
		-26 -10 43	Left SLF		
Mean diffusivity cluster-1	2428	30 -15 15	Left SLF	5.03	0.006
		11 -11 -3	Right ATR		
		11 -9 7	Right ATR		
		35 -4 10	Right SLF		
		24 -14 14	Right CST		
		31 -22 24	Right SLF		
		28 -12 23	Right CST		
Mean diffusivity cluster-2	12474	-26 -14 18	Left CST	5.81	<0.001
		-29 -8 15	Left SLF		
		-17 -9 10	Left ATR		
		-30 -18 36	Left SLF		
		-10 -6 9	Left ATR		
		-24 -25 43	Left CST		
		-10 -14 0	Left ATR		
		-15 -20 5	Left ATR		
		-39 -7 41	Left SLF		
Radial diffusivity	1466	-10 -6 6	Left ATR	4.63	0.027

DTI, diffusion tensor imaging; MNI, Montreal neurological institute; FWE, family-wise error; SLF, superior longitudinal fasciculus; ATR, anterior thalamic radiation; CST, corticospinal tract.
*Based on JHU white-matter tractography atlas.

patients from their healthy relatives (26), and it was even present in first episode psychosis (27). Decreased right anterior insula volume in schizophrenia patients was also shown to be independent of ethnicity and duration of illness, positive and negative scores and antipsychotic treatments (28). In our patient sample this result has been replicated. Though we have a very small sample size to generalize our results, our suggestion that decreased insula volume could be the main pathology in schizophrenia patients was supported by Lee et al. (29) who showed that antipsychotic-naive first episode schizophrenia patients have decreased bilateral insula volume and this decrease was progressive during the course of the disorder (29).

In our study, we showed that white matter adjacent to insula was disrupted in schizophrenia patients. Although there are a number of published articles on white matter disintegrity, to our knowledge most studies focused on a specific region-of-interest based on their hypothesis and it was not commonly replicated. In addition, most of the studies applied VBM and DTI analysis separately. In this study, we found that patients diagnosed with schizophrenia had increased AD, MD, and RD values corresponding to left and right superior longitudinal fasciculus and anterior thalamic radiation. By combining VBM and DTI techniques, we showed the correspondence of altered white matter tracts to subinsular white matter bilaterally.

Most of the DTI studies focused on FA values conducting voxel-based analysis of FA only (30, 31). In whole brain analysis studies, even early cases of schizophrenia showed bilaterally decreased FA values, which may be associated with illness duration (32, 33). In addition to this, a meta-analysis which combined findings from 15 DTI studies reported two main regions in schizophrenia patients: left frontal and temporal white matter including anterior thalamic radiation (33). However, FA is not the only value that shows the decreased white matter integrity; three other measures of MD, AD, and RD both give a different estimate of the underlying molecular pathology. Though FA decrease and MD increase may be correlated (27), MD val-

ue differences could be observed in schizophrenia patients even in the absence of volumetric abnormalities in grey matter (35). Increase in MD value in the insula has also been reported (36, 37). In addition, these parameters are not always correlated with each other (38). In our study, non-FA measures of DTI showed consistently increased values in the overlapping regions compared with controls, which suggested a consistent white matter disintegrity.

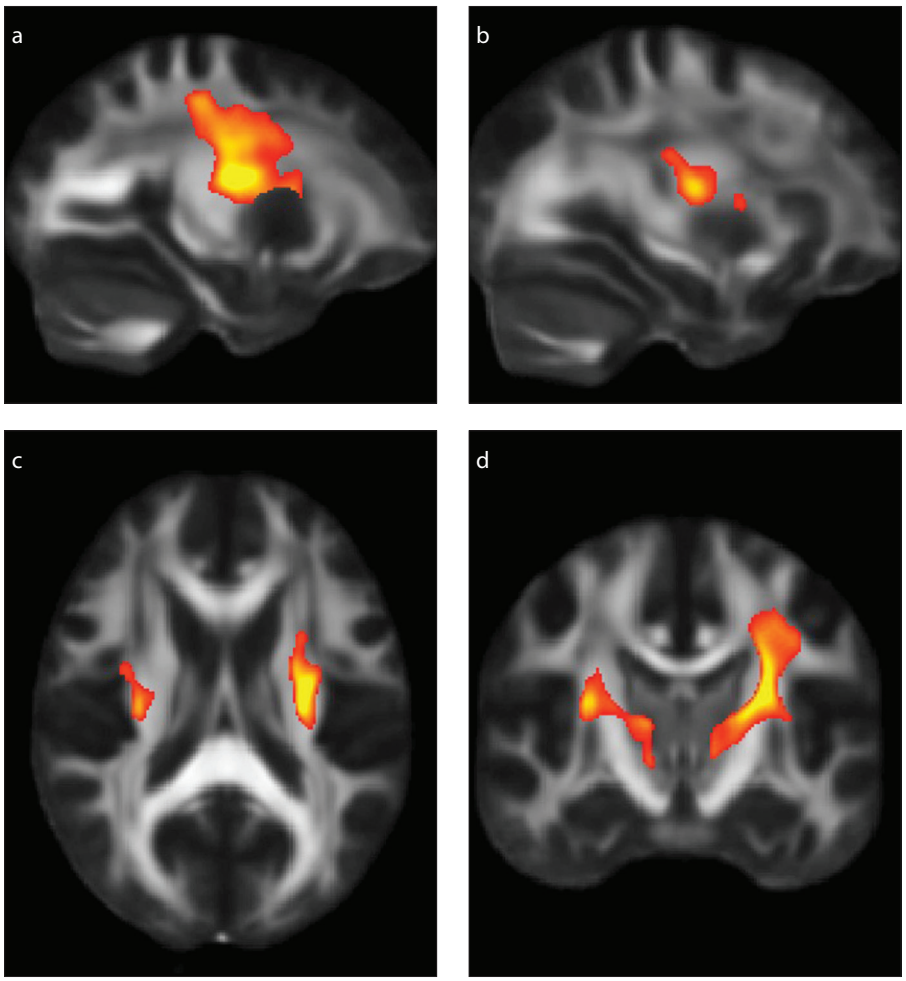

Figure 3. a–d. Voxel-wise group comparison of mean diffusivity (MD): right sagittal **(a)**, left sagittal **(b)**, axial **(c)**, and coronal **(d)** images show increased MD (height threshold uncorrected, $P < 0.0005$; cluster level FWE-corrected, $P < 0.001$) in patients with schizophrenia within left and right subinsular white matter. Clusters are superimposed on the FMRIB58_FA (1 mm) image (MNI peak coordinate, -26 -14 18; cluster size, 12474 voxels and MNI peak coordinate, 30 -15 15; cluster size, 2428 voxels, respectively).

The results of our study showed increased MD values within bilateral anterior thalamic radiation and superior longitudinal fasciculus, in addition to greater RD values within the left anterior temporal lobe and greater AD within the left superior longitudinal fasciculus. Anterior thalamic radiation provides connection between mediodorsal thalamic nuclei and the frontal cortex, as well as connection between anterior thalamic nuclei and the anterior cingulate cortices (39). It has a role in memory encoding and executive functioning (40). On the other hand, superior longitudinal fasciculus is the main white matter tract that connects frontal-parietal regions. Recently, reduced integrity in anterior thalamic radiation and superior longitudinal fasciculus has been reported (41–45). Besides, a correlation has been found between negative symptoms, cognitive impairment, and white matter disintegrity within these white matter tracts (46, 47). Thus, in accordance with the previous literature, our results point to disintegrity within cortico-striato-thalamic circuit in schizophrenia.

Although the results of our study are in agreement with the literature and there are some limitations. First, although the patients were strictly matched with healthy controls for age, gender, educational status and dominant hand, our study has a relatively small sample size that may have introduced type II error in correlation analyses between insular grey matter volume

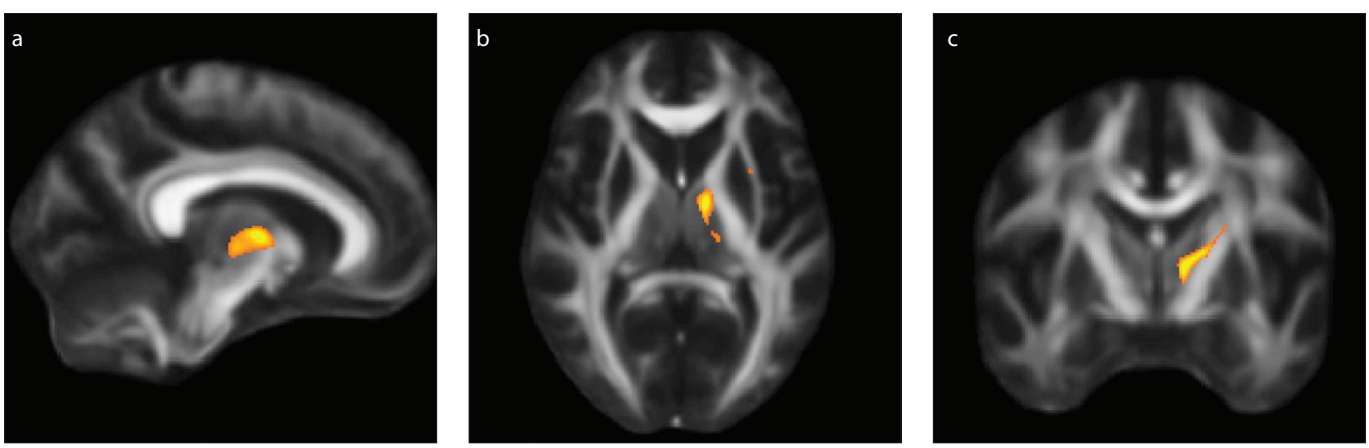

Figure 4. a–c. Voxel-wise group comparison of radial diffusivity (RD): left sagittal **(a)**, axial **(b)**, and coronal **(c)** images show increased RD (height threshold uncorrected, $P < 0.0005$; cluster level FWE-corrected, $P = 0.027$) in patients with schizophrenia in left anterior thalamic radiation. Clusters are superimposed on the FMRIB58_FA (1 mm) image (MNI peak coordinate, -10 -6 6; cluster size, 1466 voxels).

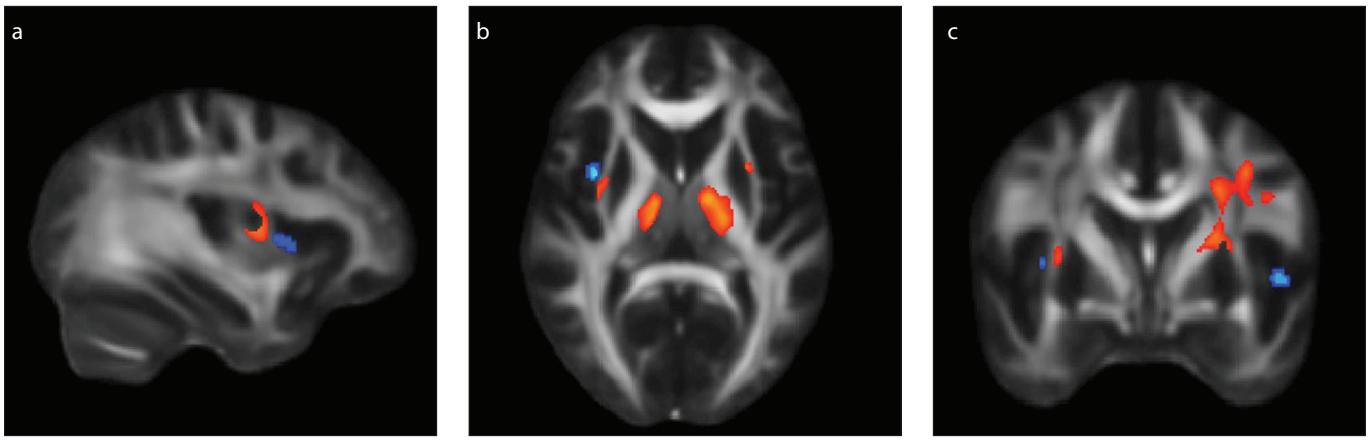

Figure 5. a–c. Significant grey matter and white matter MD differences were superimposed on the FMRIB58_FA (1 mm) image. Areas in blue color indicate significantly decreased grey matter volume, while hot colors indicate significantly increased MD in white matter of bilateral anterior thalamic radiation and superior longitudinal fasciculus in schizophrenia compared with healthy controls. It should be noted that the localizations of significant white matter differences intersect with bilateral subinsular white matter.

and clinical analyses. Second, since we included schizophrenia patients diagnosed >1 year ago they have been on antipsychotic treatment and we could not rule out medication effect on the observed grey matter differences. Nevertheless, our results of decreased grey matter volume in bilateral insula may be independent from antipsychotic treatment since a recent study with a small sample size showed that use of antipsychotics may increase bilateral insula volume. Third, we did not assess anxiety and depressive symptoms in the patient group; therefore we could not distinguish the effect of these symptoms on the neuropathology of the disease. Lastly in VBM analysis, morphology of insula was assessed as a whole but its various subdimensions may also be analyzed separately.

In conclusion, based on the findings of this study, we suggest that insula may be the main affected brain region in schizophrenia. The role of the insula in pathophysiology of schizophrenia, its functional connectivity with other brain regions, in addition to time-dependent volumetric changes should be further investigated in studies with larger number of patients with schizophrenia.

Acknowledgements

We thank all participants and their families for participating in our study.

Conflict of interest disclosure

The authors declared no conflicts of interest.

References

1. American Psychiatric Association, 2013. Diagnostic and statistical manual of mental disorders (DSM-5®). American Psychiatric Pub.
2. Ellison-Wright I, Bullmore E. Anatomy of bipolar and schizophrenia: a meta-analysis. Schizophr Res 2010; 117:1–12.
3. Insel TR. Rethinking schizophrenia. Nature 2010; 468:187–193.
4. Glahn DC, Laird AR, Ellison-Wright I, et al. Meta-analysis of gray matter anomalies in schizophrenia: application of anatomic likelihood estimation and network analysis. Biol psychiatry 2008; 64:774–781.
5. Honea R, Crow TJ, Passingham D, Mackay CE. Regional deficits in brain volume in schizophrenia: a meta-analysis of voxel-based morphometry studies. Am J Psychiatry 2005; 162:2233–2245.
6. Horn H, Federspiel A, Wirth M, et al. Gray matter volume differences specific to formal thought disorder in schizophrenia. Psychiatry Res 2010; 182:183–186.
7. McClure RK, Phillips I, Jazayerli R, Barnett A, Coppola R, Weinberger DR. Regional change in brain morphometry in schizophrenia associated with antipsychotic treatment. Psychiatry Res 2006; 148:121–132.
8. Kasparek T, Prikryl R, Schwarz D, et al. Gray matter morphology and the level of functioning in one-year follow-up of first-episode schizophrenia patients. Prog Neuropsychopharmacol Biol Psychiatry 2009; 33:1438–1446.
9. Samartzis L, Dima D, Fusar-Poli P, Kyriakopoulos M. White matter alterations in early stages of schizophrenia: a systematic review of diffusion tensor imaging studies. J Neuroimaging 2014; 24:101–110.
10. Roalf DR, Gur RE, Verma R, et al. White matter microstructure in schizophrenia: associations to neurocognition and clinical symptomatology. Schizophr Res 2015; 161:42–49.
11. Viher PV, Stegmayer K, Giezendanner S, et al. Cerebral white matter structure is associated with DSM-5 schizophrenia symptom dimensions. Neuroimage Clin 2016; 12:93–99.
12. Wheeler AL, Voineskos AN. A review of structural neuroimaging in schizophrenia: from connectivity to connectomics. Front Hum Neurosci 2014; 8:653.
13. Avery JA, Drevets WC, Moseman SE, Bodurka J, Barcalow JC, Simmons WK. Major depressive disorder is associated with abnormal interoceptive activity and functional connectivity in the insula. Biol Psychiatry 2014; 76:258–266.
14. Gasquoine PG. Contributions of the insula to cognition and emotion. Neuropsychol Rev 2014; 24:77–87.
15. Song Z, Zhang M, Huang P. Aberrant emotion networks in early major depressive disorder patients: an eigenvector centrality mapping study. Transl Psychiatry 2016; 6:819.
16. Wise T, Radua J, Via E, et al. Common and distinct patterns of grey-matter volume alteration in major depression and bipolar disorder: evidence from voxel-based meta-analysis. Mol Psychiatry 2016 [Epub ahead of print].
17. Sliz D, Hayley S. Major depressive disorder and alterations in insular cortical activity: a review of current functional magnetic imaging research. Front Hum Neurosci 2012; 6:323.
18. Yu K, Cheung C, Leung M, Li Q, Chua S, McAlonan G. Are bipolar disorder and schizophrenia neuroanatomically distinct? An anatomical likelihood meta-analysis. Front Hum Neurosci 2010; 4:189.
19. Meisenzahl EM, Koutsouleris N, Bottlender R, et al. Structural brain alterations at different stages of schizophrenia: a voxel-based morphometric study. Schizophr Res 2008; 104:44–60.
20. Nakamura K, Takahashi T, Nemoto K, et al. Gray matter changes in subjects at high risk for developing psychosis and first-episode schizophrenia: a voxel-based structural MRI study. Front Psychiatry 2013; 18:4–16.
21. Molina V, Sanz, J, Villa R, et al. Voxel-based morphometry comparison between first episodes of psychosis with and without evolution to schizophrenia. Psychiatry Res 2010; 181:204–210.
22. Spalletta G, Piras F, Rubino IA, Caltagirone C, Fagioli S. Fronto-thalamic volumetry markers of somatic delusions and hallucinations in schizophrenia. Psychiatry Res 2013; 212:54–64.
23. Palaniyappan L, Balain V, Radua J, Liddle PF. Structural correlates of auditory hallucinations in schizophrenia: a meta-analysis. Schizophr Res 2012; 137:169–173.
24. Emami S, Guimond S, Chakravarty MM, Lepage M. Cortical thickness and low insight into symptoms in enduring schizophrenia. Schizophr Res 2016; 170:66–72.
25. Uwatoko T, Yoshizumi M, Miyata J, et al. Insular gray matter volume and objective quality of life in schizophrenia. PLoS One 2015; 10:p. e0142018.

26. Xiao Y, Lui S, Zhang W, Yao L, Gong Q. Similar and different gray matter deficits in schizophrenia patients and their unaffected biological relatives. Front Psychiatry 2013; 4:150.
27. Mikolas P, Melicher T, Skoch A, et al. Connectivity of the anterior insula differentiates participants with first-episode schizophrenia spectrum disorders from controls: a machine-learning study. Psychol Med 2016; 25:1–10.
28. Gong Q, Dazzan P, Scarpazza C, et al. A neuroanatomical signature for schizophrenia across different ethnic groups. Schizophr Bull 2015; 41:1266–1275.
29. Lee SH, Niznikiewicz M, Asami T, et al. Initial and progressive gray matter abnormalities in insular gyrus and temporal pole in first-episode schizophrenia contrasted with first-episode affective psychosis. Schizophr Bull 2015; 42:790–801.
30. Bijanki KR, Hodis B, Magnotta VA, Zeien E, Andreasen NC. Effects of age on white matter integrity and negative symptoms in schizophrenia. Schizophr Res 2015; 161:29–35.
31. Ohtani T, Bouix S, Hosokawa T, et al. Abnormalities in white matter connections between orbitofrontal cortex and anterior cingulate cortex and their associations with negative symptoms in schizophrenia: a DTI study. Schizophr Res 2014; 157:190–197.
32. Kuswanto CN, Teh I, Lee TS, Sim K. Diffusion tensor imaging findings of white matter changes in first episode schizophrenia: a systematic review. Clin Psychopharmacol Neurosci 2012; 10:13–24.
33. Zhang F, Qiu L, Yuan L, et al. Evidence for progressive brain abnormalities in early schizophrenia: A cross-sectional structural and functional connectivity study. Schizophr Res 2014; 159:31–35.
34. Ellison-Wright I, Bullmore E. Meta-analysis of diffusion tensor imaging studies in schizophrenia. Schizophr Res 2009; 108:3–10.
35. Spoletini I, Cherubini A, Banfi G, et al. Hippocampi, thalami, and accumbens microstructural damage in schizophrenia: a volumetry, diffusivity, and neuropsychological study. Schizophr Bull 2011; 37:118–130.
36. Chiapponi C, Piras F, Piras F, Fagioli S, Caltagirone C, Spalletta G. Cortical gray matter and subcortical white matter brain microstructural changes in schizophrenia are localized and age independent: a case-control diffusion tensor imaging study. PLoS One 2013: 8:p.e75115.
37. von Hohenberg CC, Pasternak O, Kubicki M, et al. White matter microstructure in individuals at clinical high risk of psychosis: a whole-brain diffusion tensor imaging study. Schizophr Bull 2014; 40:895–903.
38. Levitt JJ, Alvarado JL, Nestor PG, et al. Fractional anisotropy and radial diffusivity: diffusion measures of white matter abnormalities in the anterior limb of the internal capsule in schizophrenia. Schizophr Res 2012; 136:55–62.
39. Kahle W, Platzer W, Frotscher M, Leonhardt H. Color atlas and textbook of human anatomy. 4th Ed. New York: Thieme, 2004; 462.
40. Van der Werf YD, Jolles J, Witter MP, Uylings HB. Contributions of thalamic nuclei to declarative memory functioning. Cortex 2003; 39:1047–1062.
41. Ehrlich S, Geisler D, Yendiki A, et al. Associations of white matter integrity and cortical thickness in patients with schizophrenia and healthy controls. Schizophr Bull 2014; 40:665–674.
42. Mamah D, Conturo TE, Harms MP, et al. Anterior thalamic radiation integrity in schizophrenia: a diffusion-tensor imaging study. Schizophr Bull 2014; 40:665–674.
43. Melicher T, Horacek J, Hlinka J, et al. White matter changes in first episode psychosis and their relation to the size of sample studied: a DTI study. Schizophr Res 2015; 162:22–28.
44. Zeng B, Ardekani BA, Tang Y, et al. Abnormal white matter microstructure in drug-naive first episode schizophrenia patients before and after eight weeks of antipsychotic treatment. Schizophr Res 2016; 172:1–8.
45. Zhou SY, Suzuki M, Hagino H, et al. Decreased volume and increased asymmetry of the anterior limb of the internal capsule in patients with schizophrenia. Biol Psychiatry 2003; 54:427–436.
46. Chuang JY, Murray GK, Metastasio A, et al. Brain structural signatures of negative symptoms in depression and schizophrenia. Schizophr Res 2016; 172:1–8.
47. Mitelman SA, Torosjan Y, Newmark RE, et al. Internal capsule, corpus callosum and long associative fibers in good and poor outcome schizophrenia: a diffusion tensor imaging survey. Schizophr Res 2007; 92:211–224.