Kafkas Univ Vet Fak Derg
26 (2): 165-169, 2020
DOI: 10.9775/kvfd.2019.22636

Kafkas Universitesi Veteriner Fakultesi Dergisi
ISSN: 1300-6045 e-ISSN: 1309-2251
Journal Home-Page: http://vetdergikafkas.org
Online Submission: http://submit.vetdergikafkas.org

Research Article

Colonoscopic Diagnosis of Atresia Coli in Calves: 19 Cases (2016-2018) [1]

Taylan ÖNYAY [1,a] Kamil Serdar İNAL [1,b] Birsen Deniz ÖZBAKIR [1,c]
Hatice Özlem NİSBET [1,d] Cenk YARDIMCI [1,e] Kamil SAĞLAM [1,f] Ahmet ÖZAK [1,g]

[1] The study was presented as an oral presentation in the IInd International and XVIth National Veterinary Surgery Congress of Turkey, 20-23 September 2018, Bafra, North Cyprus

[1] Ondokuz Mayıs University, Faculty of Veterinary Medicine, Department of Surgery, TR-55200 Atakum/Samsun - TURKEY
[a] ORCID: 0000-0001-5638-7257; [b] ORCID:0000-0003-0690-5743; [c] ORCID: 0000-0001-9832-1256; [d] ORCID: 0000-0001-9981-1193
[e] ORCID: 0000-0001-6126-3603; [f] ORCID: 0000-0003-4467-187X; [g] ORCID:0000-0002-4359-0691

Article ID: KVFD-2019-22636 Received: 14.05.2019 Accepted: 27.09.2019 Published Online: 27.09.2019

How to Cite This Article

Önyay T, İnal KS, Özbakir BD, Nisbet HÖ, 1,D Yardimci C, Sağlam K, Özak A: Colonoscopic diagnosis of atresia coli in calves: 19 cases (2016-2018). *Kafkas Univ Vet Fak Derg,* 26 (2): 165-169, 2020. DOI: 10.9775/kvfd.2019.22636

Abstract

Atresia coli is sporadically seen in calves and lethal unless intestinal patency is restored through surgery. While there are some reports of surgically corrected animals with atresia coli giving birth to healthy offspring, there is still controversy about treating such cases, since survival is not guaranteed and there is a chance of tainting the herd's gene pool. This study aims to investigate the efficacy of colonoscopy in cases of atresia coli in determining the atresia type and evaluating the lumen. Nineteen calves of different breeds and sex between the ages of 1 to 15 days were included in the study. Colonoscopy duration, maximum distance of the endoscope from the anus and any discernible changes inside the lumen were recorded for each case. The technique was easy to use, required no anaesthesia or sedation and very informative about the condition of the mucosa. Definitive diagnosis of the atresia type using colonoscopy is not possible unless a complete blind end is seen and iatrogenic damage may be caused during the procedure. We believe its diagnostic use can provide the surgeon with data to select which procedure to use and help with prognosis.

Keywords: *Atresia coli, Calf, Colonoscopy*

Buzağılarda Atresia Coli'de Kolonoskopik Tanı: 19 Olgu (2016-2018)

Öz

Atresia coli, buzağılarda sporadik olarak gözlenir ve cerrahi olarak bağırsaktaki içeriğin geçişi sağlanmadığı sürece ölümcüldür. Atresia coli olan ve tedavi edilen hayvanlardan sağlıklı yavru elde edildiğine dair yayınlar olsa da, tedavi sonrası sağ kalım garantisi olmadığından ve sürünün gen havuzunu kirletme riski bulunduğundan böyle hastaların tedavisi halen tartışmalıdır. Bu çalışmada, atresia coli olan buzağılarda kolonoskopi kullanımıyla atresia coli tipinin belirlenmesi ve lümenin değerlendirilmesini amaçlanmıştır. Çalışmada 1 ila 15 günlük yaş arasında, farklı ırk ve cinsiyette 19 buzağı değerlendirilmiştir. Her olgu için kolonoskopi süresi, endoskop ile anüs arasındaki uzaklık ve lümen içerisindeki gözlenebilir değişiklikler kaydedilmiştir. Tekniğin kolay olduğu, anestezi veya sedasyonsuz uygulanabildiği ve mukozanın durumunu değerlendirmede yararlı olduğu belirlenmiştir. Bunun yanında, doğrudan kör uç görülmediği sürece atresia tipinin kesin olarak belirlenmesi mümkün değildir ve uygulama sırasında iatrojenik hasar oluşabilmektedir. Tanıda kolonoskopi kullanmanın, uygulanacak cerrahi girişim şekline karar verilmesi ve prognozun belirlenmesinde katkı sağlayacağına inanıyoruz.

Anahtar sözcükler: *Atresia coli, Buzağı, Kolonoskopi*

INTRODUCTION

Atresia coli is one of the most commonly seen malformations in calves. The disorder is traditionally classified in 4 types [1] but only the first three types of atresia are commonly seen [2]. First type is stenosis, with or without an intact or perforated diaphragm, second is cord atresia and the third is blind end atresia [2]. Etiology of this condition has been theorized to involve disruption of the blood supply to the bowels through local or genetic factors, thus causing stenosis or atresia [3]. Early rectal palpation have been said to cause the malformation [4]

İletişim (Correspondence)
+90 362 3121919/1195
taylan.onyay@omu.edu.tr

although there is also evidence to the contrary, suggesting that early palpation is safe [5,6]. Genetic inheritance of this disease is proposed, and there is proof of this for some breeds, like Holstein-Friesian [7], but it remains suspect in many others [2,3]. The clinical and epidemiological prevalence suggests that this condition may not be inherited in non-predisposed breeds [4].

The prognosis of this condition is poor and worsens with the passage of time [8], as the calves born with this malformation are incompatible with life unless intestinal patency is restored with surgery [1,4]. Affected calves have been known to produce healthy offspring after being surgically corrected [9].

The diagnosis of atresia coli was traditionally based on clinical examination and findings alone. Radiography have been used for diagnosis [10] and there is a report of using contrast radiography and ultrasonography [11] to diagnose the condition. Definitive diagnosis is made by exploratory laparotomy [12].

Colonoscopy is a minimally invasive method that could potentially help to the diagnosis of the condition and provides data in preoperative planning. This study aims to evaluate the viability of this technique in calves with atresia coli.

MATERIAL and METHODS

The study material consisted of calves that were brought to the Teaching Hospital of Animal Hospital of Ondokuz Mayıs University, Faculty of Veterinary Medicine, and Department of Surgery between the years of 2016 and 2018. Animals that were unable to defecate since birth were included in the study regardless of breed and gender.

After learning patient history from the owners, physical examination of each patient was made in accordance to our routine patient exam protocol (which included heart rate, respiratory rate, capillary refill time, dehydration level, body temperature). The hemogram of each patient was evaluated from a blood sample taken from the jugular vein. The patient was then placed on lateral recumbence, rectum was lubricated with polyacrylamide gel and colonoscopy was performed without sedation or anaesthesia. A 1.4 m long flexible endoscope with a diameter of 8.5 mm (Aohua, LG-200) was used for colonoscopy. The endoscopies were recorded using an external TV card's (AverTV) own media capture software.

The atresia types were only estimations based on endoscopic findings since diagnosis requires visualizing the intestines from the outside. If there was no mucosal wall or blind end to be seen and the endoscope could not be moved further due to narrowing of the lumen, the condition was classified as "suspected type I atresia". Although the lumen was stenotic, the condition was presumed to be atresia since no feces were present. If the canal tapered to a very narrow point where the endoscope could not fit through it was recorded as "suspected type 3" atresia, and if a blind end could be clearly visualized it was recorded as a "type 3" atresia.

Breed, gender, atresia type, colonoscopy duration, reach of the endoscope (length from the anus to the maximum possible colonoscopic exam site) and mucosal damage due to previous procedures (done by the owner or private veterinarians) or during the colonoscopy performed in our hospital were recorded for each patient. The presence of iatrogenic damage during colonoscopy was determined when the endoscope was being retracted, if the mucosa was intact upon entry but damaged and/or bleeding while retracting, it was considered to be iatrogenic damage.

RESULTS

The most common breed was Simmental (n=12) followed by Jersey (n=1), Holstein mix (n=4), Limousin (n=1) and Holstein (n=1). Ten calves were male and 9 were female. Ages of the calves at the time of presentation were between 2 and 15 (mean 5.31) days. The colonoscopy is considered to be completed when the endoscope could not be moved any further due to narrowing or upon encountering a blind end. The duration varied between 1'49" and 7'57" (4'53" on average).

There was some amount of mucus content in each colon that was evaluated; in the early cases, that were brought between 1-3 days had clear, bright mucus over their mucosa, the mucus was thicker and yellow in older (4-6 days old) cases and the last three calves (7, 13 and 15 days old) had very thick, almost solid chords or lumps of dried mucus in their lumen. Types of colon content are shown in *Fig. 1*.

Twelve calves were recorded as having "suspected type 1 atresia", 3 with type 3 and 4 with suspected type 3 atresia *(Fig. 2)*. Mucosal damage was seen in 16 calves during colonoscopy; 12 cases had varying degrees of damage due to previous catheterization attempts with various materials. Six of these were delayed cases and had complications (Cases 12, 13, 14, 16, 18, 19), 5 were acute (Cases 2, 6, 7, 11, 17) being brought to the hospital right after the attempts with only superficial injury to the mucosal lining. In one case, the catheterization attempt of the owner resulted in perforation of the blind end (Case 9). The iatrogenic damage with colonoscopy was caused in 4 cases (Cases 3, 8, 10, 15) by either pushing the endoscope without sufficient lubrication of the lumen or inserting it too forcefully. Iatrogenic damage caused either erythematous changes or superficial abrasions and bleeding on the colon mucosa. Examples of mucosal damage were shown in *Fig. 3*.

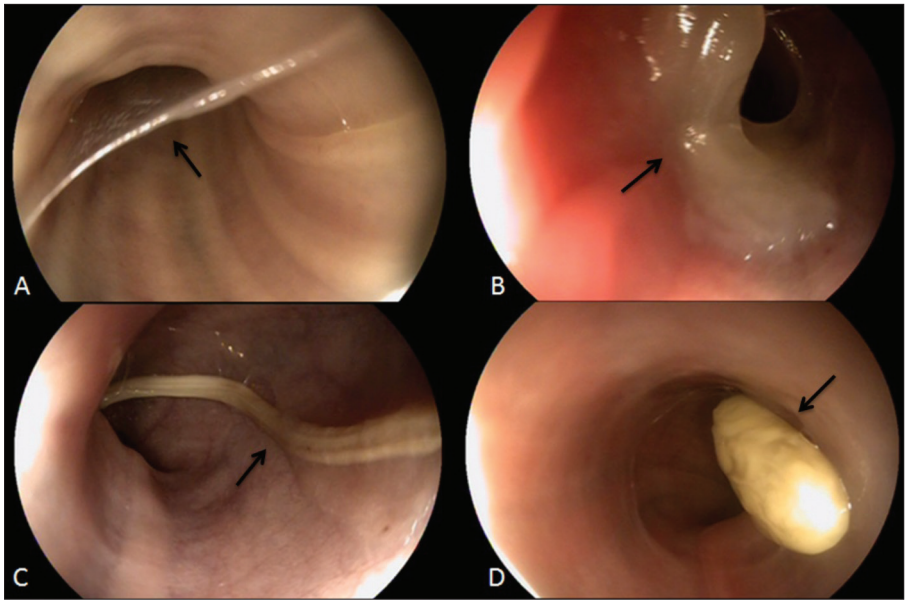

Fig 1. Types of mucus seen in the colon lumen *(black arrows):* (A) One day old clear and bright mucus (B) More opaque, gelatinous mucus (C) Thick, hardened chord of dried mucus (D) and the "lump" like appearance of the colon content

Fig 2. Examples from different atresia coli cases during colonoscopy: (A) Suspected type I atresia, with areas of mucosal erosions *(white arrows)* due to previous catheterization (B) colon lumen tapering to a narrow point *(white arrows)* (C) colon lumen coming to an abrupt end except a tiny orifice *(white arrow),* the erythematous area around the orifice *(black arrows)* was iatrogenic and caused by the endoscope (D) mucosal wall of the blind end with a dark, reddish-brown necrotic area *(white arrows)*

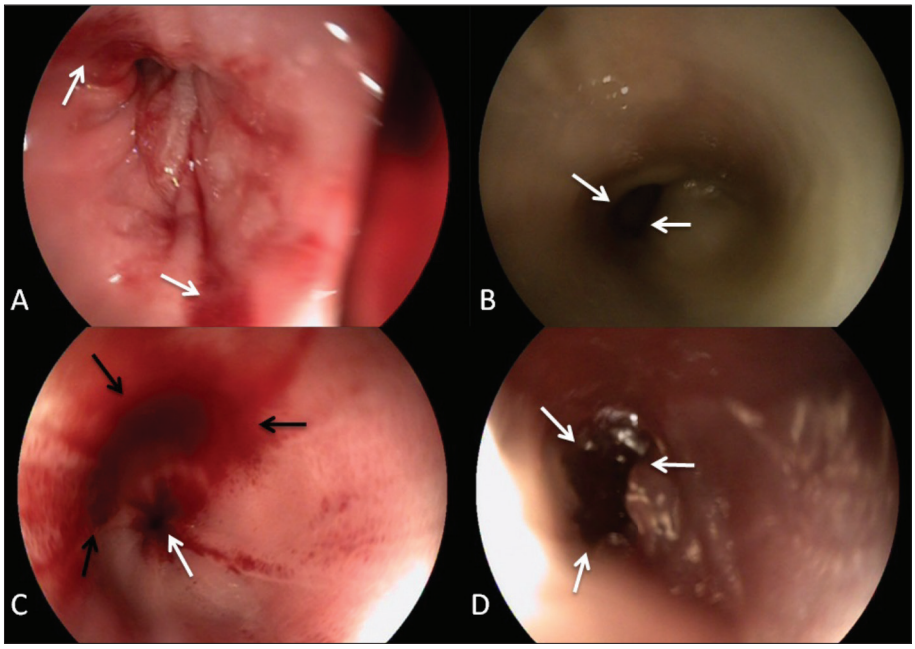

The breed, gender, time elapsed after birth, atresia type, mucosa condition and colonoscopy duration of each case was shown on *Table 1*.

DISCUSSION

The condition mostly occurs in Holstein-Friesians because of a homozygous recessive inheritance factor and is sporadically seen in other breeds [4]. In our study, most of the effected calves were Simmental; this is most likely due to the large number of Simmental breeders in the region of our hospital.

Despite being one of the most common malformations seen in calves, there is no consensus on the etiology or surgical treatment of atresia coli [4]. Surgical correction by means of anastomosis or colostomy has been suggested even though the survival rate is rather low and post-operative care is demanding [4]. There are valid points on not correcting the condition as it is not extensively known to be non-hereditary in most breeds so there is a chance of keeping the calf with defective hereditary traits in the herd. Also, considering the low survival rate and operation costs, the owner is taking a financial risk if the surgery is done. However, there are reports on having healthy calves from surgically corrected animals [9] and many owners that come to our hospital look favourably on surgical correction if every advantage and disadvantage of the operation is explained to them.

The diagnosis of atresia coli is usually easy, meconium is not passed through after birth and there is an anal opening,

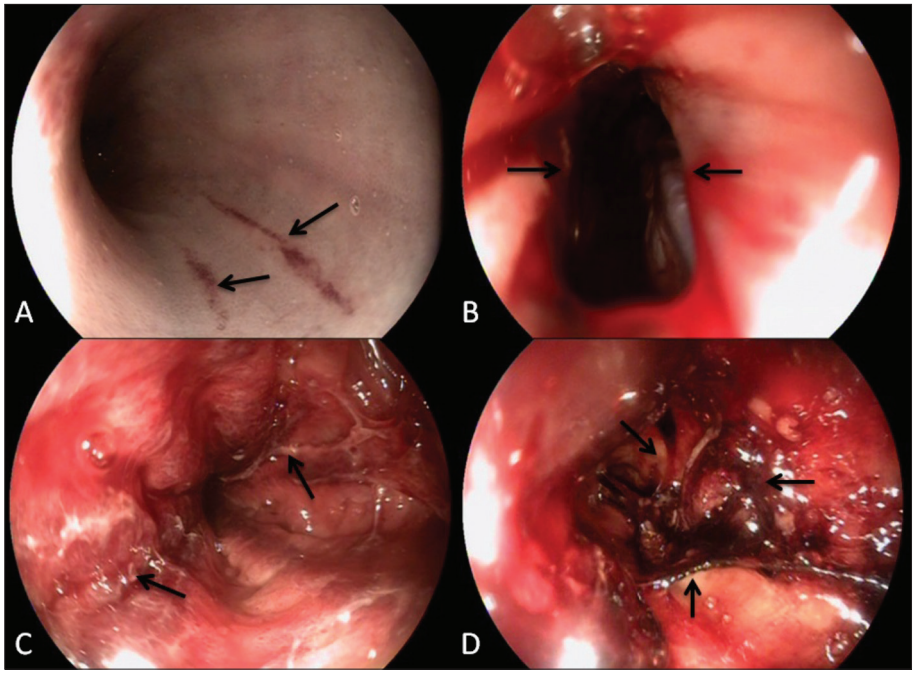

Fig 3. Examples of damage seen in the lumen during colonoscopy: Linear abrasions *(black arrows)* on the lumen (A), perforation *(between the black arrows, abdominal cavity can be seen)* on the wall of the blind end (B), mucosal adhesions *(black arrows)* surrounded by hyperemic mucosa (C), a large mass of clotted blood, mucous discharge and adhesions *(between the black arrows)* inside the lumen (D)

Table 1. *Age, breed, endoscopy duration and endoscopic findings of calves included in the study (Type 1-: Suspected type 1 atresia, Type 3-: Suspected type 3 atresia, Type 3: type 3 atresia)*

Case	Age (Days)	Breed	Gender	Colonoscopy Duration	Colonoscopy Reach (cm)	Atresia Type	Mucosa Damage
1	2	Holstein-Mix	Male	05:31	37	Type 1 -	-
2	2	Holstein-Mix	Male	06:02	40	Type 1 -	Linear abrasions
3	1	Simmental	Male	03:24	30	Type 3 -	Erythematous areas on the mucosa of blind end due to colonoscopy
4	3	Simmental	Male	04:25	30	Type 1 -	-
5	2	Simmental	Female	05:56	90	Type 1 -	-
6	6	Simmental	Female	04:32	30	Type 1 -	Diffuse clot covered areas lined with hyperaemic mucosa
7	3	Simmental	Female	07:57	22	Type 3	Linear superficial abrasions
8	4	Simmental	Male	06:41	45	Type 1 -	Linear superficial abrasions and bleeding due to colonoscopy
9	2	Simmental	Female	02:02	14	Type 3	Devitalized mucosa, adhesions, the blind end was perforated
10	4	Jersey	Male	06:43	25	Type 3 -	Abrasions and bleeding on the mucosa of blind end due to colonoscopy
11	4	Simmental	Male	04:06	60	Type 1	Superficial abrasions
12	7	Holstein-Mix	Male	03:20	25	Type 1	Clotted blood present in the lumen, hyperaemic and swollen mucosa
13	15	Holstein	Female	05:33	75	Type 1	Superficial, linear abrasions
14	13	Holstein-Mix	Male	02:30	45	Type 3	Swollen colon mucosa with diffuse erythematous areas, dark brown necrotic tissue on blind end
15	5	Simmental	Female	07:13	60	Type 3 -	Linear superficial abrasions due to colonoscopy
16	6	Simmental	Female	05:54	50	Type 1	Hyperaemic and slightly swollen areas only at the first 5 cm, rest of the colon was intact
17	2	Simmental	Female	02:53	20	Type 1	Diffuse abrasions that were bleeding
18	6	Limousin	Female	01:49	25	Type 1	Diffusely hyperaemic lumen
19	4	Simmental	Male	06:31	35	Type 3 -	Intraluminal adhesions, hyperaemic mucosa, blood clots

clinicians should suspect intestinal atresia. The condition is not immediately fatal so there is often enough time to get the animal to a reference hospital for diagnosis and treatment [12]. In this study, some of the cases were brought in very late, suggesting the owners mistook the mucus coming from the anal opening for meconium. Furthermore, most of the cases that were brought (n=11) had already damaged colon mucosae with one blind

end confirmed to be perforated, meaning the owners or practitioners tried to insert a catheter inside the atretic colon, which has a very fragile mucosal lining. In three cases, the mucosal damage was extensive and the mucosa had necrotic areas due to the passage of time after being traumatized. While the number of cases presented in this study may not reflect a larger group, they still suggest the fact that many calves will be brought to the hospital with traumatized mucosal linings. It is possible to see the blind end of the colon with direct radiography and ultrasonography [12,13], and one study shows that retrograde contrast radiography can reasonably show the atretic segment [11]. Exploratory laparotomy is the definitive way to establish diagnosis and determine the atresia type [12]. None of these techniques provide a way to noninvasively evaluate the colon mucosa, although one study investigated potential damage to the intestines through the use of biomarkers [14]. Atresia coli surgery involves either performing a colostomy or an anastomosis of the intestines, and even after surgery, functional obstruction may block the flow of feces [1]. Performing colonoscopy not only aids in diagnosis but during the surgical planning process, as seeing a necrotic, infected or obliterated colon segment during the surgery may call for euthanasia and prevent wasting valuable time and resources. Also it helps the surgeon decide in choosing colostomy over anastomosis if the colon segment attached to the rectum is too short, too stenotic or badly damaged. Colonoscopy was previously performed to diagnose the atresia coli in a foal with success [15], which shows the technique may be used for diagnosis, and the results of this study show that it can be used for diagnosis in calves.

Colonoscopy requires minimal experience, is cheap to perform, and does not require sedation or anaesthesia. Familiarizing with the technique requires only a few tries and it can be done in around 5 min. We believe colonoscopy should be used for diagnosis in atresia coli cases and is quite useful for pre-operative planning, aids in determining prognosis and explaining the condition to the owners. The only drawbacks are that endoscopy is not readily available in every clinic and its use is usually limited to reference hospitals and iatrogenic damage to the mucosa is possible during its use.

REFERENCES

1. Kilic N, Sarierler M: Congenital intestinal atresia in calves: 61 cases. *Rev Med Vet,* 155 (7): 381-384, 2004.

2. Van der Gaag I, Tibboel D: Intestinal atresia and stenosis in animals: A report of 34 cases. *Vet Pathol,* 17 (5): 565-574, 1980. DOI: 10.1177/030098588001700505

3. Johnson R: Intestinal atresia and stenosis: A review comparing its etiopathogenesis. *Vet Res Commun,* 10 (1): 95-104, 1986. DOI: 10.1007/BF02213972

4. Constable PD, Shanks RD, Huhn J, Morin DE: Evaluation of breed as a risk factor for atresia coli in cattle. *Theriogenology,* 48 (5): 775-790, 1997. DOI: 10.1016/S0093-691X(97)00301-4

5. Romano JE, Bryan K, Ramos RS, Velez J, Pinedo P: Effect of early pregnancy diagnosis by per rectum amniotic sac palpation on pregnancy loss, calving rates, and abnormalities in newborn dairy calves. *Theriogenology,* 85 (3): 419-427, 2016. DOI: 10.1016/j.theriogenology.2015.09.004

6. Romano JE, Pinedo P, Bryan K, Ramos RS, Solano KG, Merchan D, Velez J: Comparison between allantochorion membrane and amniotic sac detection by per rectal palpation for pregnancy diagnosis on pregnancy loss, calving rates, and abnormalities in newborn calves. *Theriogenology,* 90, 219-227, 2017. DOI: 10.1016/j.theriogenology.2016.11.004

7. Syed M, Shanks R: Atresia coli inherited in holstein cattle. *J Dairy Sci,* 75 (4): 1105-1111, 1992. DOI: 10.3168/jds.S0022-0302(92)77855-2

8. Kumar PR, Prasad VD, Sreenu M, Krishna N: Surgical management of atresia ani in calves-comparative evaluation of timely and delayed presentation complications. *Intas Polivet,* 18 (2): 386-389, 2017.

9. Smith DF, Ducharme NG, Fubini SL, Donawick WJ, Erb HN: Clinical management and surgical repair of atresia coli in calves: 66 cases (1977-1988). *J Am Vet Med Assoc,* 199 (9): 1185-1190, 1991.

10. Azizi S, Mohammadi R, Mohammadpour I: Surgical repair and management of congenital intestinal atresia in 68 calves. *Vet Surg,* 39 (1): 115-120, 2010. DOI: 10.1111/j.1532-950X.2009.00611.x

11. Abouelnasr K, Ishii M, Inokuma H, Kobayashi Y, Lee K, Yamada K: Atresia coli in a Japanese black calf diagnosed by a barium sulphate enema contrast radiograph in the standing position: A case report. *Vet Med (Praha),* 57 (7): 376-379, 2012. DOI: 10.17221/6267-VETMED

12. Trent A, Ducharme N, Fubini S, Steiner A: Surgery of the Calf Gastrointestinal System. **In,** Fubini SL, Ducharme N (Eds): Farm Animal Surgery. 2nd ed., 505-518, Elsevier Health Sciences, St. Louis, 2017.

13. Ducharme NG, Arighi M, Horney FD, Barker IK, Livesey MA, Hurtig MH, Johnson RP: Colonic atresia in cattle: A prospective study of 43 cases. *Can Vet J,* 29 (10): 818-824, 1988.

14. Yildiz R, Ok M, Ider M, Aydogdu U, Naseri A, Parlak K, Gulersoy E: Evaluation of intestinal damage biomarkers in calves with atresia coli. *J Vet Res,* 62 (3): 379-384, 2018. DOI: 10.2478/jvetres-2018-0054

15. Hunter B, Belgrave RL: Atresia coli in a foal: Diagnosis made with colonoscopy aided by N-butylscopolammonium bromide. *Equine Vet Educ,* 22 (9): 429-433, 2010. DOI: 10.1111/j.2042-3292.2010.00080.x