ORIGINAL ARTICLE

Eastern Journal of Medicine

East J Med 24(3): 303-309, 2019
DOI: 10.5505/ejm.2019.31932

The Frequency of Rhythm and Conduction Abnormalities and Benefits of 24-Hour Holter Electrocardiogram on Detecting These Abnormalities In Patients With Acute Rheumatic Fever

Serdar Epçaçan*, Yasemin Nuran Dönmez

University of Health Sciences, Van Training and Research Hospital, Department of Pediatric Cardiology, Van, Turkey

ABSTRACT

During the acute phase of acute rheumatic fever (ARF), cardiac arrhythmias and conduction disorders may occur. Standard electrocardiogram (ECG) may be insufficient in the cases of possible paroxysmal rhythm or conduction abnormalities. The aim of this study is to evaluate arrhythmias and conduction disorders and benefits of 24-hour Holter ECG on detecting these disorders in children with ARF.

Two hundred and ten patients who were diagnosed with ARF during a four-year period, were retrospectively analyzed. Demographic characteristics, clinical, laboratory, and echocardiographic findings of the patients were evaluated. Standard ECG and 24-hour Holter analysis were examined.

First (47.8%), second (6.9%) and third degree (4.3%) atrioventricular (AV) blocks, bundle branch blocks (9.8%), intermittent pre-excitation (1.1%), accelerated nodal rhythm (15.2%), supraventricular (10.9%) and ventricular premature contractions (8.7%), as well as supraventricular (3.3%) and ventricular tachycardia (1.1%) were detected with 24-hour Holter ECG. Frequency of both rhythm and conduction abnormalities were detected higher with Holter ECG than 12-lead ECG, and this was statistically significant ($p<0.05$). Second degree type II AV block and non-sustained supraventricular tachycardia as well as intermittent complete AV block were detected on 24-hour Holter analysis in patients with normal initial standard ECG.

The incidence of rhythm and conduction abnormalities is higher than traditionally known. 24-hour Holter ECG is very helpful to detect especially paroxysmal abnormalities and to determine the more exact incidence of rhythm and conduction abnormalities in patients with ARF. For this reason, we suggest a routine 24-hour Holter ECG analysis in pediatric heart centers for patients diagnosed with ARF.

Key Words: Acute rheumatic fever, arrhythmia, conduction disorders

Introduction

Acute rheumatic fever (ARF) is the most common acquired heart disease among children living in developing countries (1). During the acute phase of the disease, cardiac arrhythmias and conduction disorders can be seen (2-4). First degree atrioventricular (AV) block, which is a minor diagnostic criterion of the disease, is frequently seen, while advanced AV block, supraventricular tachycardia, bundle branch blocks, junctional rhythm, premature contractions and ventricular tachycardia are rarely seen (3-7). Although 12-lead electrocardiogram is sufficient for determining the cardiac rhythm in most of the cases, 24-hour Holter monitoring may be useful in the cases of possible paroxysmal rhythm or conduction abnormalities (3,4). The aim of this study is to provide an overview of the frequency of arrhythmias and conduction disorders in children with ARF.

Materials and Method

Two hundred and twenty-nine patients who admitted to Pediatric Cardiology Department of Van Training and Research Hospital between December 2014 and December 2018 and diagnosed with ARF were retrospectively analyzed. Demographic characteristics, clinical, laboratory, electrocardiographic and echocardiographic findings of the patients were evaluated. Complete blood count, titers of

***Corresponding Author:** Serdar Epçaçan, MD, University of Health Sciences, Van Training and Research Hospital, Department of Pediatric Cardiology, Süphan district, İpek yolu street, 65400, Edremit, Van, Turkey
E-mail: drserdar1980@gmail.com, Phone: +90 (505) 454 14 84, Fax: +90 (432) 212 19 54
Received: 20.02.2019, **Accepted:** 05.03.2019

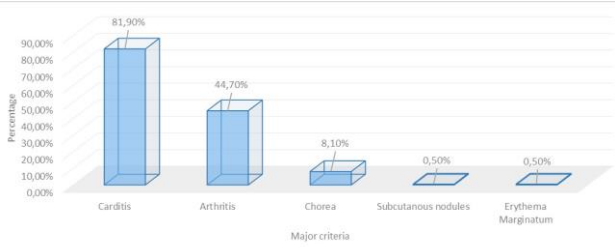

Fig. 1. The frequencies of the major criteria detected in study group

antistreptolysin-O (ASO), throat culture for group A β-hemolytic streptococcus, C-reactive protein and erythrocyte sedimentation rate levels as well as electrocardiogram and echocardiographic analysis were also obtained.

Echocardiographic examinations were performed using a General Electric Vivid Pro 7 (Vingmed Ultrasound, Norway) echocardiography device. 24-hour Holter ECG monitoring was performed using 3 or 12-lead DMS 9800 Holter recorder, and the recordings were analyzed by using Cardioscan12 Holter analysis program (DMS Inc., New York, United States of America). Holter ECG was performed as a routine procedure if Holter recorder device was available at the time of admission for the last two years of the study period, while the presence of abnormal ECG finding or any complaint suspicious with rhythm or conduction abnormality were the indications for a Holter ECG monitoring for the previous years of the study period. A control 24-Holter ECG analysis was performed for all of the patients who had any abnormal finding in initial Holter ECG analysis.

The diagnosis of acute rheumatic fever was made in accordance with the modified Jones criteria, revised in 2015 (8). Benzathine penicillin G was started for secondary prophylaxis with 3 week intervals in all patients. Oral steroids, and non-steroidal anti-inflammatory drugs (NSAIDs) when the steroid was gradually decreased, were given in the presence of moderate-to-severe carditis, whereas NSAIDs was given alone in the situation of mild carditis. Anti-congestive therapy consisting of digoxin, diuretics, or angiotensin-converting enzyme inhibitors was started in patients with evidence of heart failure. Oral NSAIDs were given in the case of isolated arthritis. Treatment was continued for 4-8 weeks according to the severity of carditis together with clinical and laboratory responses to treatment.

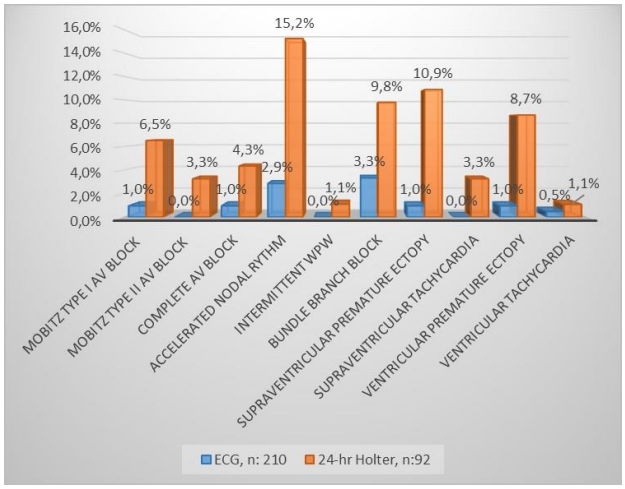

Fig. 2. Comparison of rhythm and conduction abnormalities detected with standard ECG and 24-hour Holter ECG

Statistical Analysis*:* The statistical analysis was performed using Statistical Package for Social Sciences Software, version 21. Demographic and clinical variables were summarized with descriptive statistics. Categorical variables were summarized as absolute frequency and percentage, whereas continuous variables were summarized as the median, mean and standard deviation.

Results

Patient demographics: Two hundred and twenty-nine patients who were diagnosed with ARF were revealed. Nineteen cases were excluded due to lack of ECG reports. The remaining 210 patients were included in the study group. The mean age at diagnosis was 11.58 ± 3.24 years (median: 12, range: 4-18 years) and 54.2% of the patients (n=114) were females. Recurrent rheumatic fever was present in 11 (5.2%) of the cases while the remaining 199 (94.8%) were diagnosed at first attack.

Major criteria: The frequencies of the major criteria are given in Figure 1. The most common major criterion was the carditis (81.9%, n=172) and subclinical silent carditis was constituting 16.8% (n=29) of those cases. Mild, moderate and severe carditis were observed in 63.3%, 25.5%, 12.2% of the patients with carditis. Mitral regurgitation was the most common valve involvement. Isolated mitral and aortic valve regurgitation was present in 46.6% (n=98) and 8.1% (n=17) of all cases, respectively while involvement of both mitral and aortic valve regurgitation was present in 27.1% (n=57). Ninety-four (44.7%) patients had arthritis and

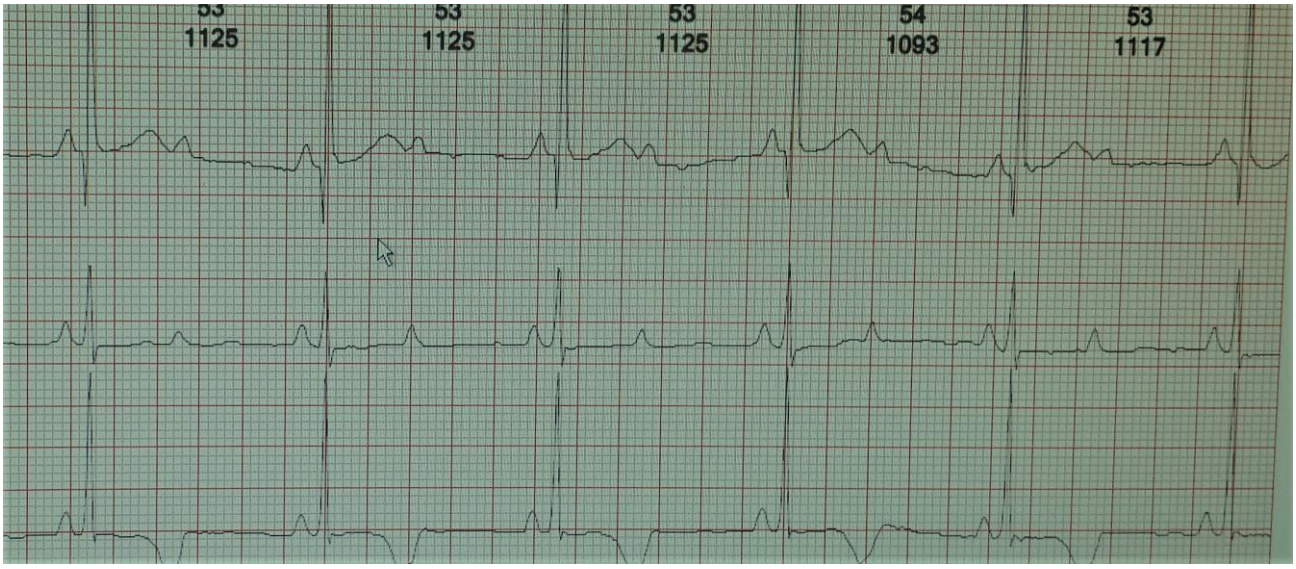

Fig. 3. 3-lead 24-hour Holter ECG record of a patient with Mobitz type II AV block

88.3% of them were polyarthritis while the remaining had mono-arthritis.

Minor criteria and evidence of GABHS infection: Fever was the most common minor criterion (89.0%). Polyarthralgia in the absence of arthritis was present in 20.4% of the cases. First degree AV block on standard ECG was detected 34.2% of the patients. Anti-streptolysin-O titers were elevated in all patients except in four patients whom ASO titers were below 200 IU on admission, but prominently rising titers of ASO were detected after 48 hours of admission. 42.4% patients had a positive throat culture for group A β-hemolytic streptococcus. The median erythrocyte sedimentation rate and C-reactive protein values on admission were 61 mm/hour (range: 30-112) and 21 mg/dl (range: 5-68), respectively.

Rhythm and Conduction Abnormalities: Rhythm and conduction abnormalities detected with standard ECG and 24-hour Holter ECG monitoring are shown on figure 2. Standard ECG was performed in all of the 210 cases, whereas 24-hour Holter ECG was performed in 92 patients. Forty-three (46.7%) of the 24-hour Holter ECGs were belonged to patients with abnormal ECG findings on admission, while 49 (53.3%) had a normal ECG on admission. The most frequent conduction abnormality detected by standard ECG and Holter ECG monitoring was 1st degree AV block, as expected. Regarding the standard ECG on admission, apart from 1st degree AV block, bundle branch block and accelerated nodal rhythm were the two most common abnormality. Incidence of both rhythm and conduction abnormalities were higher in the 24-hour Holter monitor records when compared with standard ECG, and this was statistically significant ($p<0.05$). In addition, second degree type II AV block (figure 3), intermittent complete AV block (figure 4) and non-sustained supraventricular tachycardia (figure 5) were detected on 24-hour Holter analysis in patients with normal initial standard ECG. Syncope was observed in a patient with complete AV block and pre-syncope in the case with sustained ventricular tachycardia (figure 6). The patient with ventricular tachycardia responded well to acute treatment with lidocaine and a short maintenance treatment with propranolol. No specific treatment including any medication or pacemaker implantation was required for other cases with any rhythm or conduction disorder. After the anti-inflammatory treatment, all the blocks, accelerated nodal rhythm, non-sustained supraventricular and sustained ventricular tachycardia were completely resolved, while supraventricular premature ectopy in 4 patients and ventricular premature ectopy in 2 patients were persisted on 24-hour Holter recording.

Discussion

Acute rheumatic fever (ARF) is an inflammatory disease which is caused group A β-hemolytic Streptococcus (1) infection and is still an important reason for mortality and morbidity in low in-come countries (9,10). Although the exact mechanism of ARF is not clear, autoimmune response to throat infection caused by S. pyogenes in a host with predisposing conditions is suggested widely as the pathogenesis of the disease (11,12). According to the 2015 revised Jones criteria, diagnostic criteria is divided according to low-risk

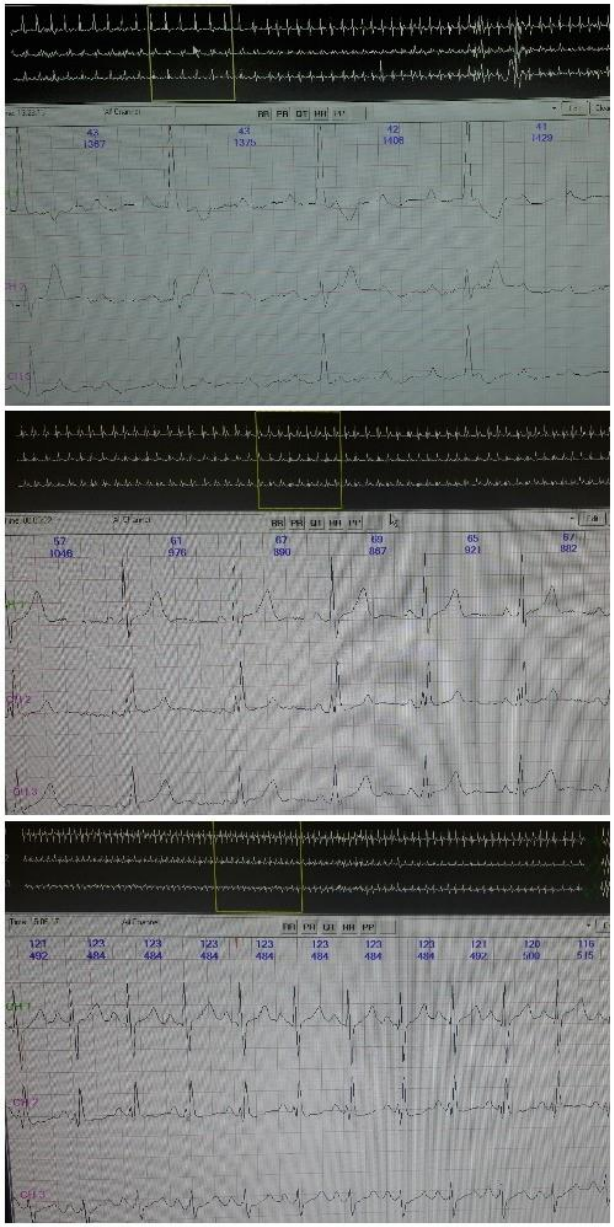

Fig. 4. 12-lead 24-hour Holter ECG records of the patient with intermittent complete AV block

populations and moderate- to high-risk populations (8) . As found in our study, carditis is the most common presentation of ARF and also has important consequences in the course of the disease (13).

Various rhythm and conduction abnormalities have been reported in the literature (3-7,14,15). Although most patients with acute rheumatic fever may be asymptomatic and show only transient electrocardiographic abnormalities, some patients may present with symptoms such as syncope or palpitations (7). Life-threatening arrhythmias such as complete heart block, ventricular tachycardia and ventricular fibrillation can lead to syncope and/or death during the course of ARF (5-7,15,16).

Antistreptolysin-O values or acute phase reactants are not correlated with incidence of arrhythmias or conduction disorders in previously reported studies (17). However, it has been shown that there is a correlation between acute phase reactants and prolonged QT interval (3). Karacan et al. found a significant correlation between prolonged corrected QT interval and patients without carditis (4). The ECG may have prolonged PR interval with or without carditis. Low-voltage QRS and ST segment elevation and/or T wave changes (inversion, diphasic or flat T waves) may also occur due to pericarditis and/or myocarditis (3). Accelerated junctional rhythm is reported to be a highly specific ECG finding in patients with ARF (14). Acquired long QT can be seen in patients with ARF and Torsade de pointes may develop accordingly (15). In addition to 12 lead ECG, arrhythmias and conduction disorders can be detected at a higher rate with 24-hour monitoring (3,4). Premature contractions have been shown to be higher rate with 24-hour Holter monitoring compared to ECG (3,4).

Atrioventricular conduction disorders are well known conditions of ARF. First degree of AV block is the most common conduction abnormality in patients with ARF. Complete AV block may be seen in the presentation of disease or the second AV block can progress to the complete AV block in the course of the disease (5). Sokolow et al., reported conduction abnormalities detected by ECG in 88 (60%) of 147 cases. Of these, 83 (94.3%) were reported as first degree of AV block, 3 (3.4%) with complete AV block and 2 (2.3%) with interventricular block (18). In Zalzstein's study, among 65 patients diagnosed with ARF, 72.3% of the patients diagnosed with first degree AV block, the second and third degree blocks were 1.5% and 4.6% of all cases, respectively (19). In our study, incidence of first degree AV block was lower than this previous reports in the literature, whereas the incidence of second and third degree AV block was compatible with the literature. Although complete AV block is transient and recover spontaneously or with anti-inflammatory treatment (16), in life-threatening situations such as complete AV block associated syncope, rarely there may be a need for temporary (7,20) and even permanent pacemaker implantation (17). In our study, complete AV block occurred in four patients, one of whom presented syncope, but none of them required any specific medication or pacemaker implantation for this situation and spontaneously recovered with

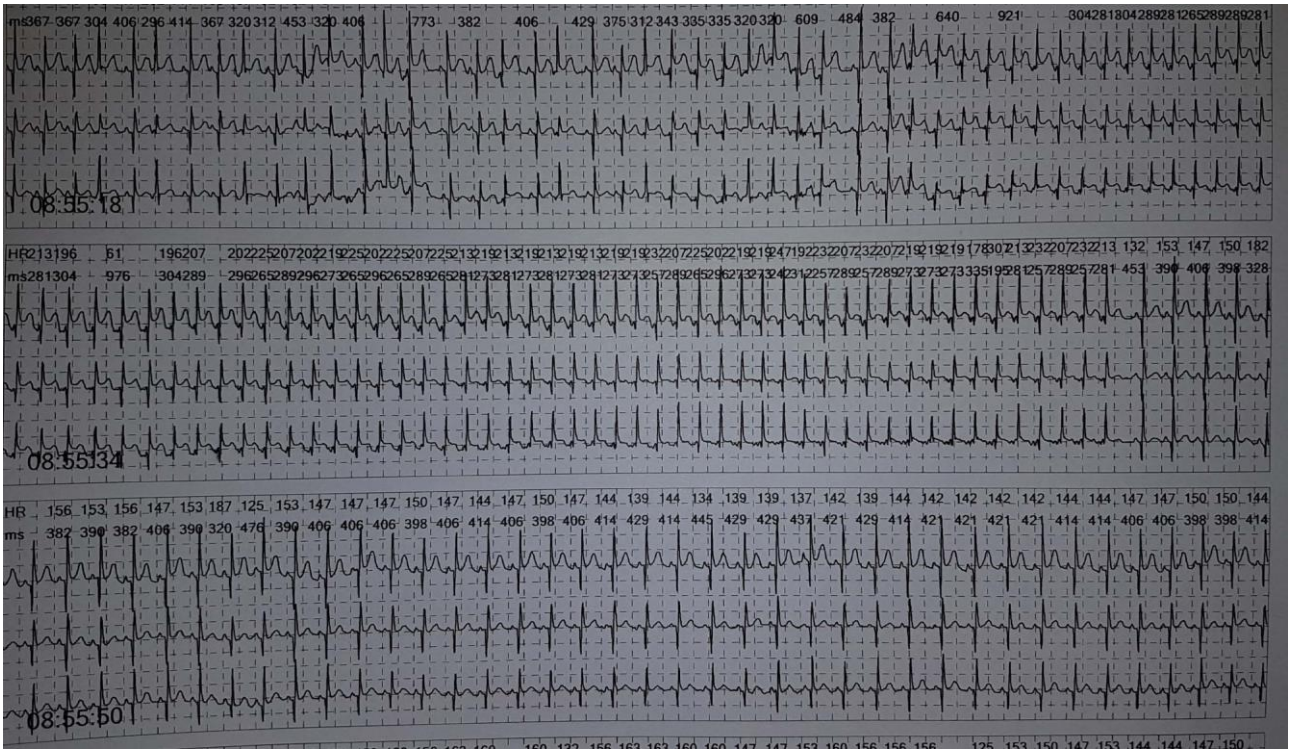

Fig. 5. 3-lead 24-hour Holter ECG record of a patient with non-sustained supraventricular tachycardia

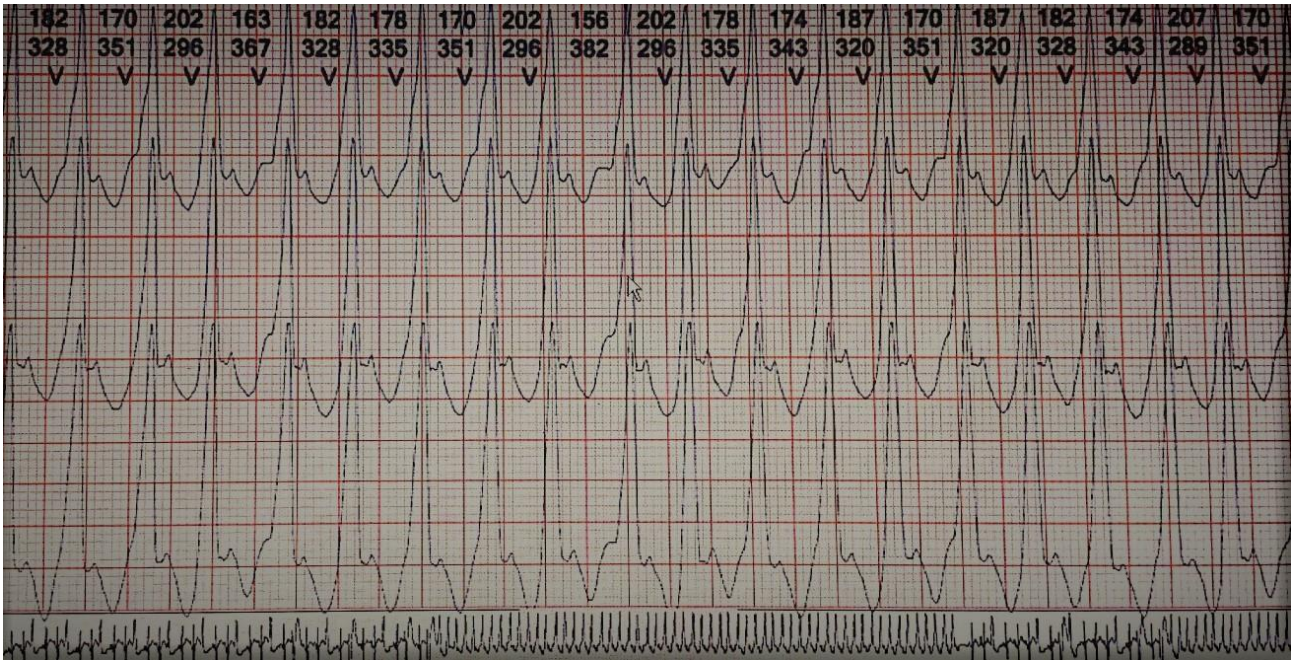

Fig. 6. 3-lead 24-hour Holter ECG record of the patient with sustained ventricular tachycardia

the anti-inflammatory treatment. Sinus pause, junctional escape rhythm, right or left bundle branch block can rarely be seen in patients with ARF (3,21).

Rhythm disorders are less common than conduction disorders in patients with ARF. It has been shown that the premature ectopic beats are correlated with the carditis (4). Ventricular arrhythmias can be seen in ARF and can be lead to life-threatening situations (6,15,22). Compatible with the literature there was a correlation between carditis and ventricular premature contractions in our study. Supraventricular tachycardia may also be seen rarely in the course of ARF (3,23,24). All of supraventricular tachycardia detected in our cases were non-sustained tachycardia attacks shown on 24-hour Holter monitoring and ECGs of these patients were negative for supraventricular tachycardia.

Anti-arrhythmic drugs can be used in patients with ventricular or supraventricular arrhythmias (23,24). It has been reported that phenytoin was administered in a patient with ventricular tachycardia. Lidocaine infusion may also be used in patients with frequent ventricular ectopy, as we experienced in this study, and DC cardioversion and resuscitation may also be required during acute phase of the disease, rarely (15).

Although the vast majority of rhythm and conduction abnormalities detected during the course of ARF are self-limited and response well to anti-inflammatory treatment, they are more common than expected. The incidence of both of these situations are detected with a higher frequency with 24-hour Holter monitoring than standard ECG examination. For this reason, all patients diagnosed with ARF should be carefully monitored to evaluate rhythm and conduction abnormalities. We suggest a routine 24-hour Holter ECG analysis in tertiary pediatric heart centers for patients diagnosed with ARF.

Funding source; None

Conflict of interest: All of the authors declare no conflict of interest in connection to the submitted article.

References

1. Carapetis JR, Beaton A, Cunningham MW, et al. Acute rheumatic fever and rheumatic heart disease. Nat Rev Dis Primers 2016; 2: 15084.
2. Kula S, Olgunturk R, Ozdemir O. Two unusual presentations of acute rheumatic fever. Cardiol Young 2005; 15: 514-516.
3. Balli S, Oflaz MB, Kibar AE, Ece I. Rhythm and conduction analysis of patients with acute rheumatic fever. Pediatr Cardiol 2013; 34: 383-389.
4. Karacan M, Isikay S, Olgun H, Ceviz N. Asymptomatic rhythm and conduction abnormalities in children with acute rheumatic fever: 24-hour electrocardiography study. Cardiol Young 2010; 20: 620-630.
5. Hubail Z, Ebrahim IM. Advanced heart block in acute rheumatic fever. J Saudi Heart Assoc 2016; 28: 113-115.
6. Ramoglu MG, Epcacan S, Yesilbas O. Acute rheumatic fever presenting with severe endocarditis involving four valves, and ventricular tachycardia. Cardiol Young 2019; 29: 78-81.
7. Argun M, Baykan A, Ozyurt A, Pamukcu O, Uzum K, Narin N. Syncope due to complete atrioventricular block and treatment with a transient pacemaker in acute rheumatic fever. Turk Pediatri Ars 2018; 53: 197-199.
8. Gewitz MH, Baltimore RS, Tani LY, et al. Revision of the Jones Criteria for the diagnosis of acute rheumatic fever in the era of Doppler echocardiography: a scientific statement from the American Heart Association. Circulation 2015; 131: 1806-1618.
9. Karthikeyan G, Guilherme L. Acute rheumatic fever. Lancet 2018; 392 : 161-174.
10. Narin N, Mutlu F, Argun M, et al. Incidence and clinical features of acute rheumatic fever in Kayseri, Central Anatolia, 1998-2011. Cardiol Young 2015; 25: 745-751.
11. Guilherme L, Kalil J. Rheumatic fever and rheumatic heart disease: cellular mechanisms leading autoimmune reactivity and disease. J Clin Immunol 2010; 30: 17-23.
12. Jaine R, Baker M, Venugopal K. Acute rheumatic fever associated with household crowding in a developed country. Pediatr Infect Dis J 2011; 30: 315-319.
13. Cann MP, Sive AA, Norton RE, McBride WJ, Ketheesan N. Clinical presentation of rheumatic fever in an endemic area. Arch Dis Child 2010; 95: 455-457.
14. Ceviz N, Celik V, Olgun H, Karacan M. Accelerated junctional rhythm in children with acute rheumatic fever: is it specific to the disease? Cardiol Young 2014; 24: 464-468.
15. Liberman L, Hordof AJ, Alfayyadh M, Salafia CM, Pass RH. Torsade de pointes in a child with acute rheumatic fever. J Pediatr 2001; 138: 280-282.
16. Carano N, Bo I, Tchana B, Vecchione E, Fantoni S, Agnetti A. Adams-Stokes attack as the first symptom of acute rheumatic fever: report of an adolescent case and review of the literature. Ital J Pediatr 2012; 38: 61.
17. Oba Y, Watanabe H, Nishimura Y, et al. A Case of Adult-Onset Acute Rheumatic Fever With Long-Lasting Atrioventricular Block Requiring Permanent Pacemaker Implantation. Int Heart J 2015; 56: 664-667.
18. Sokolow M. Significance of electrocardiographic changes in rheumatic fever. Am J Med 1948; 5: 365-378.
19. Zalzstein E, Maor R, Zucker N, Katz A. Advanced atrioventricular conduction block in acute rheumatic fever. Cardiol Young 2003; 13: 506-508.
20. Reddy DV, Chun LT, Yamamoto LG. Acute rheumatic fever with advanced degree AV block. Clin Pediatr 1989; 28: 326-328.
21. Yahalom M, Jerushalmi J, Roguin N. Adult acute rheumatic fever: a rare case presenting with left bundle branch block. Pacing Clin Electrophysiol 1990; 13: 123-127.

22. Olgun H, Ceviz N. Unusual rhythm problems in acute rheumatic fever: two patient reports. Clin Pediatr 2004; 43: 197-199.
23. Ergul Y MH, Nisli K, Aydogan U, Dindar A, Eker-Omeroglu R. A Rare Rhythm Abnormality in Acute Rheumatic Fever: Supraventricular Tachycardia. J Child 2011; 11: 36-38.
24. Kayali Ş DV, Keskin M, Yoldaş T, et al. Rhythm Disturbances in the Acute Stage of Acute Rheumatic Fever; Report of Four Cases. Ann Pediatr Child Health 2015; 3: aid1051.