DOI:10.14744/bej.2020.65707
Beyoglu Eye J 2020; 5(1): 49-52

Case Report

Sterile Corneal Infiltrate Management After Corneal Crosslinking in Pediatric Keratoconus

Ayhan Saglik,[1] Mehmed Ugur Isik[2]

[1]Department of Ophthalmology, Harran University, Sanliurfa, Turkey
[2]Department of Ophthalmology, Balikligol State Hospital, Sanliurfa, Turkey

Abstract

A 6-year-old female was admitted to the ophthalmology department with a preliminary diagnosis of keratoconus. An accelerated cross-linking (CXL) protocol (9 mW/cm^2 in 10 minutes) was performed on the right eye. On postoperative day 2, a slit-lamp examination revealed 2 corneal infiltrates with grade 3 haze. Since there was no growth in the cultivated cultures and no response to topical antibiotic treatment, the infiltrates were considered to be sterile, and topical 1% prednisolone drops were applied hourly. Despite topical steroid treatment of 1% prednisolone on postoperative day 5, no significant improvement was observed in the patient's symptoms and slit-lamp findings. Therefore, systemic 1 mg/kg prednisolone (total dose, 15 mg) was added to the treatment on postoperative day 5. One day after initiating the systemic steroid treatment, the infiltrates had shrunk, and the patient's complaints decreased. In patients with keratoconus who are under 10 years of age, the addition of a potent steroid regimen to the treatment may be essential in cases with suspected infiltrates after CXL treatment.

Keywords: Cross-linking, pediatric keratoconus, sterile infiltrate, steroid.

Introduction

Keratoconus is a corneal ectasia with irregular astigmatism, progressive corneal thinning, and corneal scarring. It usually begins during puberty, with progression rates varying among patients (1, 2). Since the rate of rapid progression at a pediatric age is greater than in adulthood, strict follow-up is recommended (3). The global consensus in 2015 described this in detail (4).

This is a case report of a 6-year-old female who developed sterile corneal infiltrates after accelerated corneal crosslinking (CXL) treatment for keratoconus.

Case Report

A 6-year-old female was admitted to our ophthalmology department with a preliminary diagnosis of keratoconus. The best-corrected visual acuity (BCVA) was 20/40 in the right eye with a cycloplegic refractive correction of +1.0/−4.50/25° and 20/30 in the left eye with a cycloplegic refractive correction of +1.0/−2.50/165°. Slit-lamp examination revealed vernal conjunctivitis in both eyes. No pathological finding of opacity, scarring, or striae was found in the cornea. She had been taking topical fluoromethalone 4 times a day and olopatadine 2 times a day for 2 weeks for the vernal conjunctivitis. There was no additional ocular or systemic disease.

There was stage 2 keratoconus in the right eye and stage 1 keratoconus in the left eye, according to the Amsler-Krumeich system (5). Before treatment, the thinnest corneal thickness measured using a Pentacam HR system (Oculus Optikgerate GmbH, Wetzlar, Germany) was 464 µm in the right eye and 476 µm in the left eye. The maximal curvature (Kmax) was 54.9 diopters (D) in the right eye and 52.3 D in the left eye. An asymmetric bow tie pattern was observed on the axial map in both eyes (Fig. 1).

Address for correspondence: Ayhan Saglik, MD. Osmanbey Kampusu, Harran Universitesi Tip Fakultesi Hastanesi, Goz Hastaliklari Poliklinigi Haliliye, Sanliurfa, Turkey
Phone: +90 536 356 11 71 **E-mail:** saglikayhan@yahoo.com

Submitted Date: November 05, 2019 **Accepted Date:** January 14, 2020 **Available Online Date:** February 17, 2020

©Copyright 2020 by Beyoglu Eye Training and Research Hospital - Available online at www.beyoglueye.com
OPEN ACCESS This work is licensed under a Creative Commons Attribution-NonCommercial 4.0 International License.

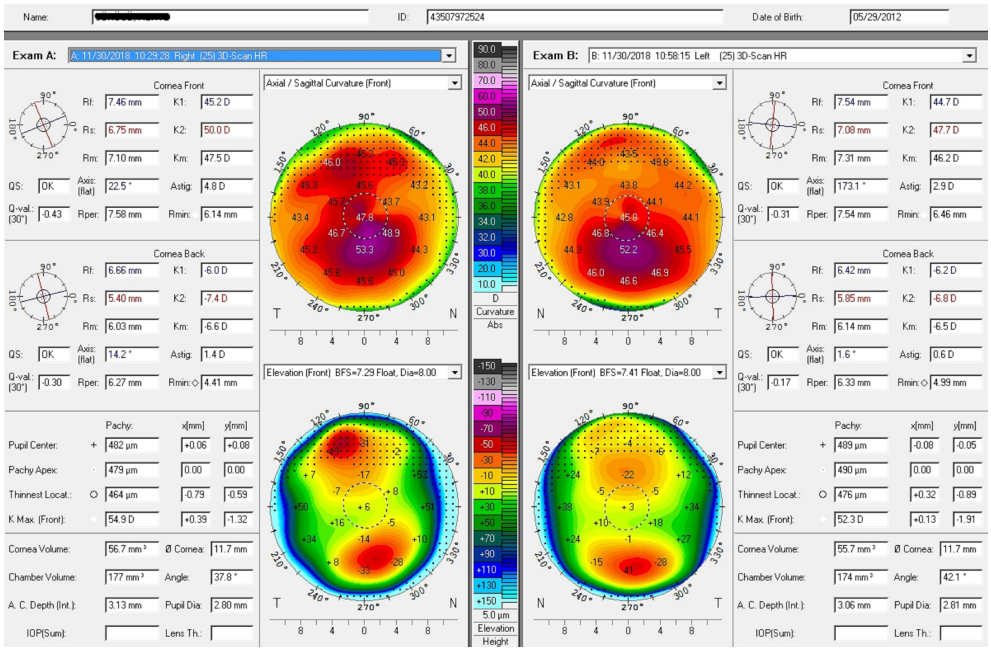

Figure 1. Scheimpflug topography maps of the right and left eyes before the crosslinking treatment.

After general anesthesia, 9 mm of the corneal epithelium was separated using a crescent knife before the corneal CXL treatment. Isotonic riboflavin solution (0.1% riboflavin with 20% dextran T500; Collagex, Taipei, Taiwan) was instilled for 30 minutes at 2-minute intervals. After separation of the epithelium, the corneal thickness as measured using an ultrasonic pachymeter was 411 µm. Ultraviolet A (UVA) light (365 nm) was then used at an irradiance of 9.0 mW/cm^2 for 10 minutes (LightLink-CXL; LightMed, San Clemente, CA, USA). During the application of UVA, riboflavin was instilled at 2-minute intervals. The corneal thickness was 406 µm at the completion of treatment. The surface of the eye was then washed with 10 mL of balanced salt solution. Immediately following the CXL treatment, a balafilcon A contact lens (PureVision; Bausch & Lomb, Bridgewater Township, NJ, USA) was inserted. At postoperative 1 hour, treatment with moxifloxacin hydrochloride drops was initiated 6 times a day as well as preservative-free artificial tears 1 drop every 2 hours (Hypromellose; Bausch & Lomb, Bridgewater Township, NJ, USA).

On postoperative day 2, the patient had severe pain, photophobia, and blurred vision in her right eye. Her visual acuity was 20/400, and a slit-lamp examination revealed 2 infiltrates with grade 3 haze: one 1.5×1.5 mm in diameter at the 2 o'clock level, and the other 0.5×0.5 mm in diameter at the corneal center. No anterior chamber reaction was detected (Fig. 2A).

The bandage contact lens was removed and a corneal swab sample was cultured at bedside. No pathogen was detected using Gram and Geimsa staining. The cultures did not exhibit growth in the first 24 hours. During this period, topical fortified vancomycin gtt (50 mg/mL, hourly), fortified cefazolin gtt (50 mg/mL, hourly), cyclopentolate gtt (1%, 3 times a day), and tear substitutes (Artelac Complete, hourly; Bausch & Lomb, Bridgewater Township, NJ, USA) were applied at regular intervals.

On postoperative day 3, the patient's complaints of pain and blurred vision increased, and the infiltrate size had not decreased. Because there was no growth in the cultures, the infiltrates were considered to be sterile, and hourly treatment with topical 1% prednisolone drops was added. Despite topical steroid treatment of 1% prednisolone on postoperative day 5, no significant improvement was observed in the patient's symptoms and slit-lamp findings (Fig. 2B). Systemic prednisolone (1 mg/kg; total dose, 15 mg) was added to the treatment on postoperative day 5.

The existing treatment with topical antibiotics and steroids was continued. One day after systemic steroid treatment, the infiltrates had decreased in size, and the patient's complaints decreased. Systemic prednisolone treatment was continued for 3 days. The corneal infiltrates were completely resolved and scar formation developed after postoperative day 8 (Fig. 2C). The dose of topical prednisolone was reduced to a drop every 3 hours during the day and continued for 2 weeks. After 2 weeks, it was replaced with fluoromethalone 5 times a day.

The patient's symptoms improved in the second postoperative week. The fluoromethalone treatment (3 times/day) was continued for 3 months and artificial tears were applied as needed. After 6 months, the patient's BCVA was 20/30

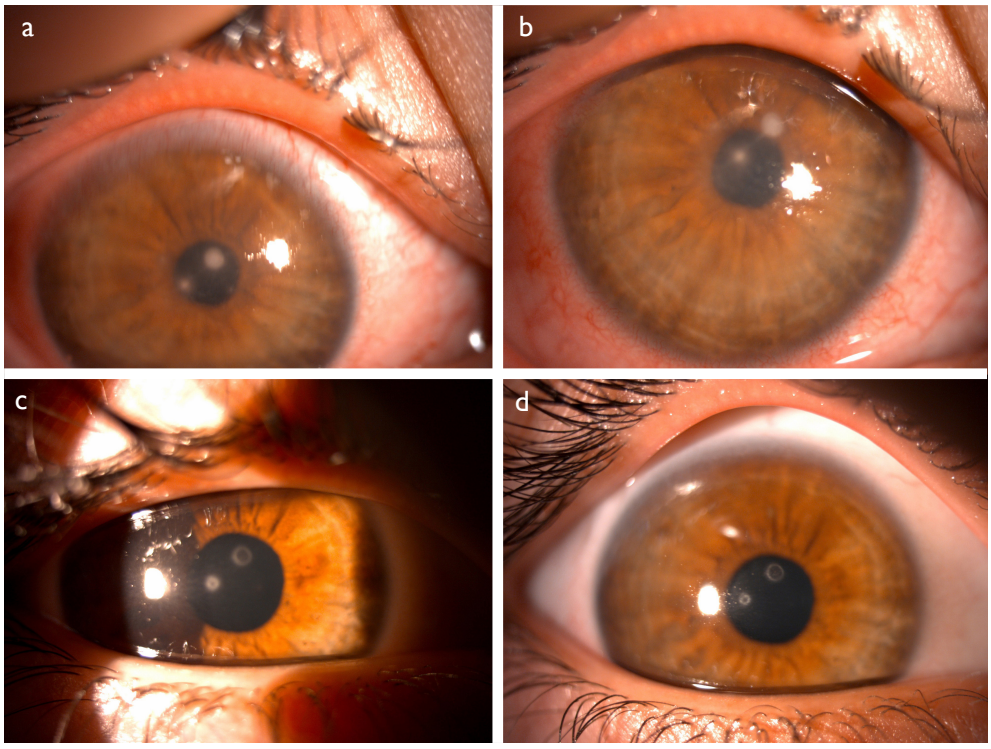

Figure 2. Slit-lamp photograph of the patient after crosslinking treatment. **(a)** Postoperative day 2: Two infiltrates with grade 3 haze: one 1.5×1.5 mm in diameter at the 2 o'clock level and the other 0.5x0.5 mm in diameter at the corneal center. **(b)** Postoperative day 5: Despite topical steroid treatment with 1% prednisolone, no significant improvement was observed in the patient's symptoms or slit-lamp findings. **(c)** Postoperative day 8: After systemic prednisolone treatment, the corneal infiltrates were completely resolved and scar formation developed. **(d)** Postoperative 6 months: Scar formation was present in the cornea center and at the 2 o'clock position.

with a cycloplegic refractive value of −2.50/20°. Scar formations were present in the cornea center and at 2 o'clock (Fig. 2D). According to topographic parameters, there was a 13-µm thickening of the cornea. There was also a 0.5-D decrease in the Kmax (Fig. 3).

One month after treatment of the right eye, accelerated CXL treatment was planned for the left eye. One day before treatment, a single dose of systemic 15 mg prednisolone was administered. No infiltrates developed after CXL treatment in the left eye.

Discussion

Although corneal CXL treatment is known to be a reliable method, some postoperative problems may develop. In the development of sterile infiltrates, factors such as bandage contact lens-induced hypoxia, alcohol use for epithelial debridement, reaction to UV rays, overdose of UV radiation, and topical nonsteroidal anti-inflammatory drugs, are thought to be potential facilitators (6). It has been reported that increased cell-mediated response to staphylococcal antigens deposited at high concentrations in the static tear pool may be the cause of sterile corneal stromal infiltrates (7). In addition to these factors, the relationship between vernal conjunctivitis and sterile corneal infiltrate formation after CXL has been investigated, but no significant relationship has been found (8). In this case report, a 6-year-old female with keratoconus developed problems after accelerated CXL treatment. Based on past studies, pediatric CXL treatment data have generally been recorded from patients aged 8 years and older (3, 9). However, Sabti et al. (10) described use of CXL to treat a 4-year-old girl with Down syndrome with no complications after the treatment.

In our case, parameters such as nonresponsiveness to antibiotics and lack of culture growth led us to consider the possibility of sterile infiltrates. Additionally, the lack of response to topical steroid treatment was a symptom of the clinical course. In previous studies, the response of the infiltrate to topical steroid treatment has been used as an important guide in the diagnosis of sterile keratitis after CXL treatment in patients under 15 years of age (6, 8, 11, 12). In the current case, when there was no response to topical steroids, we suspected that the infiltrates were sterile. A rapid response to systemic steroid treatment can result in a different experience in the management of sterile keratitis in

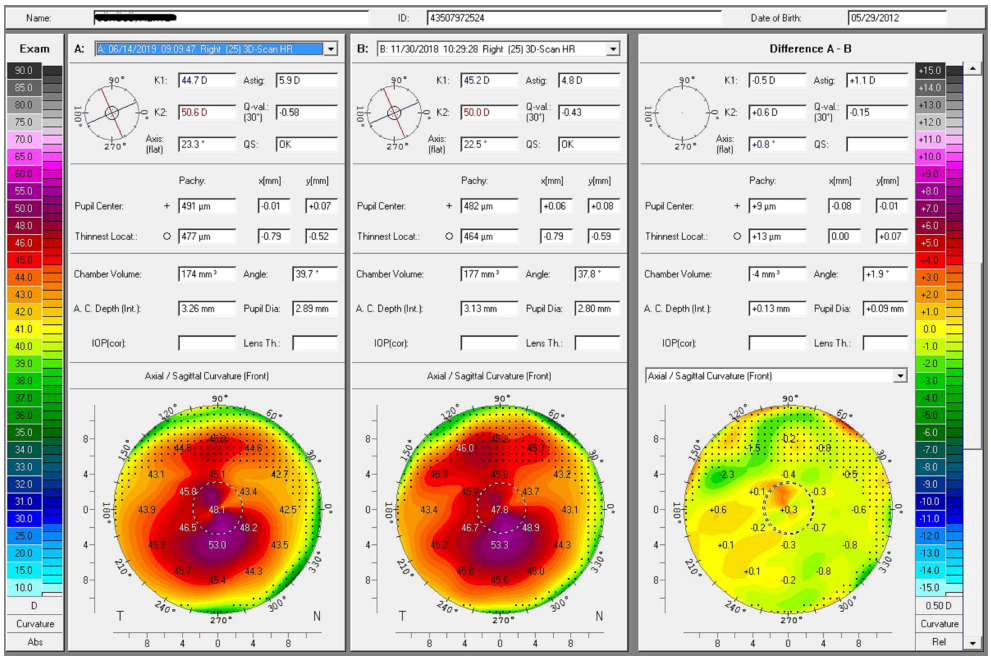

Figure 3. Scheimpflug axial map comparison before the crosslinking treatment and the results at postoperative 6 months.

young children. Prophylactic systemic steroid treatment before the treatment of the other eye of the patient likely prevented the development of infiltrates after the procedure.

As a result, especially in patients with keratoconus who are under 10 years of age, patient follow-up is more important. Furthermore, the addition of potent systemic steroid regimens to treatment may be essential in cases with suspected infiltrates.

Disclosures

Informed Consent: Written informed consent was obtained from the parents of the patient for the publication of the case report and the accompanying images.

Peer-review: Externally peer-reviewed.

Conflict of Interest: None declared.

Authorship Contributions: Involved in design and conduct of the study (AS); preparation and review of the study (AS, MUI); data collection (AS).

References

1. Rabinowitz YS. Keratoconus. Surv Ophthalmol 1998;42:297–319.
2. Jhanji V, Sharma N, Vajpayee RB. Management of keratoconus: current scenario. Br J Ophthalmol 2011;95:1044–50.
3. Mukhtar S, Ambati BK. Pediatric keratoconus: a review of the literature. Int Ophthalmol 2018;38:2257–66.
4. Gomes JA, Tan D, Rapuano CJ, Belin MW, Ambrósio R Jr, Guell JL, et al. Global consensus on keratoconus and ectatic diseases. Cornea 2015;34:359–69.
5. Krumeich JH, Daniel J, Knülle A. Live-epikeratophakia for keratoconus J Cataract Refract Surg 1998;24:456–63.
6. Arora R, Jain P, Gupta D, Goyal JL. Sterile keratitis after corneal collagen crosslinking in a child. Cont Lens Anterior Eye 2012;35:233–5.
7. Koppen C, Vryghem JC, Gobin L, Tassignon MJ. Keratitis and corneal scarring after UVA/riboflavin cross-linking for keratoconus. J Refract Surg 2009;25:S819–23.
8. Çerman E, Özcan DÖ, Toker E. Sterile corneal infiltrates after corneal collagen cross linking: evaluation of risk factors. Acta Ophthalmol 2017;95:199–204.
9. Perez-Straziota C, Gaster RN, Rabinowitz YS. Corneal Cross-Linking for Pediatric Keratcoconus Review. Cornea 2018;37:802–9.
10. Sabti S, Tappeiner C, Frueh BE. Corneal cross-linking in a 4-year-old child with keratoconus and down syndrome. Cornea 2015;34:1157–60.
11. Mereaux D, Knoeri J, Jouve L, Laroche L, Borderie V, Bouheraoua N. Sterile keratitis following standard corneal collagen crosslinking: A case series and literature review. J Fr Ophtalmol 2019;42:603–11.
12. Seven E, Batur M, Çinal A, Yaşar T. Sterile keratitis after corneal collagen crosslinking in keratoconus. JCRS Online Case Reports 2016;4:23–6.