Diagn Interv Radiol 2019; 25:109–113
© Turkish Society of Radiology 2019

CARDIOVASCULAR IMAGING
ORIGINAL ARTICLE

Vieussens' arterial ring: a rare coronary variant anatomy

Nurullah Doğan
Aydın Dursun
Hakan Özkan

PURPOSE
We aimed to evaluate Vieussens' arterial ring (VAR) variants by consecutive coronary computed tomography (CT) angiography examinations.

METHODS
We retrospectively evaluated the presence of VAR in a total of 3443 consecutive coronary CT angiography examinations performed between November 2010 and January 2015. CT examinations were performed with a 64-row multidetector computed tomography (MDCT) scanner. All CT angiography images were evaluated for the presence and morphologic features of VAR subtypes. VAR variants were classified into four subgroups.

RESULTS
Eleven VAR variations (3.19‰) were identified. Type 1A was the most common VAR type (n=8), followed by Type 2 (n=2) and Type 3 (n=1). Type 1B was not detected.

CONCLUSION
Although VAR variation is less frequently detected with coronary CT angiography than in previously reported anatomic series, coronary CT angiography is quite effective to reveal VAR subtypes and other relevant cardiocoronary anomalies.

The long-term outcome of coronary artery disease is mainly determined by the presence or absence of collateral circulation. Vieussens' arterial ring (VAR) refers to the connection between the conus artery and the left anterior descending (LAD) coronary artery's proximal right ventricular branch (1). VAR is present in 48% of the population as an embryonic conotruncal ring remnant (2). However, the VAR detection rates are low when imaging methods are used (3). A literature search for VAR included case reports (4–13), review articles (2, 3) and one brief report (1). To our knowledge there are no original articles or research regarding the VAR incidence in the population or classification of VAR. Multidetector computed tomography (MDCT) can complement traditional coronary angiography by providing highly accurate images of coronary arteries (1). In this study, we aimed to determine the frequency of VAR and evaluate VAR variations according to their anatomical differences in a large number of consecutive coronary CT angiography examinations.

Methods

Patients

The presence of VAR was evaluated in a total of 3443 consecutive coronary CT angiography examinations performed in our department between November 2010 and January 2015 for various reasons including coronary and cardiac morphology assessment, electrocardiography (ECG) abnormalities, coronary bypass graft evaluation, coronary stent evaluation, coronary atherosclerosis evaluation, and screening of high risk patients (with diabetes, smoking history, family history, and hypertension). Of 3443 patients, 67.4% were male. The rate of coronary artery disease was 25.6% with 3% myocardial infarction, 7.7% prior coronary stenting, and 6.7% prior coronary surgery. Of the patients, 29.3% had hy-

From the Department of Radiology (N.D. ✉ *drndogan@gmail.com*), Doruk Medical Center, Bursa, Turkey; Department of Cardiology (A.D.), MedicalPark Hospital, Bursa, Turkey; Department of Cardiology (H.Ö.), Bahçeşehir University School of Medicine, İstanbul, Turkey.

Received 30 November 2017; revision requested 28 December 2017; last revision received 13 August 2018; accepted 14 August 2018.

Published online 12 February 2019.

DOI 10.5152/dir.2019.17449

You may cite this article as: Doğan N, Dursun A, Özkan H. Vieussens' arterial ring: a rare coronary variant anatomy. Diagn Interv Radiol 2019; 25:109–113.

pertension and 11% had diabetes mellitus. The reason for coronary CT evaluation was inappropriate exercise test or suspected ischemia in myocardial perfusion imaging in 75% of the patients. The remaining 25% were screened for suspected ischemia according to their risk factors such as diabetes mellitus, hypertension, hyperlipidemia or family history. All images were reviewed by a radiologist highly experienced in cardiac imaging. When a coronary anomaly was detected, images were re-evaluated by an expert interventional cardiologist. The study was approved by institutional review board (Protocol number was 2015/08-10) and all patients signed a written consent form.

Imaging

Coronary CT angiography examinations were conducted with a 64-row MDCT scanner (Optima CT660, GE Healthcare). All CT angiography examinations were performed with prospective or retrospective electrocardiography (ECG)-gating according to heart rate and cardiac rhythm. The target cardiac rate was <70 bpm. If necessary, intravenous (IV) metoprolol was used immediately prior to the scanning and the heart rate, blood pressure, and ECG were routinely monitored during the procedure. A total of 70 mL noniodinated contrast medium (Ioversol 350 mg/dL, Mallinckrodt) was injected at a rate of 5–6 mL/s by using the bolus tracking protocol. The coronary CT angiography procedure was prospective in 1954 and retrospective in 1489 patients. In prospective ECG-gated scans, the mean effective dose was 2.1 mSv (1.2–4.9 mSv), the mean kilovoltage was 95 kV (80–100 kV), the mean milliampere second was 220 mAs (150–330 mAs), and the mean dose length product was 150 DLP (80–260 DLP). In retrospective ECG-gated scans, the mean effective dose was 4.5 mSv (3.6–9.1 mSv), the mean kilovoltage was 105 kV (100–120 kV), the mean milliampere second was 220 mAs (180–350 mAs) and the mean dose length product, 355 DLP (260–690 DLP). The constructed coronary CT angiography images were stored in our PACS.

Statistical analysis

Descriptive statistics were calculated using Statistical Package for the Social Sciences (SPSS) 10 program. The 95% confidence intervals (95% CI) were calculated using the exact binomial method.

Results

Four subgroups of VAR were found and defined as a collateral pathway originating from the right anterior conus artery, a collateral pathway passing in front of the pulmonary artery, a collateral pathway connecting the right and a collateral pathway connecting the left coronary artery circulation (Table). We also included congenital variations with various names thought to be compatible with life thanks to a patent collateral pathway and its acquired pathologies in the classification (5, 14–16). Based on this we defined VAR variants as Types 1A, 1B, 2, and 3. Type 1A refers to cases with VAR that have no accompanying vascular pathology and an appearance consistent with classic VAR (Fig. 1). Type 1B indicates VAR accompanying with vascular pathology such as an aneurysm or fistula directly associated with the VAR (4, 8, 11, 12). In Type 2, VAR is associated with a short LAD branch which terminates in the anterior descending groove and the long branch which originates from the right coronary circulation, passes in front of the pulmonary artery and extends to the distal section of the anterior descending groove (Fig. 2). This variant was similar with Type 4 of LAD artery duplication classification. Cases with a single coronary artery anomaly together with VAR were defined as Type 3 (Fig. 3) (5, 16).

Eleven VAR variations were detected among the 3443 cases (3.19‰; 95% CI, 1.60–5.71). The mean age was 53.7 years

Table. The classification of VAR variants

Type	Explanation
1A	VAR with no accompanying vascular pathology
1B	VAR with accompanying vascular pathology (aneurysm, fistula)
2	VAR-like dual LAD duplication
3	VAR with single coronary artery anomaly

LAD, left anterior descending coronary artery; VAR, Vieussens' arterial ring.

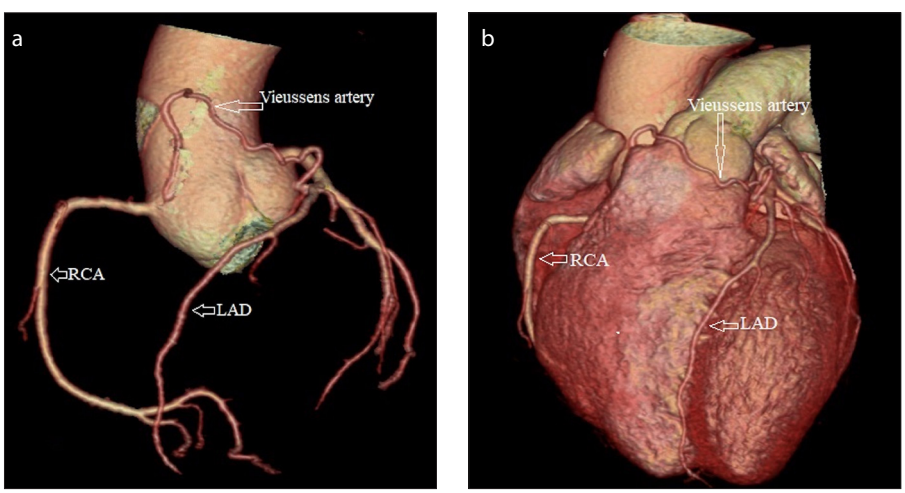

Figure 1. a, b. The conus artery and proximal portion of LAD coronary artery connection (Type 1A Vieussens' arterial ring, VAR) in three dimensional (3D) volume rendering **(a)** and heart surface volume rendering **(b)** reconstructions. RCA, right coronary artery; LAD, left anterior descending coronary artery.

Main points

- Although Vieussens' arterial ring (VAR) has been reported to have a high rate of 48% in anatomical studies, there is no study in the literature about how much it can be detected with imaging methods.
- Existing literature reports consist of case reports and reviews where pathologic cases are reported incidentally.
- This study is the first to investigate the frequency of VAR in the literature and classify VAR in subgroups.
- This study will be useful in planning the treatment of VAR in patients scheduled for revascularization or surgery.

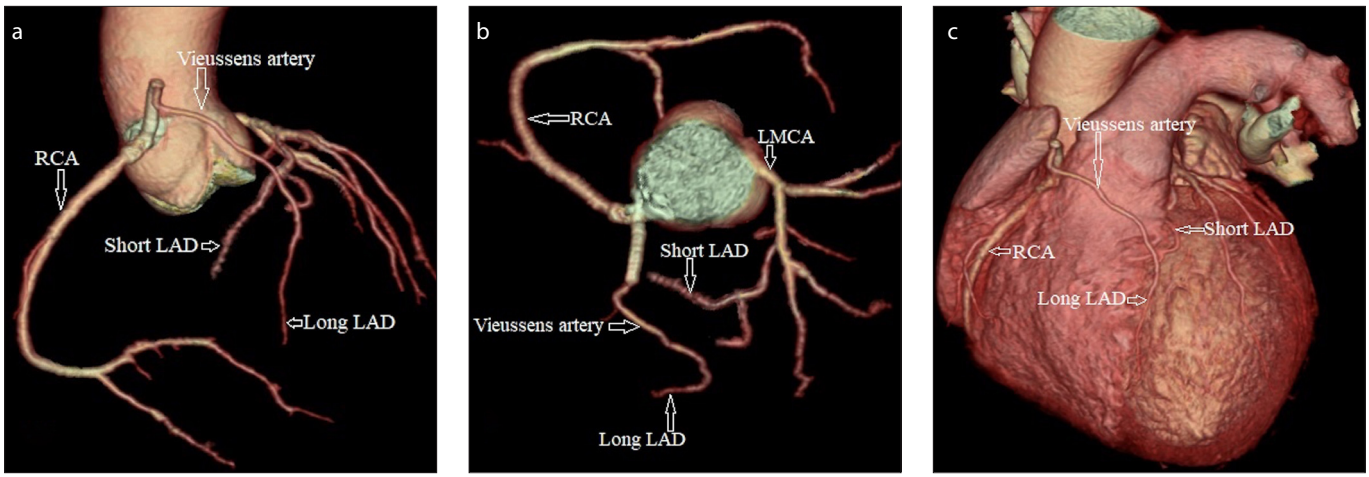

Figure 2. a–c. Type 2 VAR (type 4 LAD duplication) in 3D volume rendering **(a, b)** and heart surface volume rendering **(c)** reconstructions. A short LAD originates from the LMCA and terminates in the proximal anterior inferior sulcus (AIS) while a long LAD originates from the proximal section of the right coronary artery and enters the distal AIS after an anomalous pre-pulmonic course that lies anterior to the right ventricular outflow tract. RCA, right coronary artery; LAD, left anterior descending coronary artery; LMCA, left main coronary artery.

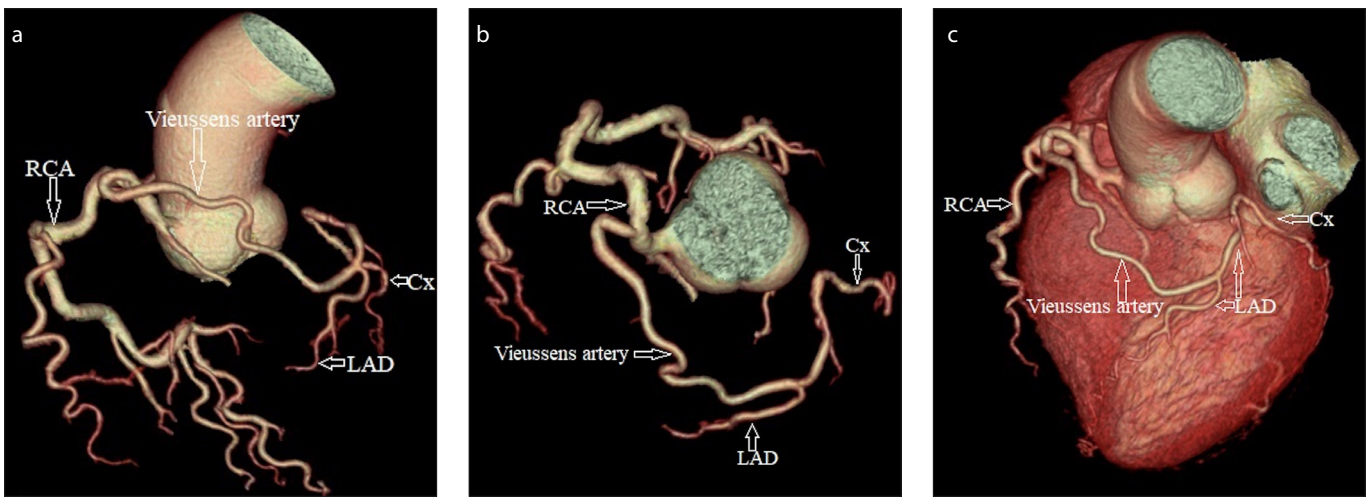

Figure 3. a–c. Type 3 VAR (a single coronary artery) in 3D volume rendering **(a, b)** and heart surface volume rendering **(c)** reconstructions. The LMCA is absent. VAR lies between the conus artery and the left anterior descending coronary artery's proximal right ventricular branch. RCA, right coronary artery; LAD, left anterior descending coronary artery; Cx, circumflex artery.

(range, 35–68 years) with 9 male and 2 female cases.

Type 1A VAR was detected in 8 cases (2.3‰; 95% CI, 1.0–4.6) (Fig. 1). Type 1B VAR was not observed. Type 2 VAR was detected in two cases (0.6‰; 95% CI, 0.1–2.1) (Fig. 2), and Type 3 was detected in one case (0.3‰; 95% CI, 0.00–1.6) (Fig. 3).

MDCT angiography was performed in 75% (n=6) of Type 1A VAR patients because of atypical chest pain and nonspecific ECG changes whereas two others were performed due to family risk factors for coronary artery disease.

One patient with Type 2 VAR underwent conventional angiography following a diagnosis of acute myocardial infarction (MI), and percutaneous coronary intervention (PCI) was performed proximal to Vieussens' artery. MDCT angiography was later requested for better visualization of the coronary arterial anatomy.

MDCT angiography was performed because of atypical chest pain and nonspecific ECG changes in the other Type 2 VAR case and all Type 3 VAR cases.

Discussion

The development of imaging methods in the cardiovascular system made it easier to diagnose diseases such as coronary anomalies. The importance of MDCT in identifying and diagnosing VAR, an important and life-saving feature, has been demonstrated in our study. Although researches by Germin and Mugge (2) showed that 48% of the population has embryonic conotruncal ring remnant of VAR, the detection rate of this anomaly by imaging methods is low. Our study showed a VAR frequency of 3.19‰.

Raymond de Vieussens in 1706 was the first to describe the proximally epicardial connection between RCA and LAD. This connection was later (19th century) called the Vieussens' arterial ring. The pressure in the right and left coronary arteries is equal and no significant flow is detected in the connection under normal conditions. When stenosis develops in one of the two systems, this vessel dilates and allows the blood flow through the low-pressure system (17, 10) (Fig. 4). Therefore, VAR could be a life-saving anomaly. In congenital life, three basic collateral pathways, including

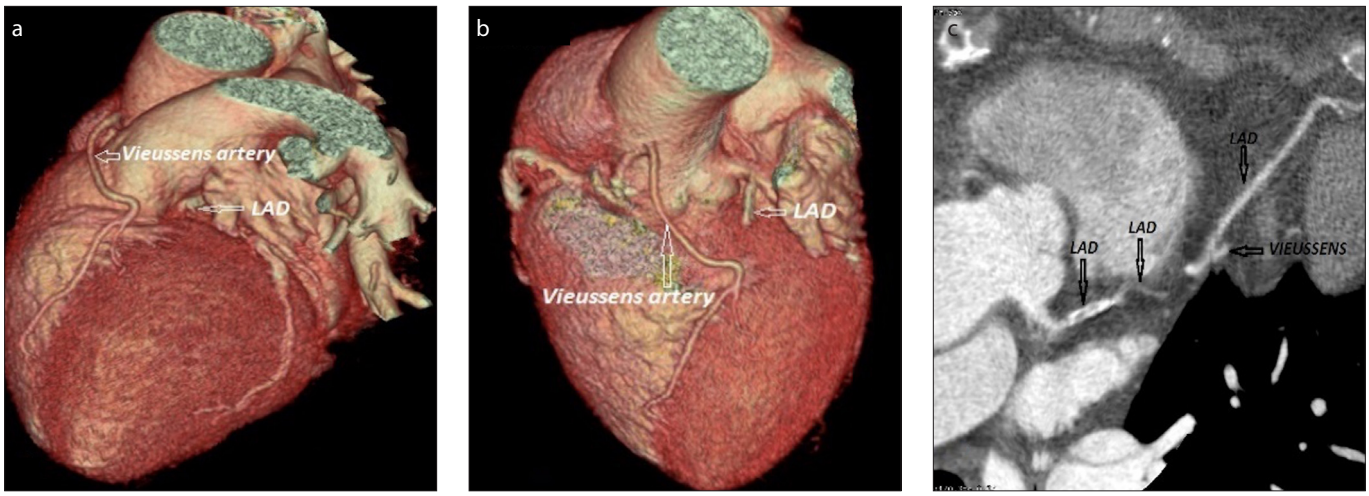

Figure 4. a–c. Total occlusion of the proximal portion of the left anterior descending artery (LAD) shown in heart surface volume rendering **(a, b)** and curve MPR **(c)** reconstructions. The connection between the conus artery and the middle portion of the LAD (Vieussens' artery) is also seen.

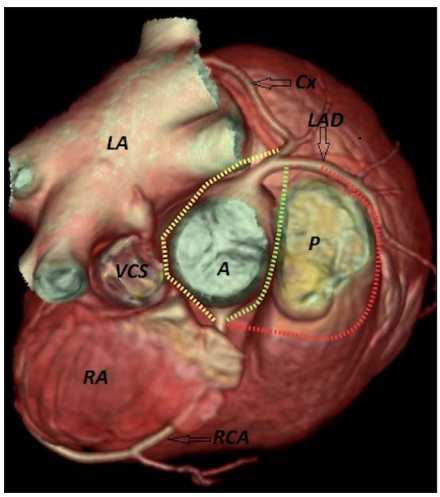

Figure 5. Conotruncal arterial anastomotic circulation schematic drawing. The three arterial anastomotic rings involved in vascular supply of the aortopulmonary trunk and the collateral circulation located between proximal right and left coronary artery systems area are shown. VAR, i.e., the preconal ring *(red line)*, includes right pulmonary conus branches from the RCA or the aorta and left conus branches from the left main or proximal LAD arteries. The right and left coronary arteries are connected with the retroconal anastomotic ring *(green line)* with collaterals going through the interarterial space behind the main pulmonary artery and anterior to the ascending aorta. Kugel's arterial anastomotic network, i.e., the retroaortic anastomotic ring, provides communication between the proximal right and left coronary systems, together *(yellow line)* or individually, with the distal coronary system bypassing through the interatrial septum. A, aorta; P, pulmonary artery; VCS, vena cava superior; LA, left atrium; RA, right atrium; RCA, right coronary artery; LAD, left anterior descending coronary artery; Cx, circumflex artery.

VAR, are defined between right and left coronary system (Fig. 5). The second collateral pathway, Kugel anastomic artery, is clinically important because it arises through the distal branches of atrioventricular node, passes behind the aorta and extends between the proximal circumflex artery (Cx) and right main coronary artery (RCA). The third collateral pathway is the retroconal anastomotic ring which connects the RCA and the LAD through the gap between the pulmonary artery and the aorta (18).

In our study, we observed that VAR was associated with other coronary anomalies and atherosclerosis. Based on these findings we classified VAR in subgroups according to MDCT imaging. Some classification systems for VAR have been suggested, but no clear clinical consensus on the normal variation and anomaly definition is made. Angelini (14), Greenberg (15), and Lipton (16) classified coronary anomalies. However, VAR has not been adequately present in these classifications. In our study we classified VAR as Type 1A, 1B, 2, and 3. Type 1A was used for cases with no pathology accompanying an appearance consistent with classic VAR. Type 1B was the presence of pathologies other than atherosclerotic disorders such as an aneurysm or fistula directly associated with the VAR. The anomaly named Type 4 LAD duplication, where the short LAD branch terminates in the anterior descending groove and the long branch originates from the right coronary circulation, passes in front of the pulmonary artery and extends to the distal section of the anterior descending groove, was also included in the Type 2 group (19). Cases with a single coronary artery anomaly together with VAR were defined as Type 3. Eleven cases of VAR were detected in our study population (3.19‰; 95%CI, 1.60–5.71). The frequency of detected VAR types were as follows: Type 1A, 8 cases (2.3‰; 95%CI, 1.0–4.6); Type 1B VAR, no cases; Type 2, 2 cases (0.6‰; 95%CI, 0.1–2.1); Type 3, 1 case (0.3‰; 95%CI, 0.00–1.6). The clinical importance of the subgroups of this variant was not identified but anatomically all subgroups of VAR variants were different from each other.

This study has some limitations. This study is not a population screening study. The data was collected from patients who presented to the hospital for check-up or were referred for coronary CT angiography by the cardiology clinic. Only patients from a specific geographical region were included in the study. This study would benefit if our data could be compared with data from patients of different geographical regions.

In conclusion, MDCT enables us to clearly map coronary arteries and their variants. Recognition of the collateral pathways between the right and left coronary systems, especially VAR, will contribute to more accurate evaluation, particularly in cases where revascularization or surgery is planned. Therefore, the definition of VAR subtypes will be clinically important.

Conflict of interest disclosure

The authors declared no conflicts of interest.

References

1. De Agustín JA, Marcos-Alberca P, Hernández-Antolín R, et al. Collateral circulation from the conus coronary artery to the anterior descending coronary artery: assessment using multislice coronary computed tomography. Rev Esp Cardiol 2010; 63:347–351. [CrossRef]
2. Germing A, Mugge A. Images in cardiology: Vieussens' ring. Clin Cardiol 2003; 26:441. [CrossRef]

3. O'Leary EL, Garza L, Williams M, McCall D. Images in cardiovascular medicine. Vieussens' ring. Circulation 1998; 98:487–488. [CrossRef]
4. Alsancak Y, Ali S, Duran M, Saatci Yaşar A, Bilge M. An unusual image of Vieussens' arterial ring communicating with the pulmonary artery. Anatol J Cardiol 2015; 15:E13–14. [CrossRef]
5. Atallah PC, Atallah PC, Spears JR. Vieussens' ring with congenitally hypoplastic left coronary arterial system. Int J Cardiol 2011; 152:e31–32. [CrossRef]
6. Bamoshmoosh M, F anfani F, Volpe C. Vieussens' arterial ring visualized by MDCT. Open J Radiol 2014; 4:9–12. [CrossRef]
7. Cam F, Gungor H, Unal M, Eryilmaz U. Life-saving necklace: collateral circulation from the conus artery to the anterior descending artery. Postepy Kardiol Interwencyjnej 2013; 9:109–110. [CrossRef]
8. Chan CY, Lee PW, Lam YY, Chan WW, Wong KT, Yu CM. Detection of large aneurysm of Vieussens' arterial ring after abnormal shadow on chest radiography. Circulation 2009; 120:e134–136. [CrossRef]
9. De Agustin JA, Nunez-Gil IJ, del Carmen Manzano M et al. C.Occlusion of the left main coronary artery and collateral circulation via the conus branch. J Cardiovasc Med (Hagerstown) 2009; 10:431–432. [CrossRef]
10. Hansen MW, Merchant N. Images in cardiovascular medicine. Vieussens' ring: combining computed tomography coronary angiographyand magnetic resonance imaging in assessing collateral pathways. Circulation 2006; 114:e545–546. [CrossRef]
11. Lee HY, Cho SH. An unusual form of coronary artery fistula: a small aneurysm of vieussens' arterial ring communicating with the pulmonary artery. Korean J Thorac Cardiovasc Surg 2014; 47:152–154. [CrossRef]
12. Sánchez-Soriano RM, Chamorro-Fernández CI, Raso-Raso R, Valencia J, Mainar V, Grau-Jornet G. Patient with angina and "congenital bypass". A new case of aortocoronary fistula. Rev Esp Cardiol (Engl Ed) 2013; 66:825–827. [CrossRef]
13. Singla R, Sasidharan B."Vieussens ring" from isolated conus artery. Indian Heart J 2013; 65:482–483. [CrossRef]
14. Angelini P, Velasco JA, Flamm S Coronary anomalies: incidence, pathophysiology, and clinical relevance. Circulation 2002; 105:2449–2454. [CrossRef]
15. Greenberg MA Congenital anomalies of the coronary arteries. Classification and significance. Radiol Clin North Am 1989; 27:1127–1146.
16. Lipton MJ, Barry WH, Obrez I, Silverman JF, Wexler L Isolated single coronary artery: diagnosis, angiographic classification, and clinical significance. Radiology 1979; 130: 39–47. [CrossRef]
17. Latson LA. New look at an old ring. Catheter Cardiovasc Interv 2008; 71:572. [CrossRef]
18. Angelini P Coronary artery anomalies: an entity in search of an identity. Circulation 2007; 115:1296–1305. [CrossRef]
19. Bozlar U, Uğurel MŞ, Sarı S, Akgün V, Örs F, Taşar M. Prevalence of dual left anterior descending artery variations in CT angiography. Diagn Interv Radiol 2015; 21:34–41. [CrossRef]